Treatment of skin graft donor sites with a unique absorbent clear acrylic dressing*

Marcia Spear, APRN-BC, CPSN, CWS and Amanda E. Bailey, APRN-BC, CWS, CRRN

Department of Plastic Surgery, Vanderbilt University Medical Center, Nashville, TN, USA

Background

CLINICAL PROBLEM: The goal of treating skin graft donor sites is to promote healing while minimizing the risk of introducing new complications and pain to an already traumatized patient. An old and still practiced strategy is to cover the wound with petrolatum (paraffin) gauze and allow it to dry out. Drying was often accomplished with the use of hair dryers, heating blankets (bear huggers), or air drying. The procedure often resulted in pain and discomfort for the patient, and vigilance was needed to regularly trim the edges of the dressing as it peeled away from the healing wound. If not done, the dressing could catch on clothing or linen, causing pain to the patient, trauma to the wound, and necessitating a repeat of the drying process. Essentially, the wound was left open to scab, which is contradictory to the best evidence-based practice of today, that of moist wound healing.

In recent years, much has been published highlighting the benefits of moisture-retentive dressings in treating donor sites. Moisture-retentive dressings that have been used include hydrocolloids, foams, and transparent thin film dressings, alone or in combination with absorbent materials such as alginates, hydrofibers or gauze. While hydrocolloids and foams provide the needed absorbency, they must be removed whenever wound inspection is required, increasing treatment cost and the risk of traumatizing the wound. Thin film dressings allow for wound visualization, but usually fail to contain the drainage for more than 24 hours, even when used secondary to other absorbent dressings (which also negates the benefit of transparency).

A moisture-retentive, absorbent clear acrylic dressing has been introduced which combines the benefits of highly absorbent dressings such as hydrocolloids, foams, alginates and hydrobibers with the transparency of thin film dressings. Recent published work indicates that this dressing provides excellent results with skin donor sites.[1,2]

Methods

Twelve patients with skin donor wounds were recruited and enrolled in this case study series. The absorbent clear acrylic dressing was applied to donor sites post-operatively on day one (POD-1) and subsequently followed for up to 21 days or until dressing leakage, whichever came first. Wounds were evaluated for healing, leakage, and pain. Healing was noted when 90% of the surface had epithelialized, leakage was determined visually as drainage outside of the dressing enclosure, and pain was evaluated using a 10-point Likert scale. Case studies are presented for 3 of the enrolled patients and summary results are presented for all of the patients enrolled into the study.

Case Study 1

A 49-year-old male presented with an open wound of the right popliteal space following excision of a cystic lesion. Subsequently, the wound was debrided in preparation for a gastrocnemius muscle flap coverage with a split thickness skin graft.

The donor site on the right lateral thigh measured 10.5 x 4.5 cm with a depth of 0.010 inches. A transparent film dressing was used as the initial post surgical dressing. Wound drainage leaked from under the transparent film dressing on POD-1.

The patient reported his pain to be 7/10 at the donor site during the first 24 hour post operative period. During removal of the transparent film dressing and cleansing of the donor site, the patient reported his wound pain to be 2/10.

Following cleansing of wound, two 20.0 X 20.3 cm absorbent clear acrylic dressings (pad size 14.9 x 15.2 cm, #90805) were applied. The patient reported his pain level to be 0/10 immediately following dressing application.

The dressings remained intact for 16 days without leakage. At a follow-up appointment on POD-16, the absorbent clear acrylic dressings were removed, and the donor site was healed.

POD 1: Wound before placement of dressing.

POD 1: Wound with the absorbent clear acrylic dressing in place.

POD 5: Absorbent clear acrylic dressing in place.

POD 16: Wound after removal of the dressing.

Case Study 2

A 53-year-old female presented with dog bite injuries including bilateral ulna and radius fractures, massive soft tissue injuries and complete devascularization of her hands. Although the bones were stabilized and revascularized, she had ongoing, large open wounds with necrosis requiring subsequent debridement and intensive wound care. Eventually, a bilayer skin substitute was placed over the wound. After total wound bed granulation was complete, the patient had a split thickness skin graft to her right arm.

The donor site on the left lateral thigh measured 12.5 x 2 cm with a depth of 0.010 inches. The initial post operative dressing consisted of a silver layer, a hydrofiber, and a transparent film dressing. Wound drainage leaked from under the transparent film dressing on POD-1.

The patient reported her pain to be 6/10 at the donor site during that first 24 hour post operative period. During removal of the initial dressing and cleansing of the donor site, the patient reported her wound pain to be 4/10.

Following cleansing of the donor site two 20.0 X 20.3 cm absorbent clear acrylic dressings (pad size 14.9 x 15.2 cm, #90805) were applied. The patient reported her pain level to be 4/10 immediately following dressing application.

The dressings remained intact for 19 days without leakage. At a follow-up appointment on POD-19, the dressings were removed and the donor site was healed.

POD 1: Wound before placement of dressing.

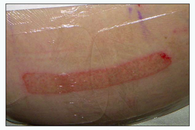

POD 1: Wound with the absorbent clear acrylic dressing in place.

POD 15: Absorbent clear acrylic dressing in place.

POD 19: Wound after removal of the dressing.

Case Study 3

This 86-year-old female presented with a malignant melanoma of the scalp. She underwent resection and closure of the defect with local advancement flaps and application of a split thickness skin graft over the resulting defect.

The donor site on the left anterior thigh measured 14 x14 cm with a depth of 0.010 inches. A hydrofiber and a transparent film dressing were used as the initial post operative dressing. Wound drainage leaked from under the transparent film dressing on POD-1.

The patient reported her pain to be 2/10 at the donor site during the first 24 hour post operative period. During removal of the hydrofiber and transparent film dressing and cleansing of the donor site, the patient reported her pain to be 4/10.

Following cleansing of the donor site, four 20.0 X 20.3 cm absorbent clear acrylic dressings (pad size 14.9 x 15.2 cm, #90805) were applied. The patient reported her pain level to be 0/10 immediately following dressing application.

The absorbent clear acrylic dressings remained intact for 15 days without leakage. On POD-15 the dressings were removed, and the donor site was healed.

POD 1: Wound before placement of dressing.

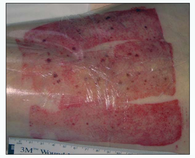

POD 1: Wound with the absorbent clear acrylic dressing in place.

POD 15: Absorbent clear acrylic dressing in place.

POD 15: Wound after removal of the dressing.

Results

- Twelve patients with 13 donor site wounds were enrolled into the study. Six patients were male and 6 were female. Average (SD) age was 50 (21) years.
- One patient was still ongoing at the time of this report and 3 were discontinued for reasons unrelated to the study dressing.
- Wound healing occurred in 7 of the remaining 9 wounds within the 21-day follow up period. One of the 2 open wounds was 50% healed when dressing leakage occurred on POD-10. The other open wound was later determined to be a full thickness wound after the dressing was removed on POD-21.
- In most cases (10/13 wounds), the dressings remained in place and functional until the wound healed or the patient was discontinued.
- Average (SD) time to healing for the 7 wounds that healed was 14.3 (2.9) days.
- Average (SD) dressing wear time for the 9 wounds that completed the study was 14.6 (3.7) days.
- Median (range) pain score before and after application of the dressing was 3 (0-7) and 0 (0-5), respectively.

Conclusions

- The absorbent clear acrylic dressing allowed for monitoring of the donor site without unnecessary dressing change or disruption of the wound bed.
- Wear time for the absorbent clear acrylic dressing exceeded our expectations, remaining functional until the wound was healed or the patient was discontinued from the study.
- The majority of patients reported a decrease in pain with use of an absorbent clear acrylic dressing on the donor site.
- No additional adhesive products were required to maintain dressing integrity.
- In our experience with these highly draining wounds, the dressing should be applied such that the absorbent pad overlaps onto healthy skin approximately 2-4 inches.
- Based on our outcomes, we recommend that the dressing be applied on POD-1 and stay in place until at least POD-14 and no later than POD-21. This is the general healing time for most partial thickness donor sites. If patient's age is over 65 years, longer wear time (up to POD-21) is recommended, as these patients generally require more time to heal.

Footnotes:

* 3M™ Tegaderm™ Absorbent Clear Acrylic Dressing

References:

1. Terrill P. Pr02 the split thickness skin graft donor site; have we found the perfect dressing? ANZ J Surg 2007;77 Suppl 1:A62.
2. Terrill PJ, Goh RCW, Bailey MJ. Split thickness skin graft donor sites: comparative study of two absorbent dressings. J Wound Care 2007;16(10):453-458.

Acknowledgements

Poster design by Lutz Consulting LLC

This study was supported by 3M Health Care