

3M ESPE

Clinical Case Studies



Express 2

VPS Impression Materials

Replacement of Insufficient PFM Crown by 3M™ ESPE™ Lava™ Zirconia Crown

Clinical Case by Dr. med. dent. Gunnar Reich, Munich, Germany

Initial situation:

Insufficient 2 year old PFM Crown with large destruction of tooth 36 on its lingual aspect. Tooth 36 underwent endodontical treatment 1½ years ago. The insufficient crown was replaced by an all ceramic Lava™ Crown.

Treatment plan:

The insufficient crown was removed, and the caries was completely excavated (Fig. 1). Revision of the endodontical treatment was considered as not necessary based on X-ray examination and visual control. Two 3M™ ESPE™ RelyX™ Fiber Posts were inserted in tooth 36 (Fig. 2) to stabilise the following core build-up with 3M™ ESPE™ Filtek™ Z250 Universal Restorative System (Fig. 3). Precision impression using 2-step impression technique with full arch metal trays was taken with 3M™ ESPE™ Express™ 2 Penta™ H Universal Quick and Express™ 2 Light Body Flow Quick VPS Impression Materials (blue, Fig. 4, 5, 6, 7).

A second 2-step impression was taken with the somewhat thicker 3M™ ESPE™ Express™ 2 Light Body Standard Quick Wash Material (pink, Fig. 8, 9, 10). A temporary crown was made with 3M™ ESPE™ Protemp™ 3 Garant™ Composite for Temporary Crowns and Bridges, and cemented with 3M™ ESPE™ RelyX™ Temp NE Temporary Cement Zinc Oxide (Non-Eugenol). Final Lava™ Crown restoration (Fig. 11) was permanently cemented with 3M™ ESPE™ RelyX™ Unicem Self-Adhesive Resin Cement (Fig. 12).

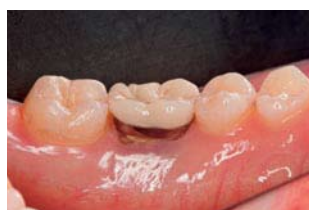

Fig. 1: Initial situation – Insufficient PFM crown with large carious lesion at lingual aspect of tooth 36

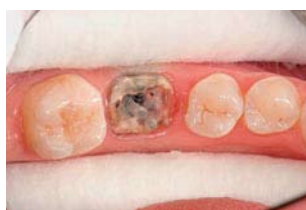

Fig. 2: Tooth 36 reinforced with 2 fiber posts, occlusal view

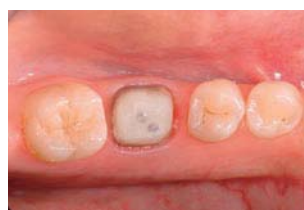

Fig. 3: Tooth 36 after core build-up and circular chamfer preparation for Lava™ Crown restoration, occlusal view

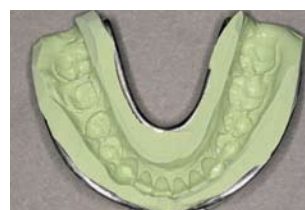

Fig. 4: Initial impression Express™ 2 Penta™ H Universal Quick after carving

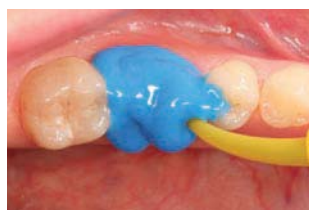

Fig. 5: Intra-oral syringing with Express™ 2 Light Body Flow Quick

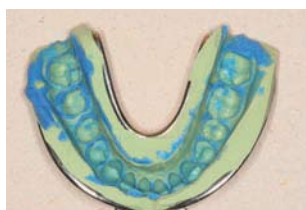

Fig. 6: Express™ 2 Penta™ H Universal Quick & Express™ 2 Light Body Flow Quick 2-step Impression Material

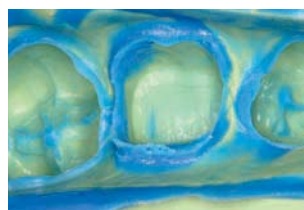


Fig. 7: Close-up 2-step impression – Express™ 2 Penta™ H Universal Quick & Express™ 2 Light Body Flow Quick Impression Material

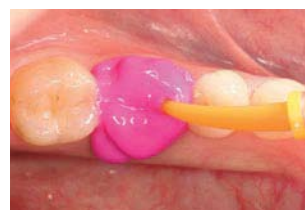

Fig. 8: Intra-oral syringing with Express™ 2 Light Body Standard Quick 2-step Impression Material

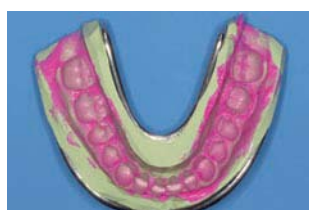

Fig. 9: Express™ 2 Penta™ H Universal Quick & Express™ 2 Light Body Standard Quick 2-step Impression Material

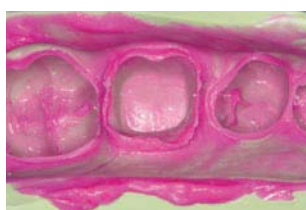

Fig. 10: Close-up 2-step impression Express™ 2 Penta™ H Universal Quick & Express™ 2 Light Body Standard Quick Impression Material

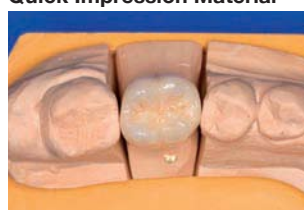

Fig. 11: Final Lava™ Crown on split cast model, occlusal view

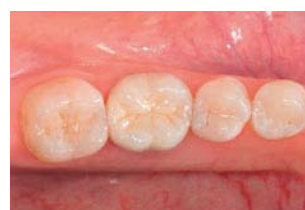

Fig. 12: Final Lava™ Crown in patients mouth, occlusal view

Aesthetics in the Anterior Region: Two 3-unit PFM Restorations replaced by 3M™ ESPE™ Lava™ Bridges in the Upper Anterior Region

Clinical Case by Dr. med. dent. Christoph Zawta, Meran, Italy

Initial situation:

Poor aesthetics in the upper anterior region due to old insufficient PFM bridges 13, 12, 11 and 21, 22, 23 with recurrent caries and partly exposed crown margins (Fig. 1, 2). The patient was very unsatisfied with this situation. In order to re-establish the aesthetic aspect in the anterior region the old restorations were replaced by new PFM bridges and tooth 24 was restored with an Empress-Inlay.

Treatment plan:

After removal of the insufficient restorations and restorative pre-treatment a direct temporary bridge (3M™ ESPE™ Protemp™ 3 Garant™ Composite for Temporary Crowns and Bridges) was inserted (Fig. 3). Subsequently periodontal pre-treatment was performed. After a healing period of 3 months a chamfer preparation was carried out for the abutment teeth 13, 11, 21, 23. Ultrapak cords (Size 00, 0) have been placed for retraction of the gingival tissue in two-cord technique (Fig. 4). The precision impression using 1-step impression technique was done with 3M™ ESPE™ Express™ 2 Penta H and Express™ 2 Light Body Flow VPS Impression Materials (Fig. 5). Tray and wash materials offer a very good colour contrast allowing an excellent readability of all relevant details. Fig. 6 exhibits a detailed view of the upper central incisors showing that the preparation margins for both abutment teeth are entirely captured. Neither tears nor voids occurred at the preparation margins or at other relevant areas. A master model has been created (Fig. 7). Fig. 8 shows the precise fit of the high-gold alloy frameworks on the master model. The intra-oral try-in of the frameworks showed an excellent precision of fit (Fig. 9). After try-in of the firstly fired frameworks the PFM bridges with ceramic shoulders were glaze fired and finalised. (Fig. 10). The bridge restorations were permanently cemented with 3M™ ESPE™ RelyX™ Unicem Self-Adhesive Resin Cement (Fig. 11, 12).

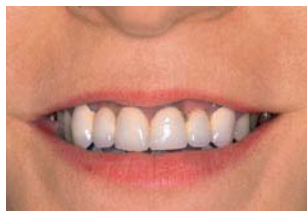

Fig. 1: Initial situation – Insufficient PFM bridges

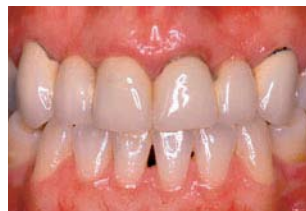

Fig. 2: Close-up initial situation – insufficient PFM bridges

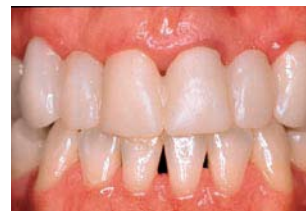

Fig. 3: Close-up Protemp™ Temporary in mouth

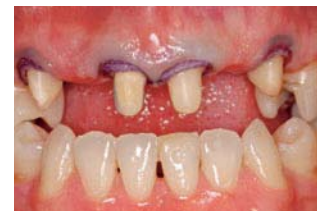

Fig. 4: Prepared teeth 13, 11, 21, 23 with retraction cords in place

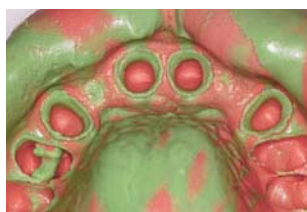

Fig. 5: Precision impression Express™ 2 Penta™ H & Express™ 2 Light Body Flow Impression Material

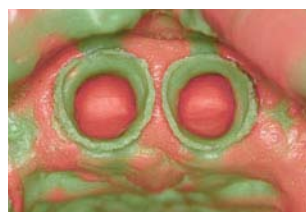

Fig. 6: Close-up precision impression Express™ 2 Penta™ H & Express™ 2 Light Body Flow Impression Material teeth 11, 21

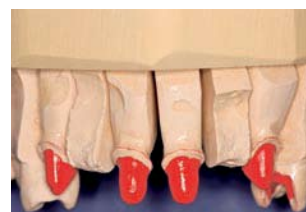

Fig. 7: Split cast model, prepared, buccal view

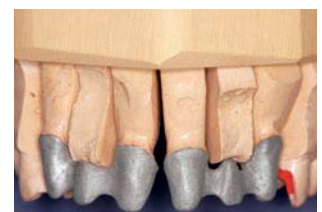

Fig. 8: Bridge frameworks on master model, buccal view

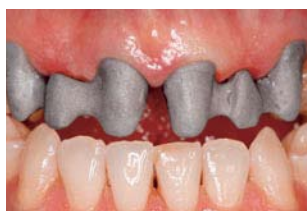

Fig. 9: Bridge frameworks in patient's mouth, buccal view

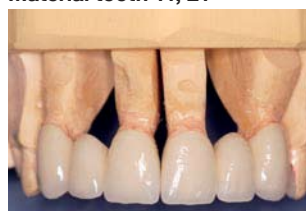

Fig. 10: Final bridge restoration on split cast model, buccal view

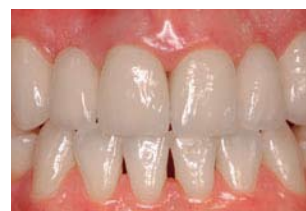

Fig. 11: Final restoration inserted in mouth, buccal view

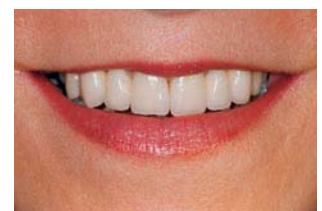

Fig. 12: Smiling patient with final restoration

Lava™ Crown Zirconia Restoration

Clinical Case by Dr. med. dent. Vivien Porsfeld, Munich, Germany

Initial situation:

Endodontically treated tooth 26 temporarily restored with 3M™ ESPE™ Filtek™ Supreme XT Flowable Restorative (Fig. 1). Tooth 26 required full crown restoration due to large occlusal defect and advanced crack at its mesial aspect. The patient chose to have an all ceramic restoration.

Treatment plan:

After removal of the temporary restoration, tooth 26 has been built-up with Filtek™ Z250 universal restorative system followed by a circular chamfer preparation for the 3M™ ESPE™ Lava™ Crown (Fig. 2). A precision impression with full arch metal tray was taken with 3M™ ESPE™ Express™ 2 Penta™ H Quick and Express™ 2 Light Body Flow Quick VPS Impression Materials (blue, Fig. 3, 4,5). A second impression was taken with the somewhat thicker 3M™ ESPE™ Express™ 2 Light Body Standard Quick Wash Material (pink, Fig. 6).

Both new wash material consistencies showed great flow characteristics – they perfectly flowed into the deep sulcus, far below the preparation margins. For both impressions the colour contrast between tray and wash material was very good, allowing an excellent readability of all relevant details. Both impressions entirely captured the preparation margins of the prepared teeth (Fig. 5, 6). Neither tears nor voids occurred at the preparation margins or at other relevant areas.

The impression for the temporary crown was made with the 3M™ ESPE™ Position™ Tray and with Position™ Penta™ Vinyl Polysiloxane Preliminary Impression Material. Crown temporary was made with 3M™ ESPE™ Protemp™ 3 Garant™ Composite for Temporary Crowns and Bridges, and cemented with 3M™ ESPE™ RelyX™ Temp NE Temporary CementZinc Oxide (Non-Eugenol). Final Lava crown restoration (Fig. 7, 8) was permanently cemented with 3M™ ESPE™ RelyX™ Unicem Self-Adhesive Resin Cement.

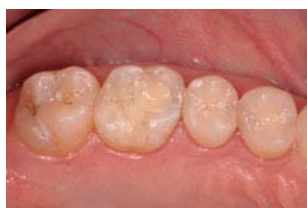

Fig. 1: Initial situation – tooth 26 temporarily restored with Filtek Supreme XT restorative

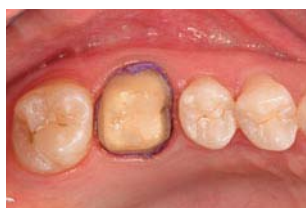

Fig. 2: Tooth 26 prepared, with retraction cords in place, occlusal view

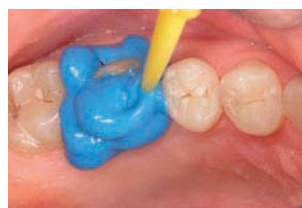

Fig. 3: Intra-oral syringing with Express 2 Light Body Flow Quick Impression Material

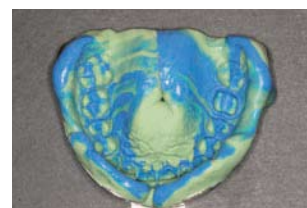

Fig. 4: Express 2 Penta H Quick & Express 2 Light Body Flow Quick Impression Material

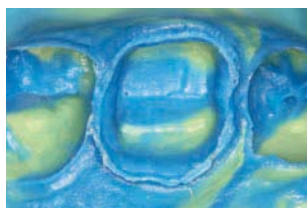


Fig. 5: Close-up Express 2 Penta H Quick & Express 2 Light Body Flow Quick Impression Material

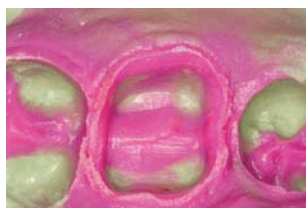

Fig. 6: Close-up Express 2 Penta H Quick & Express 2 Light Body Standard Quick Impression Material

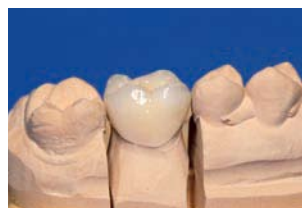

Fig. 7: Final Lava crown restoration on model, buccal view

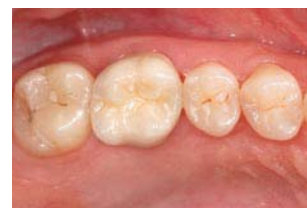

Fig. 8: Final Lava restoration inserted in mouth, occlusal view

3M ESPE

3M House
Morley Street
Loughborough
Leicestershire
LE11 1EP

3M, ESPE, Express, Filtek, Garant, Lava, Penta, Position, Protemp and RelyX are trademarks of 3M or 3M ESPE AG.

© 3M 2007. All rights reserved. IPS Empress is a trademark of Ivoclar Vivadent. Ultrapak is a trademark of Ultradent Products Inc.