

**Case Study:** 3M™ Clarity™ Aligners

**Correction of deep bite and mild crowding.**

**Age:** 50

**Total number of aligners:** 36 (dual arch)

**Wear interval:** Weekly

**Treatment time:** 10 months

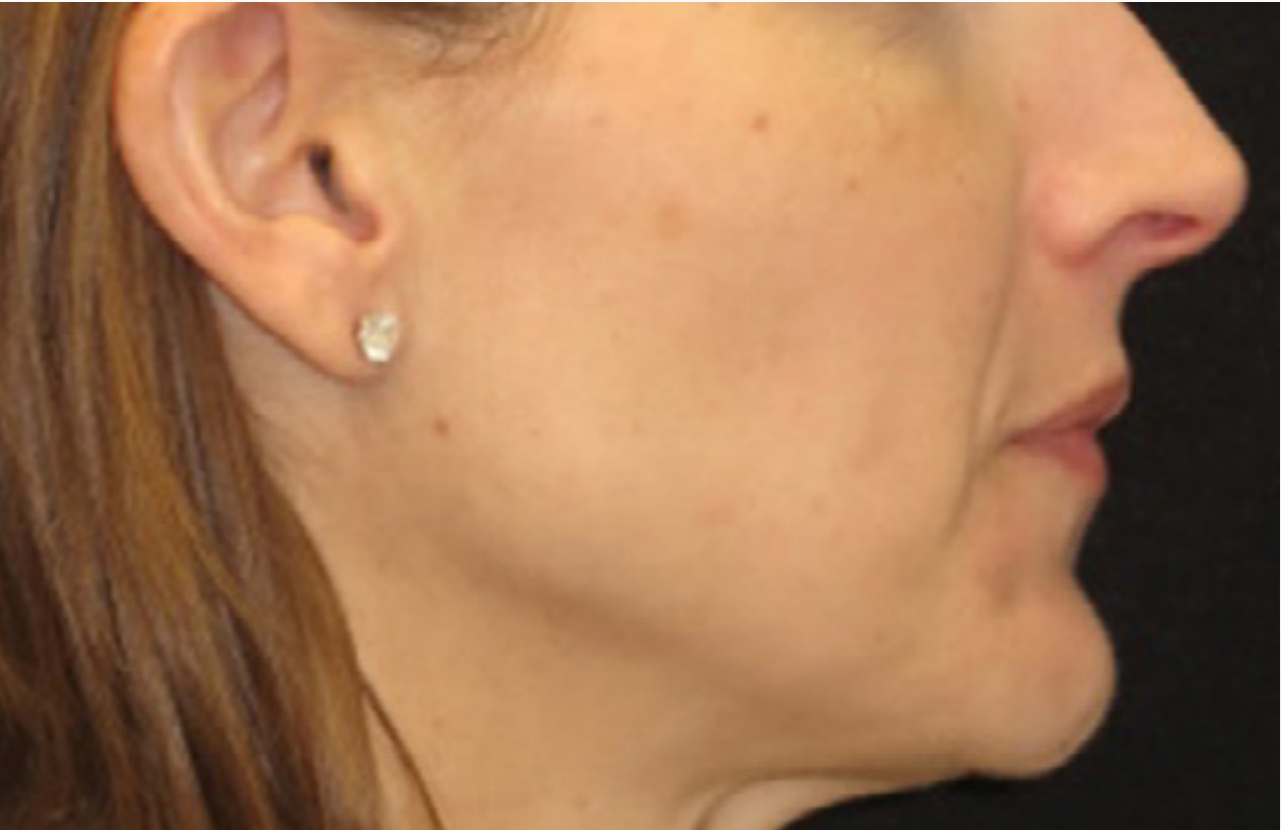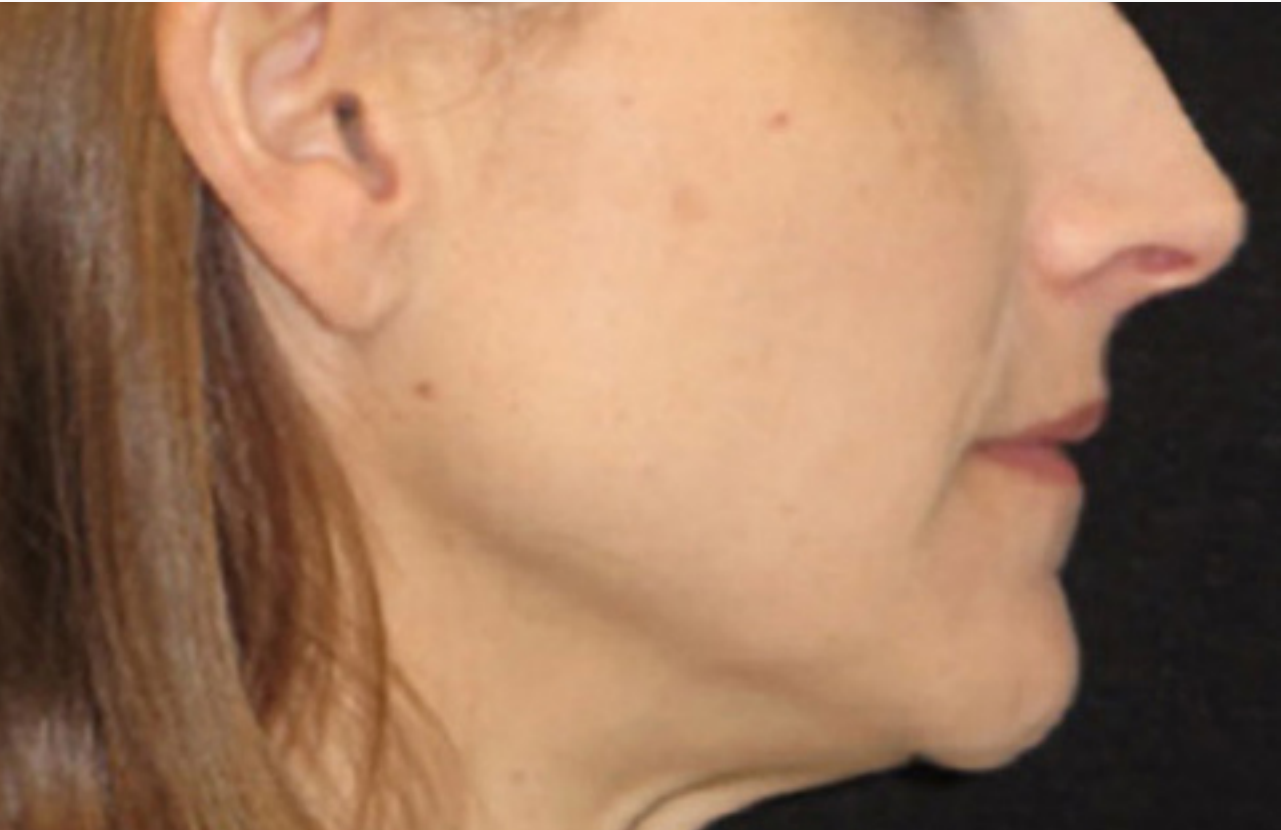**IPR:** Total IPR on Lower Arch = 0.8 mm

**Case courtesy of:**  
Hughes Orthodontics  
Alexandria, VA – USA

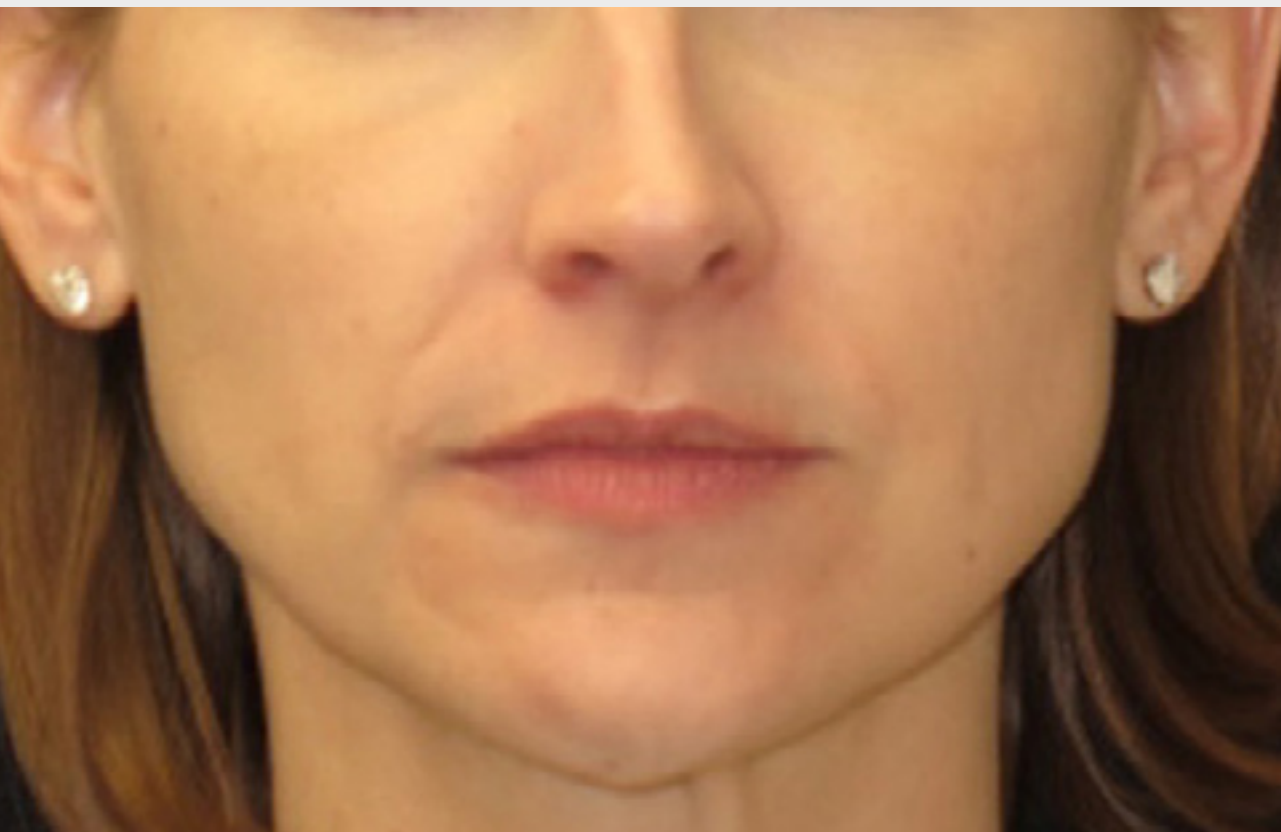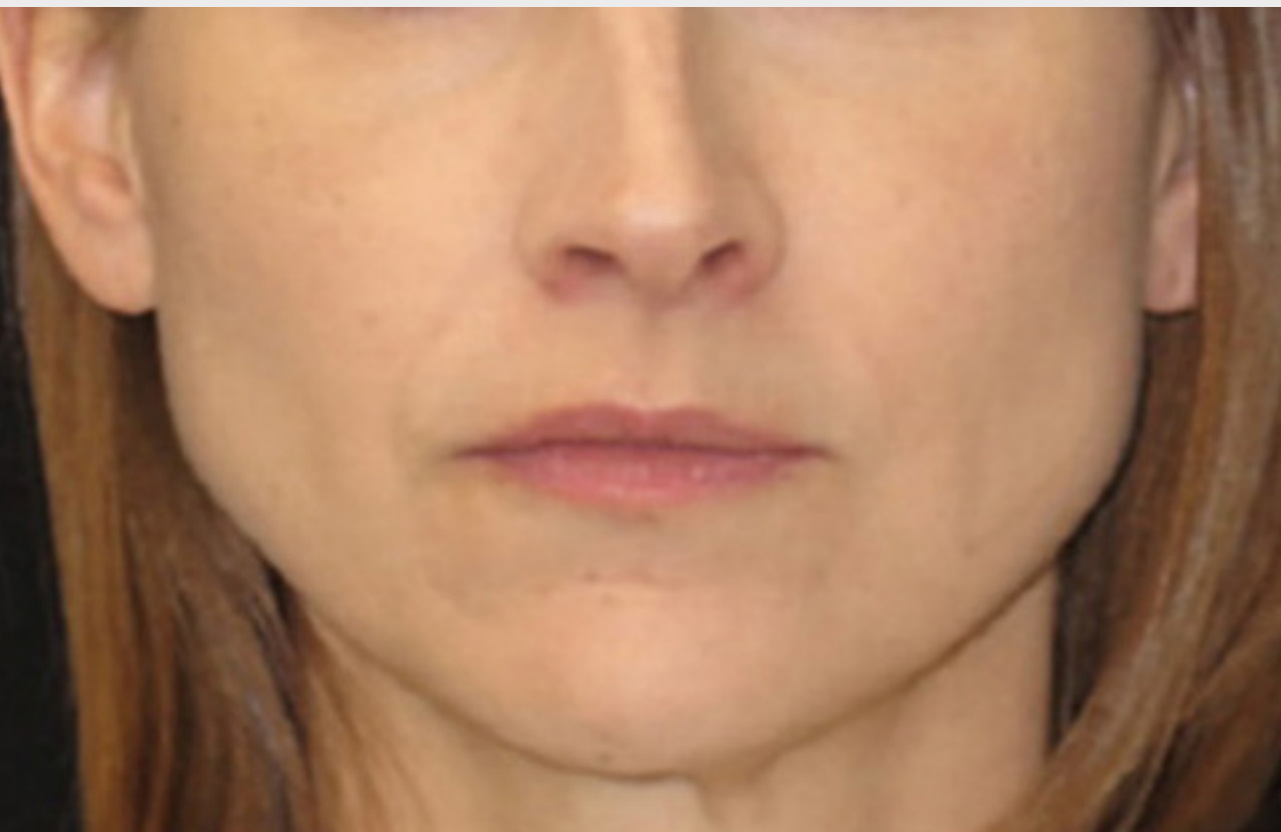**Initial**

**Final**

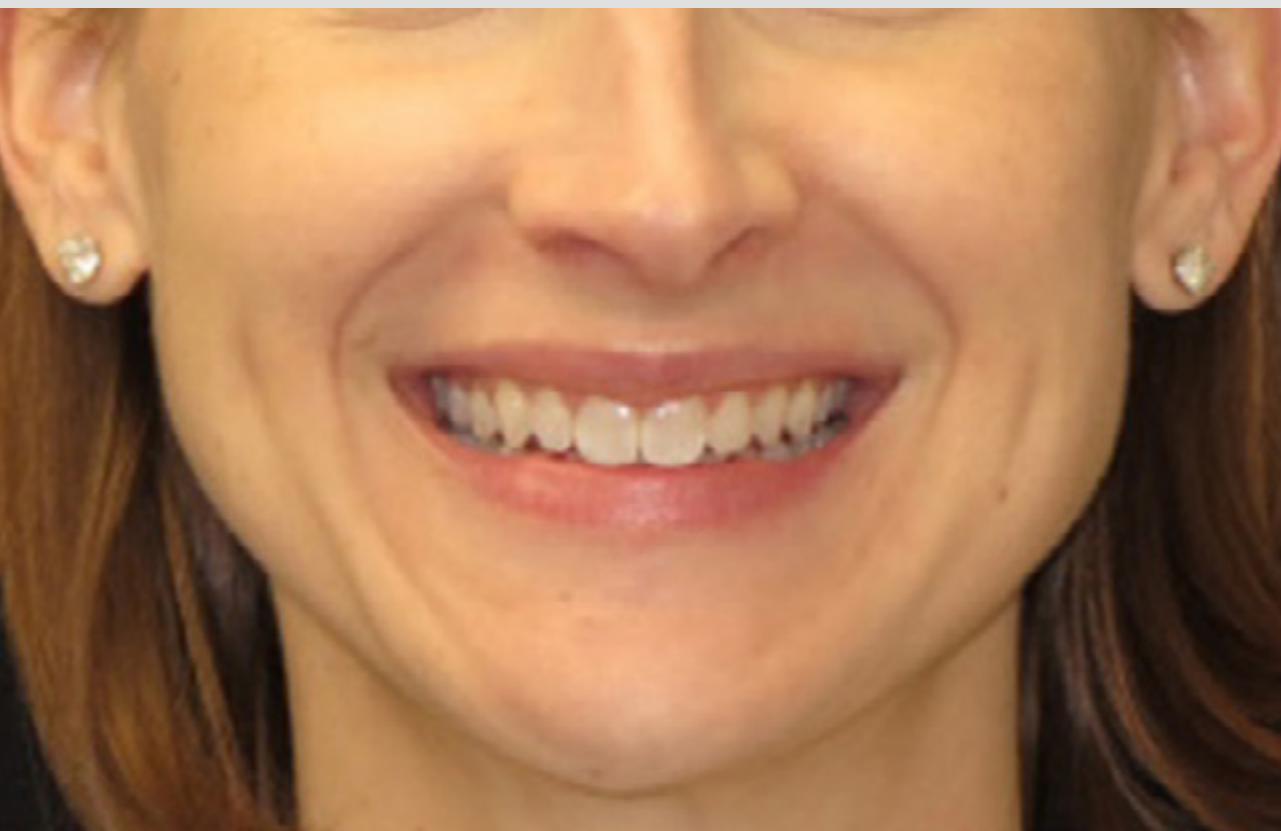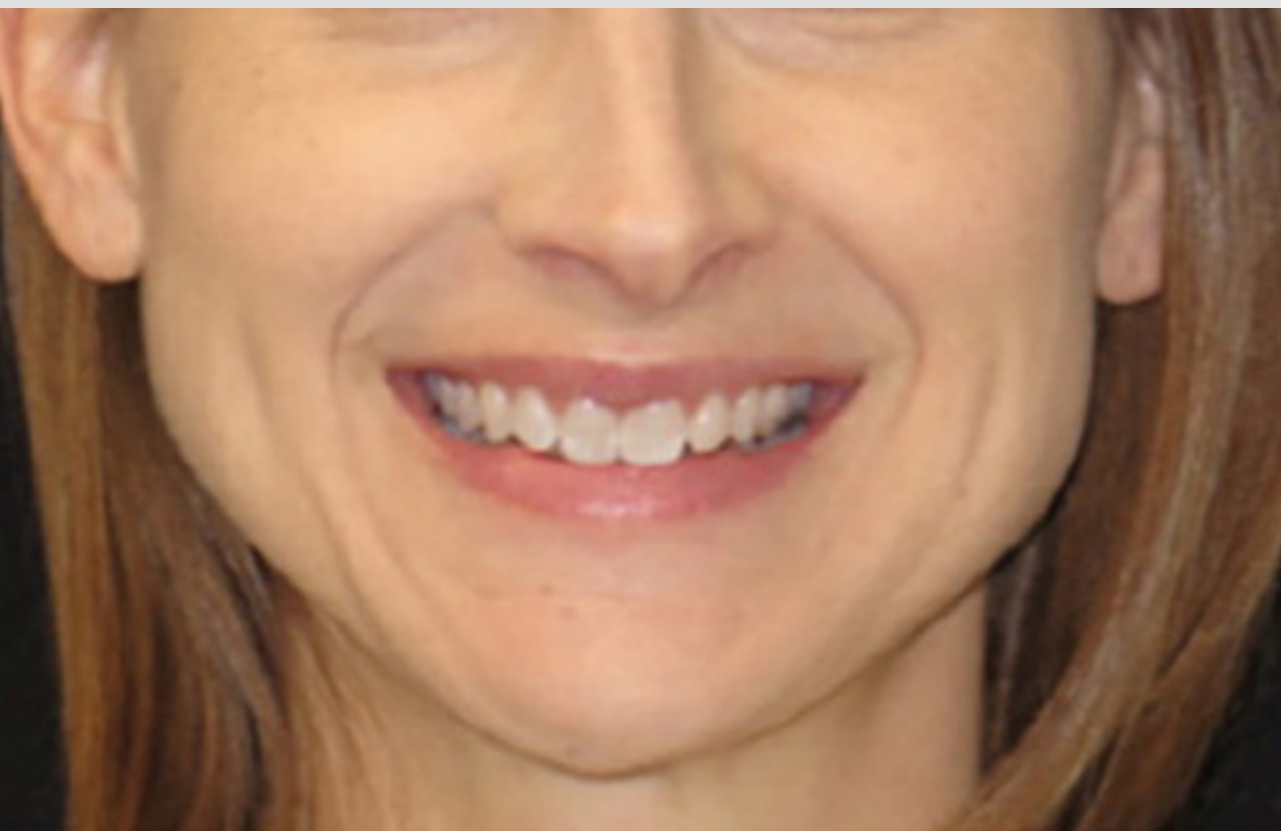**Profile at rest**



**Face at rest**



**Face smiling**

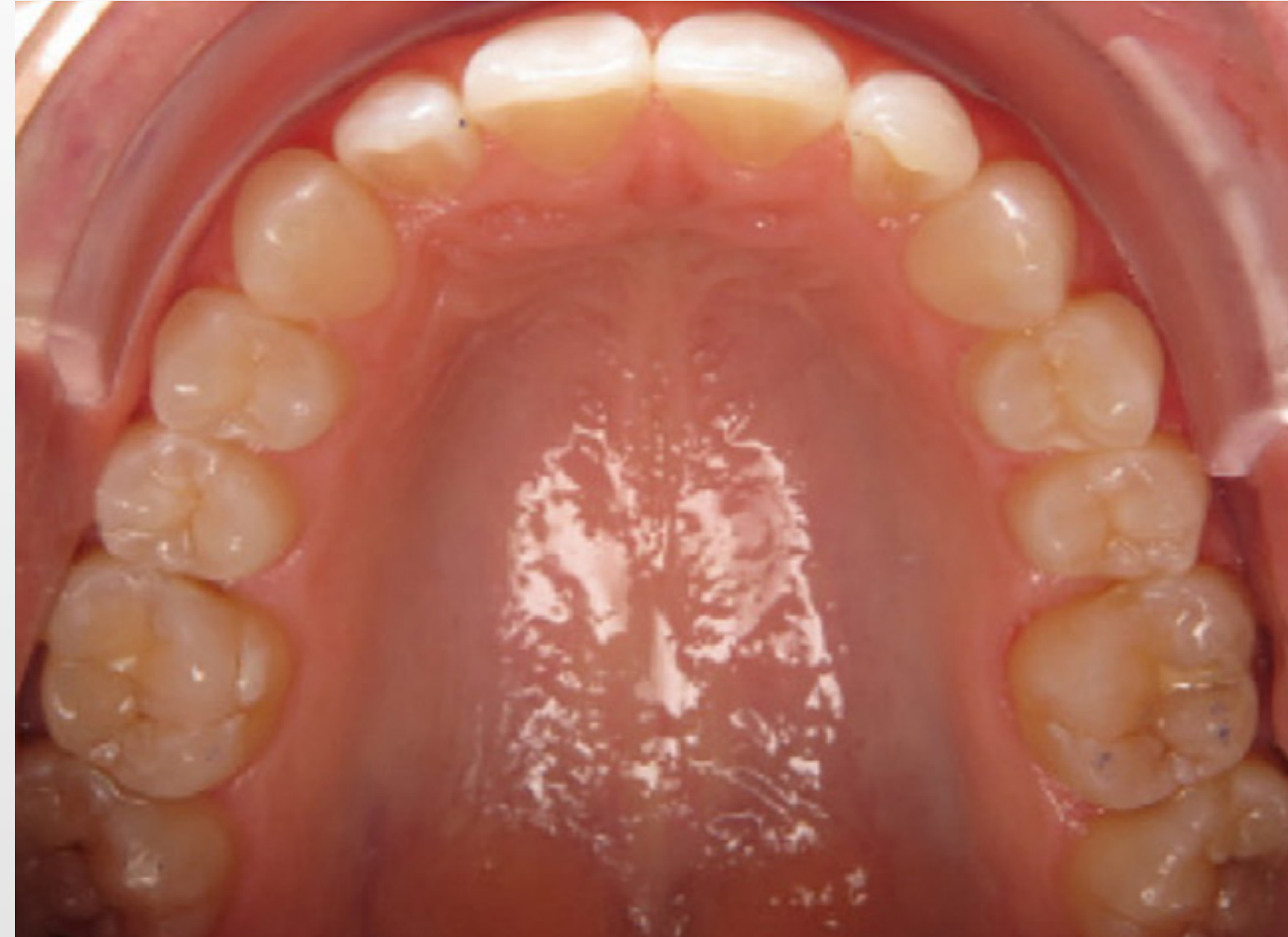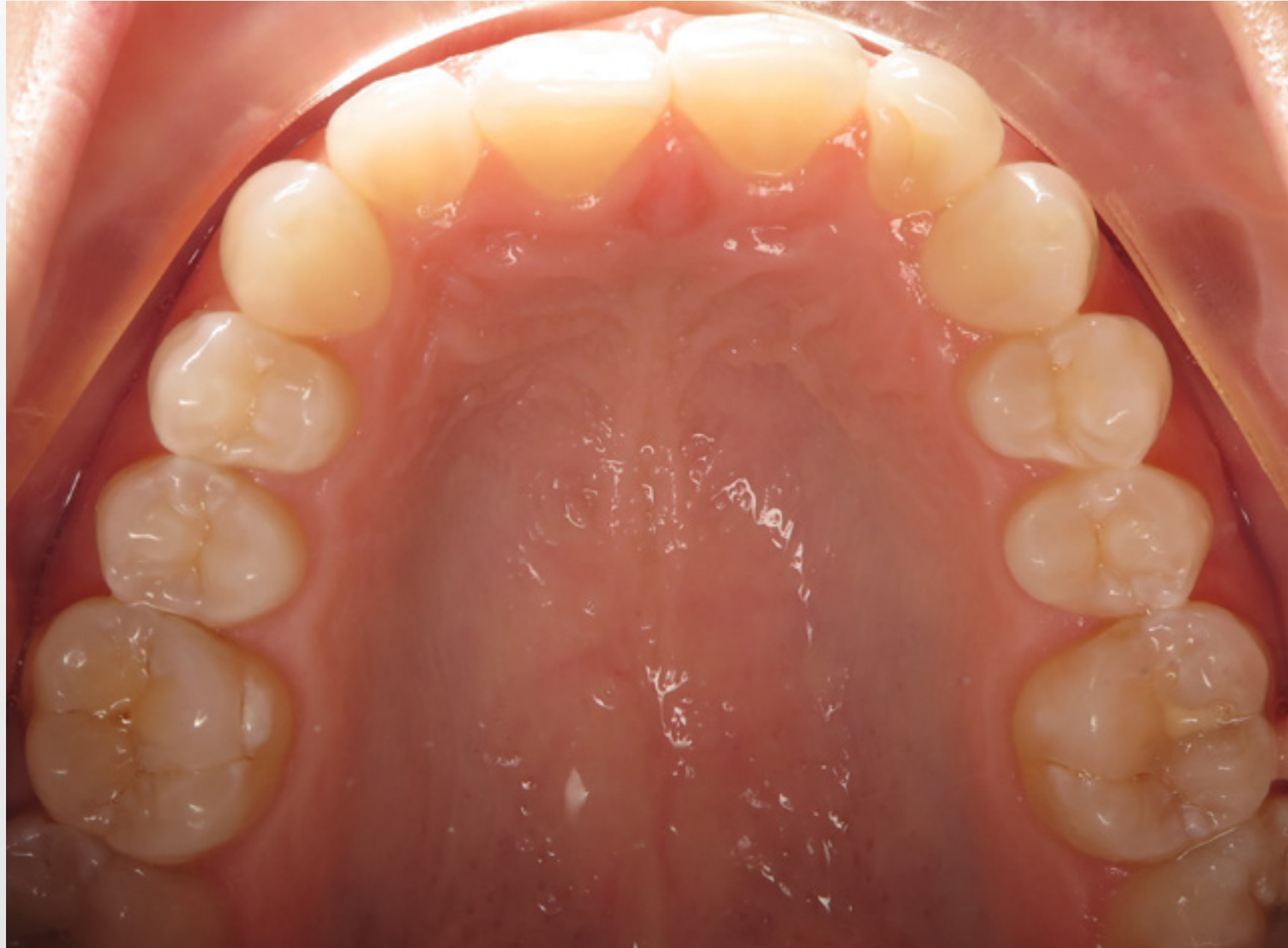




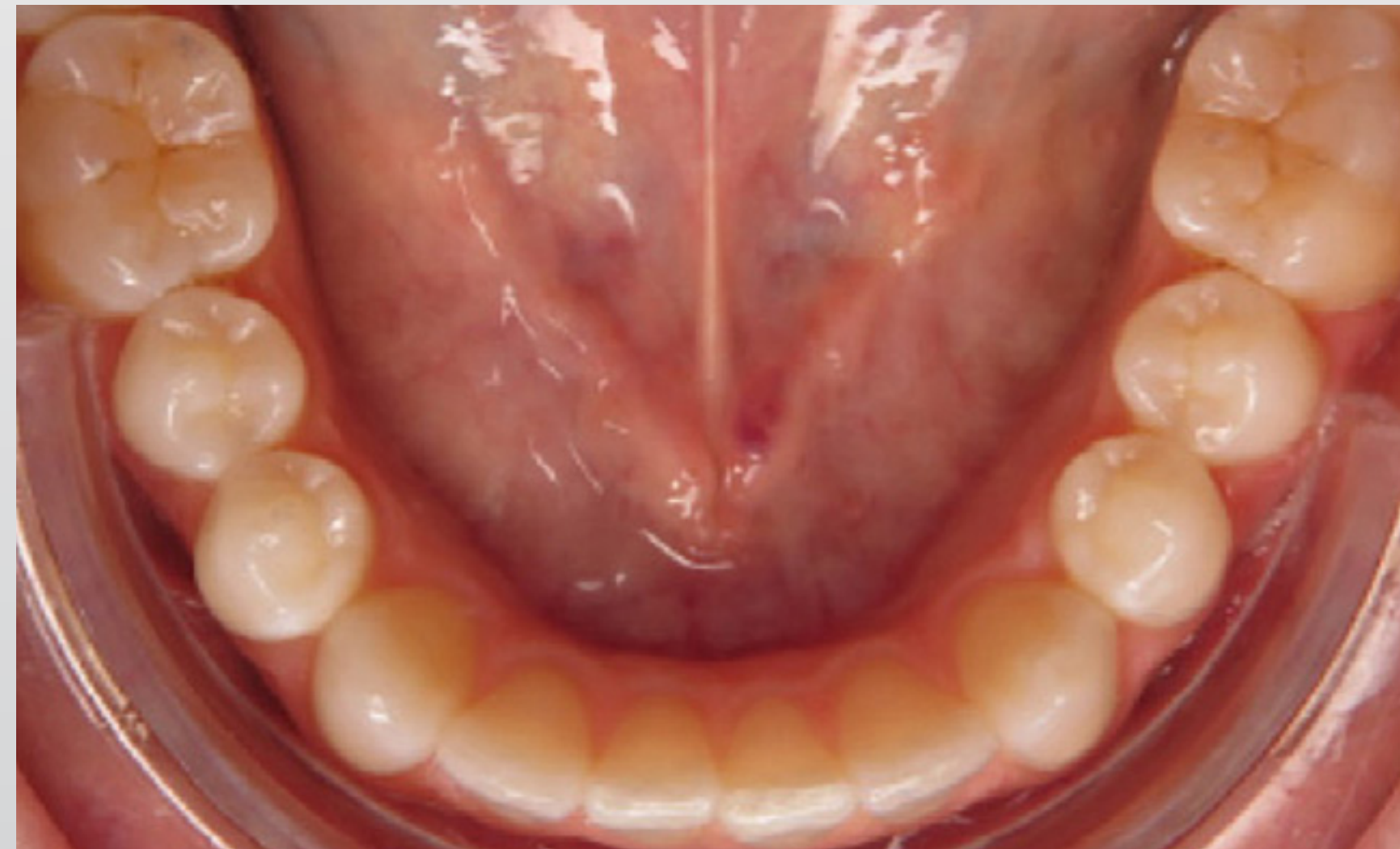
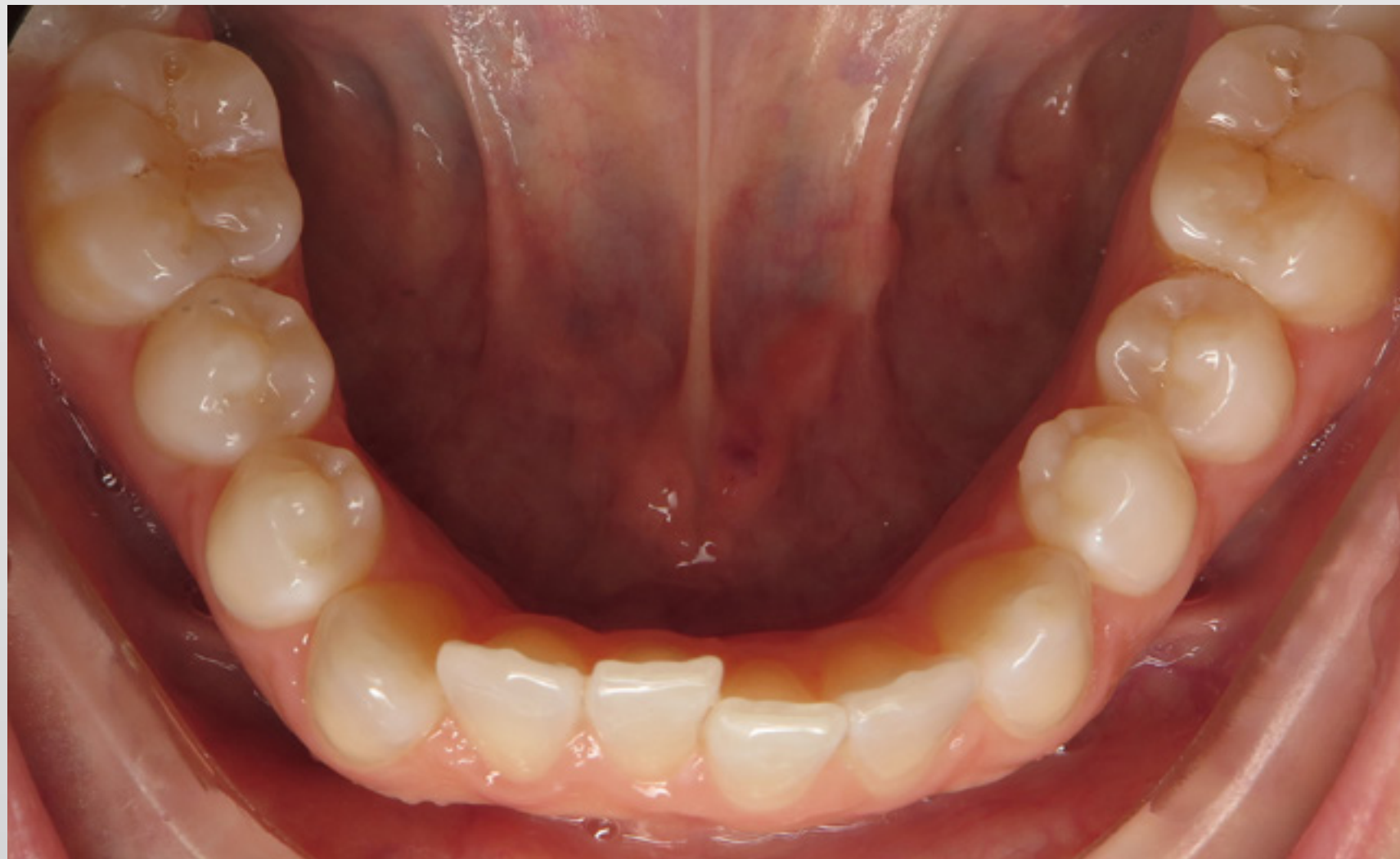**Initial**

**Final**

**Occlusal –  
maxillary**



**Occlusal –  
mandibular**

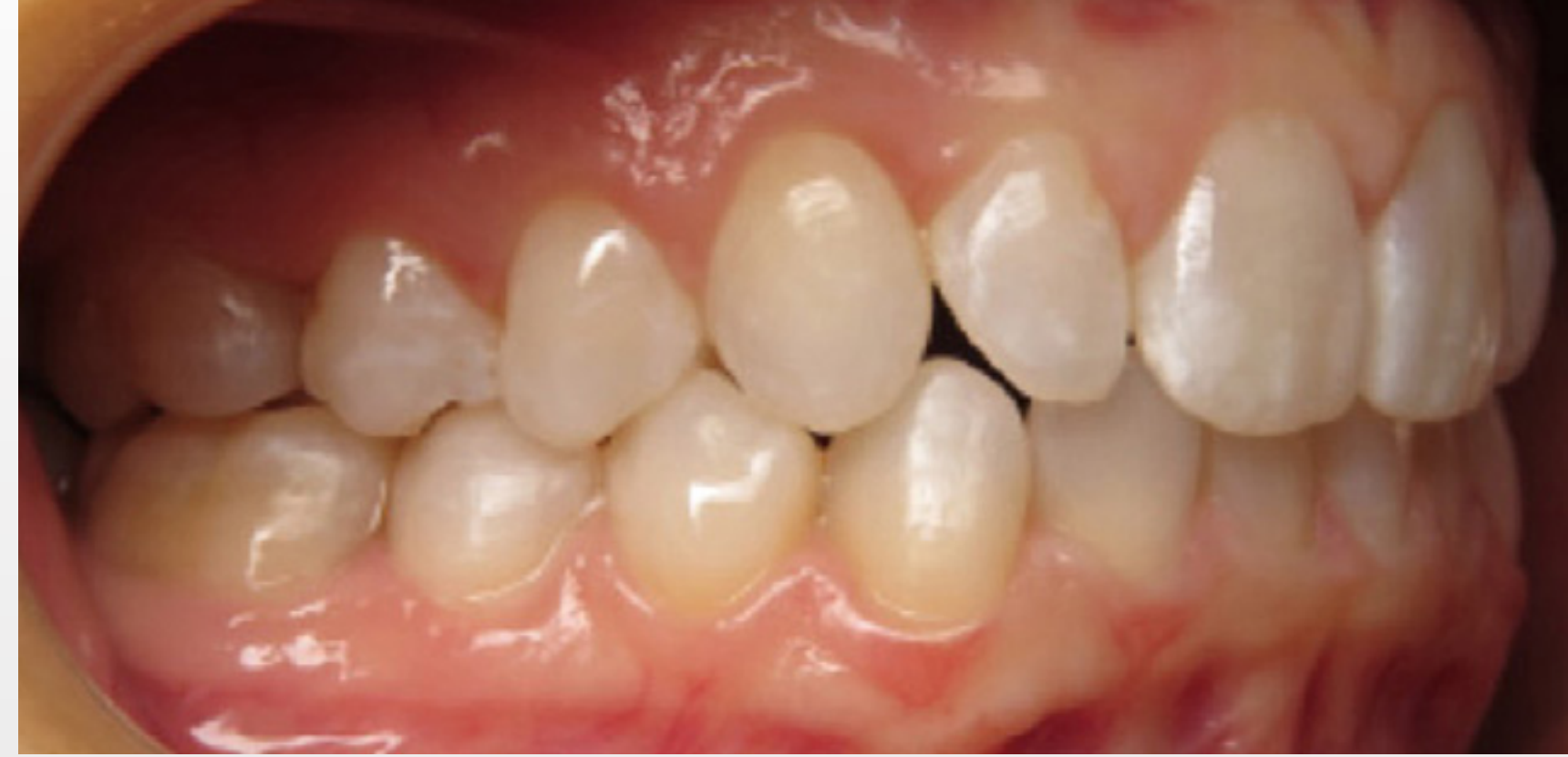
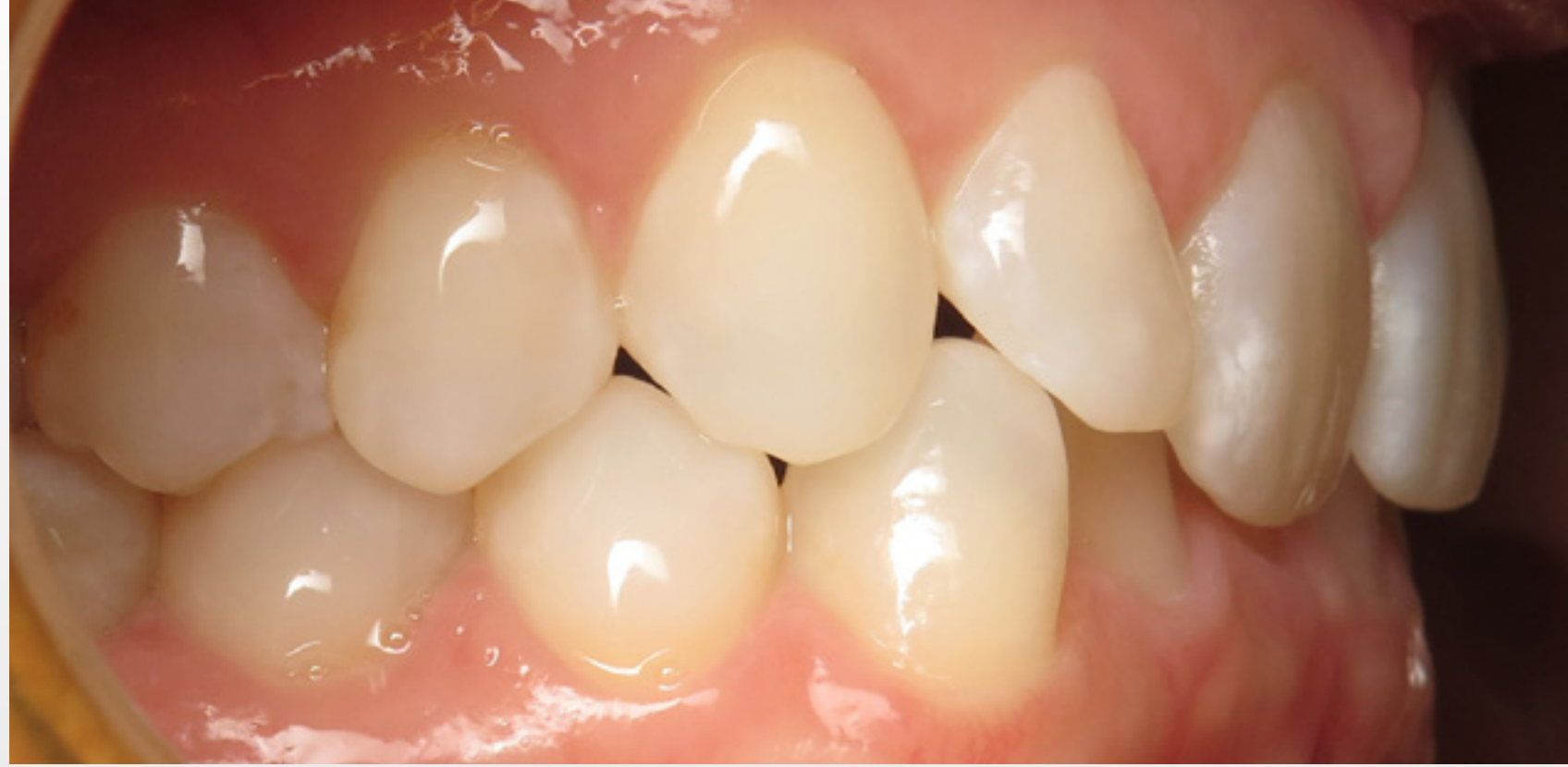


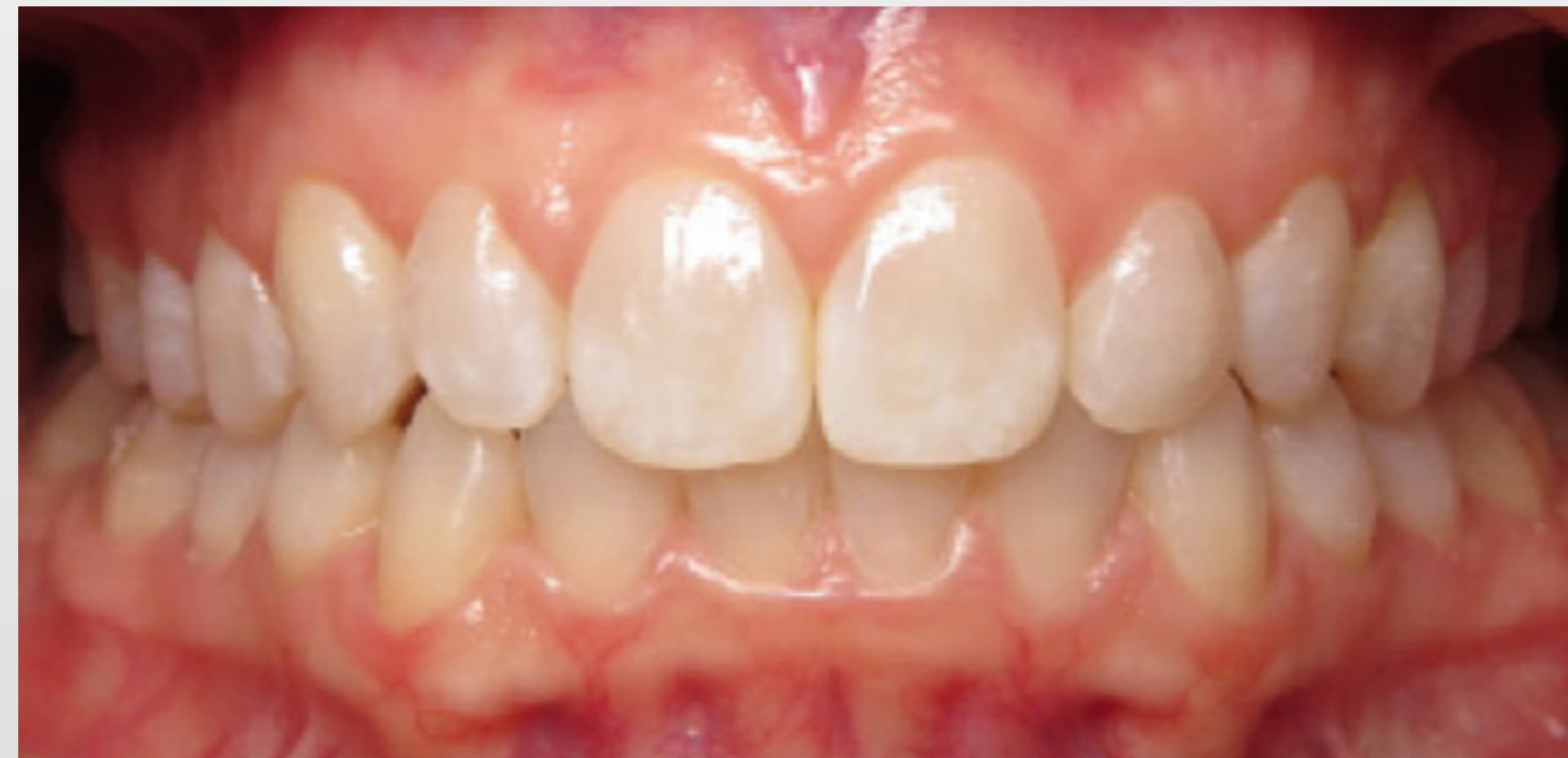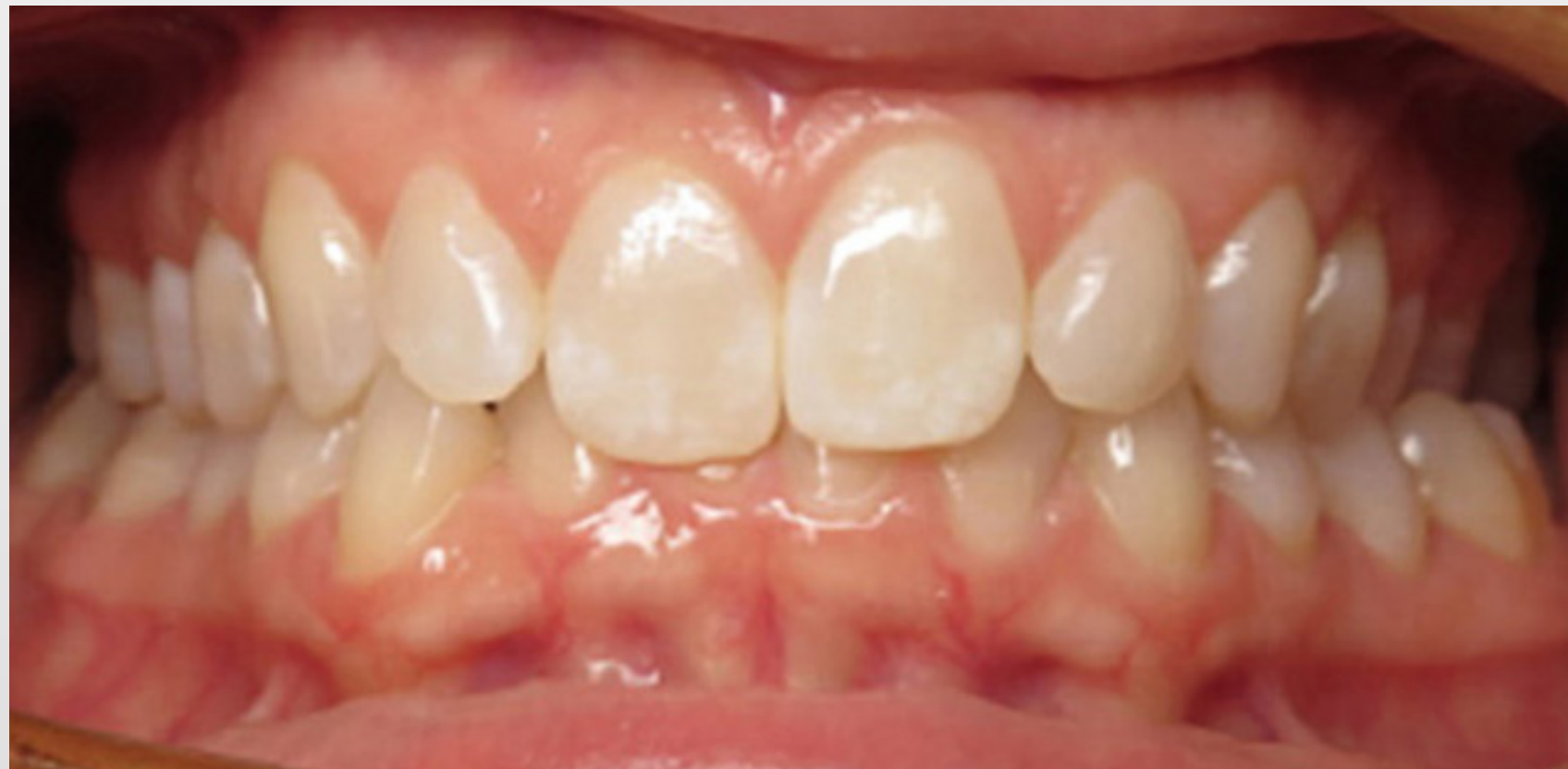**Initial**

**Final**

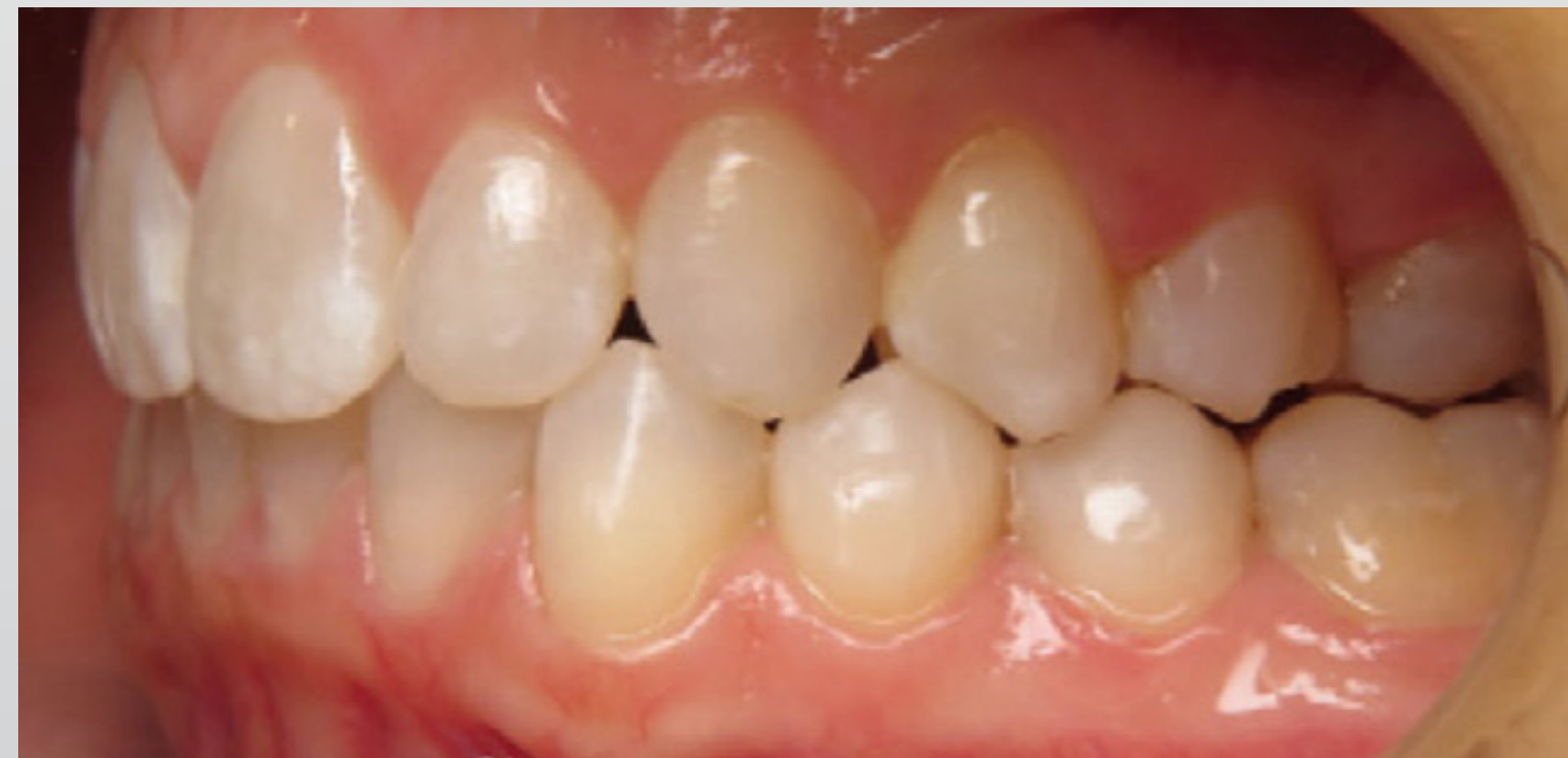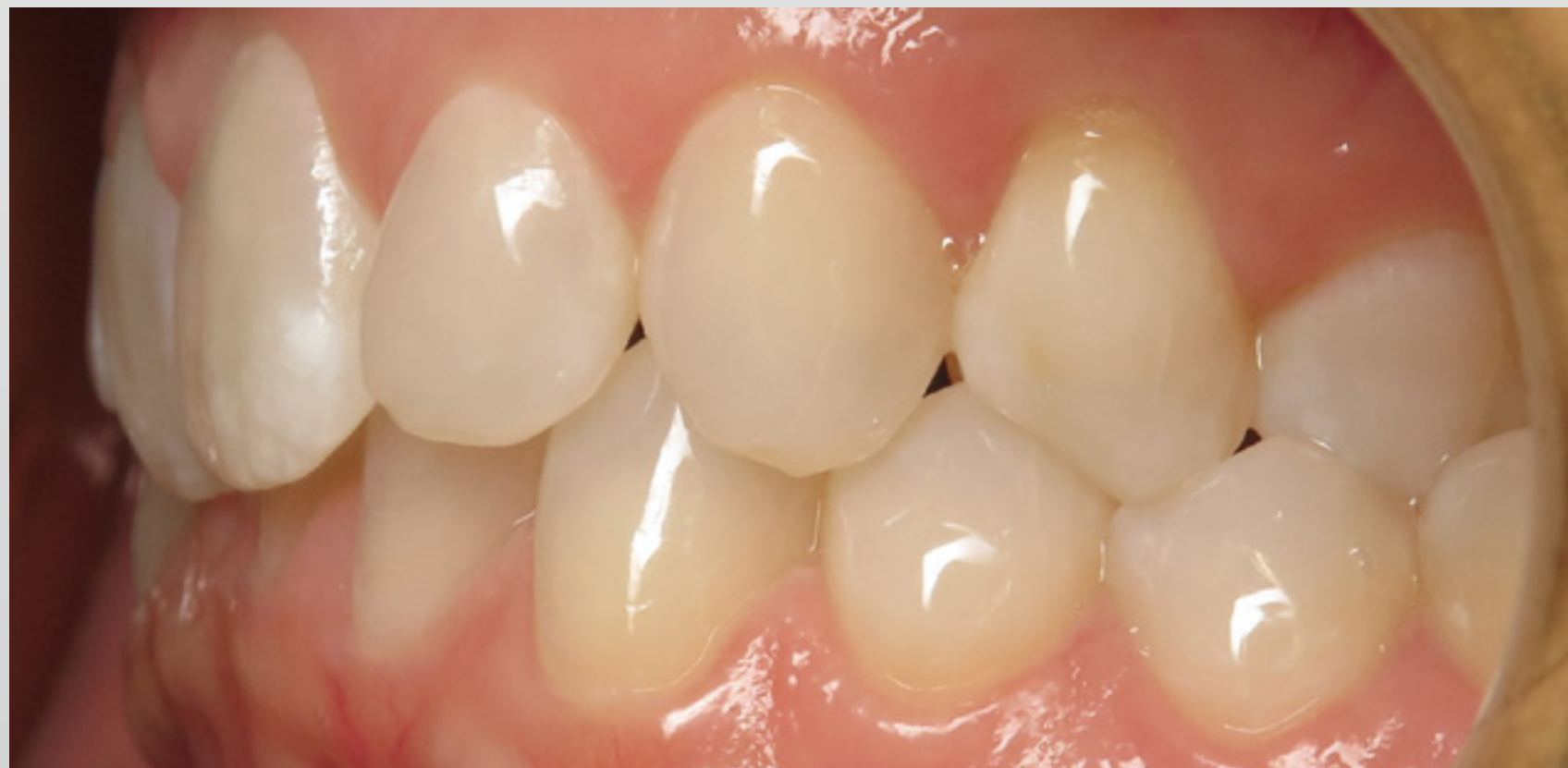**Retracted  
buccal – right**



**Retracted  
anterior biting**



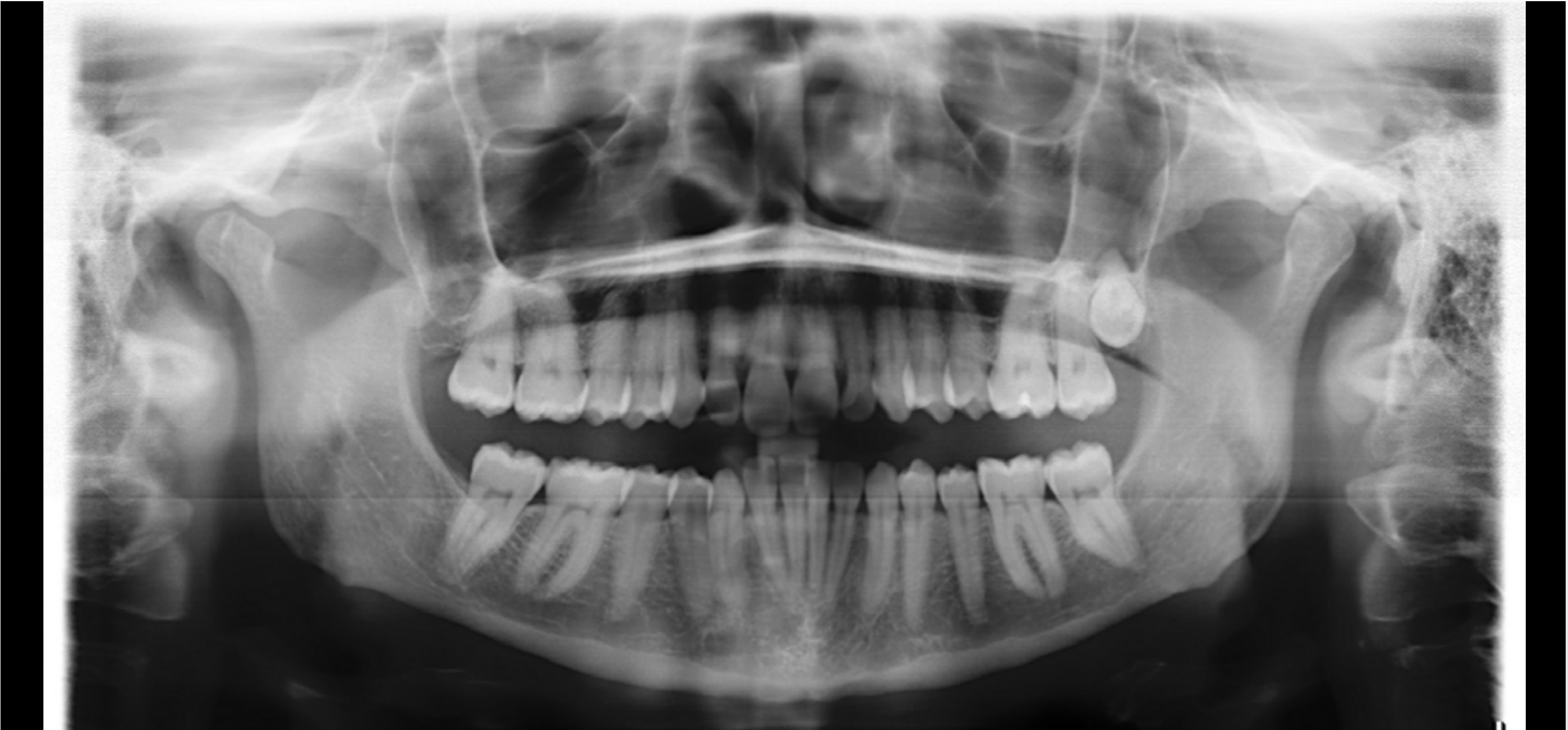**Retracted  
buccal – left**



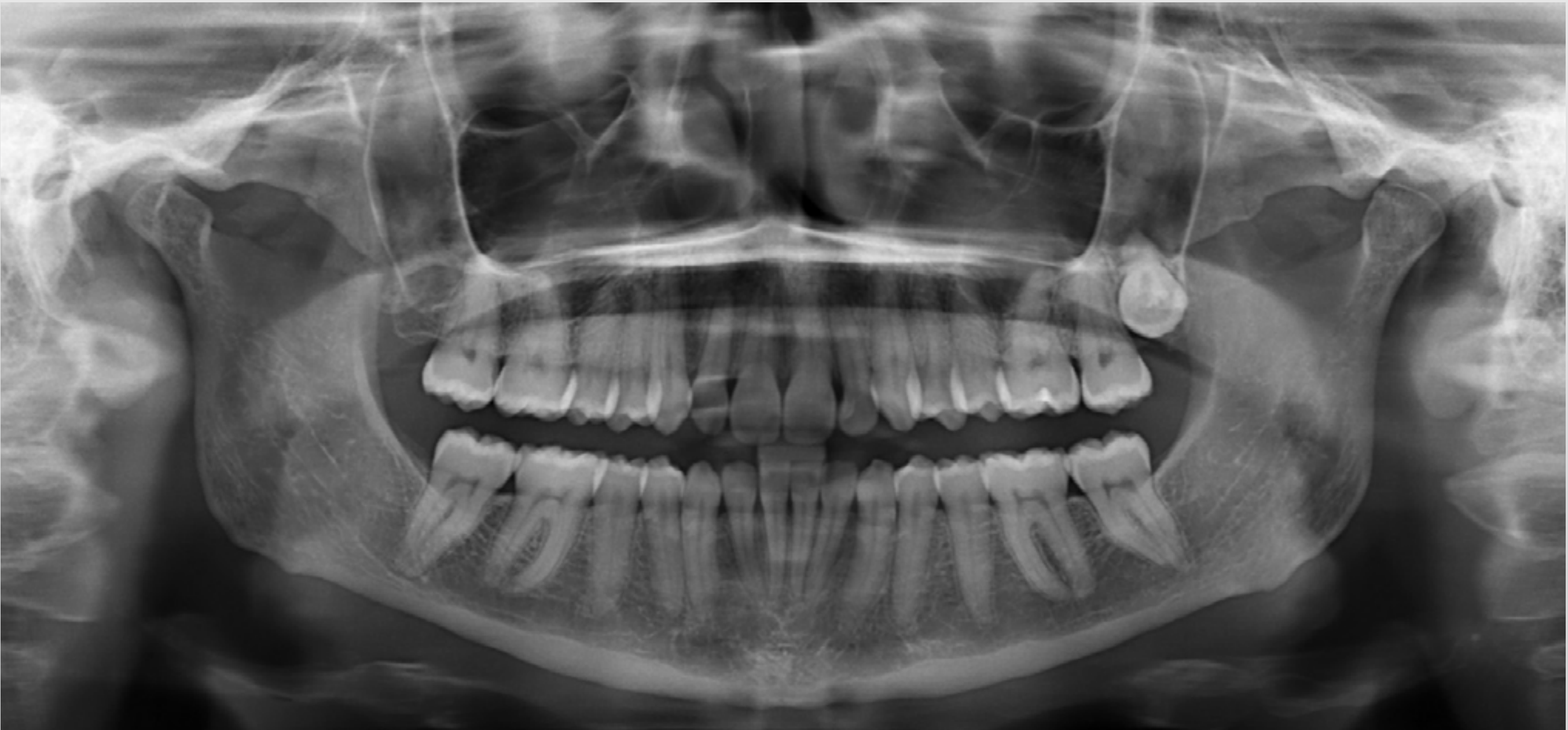

Panoramic radiograph

Initial



Final



Learn more at **3M.com/ClarityCasesAU**  
and **3M.com/ClarityCasesNZ**