

Case Study: 3M™ Clarity™ Aligners

Interdisciplinary Treatment with Congenitally Missing Teeth

Age: 16

Chief concern: Missing teeth and small lateral incisor

Case diagnostics: Class III skeletal, Class I malocclusion with moderate maxillary spacing and moderate mandibular crowding

Total number of aligners: 80 aligners

Wear interval: Weekly

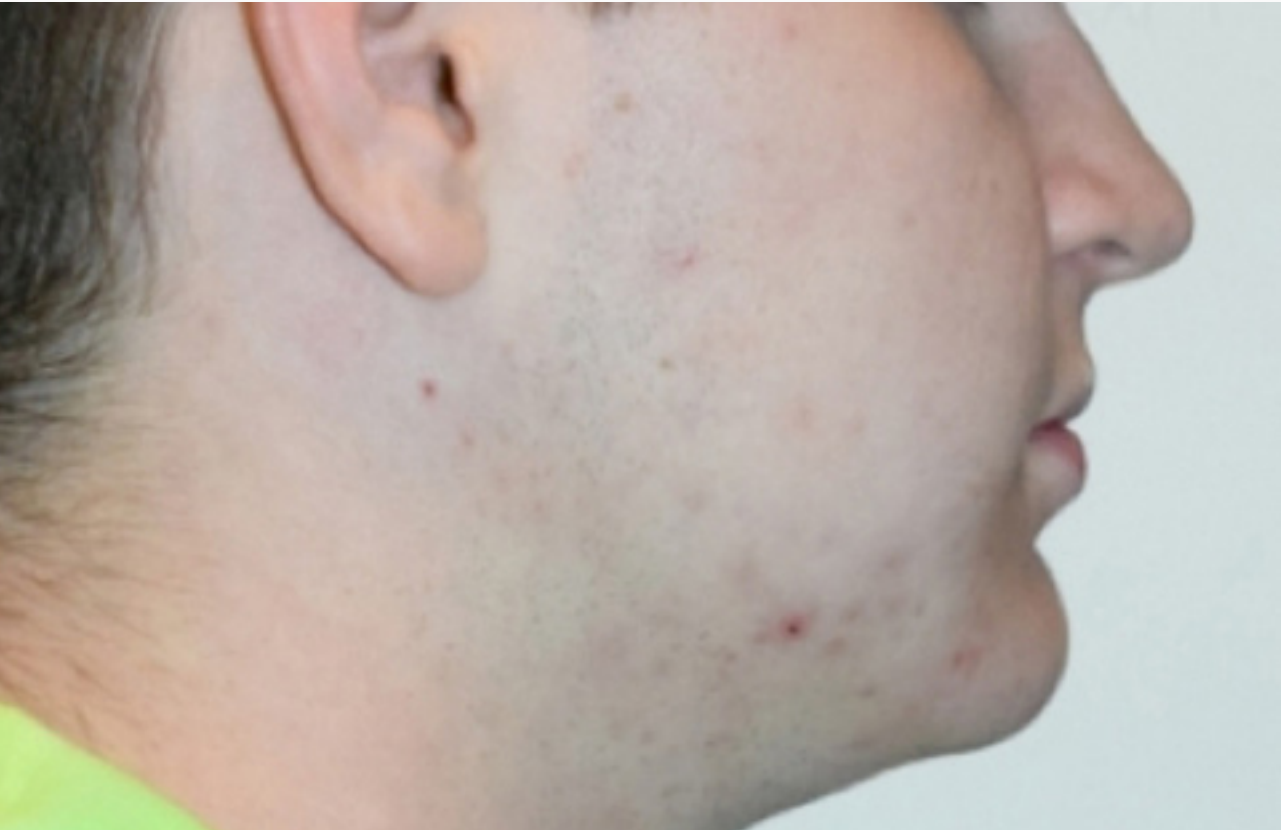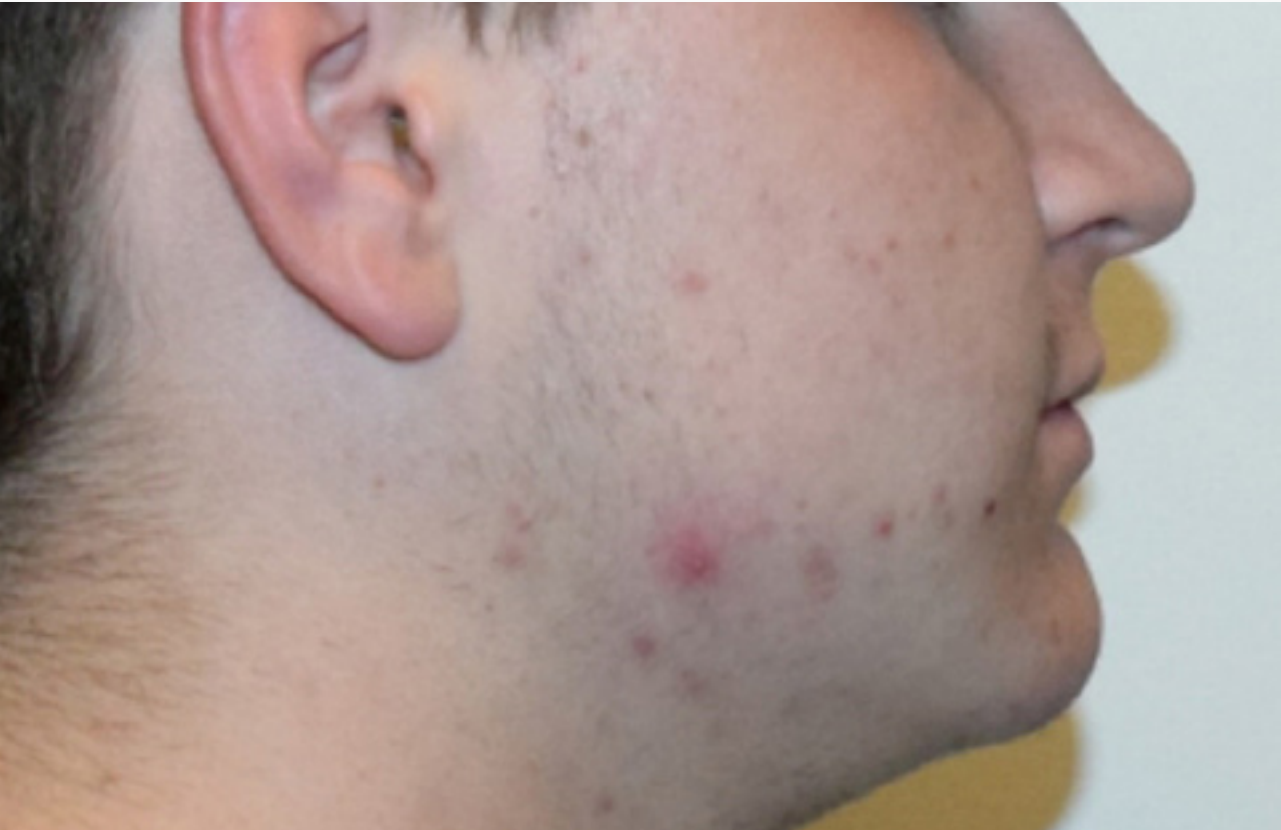Treatment time: 22 months

Case courtesy of:
Dr. Lisa Davison
Powell, OH – USA

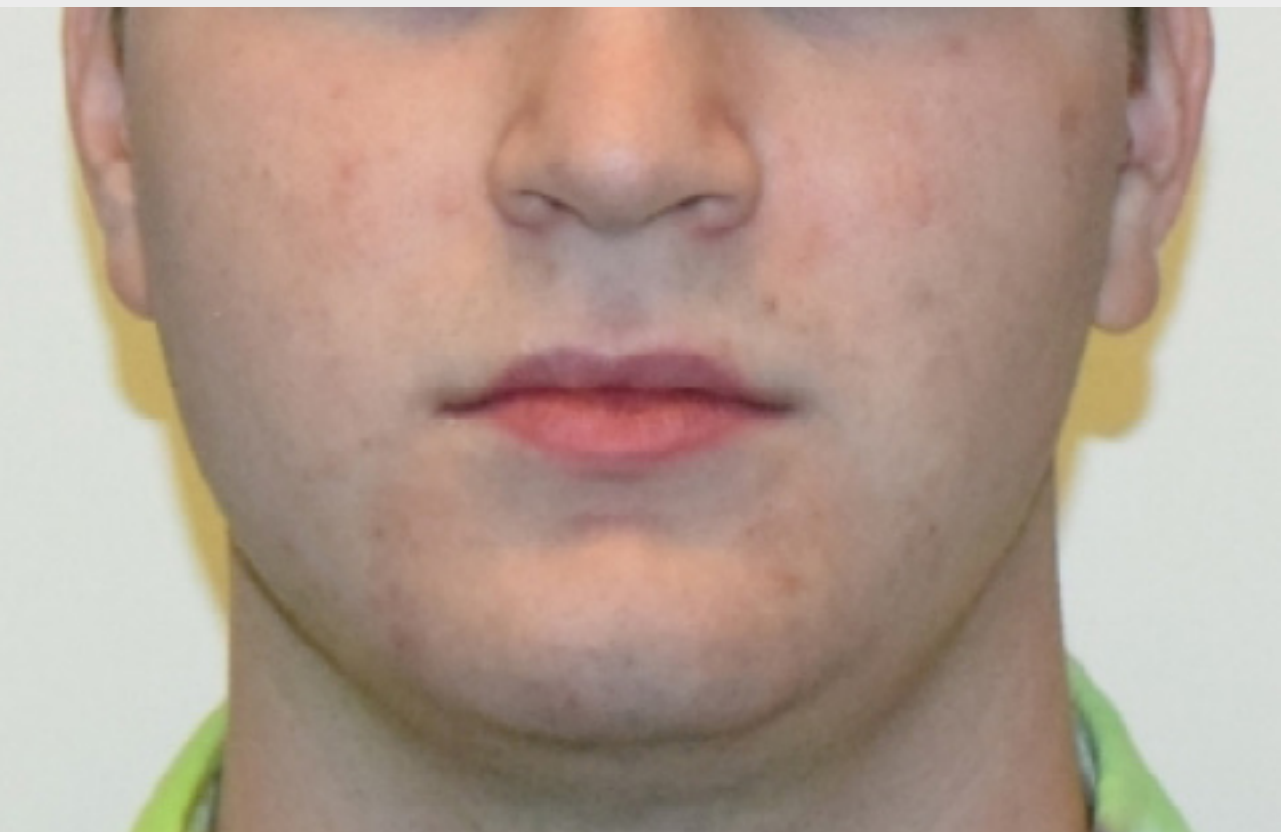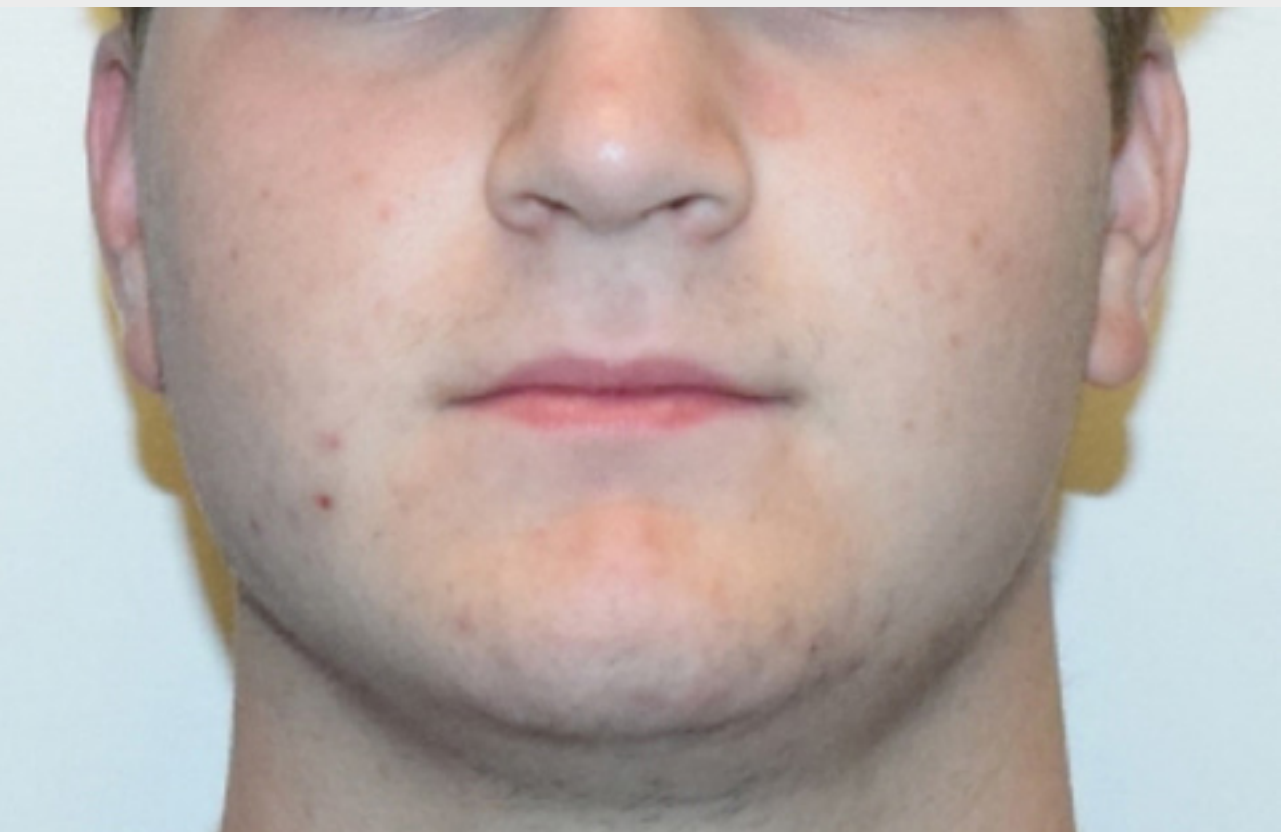Initial

Final

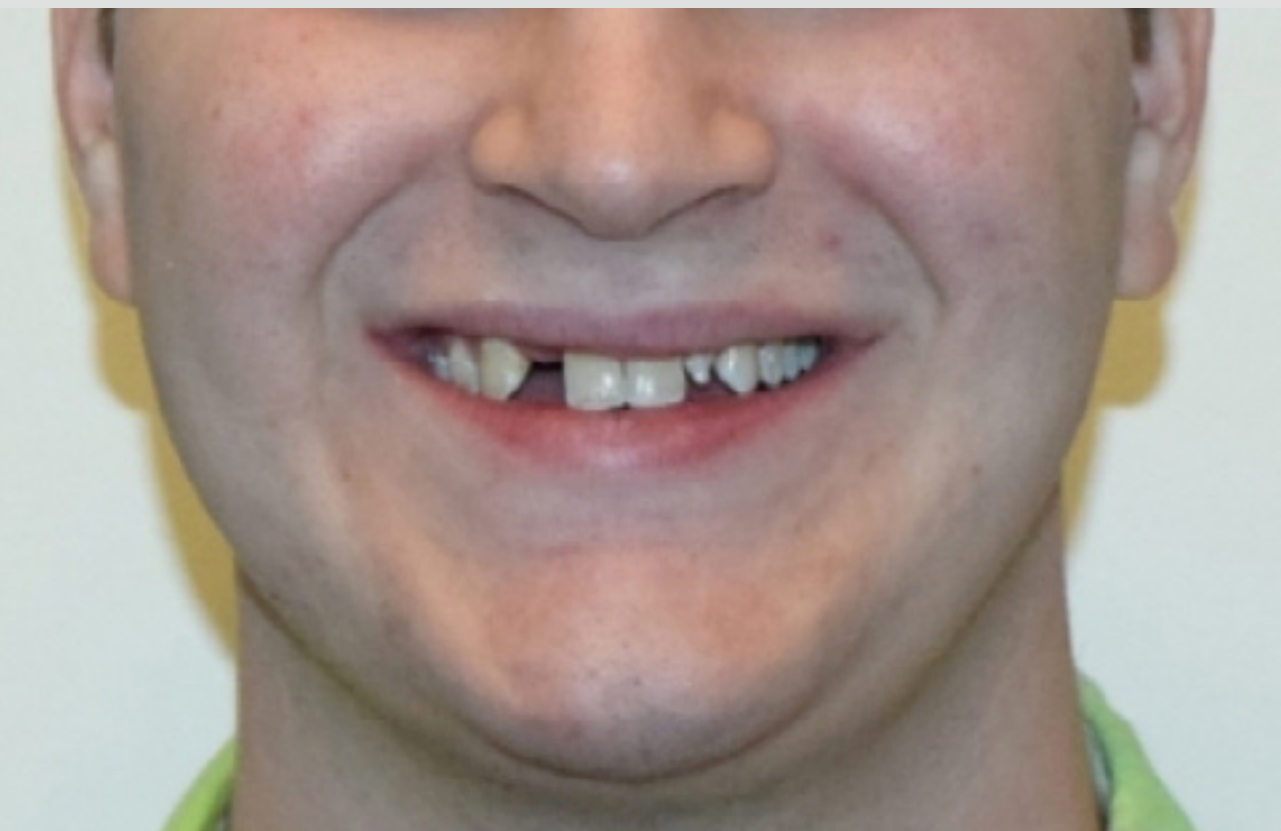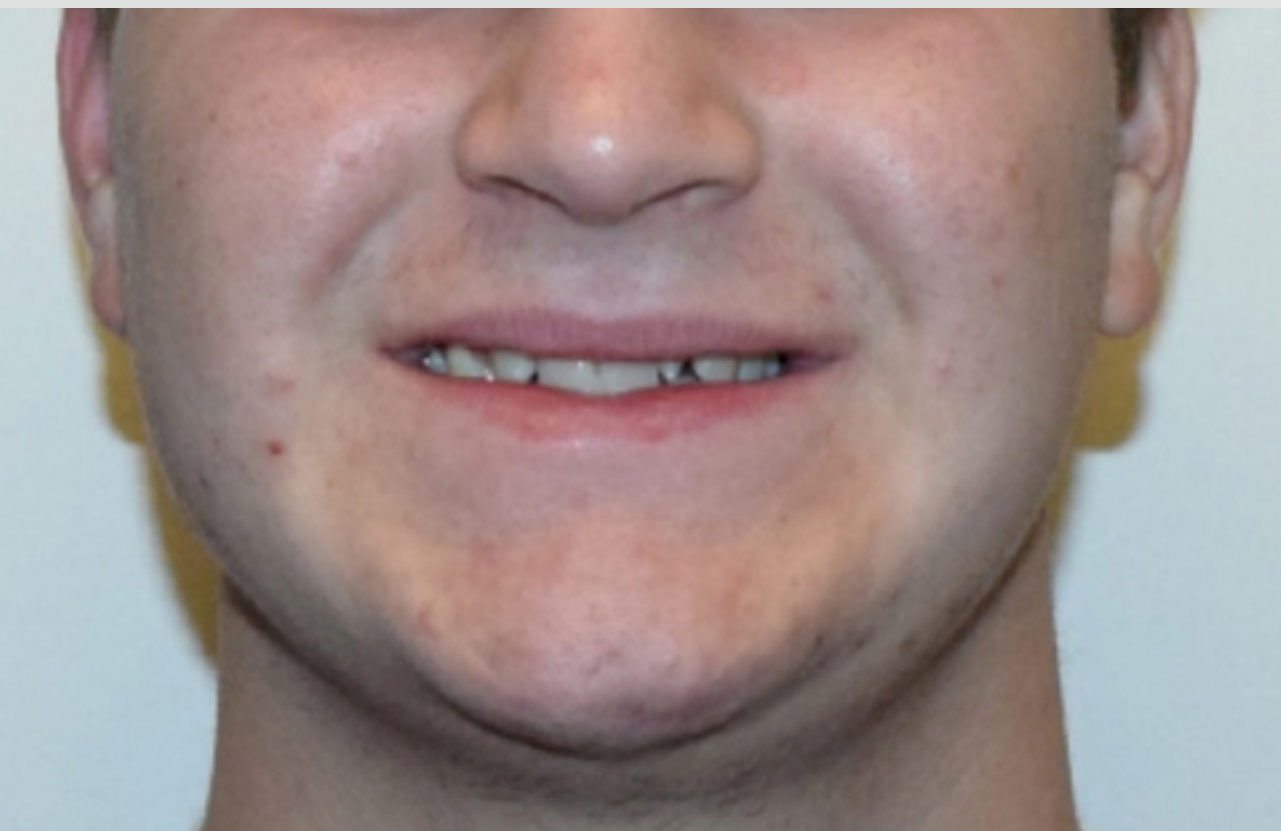Profile at rest



Face at rest



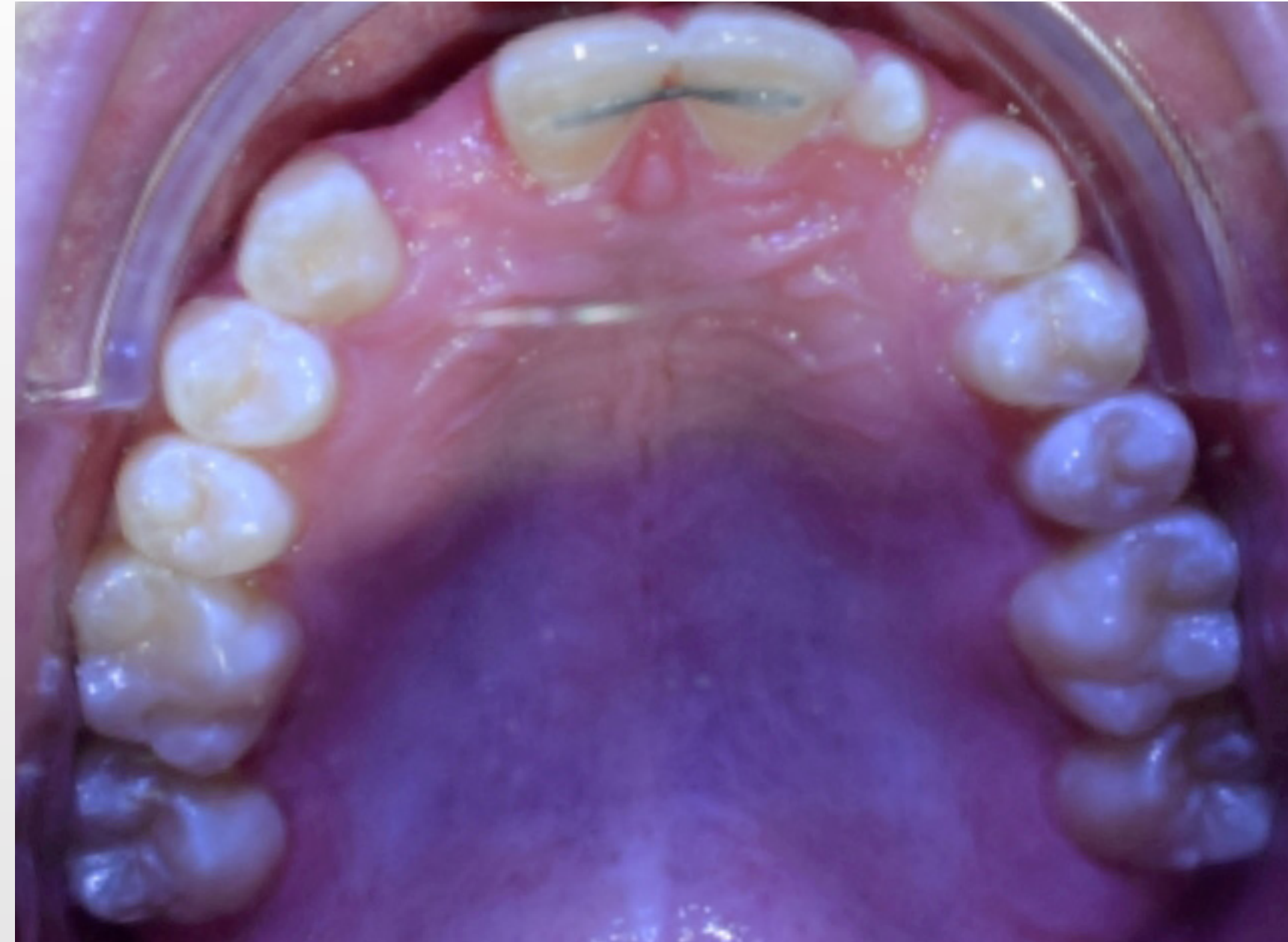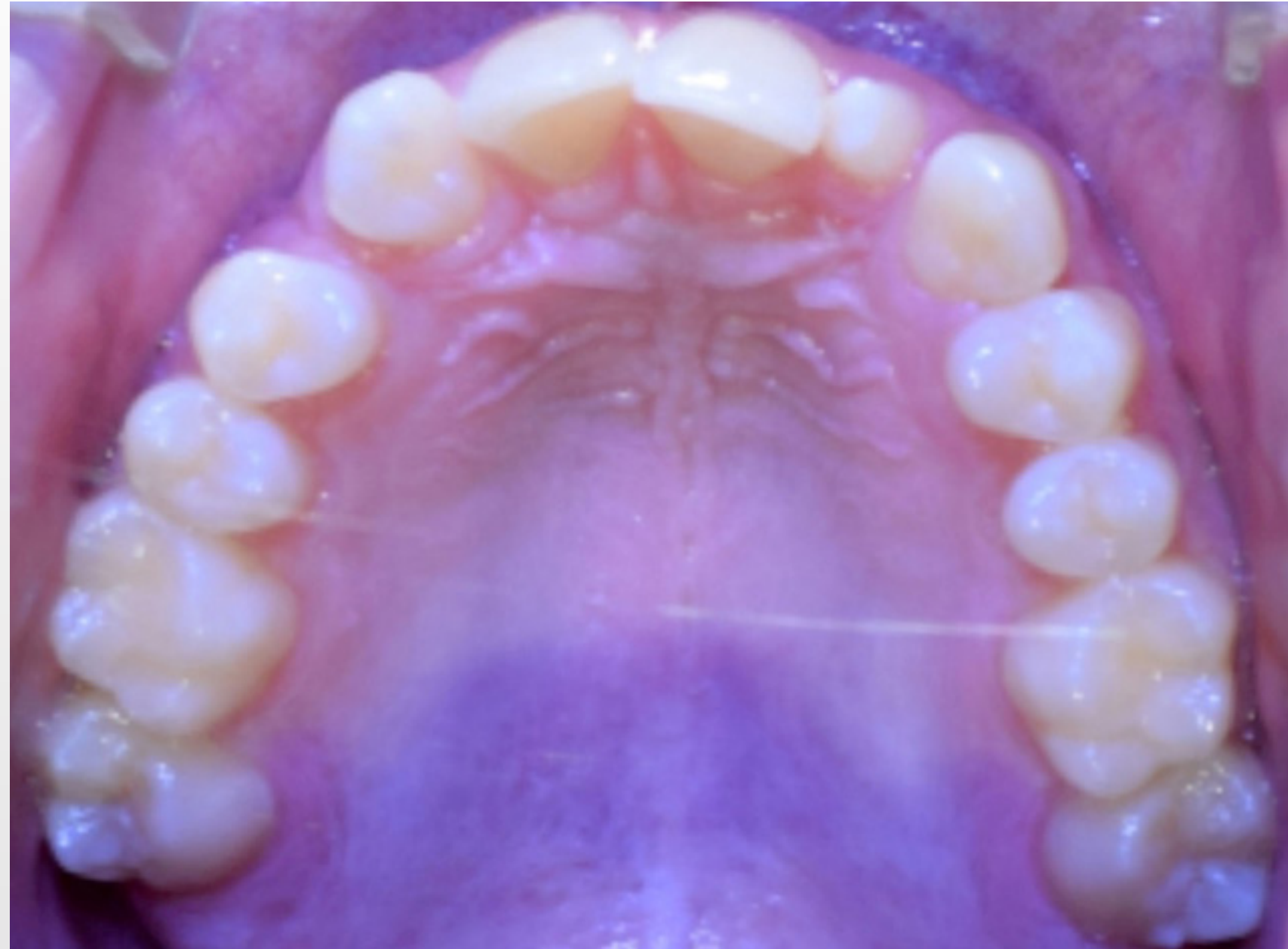Face smiling



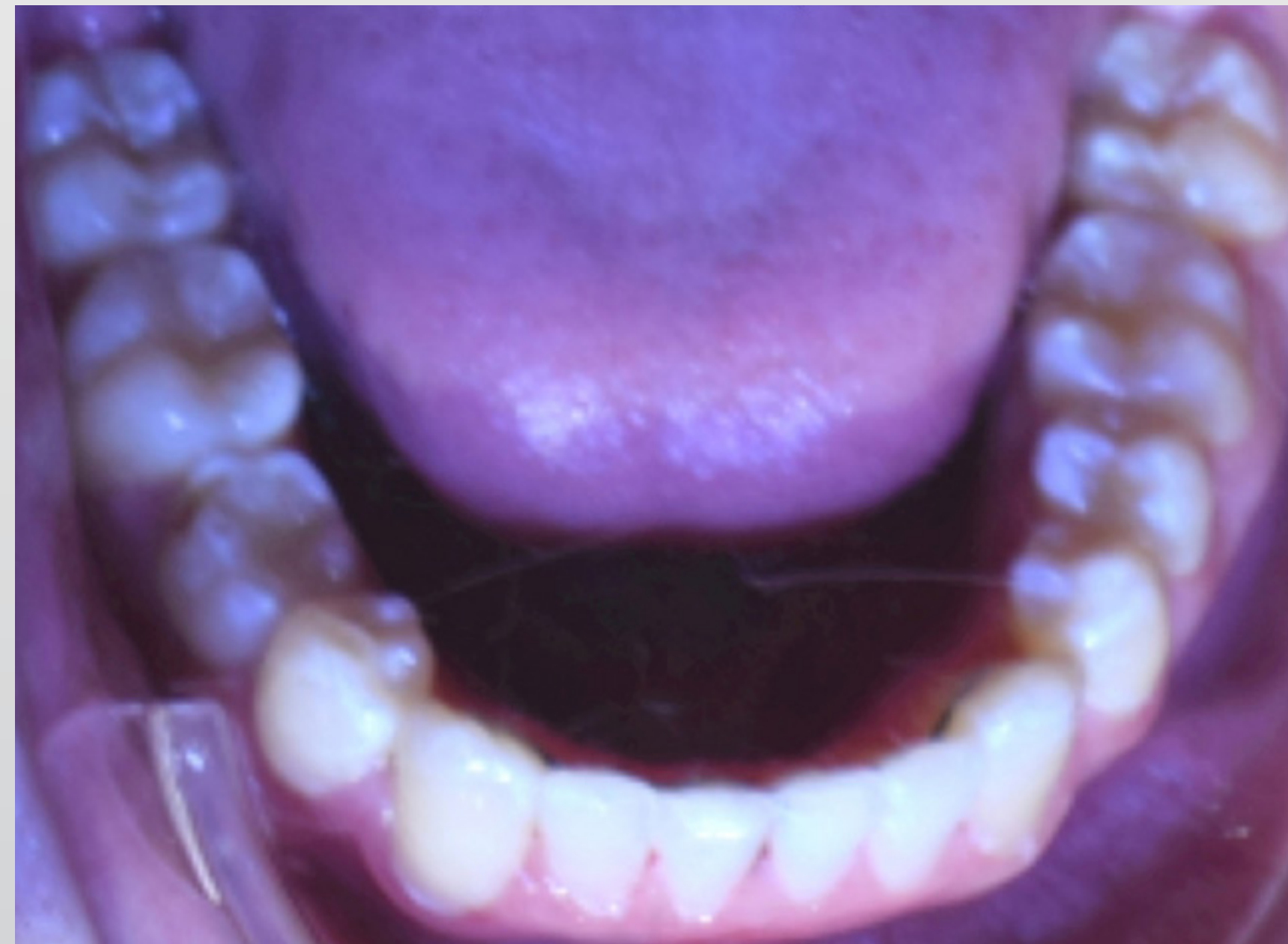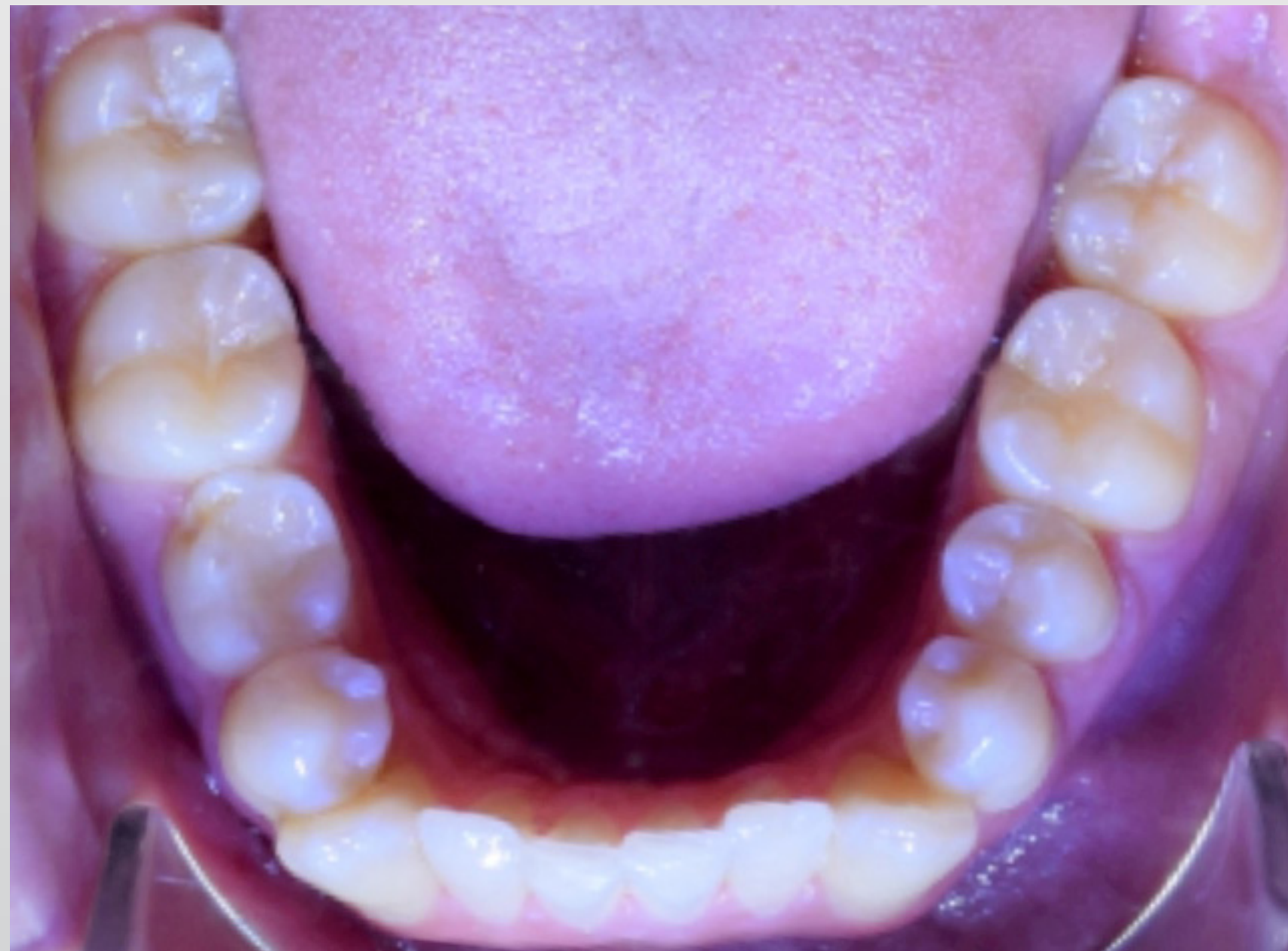Initial

Final

**Occlusal –
maxillary**



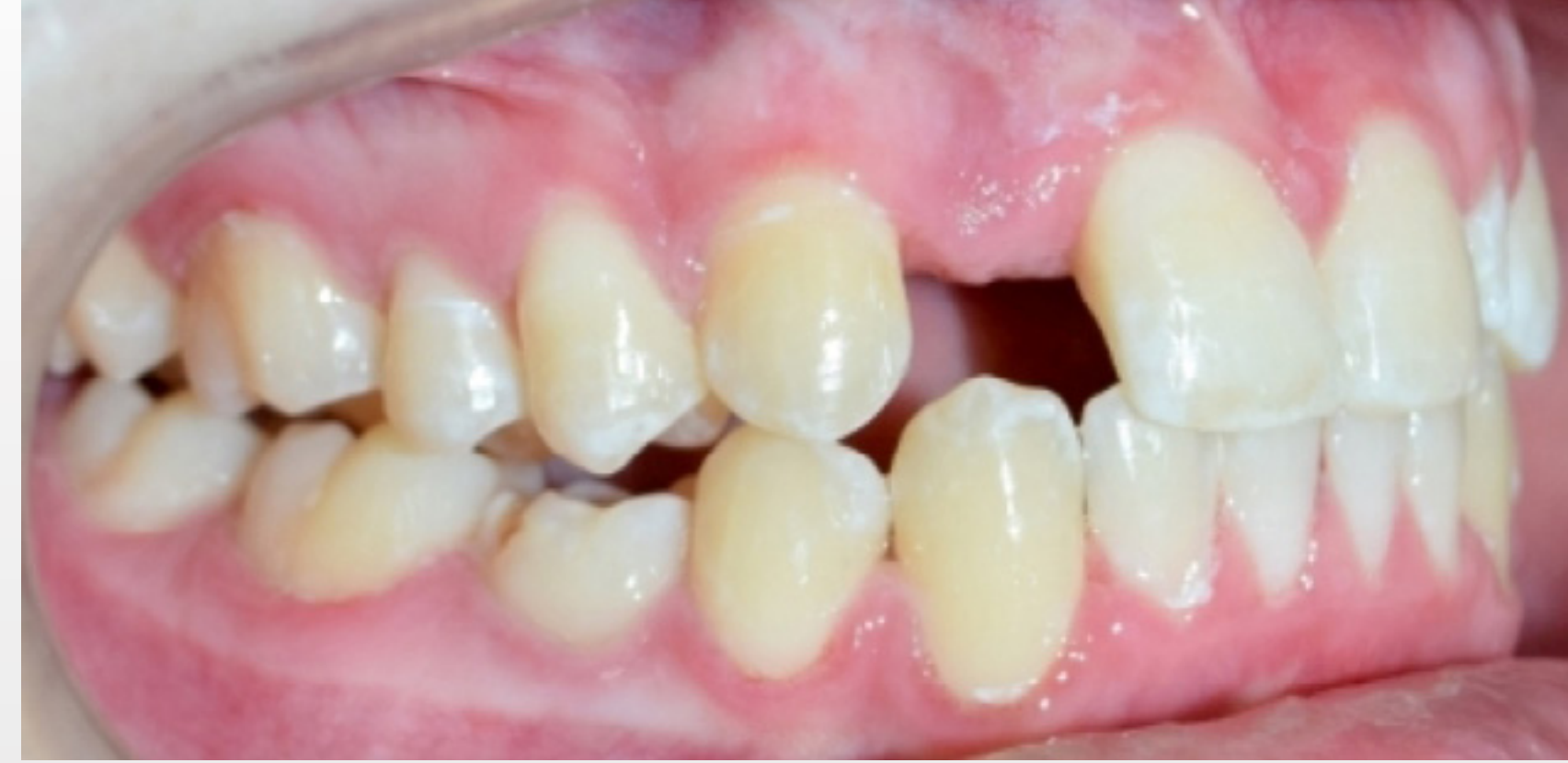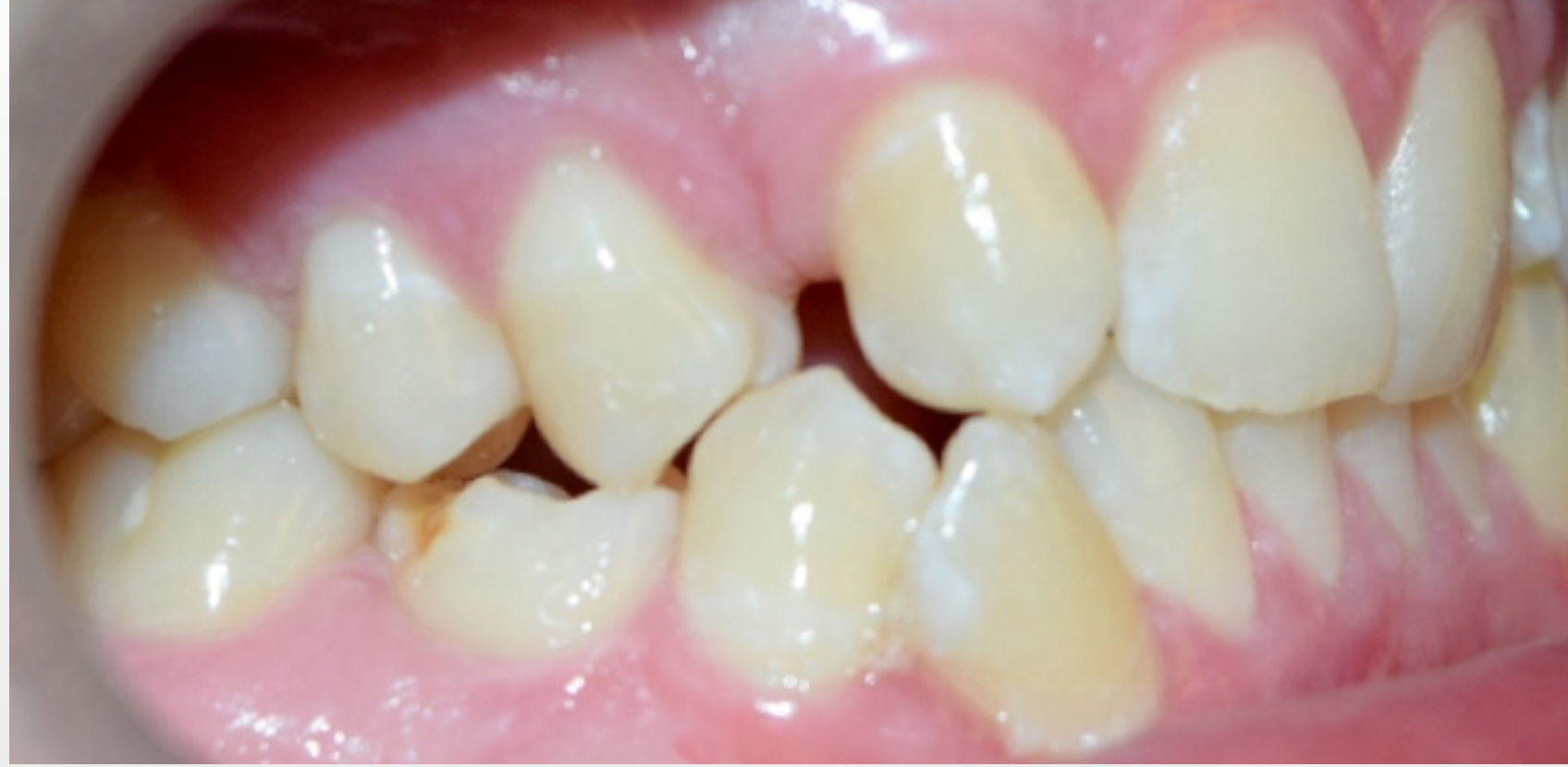**Occlusal –
mandibular**



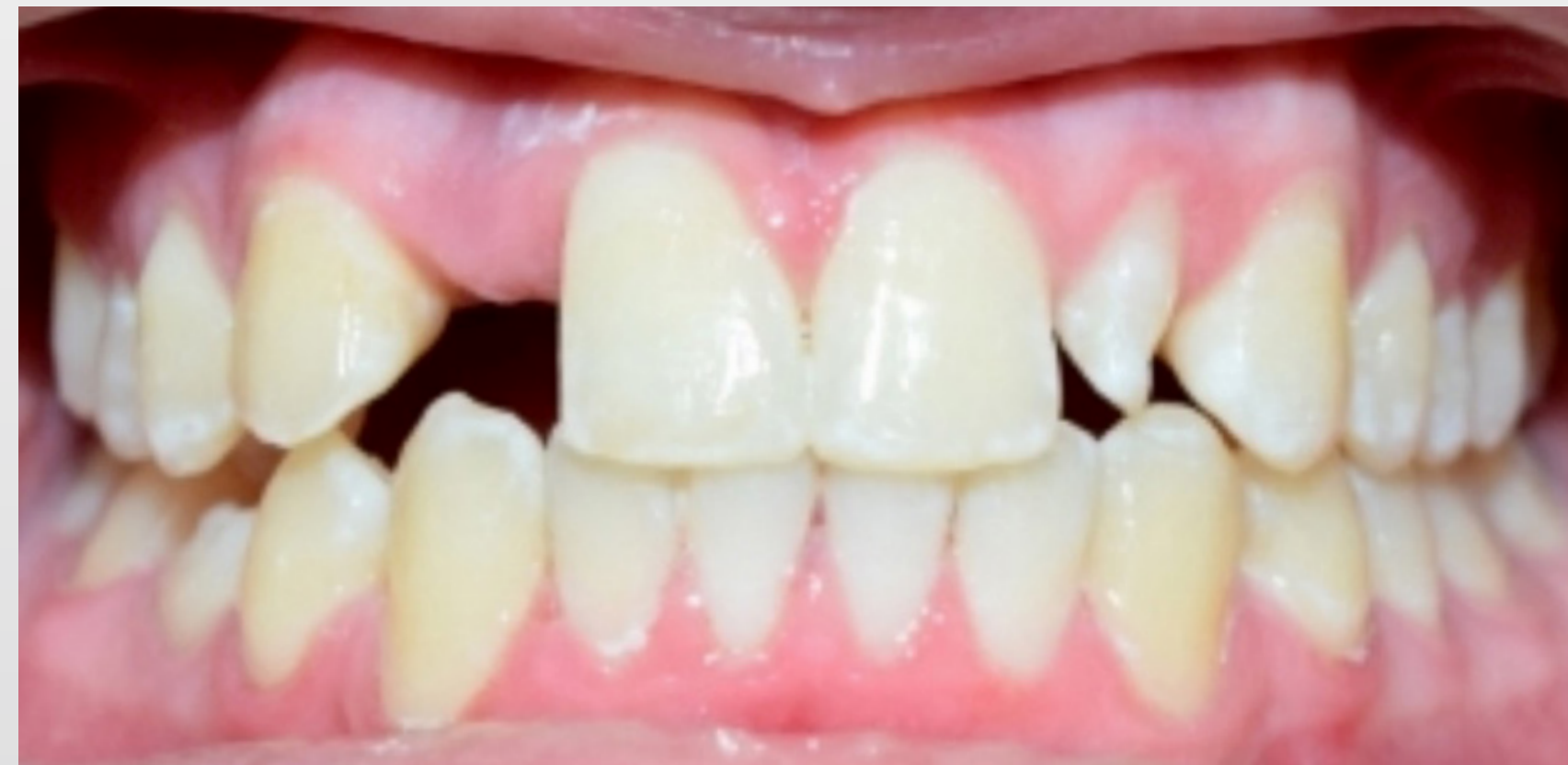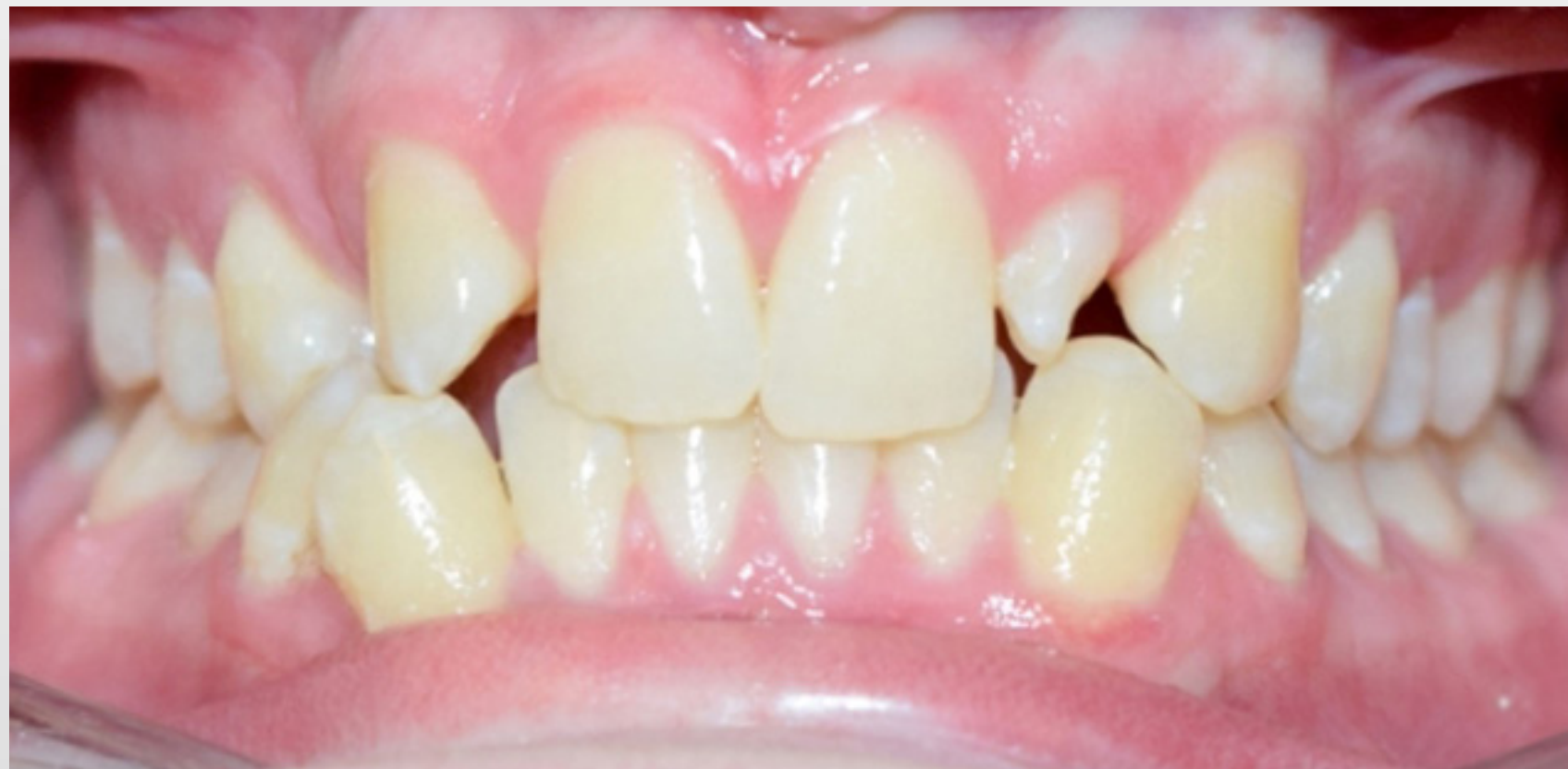Initial

Final

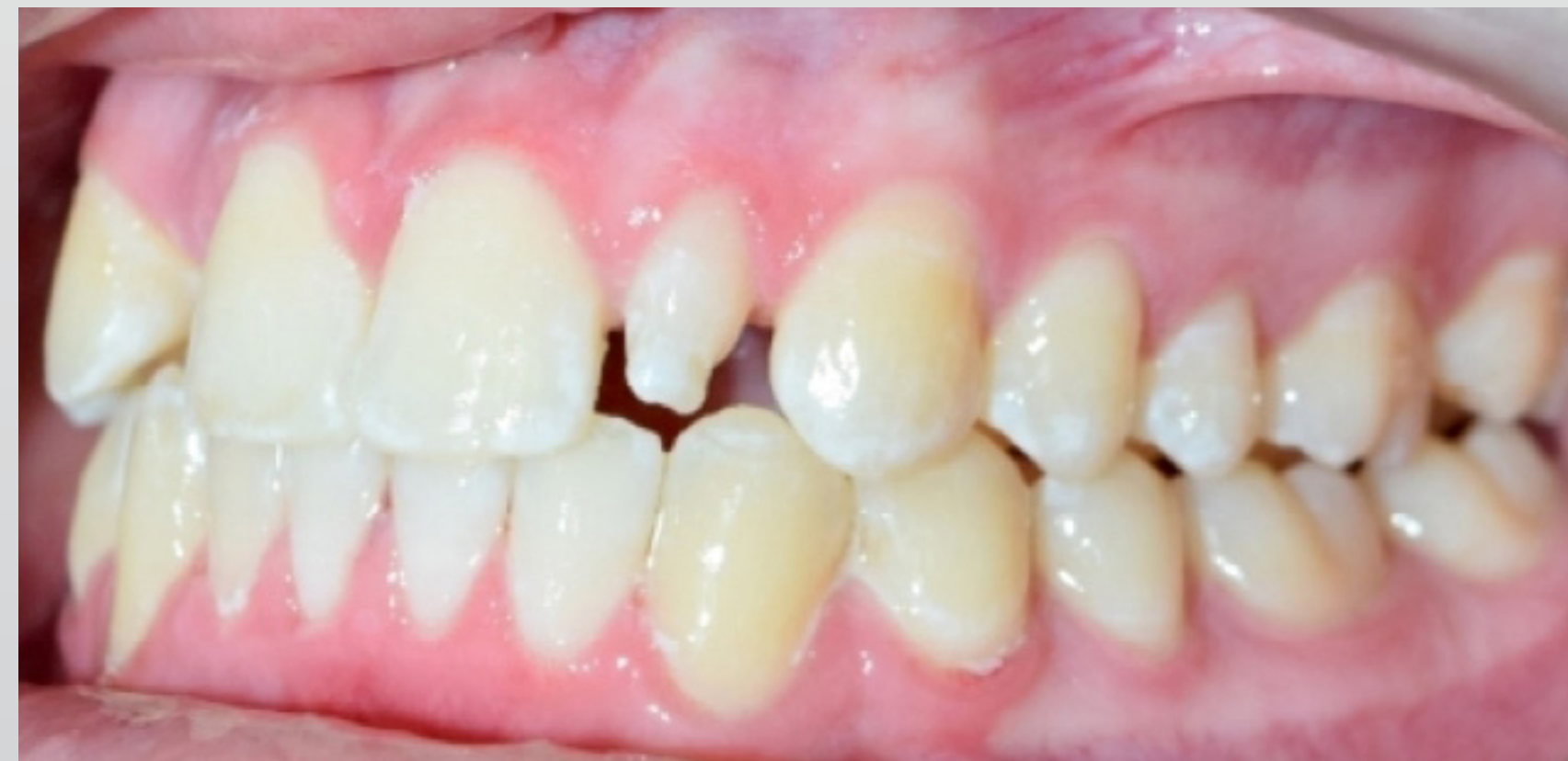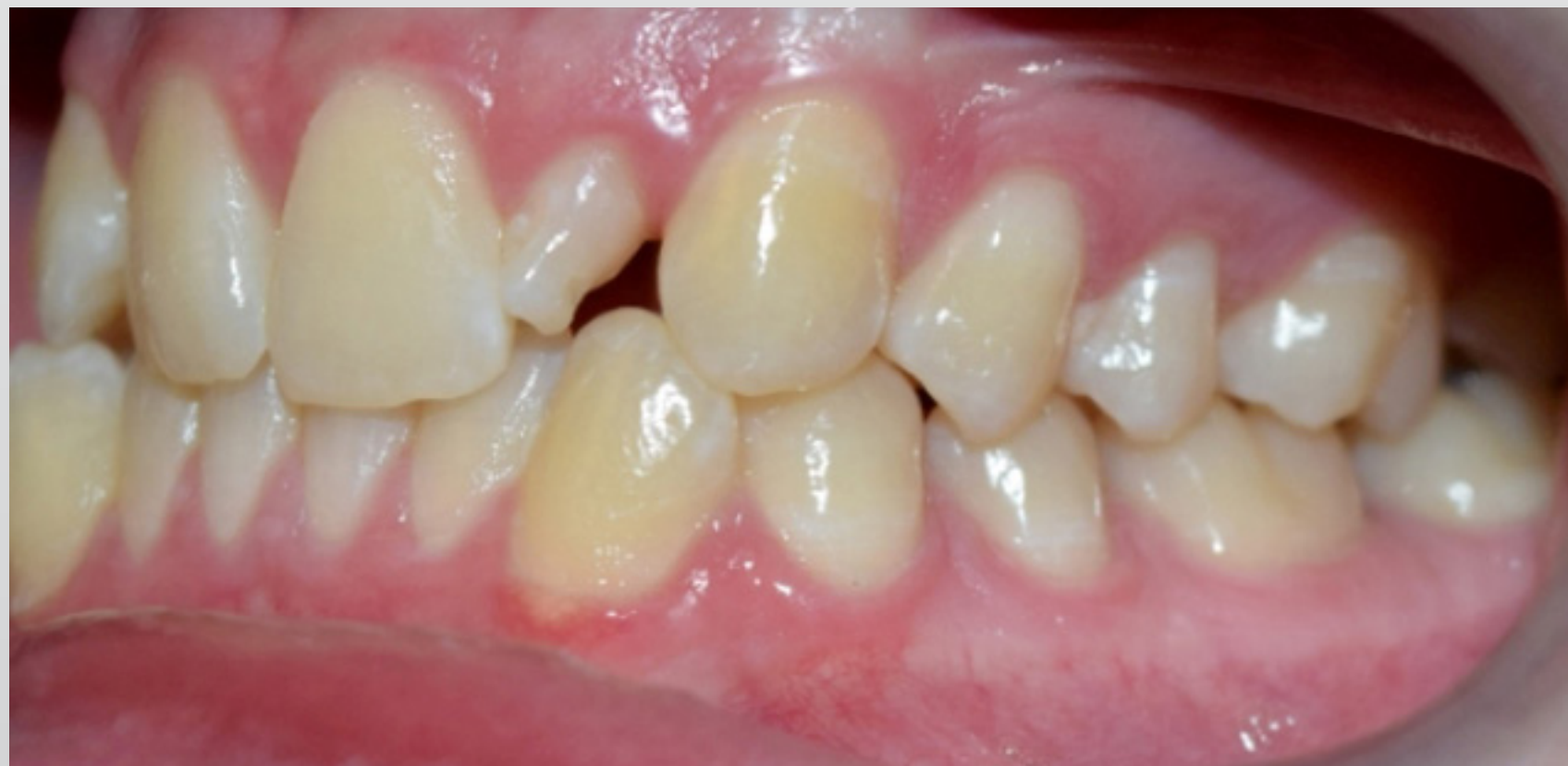**Retracted
buccal – right**



**Retracted
anterior biting**

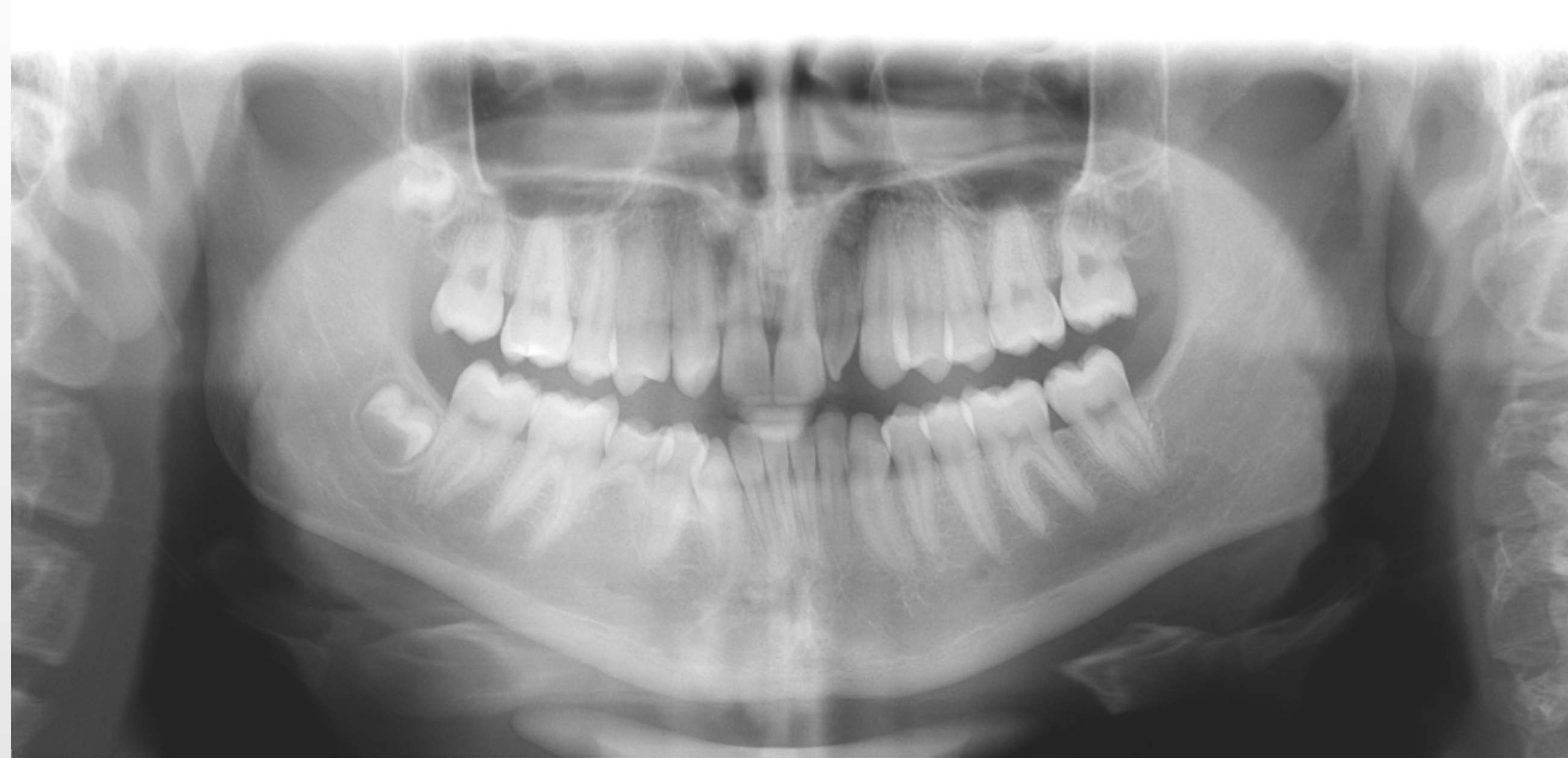

**Retracted
buccal – left**

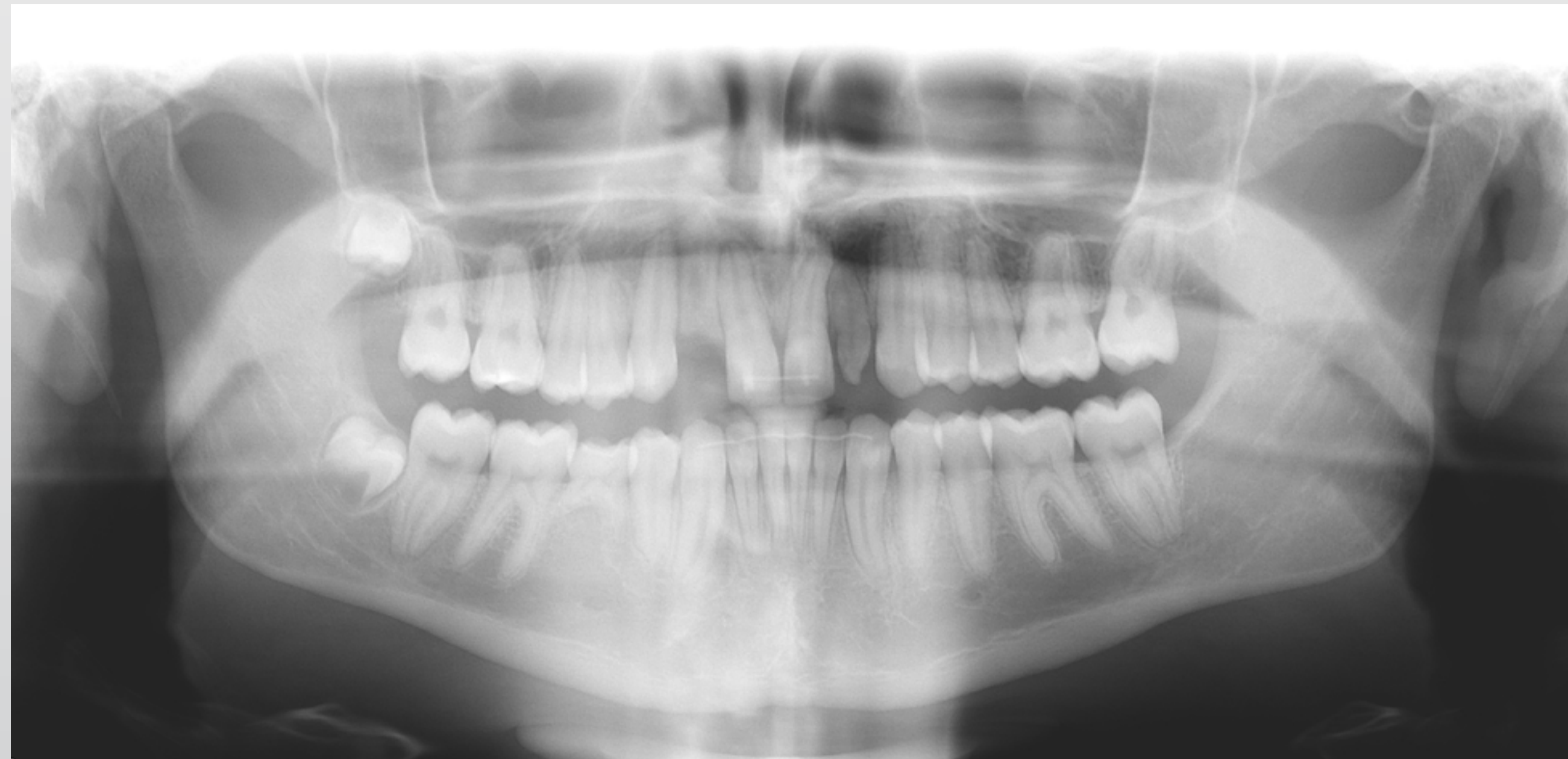

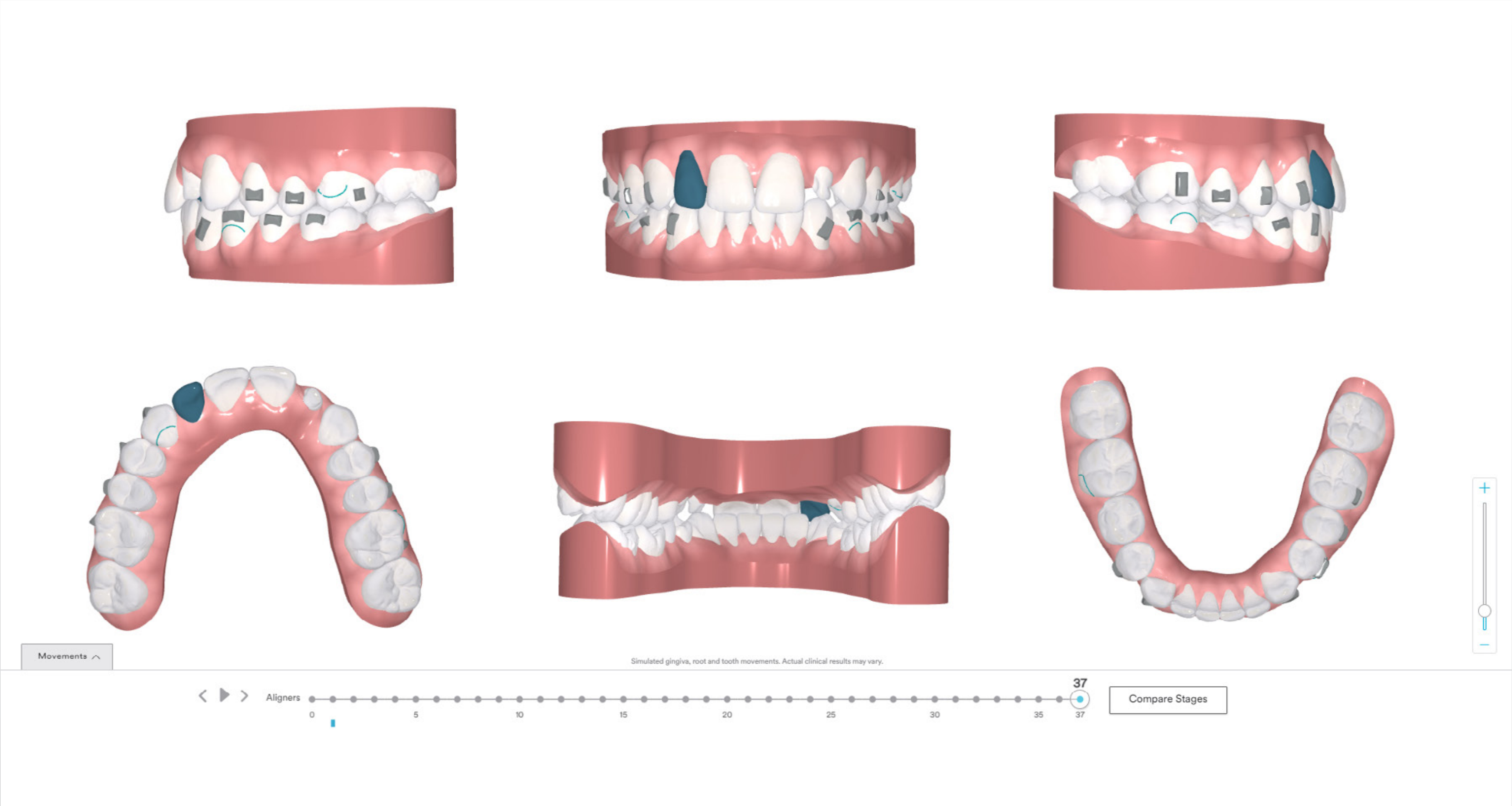
Panoramic radiograph

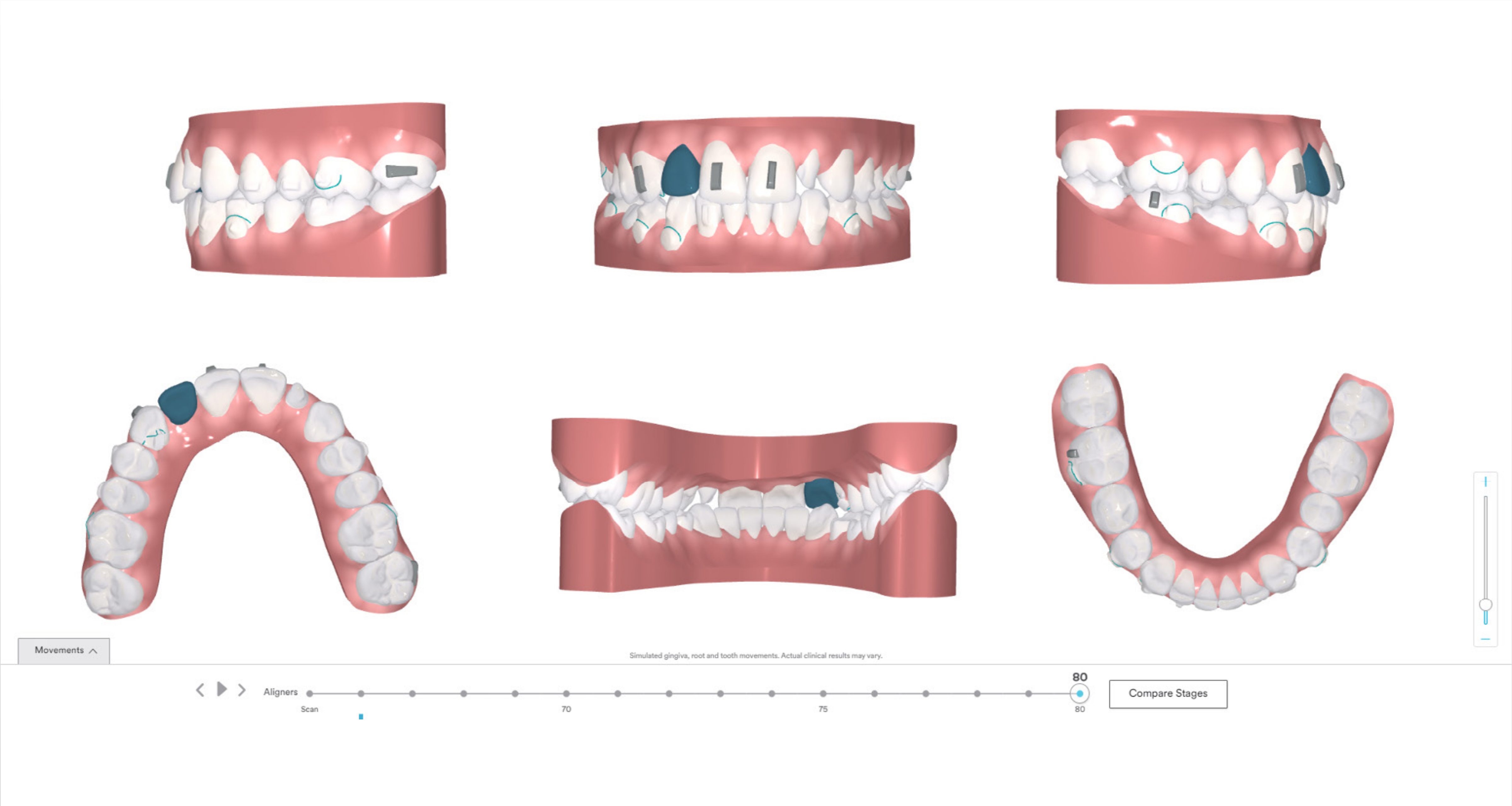
Initial



Final







Learn more at **3M.com/ClarityCasesAU**
and **3M.com/ClarityCasesNZ**