

Case Study: 3M™ Clarity™ Aligners

Class III open bite with skeletal asymmetry (surgery was declined).

Age: 41

Total number of aligners: 50 (dual arch)

Wear interval: Weekly

Treatment time: 16 months

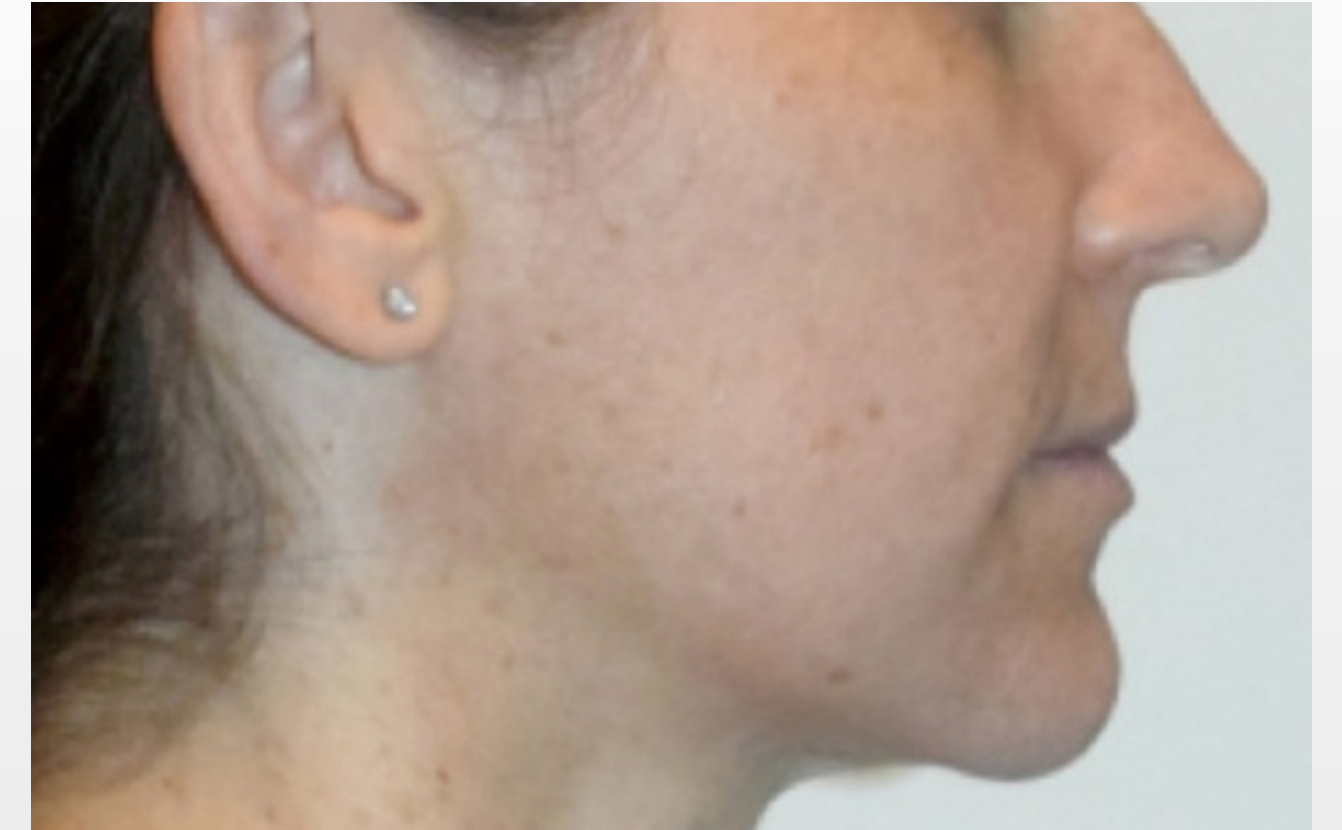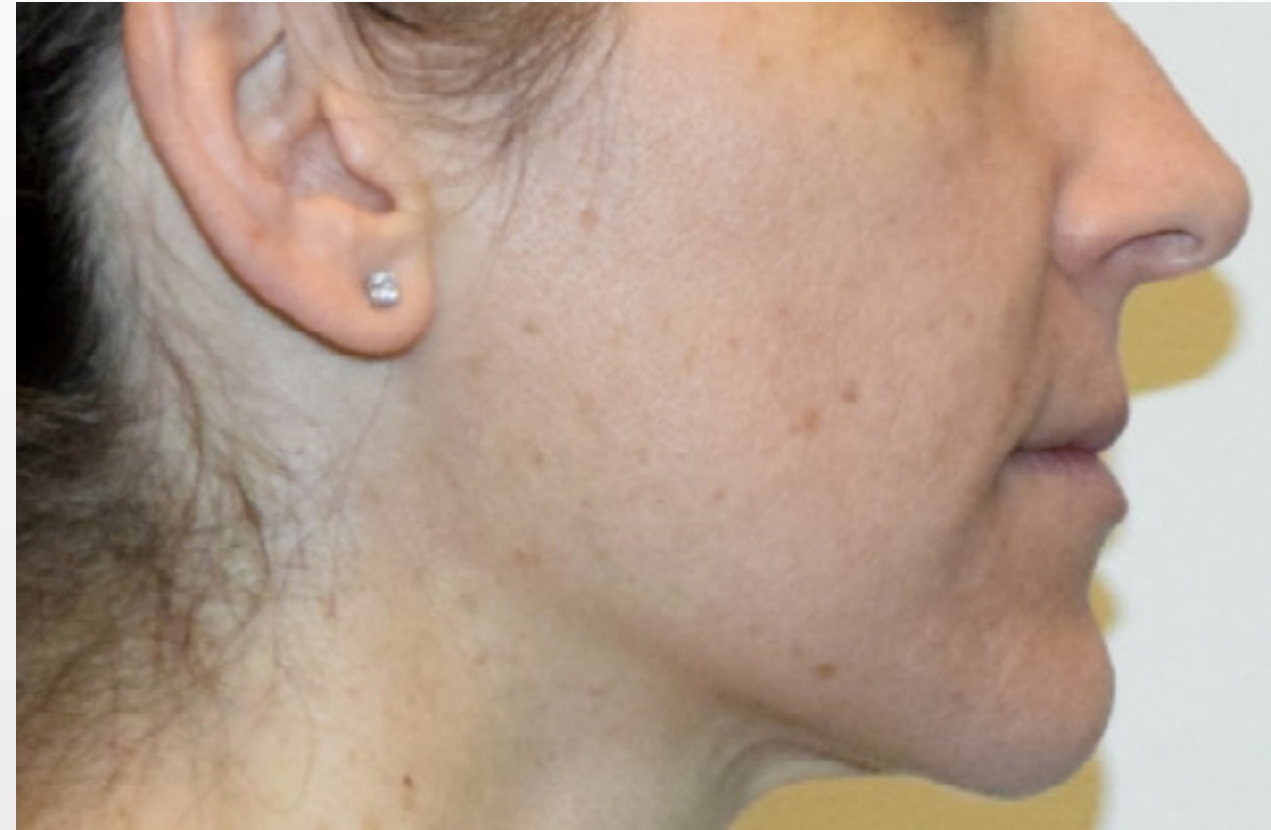Case courtesy of:

Dr. Lisa Davison
Powell, OH – USA

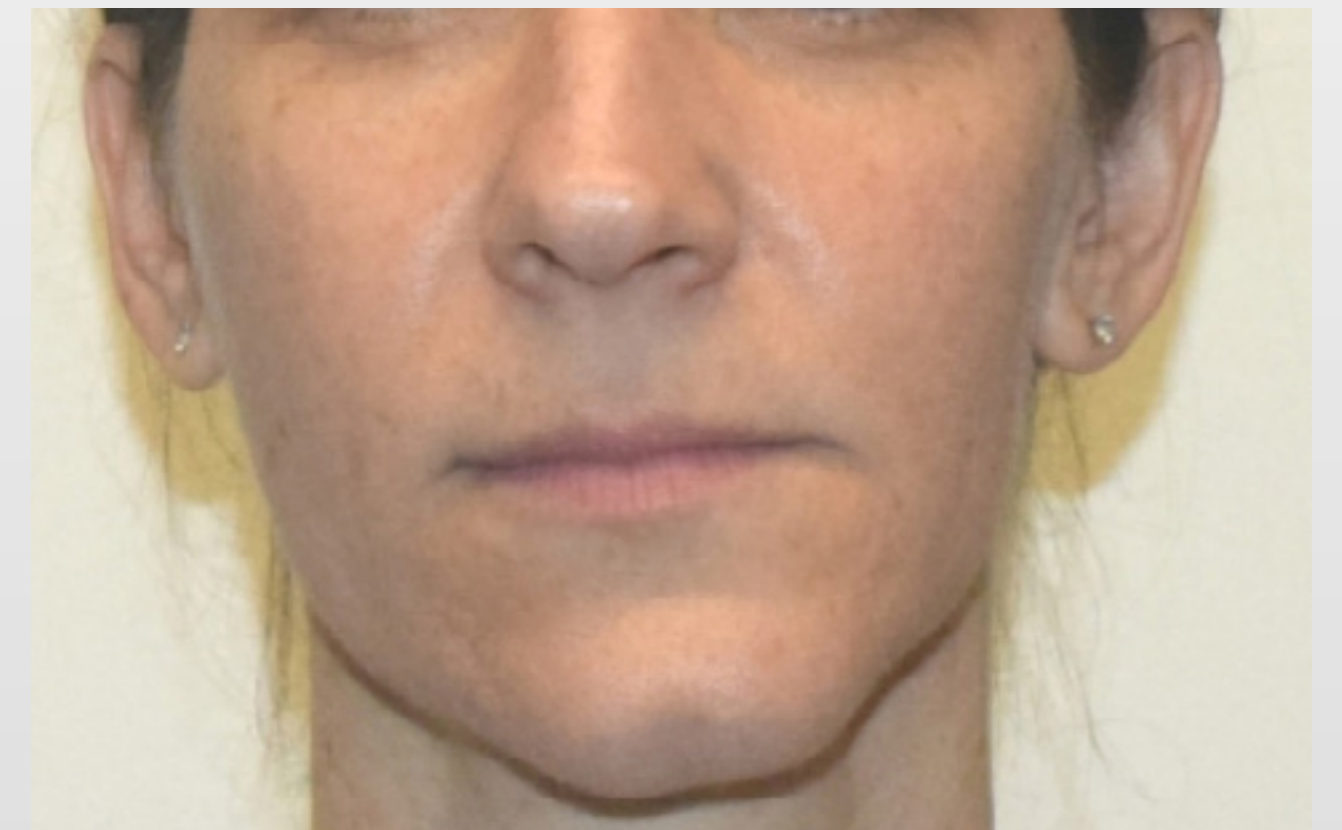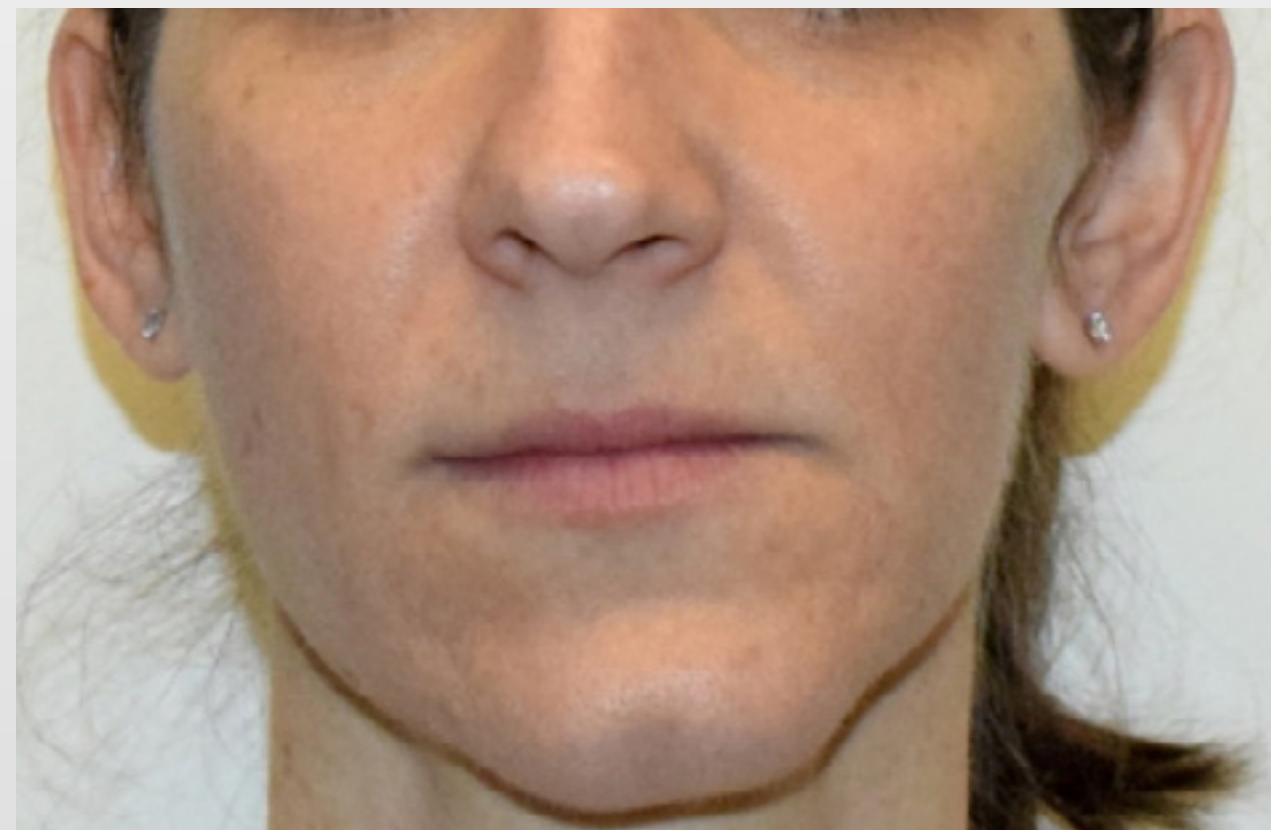Initial

Final

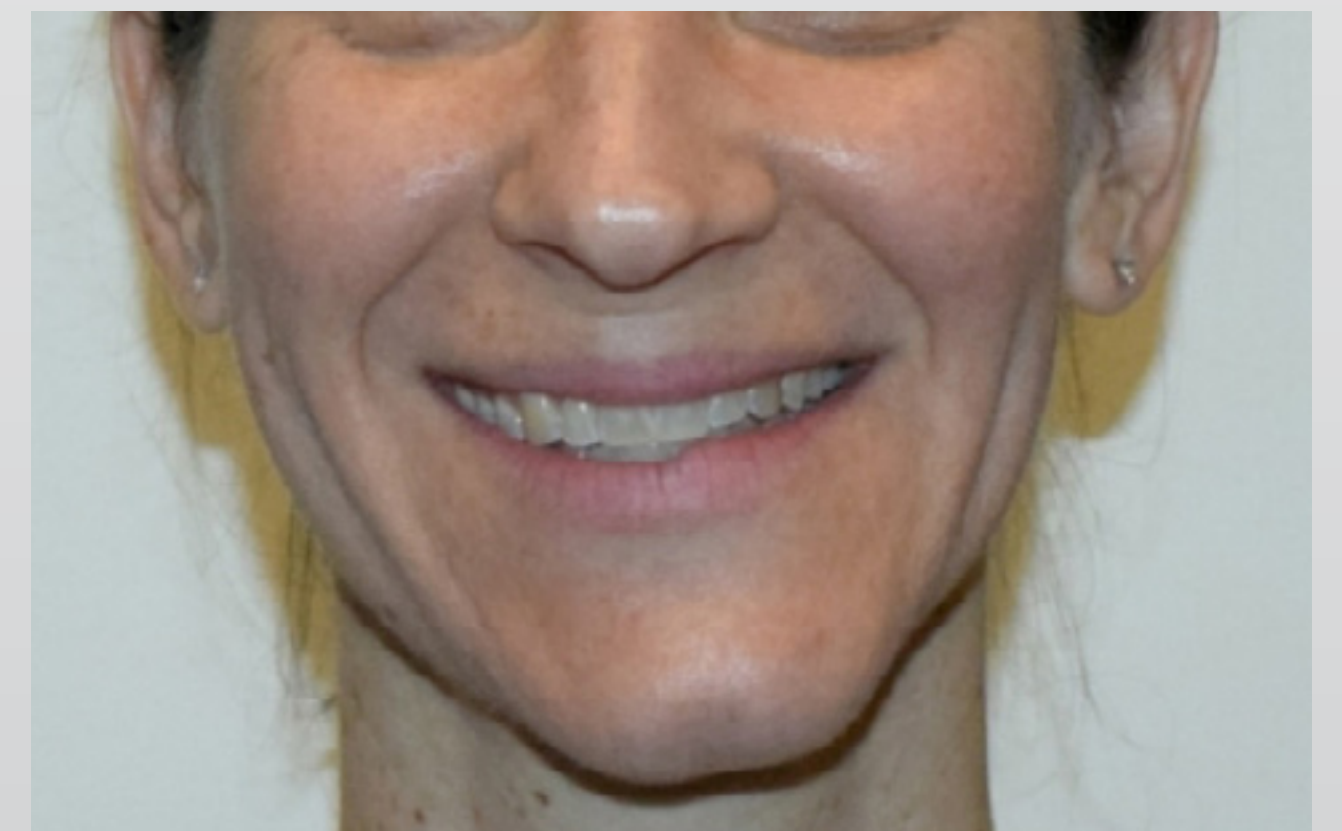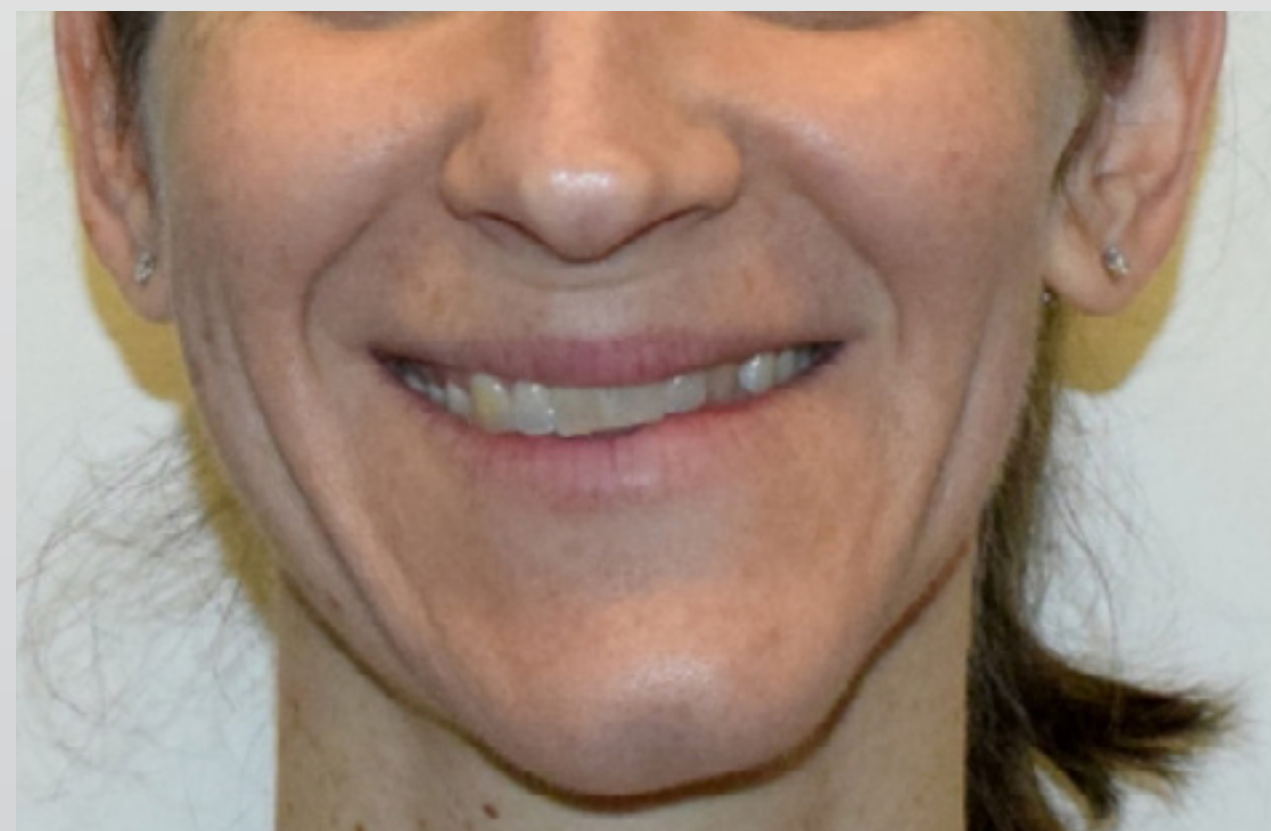Profile at rest



Face at rest



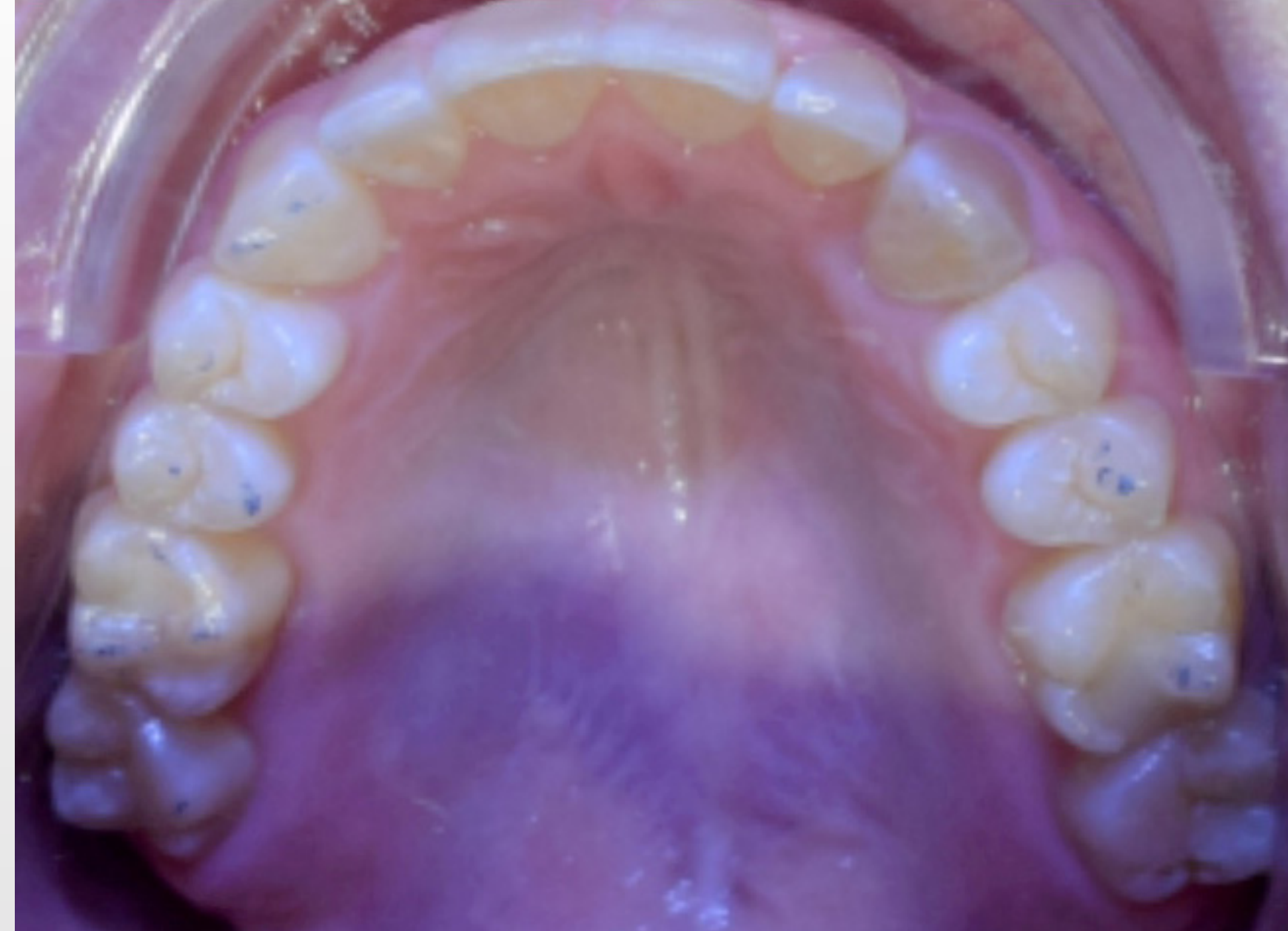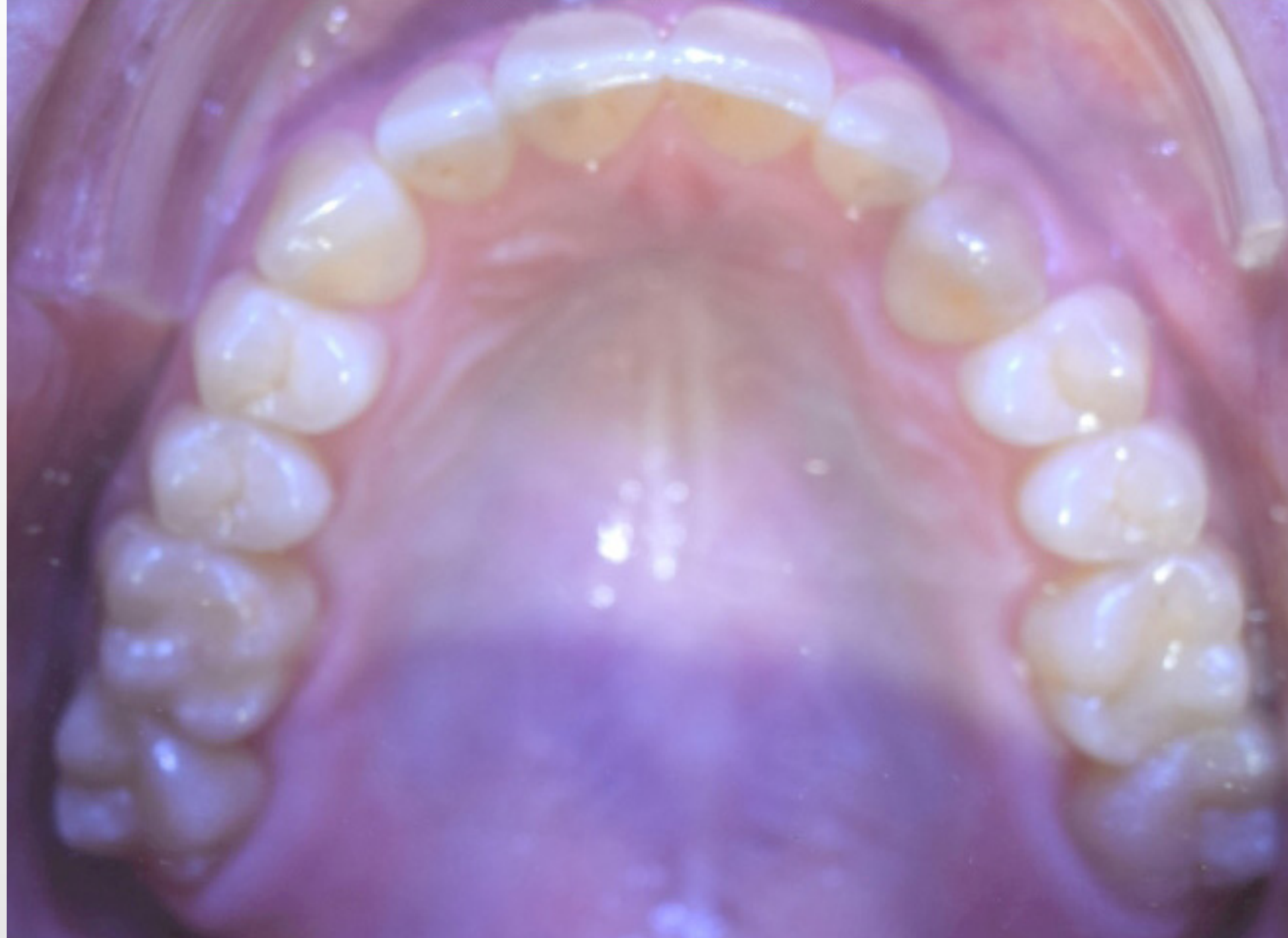Face smiling



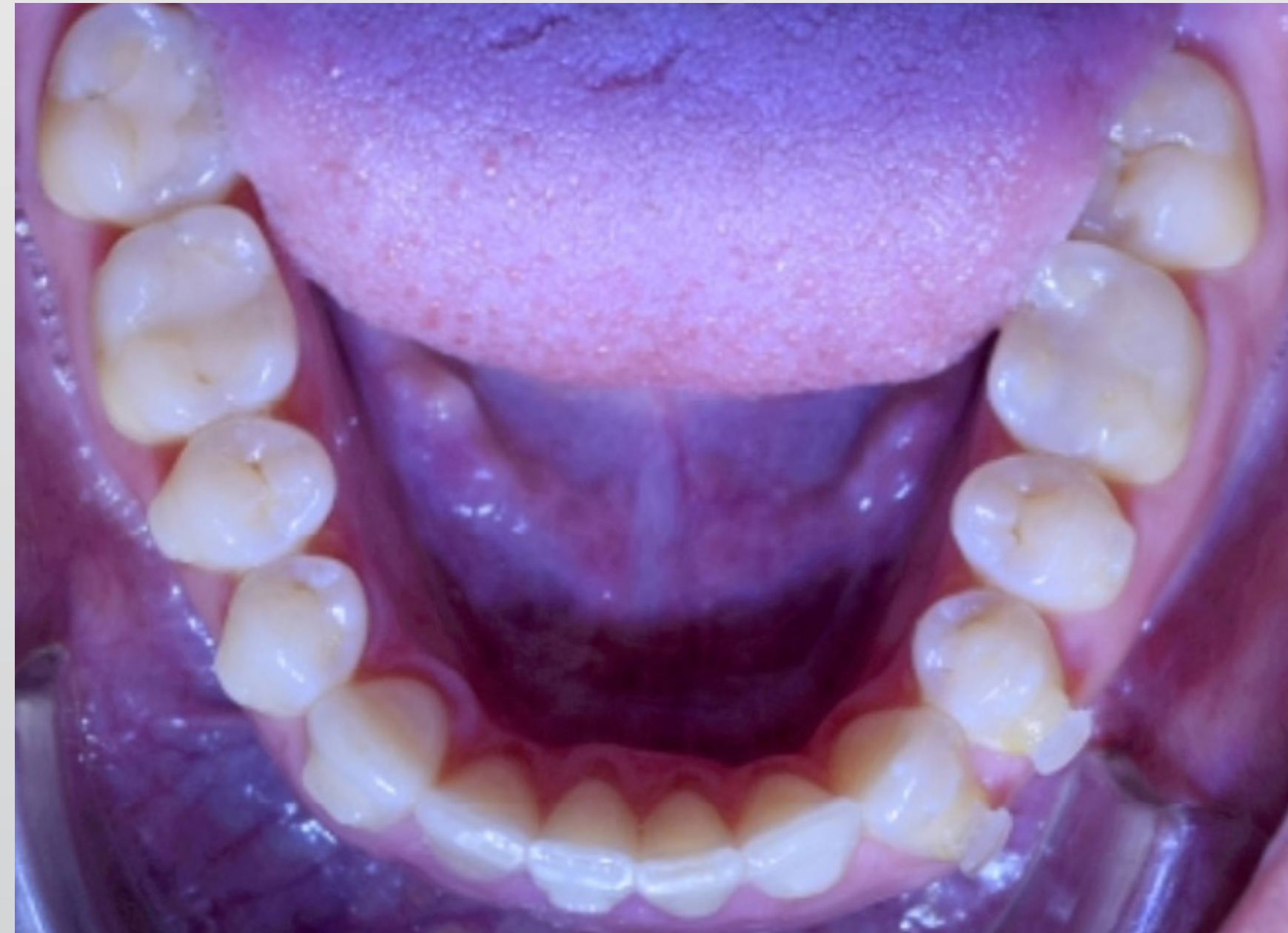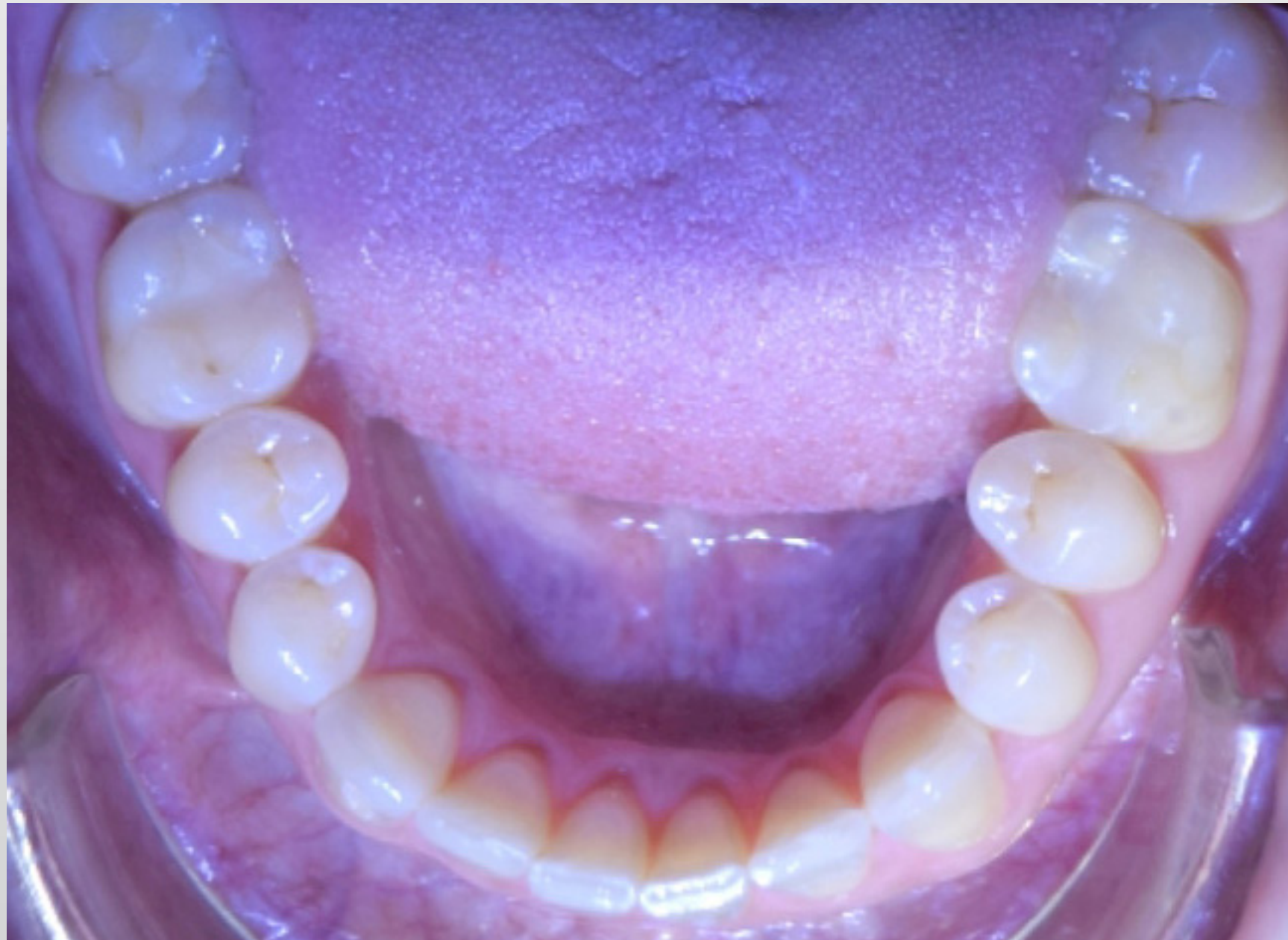Initial

Final

**Occlusal –
maxillary**



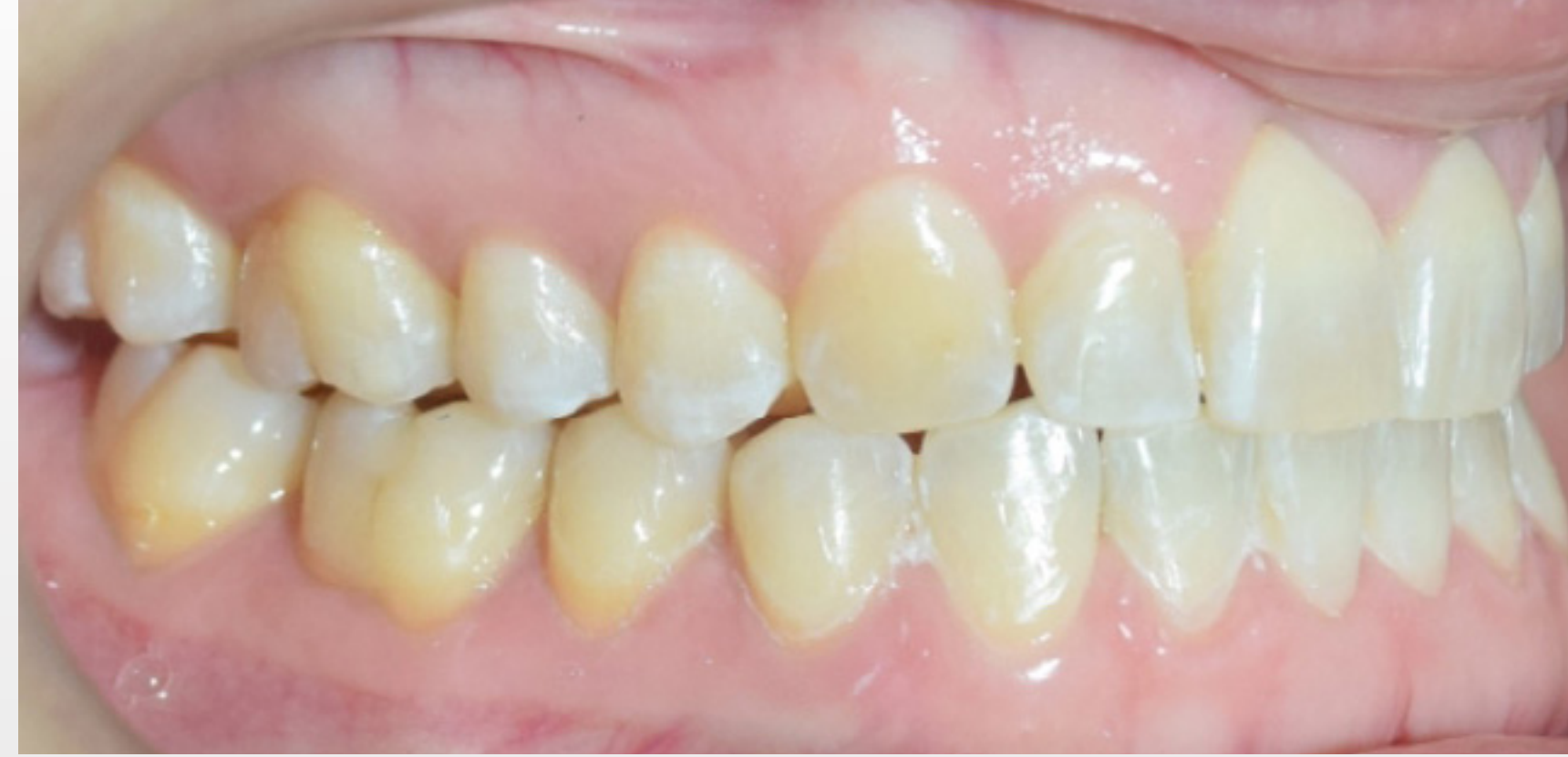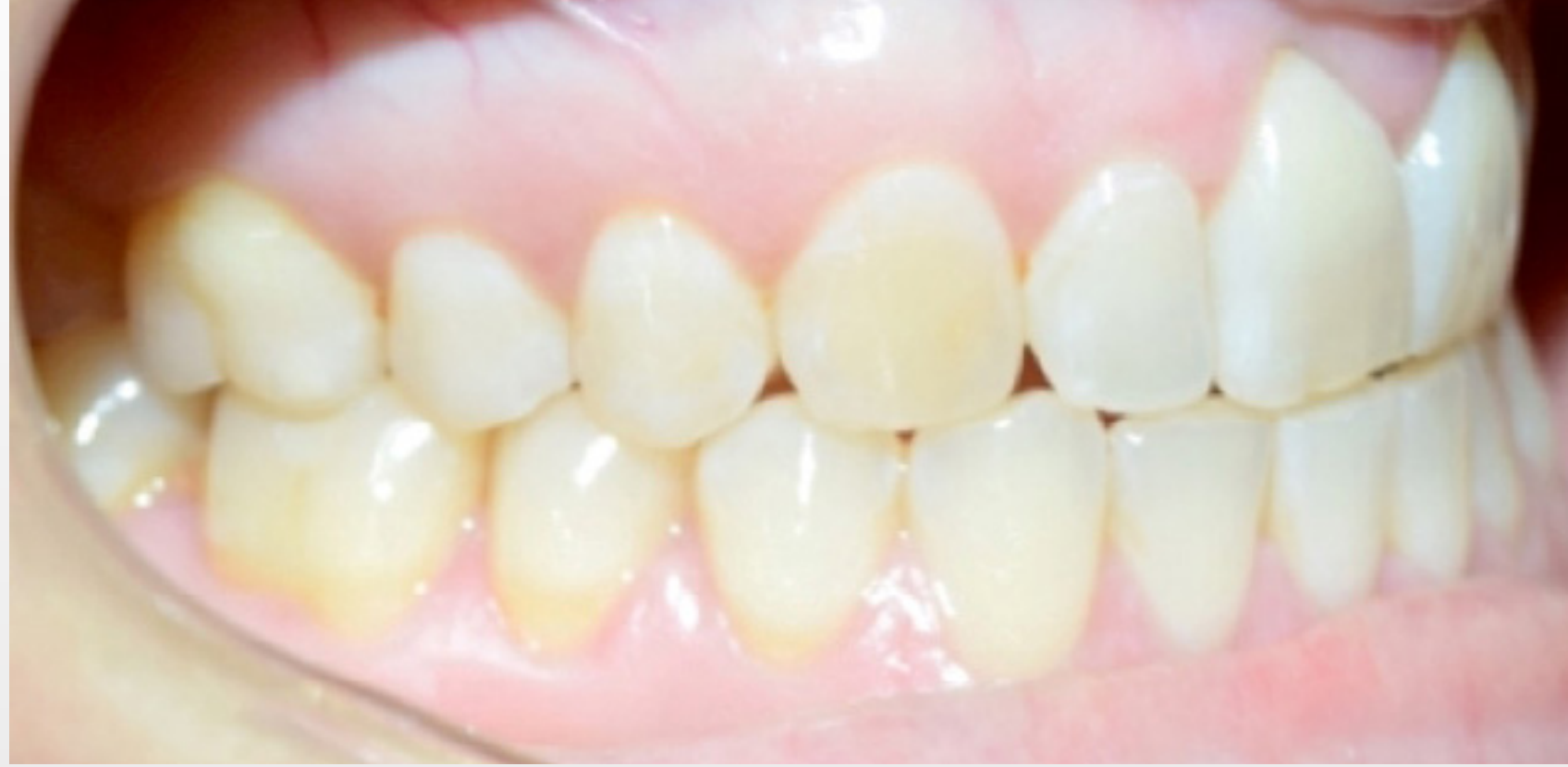**Occlusal –
mandibular**



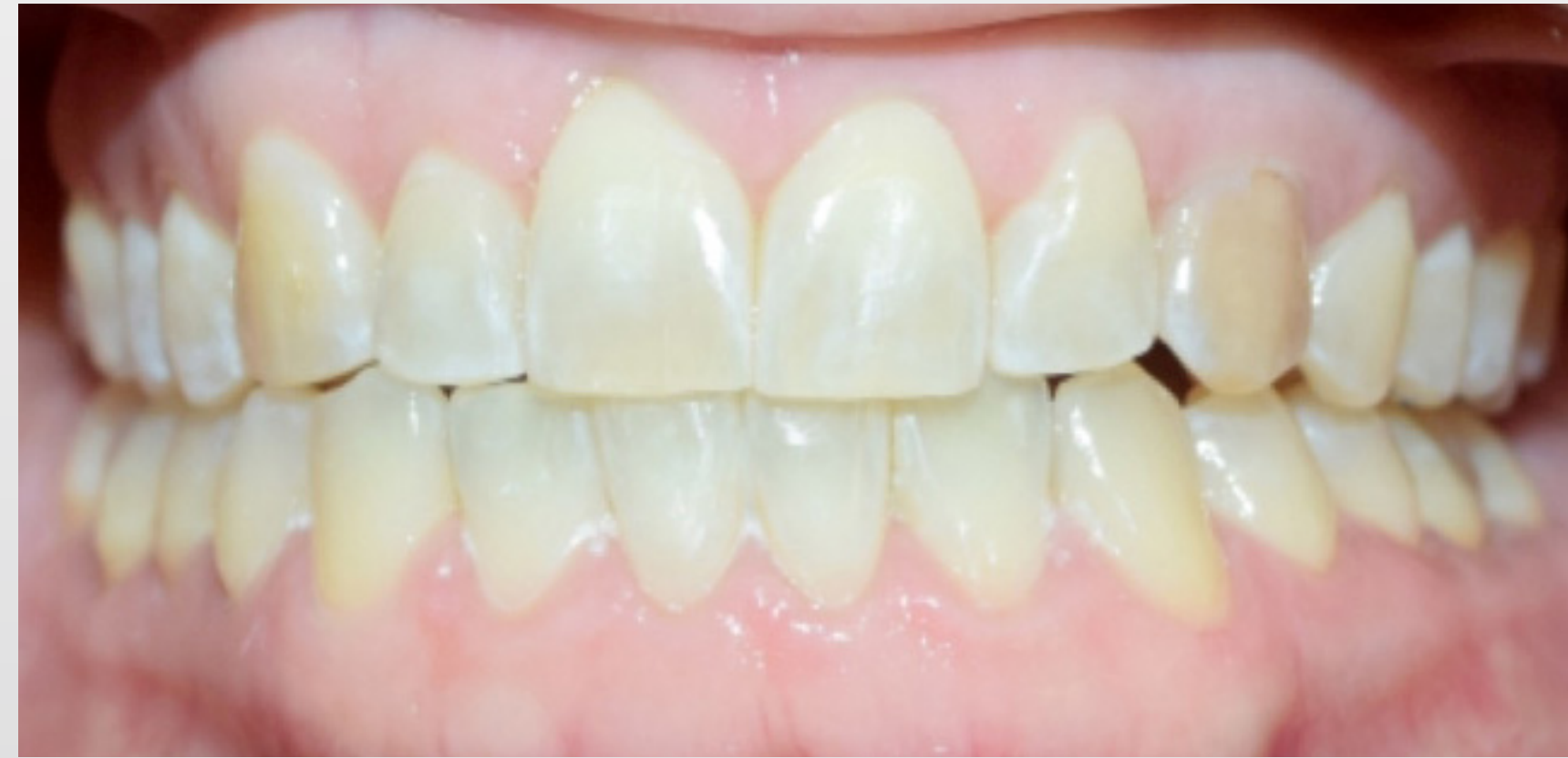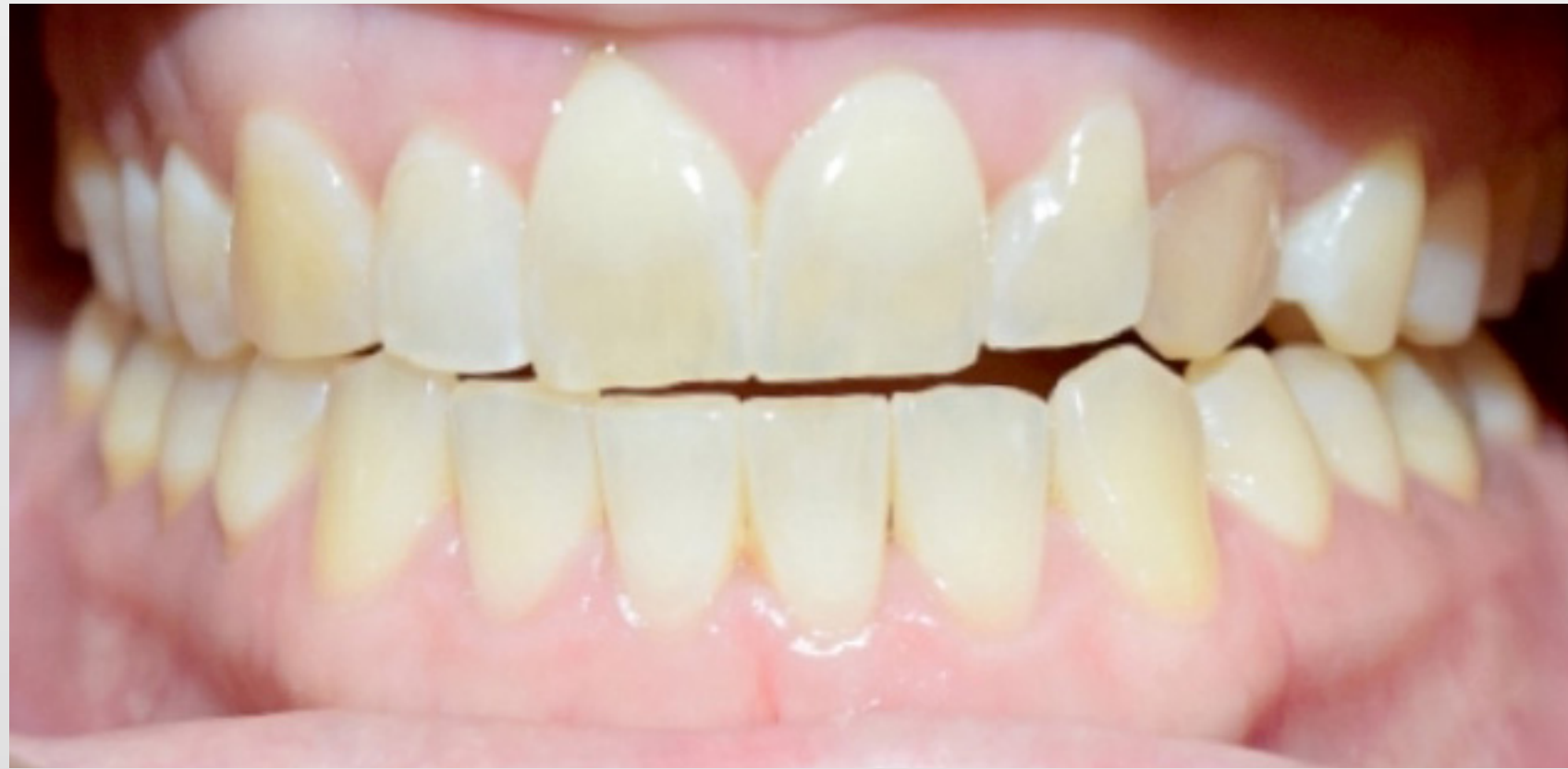Initial

Final

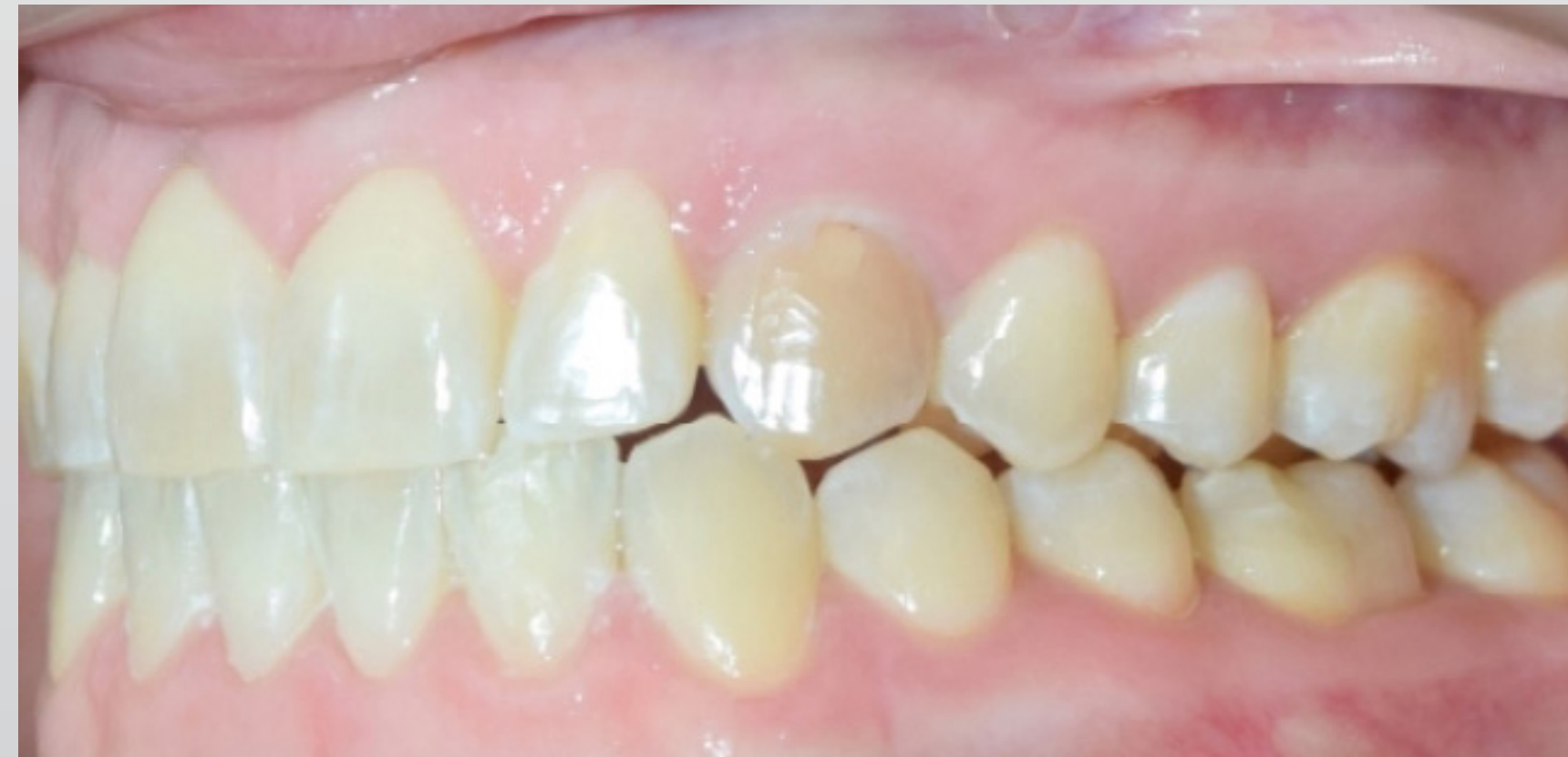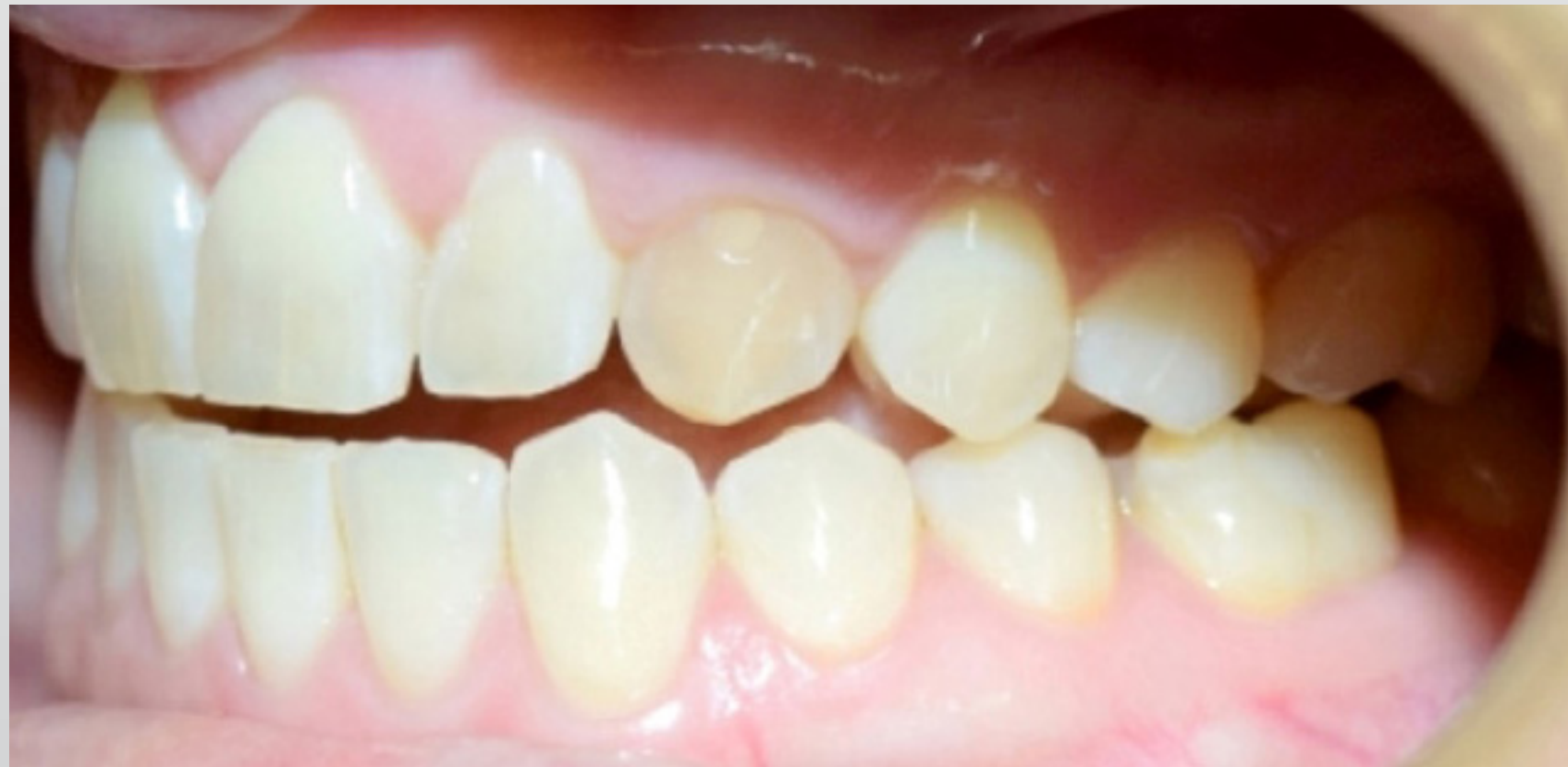**Retracted
buccal – right**

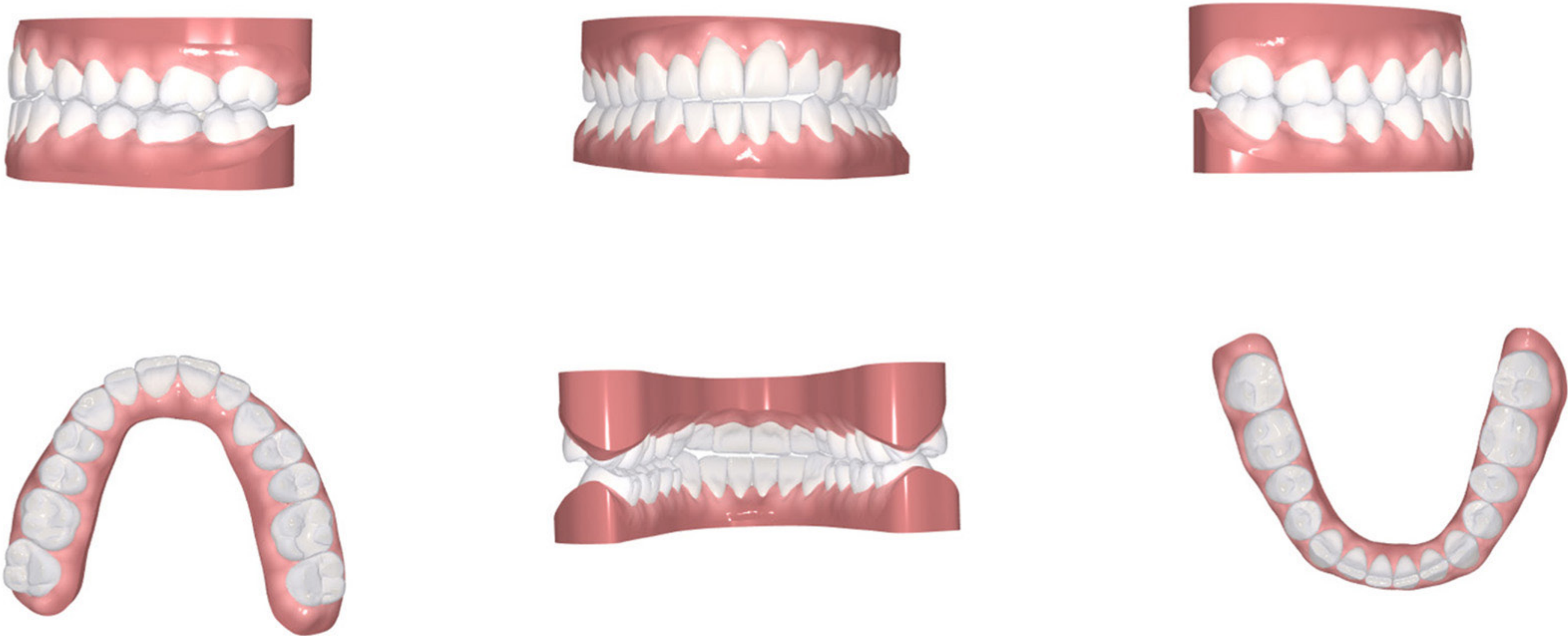


**Retracted
anterior biting**



**Retracted
buccal – left**

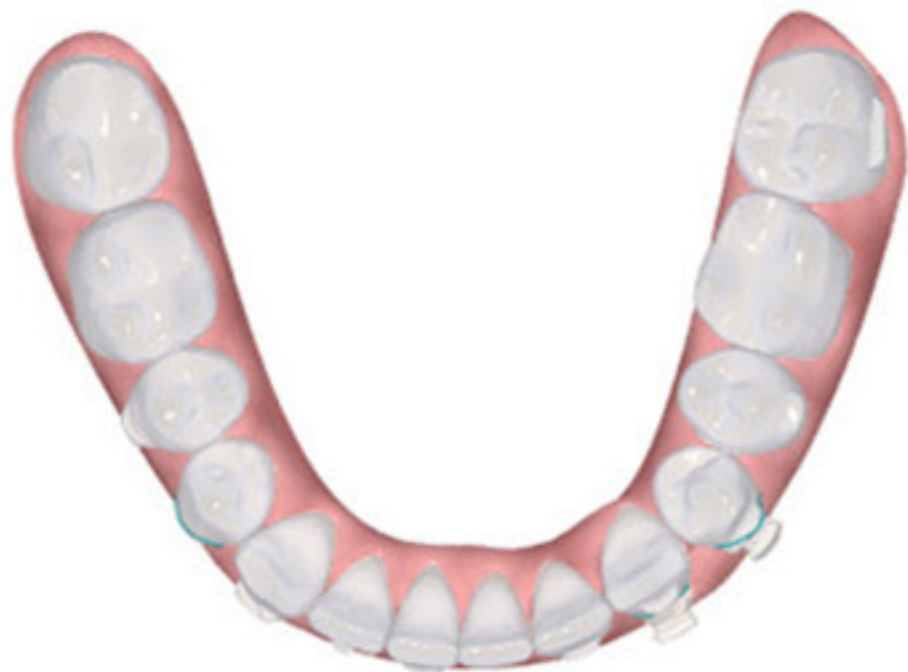
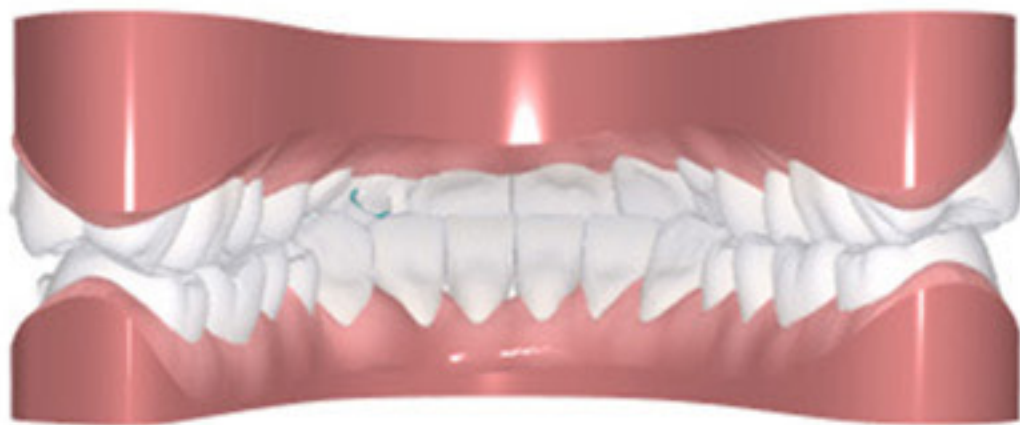
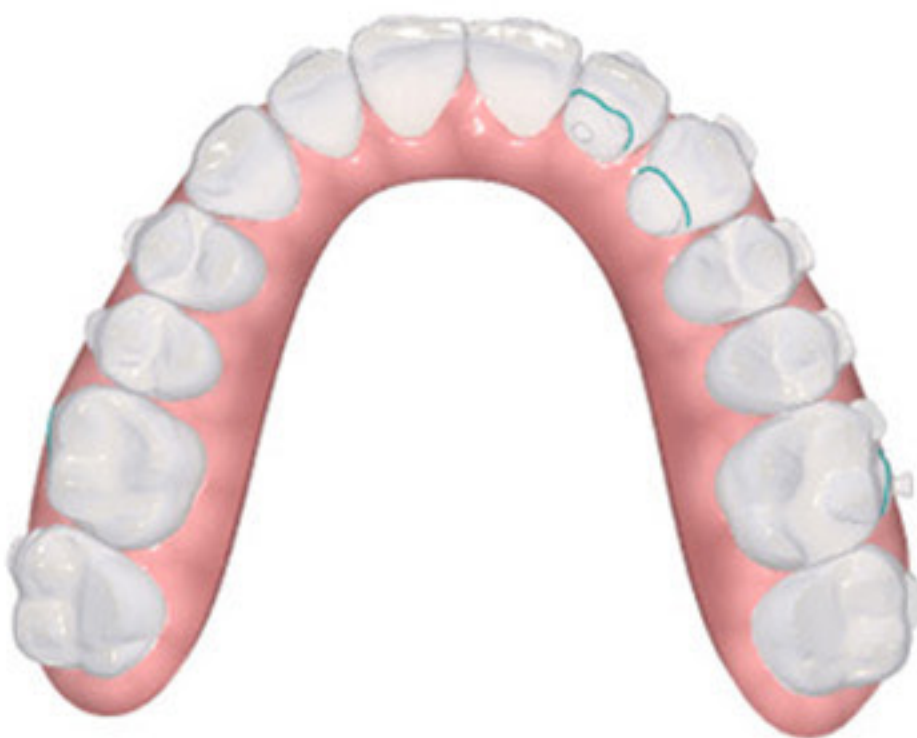
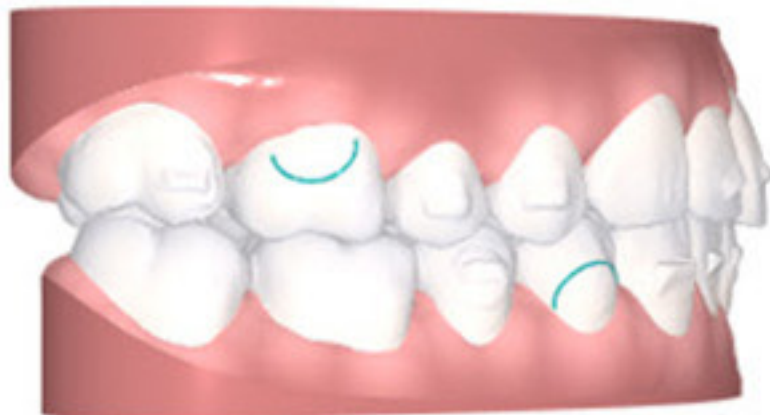
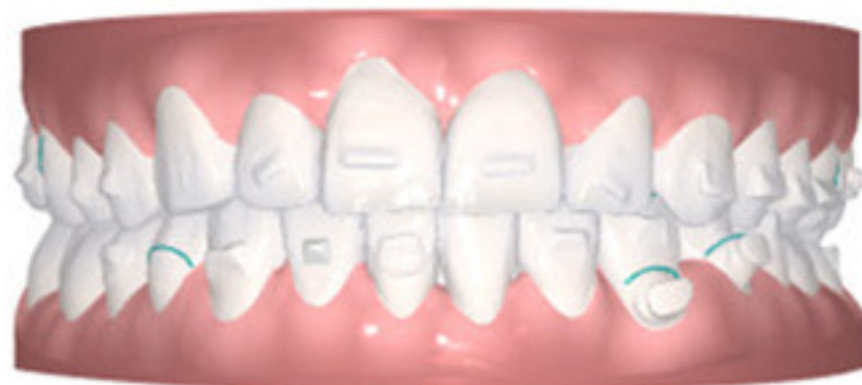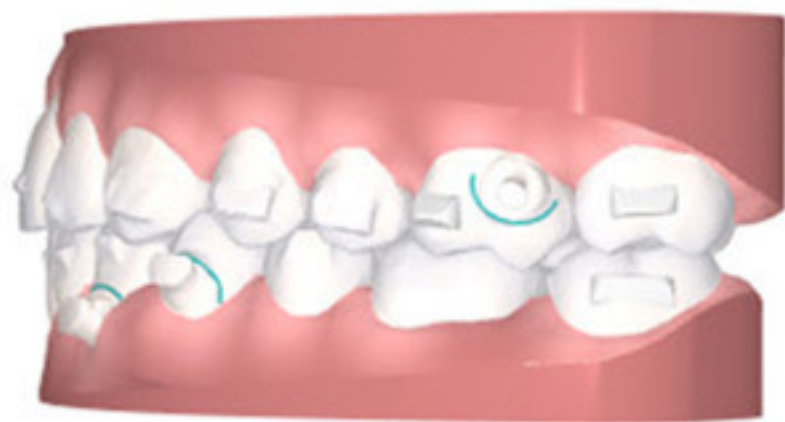Movements ^


Simulated gingiva, root and tooth movements. Actual clinical results may vary.





Movements ^

Simulated gingiva, root and tooth movements. Actual clinical results may vary.



Compare Stages

Learn more at **3M.com/ClarityCasesAU**
and **3M.com/ClarityCasesNZ**