

**Case Study:** 3M™ Clarity™ Aligners

## Asymmetric Class III with mild upper and lower crowding

**Age:** 29

**Chief concern:** Front top teeth and bottom teeth rubbing together

**Case diagnostics:** Class I skeletal, asymmetrical Class III malocclusion with traumatic incisor occlusion and mild upper and lower crowding

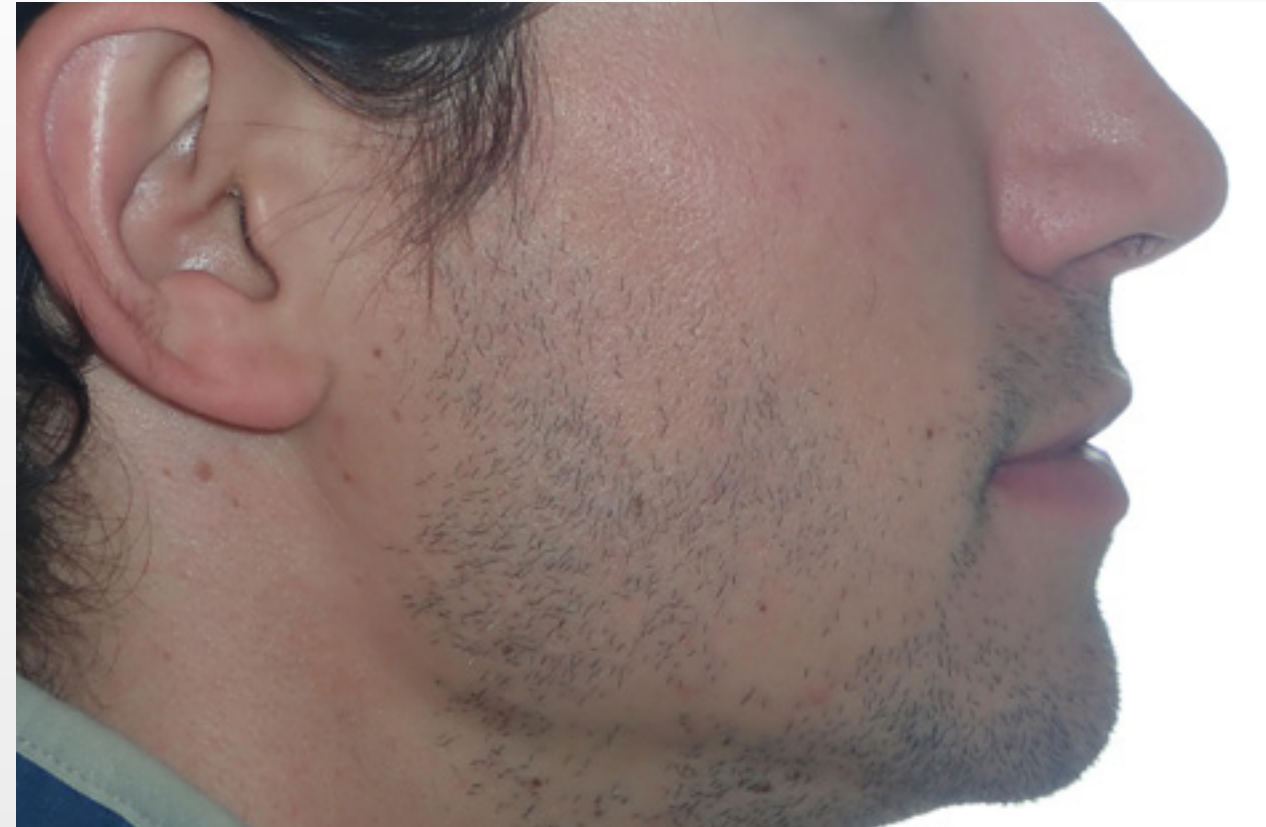**Total number of aligners:** 47 total aligners (11 aligners in Initial Tx Design), (16 aligners in Refinement 1), (12 aligners in Refinement 2), (8 aligners in Refinement 3)

**Wear interval:** 2 week changes for stages 1-2. Weekly changes with attachment placement at the beginning of stage 3

**Treatment time:** 25 months (includes 19 weeks “logistics” wait time and a two month delay due to COVID-19 pandemic office closure)

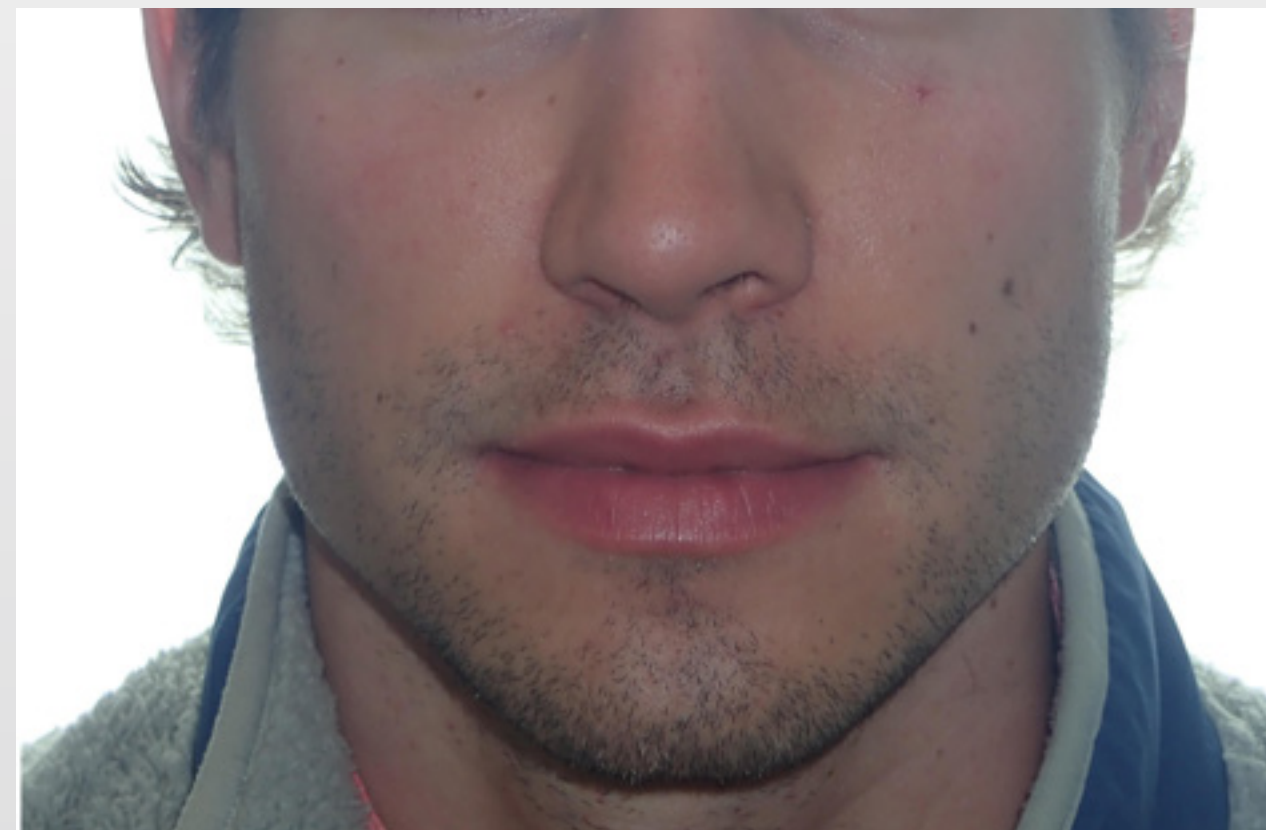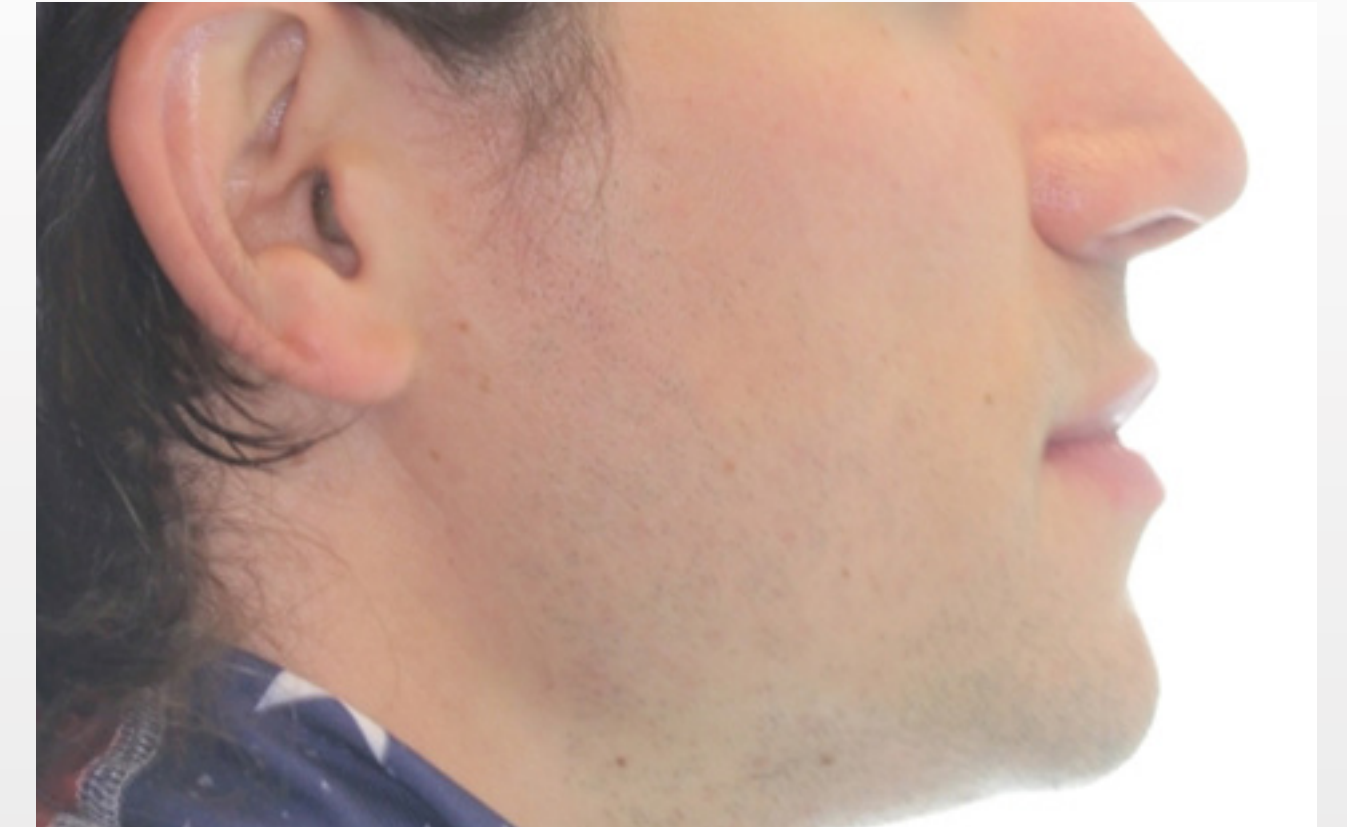**Case courtesy of:**  
Dr. David Hime  
Austin, TX – USA

### Initial

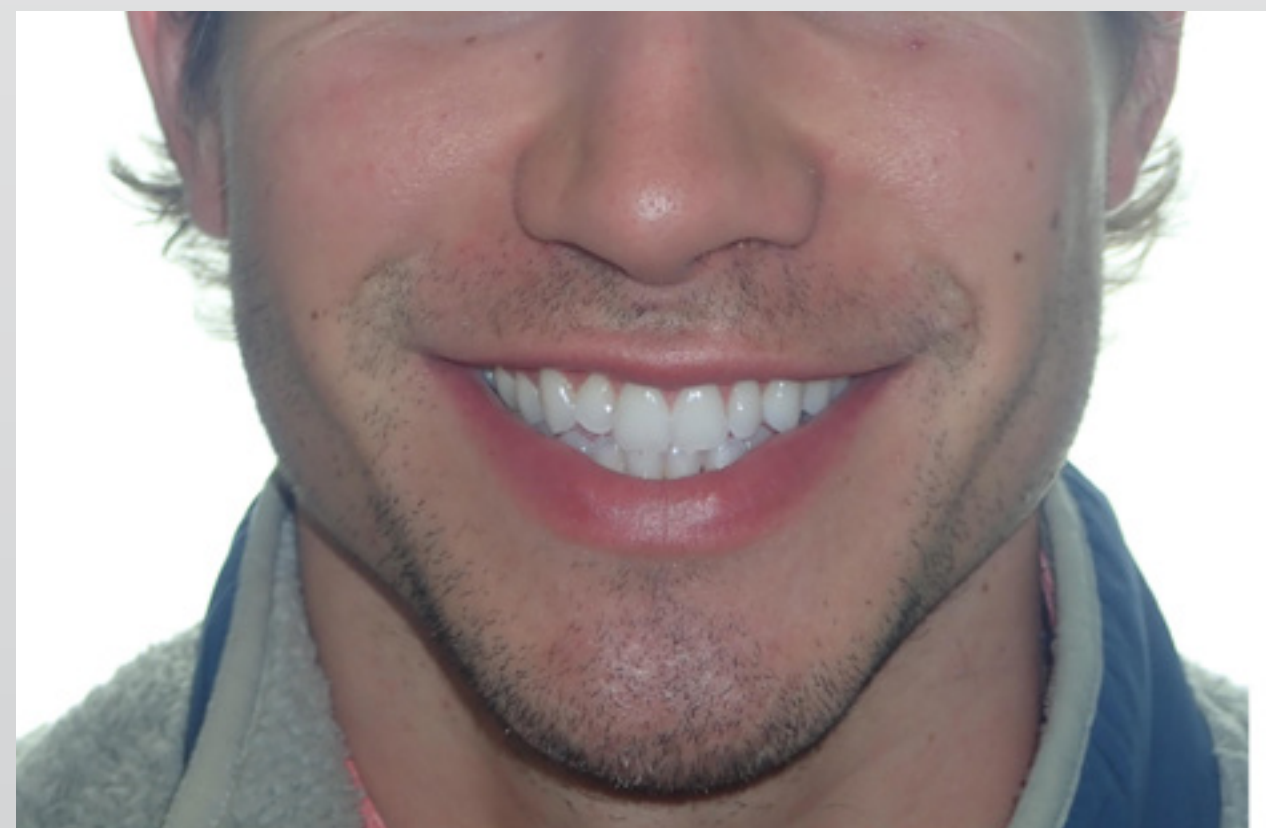
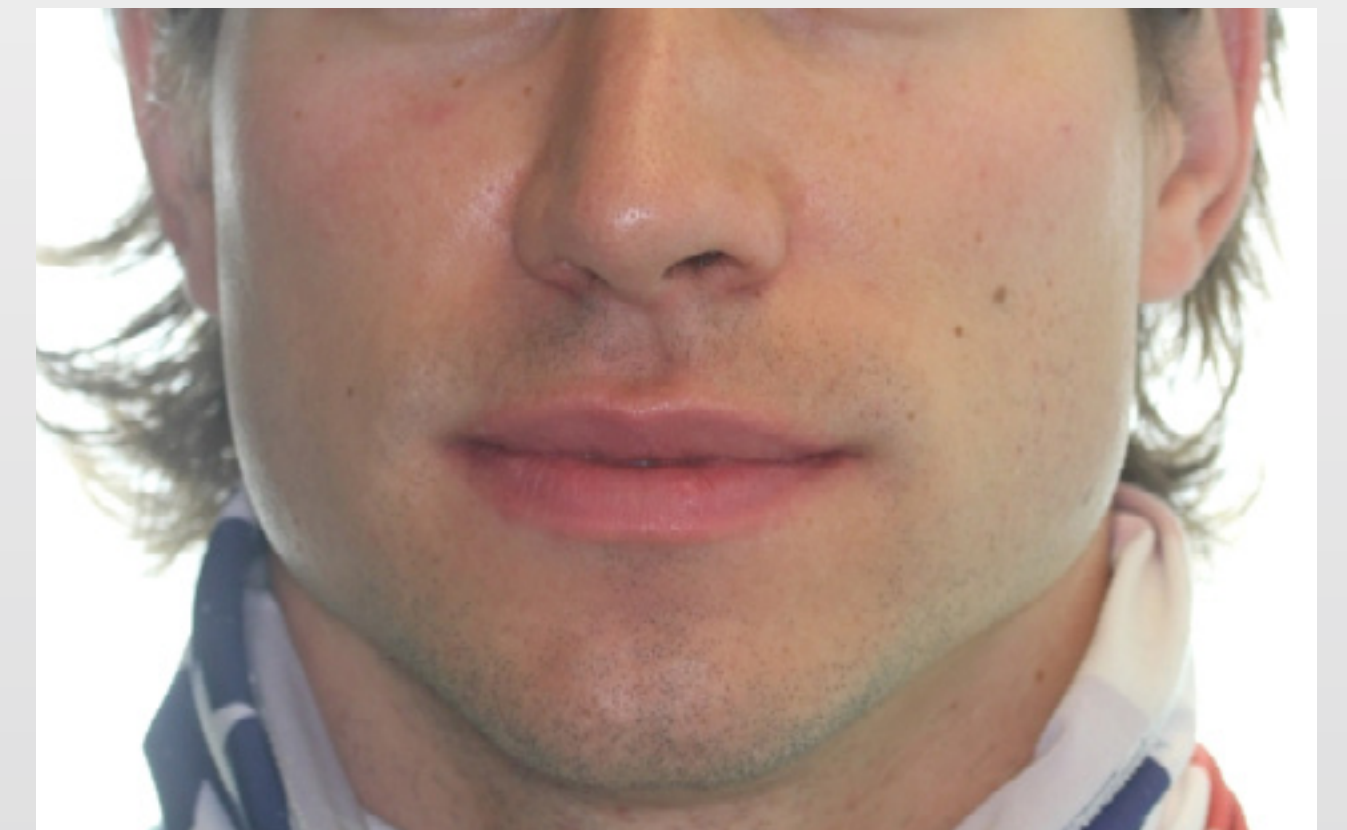
**Profile at rest**

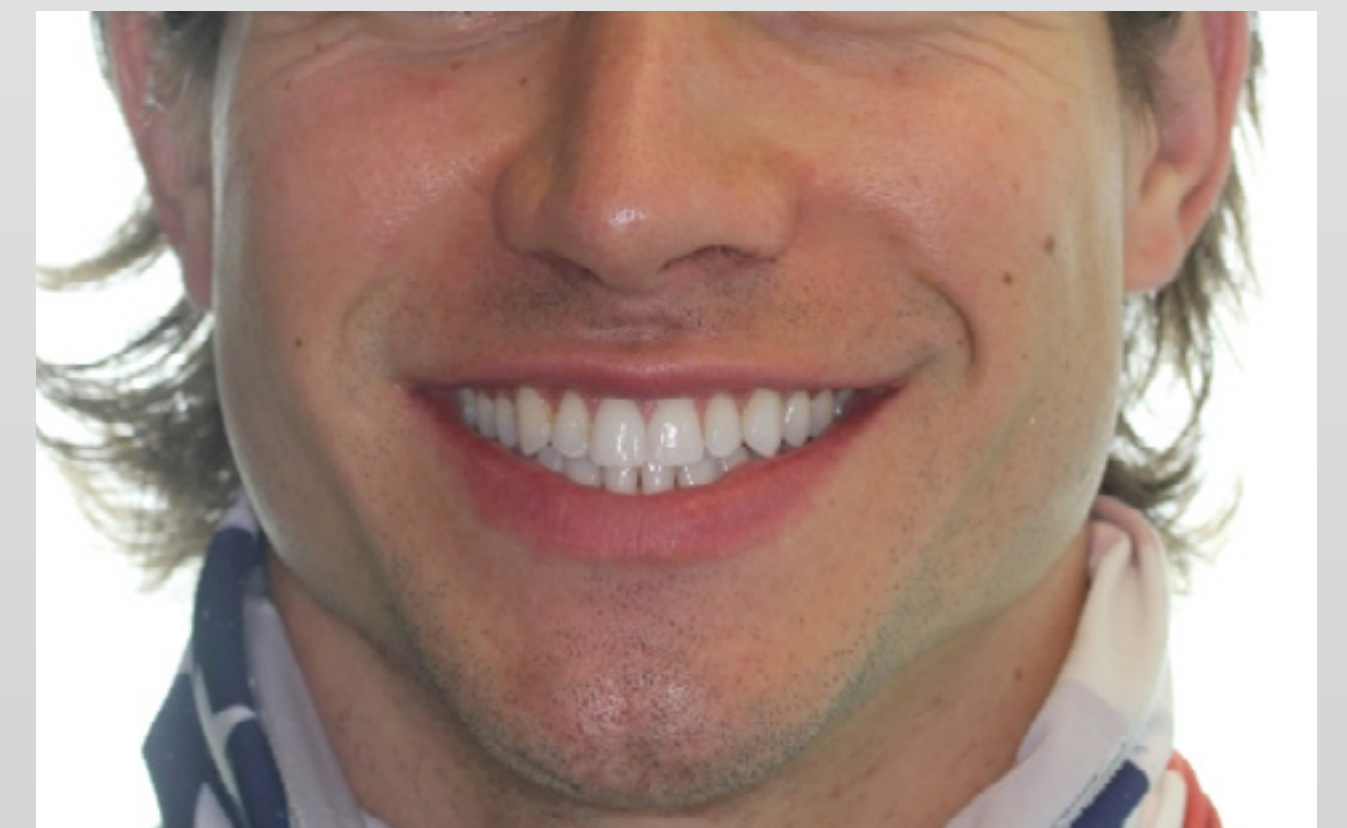### Progress - 2 years, 2 months



**Face at rest**



**Face smiling**



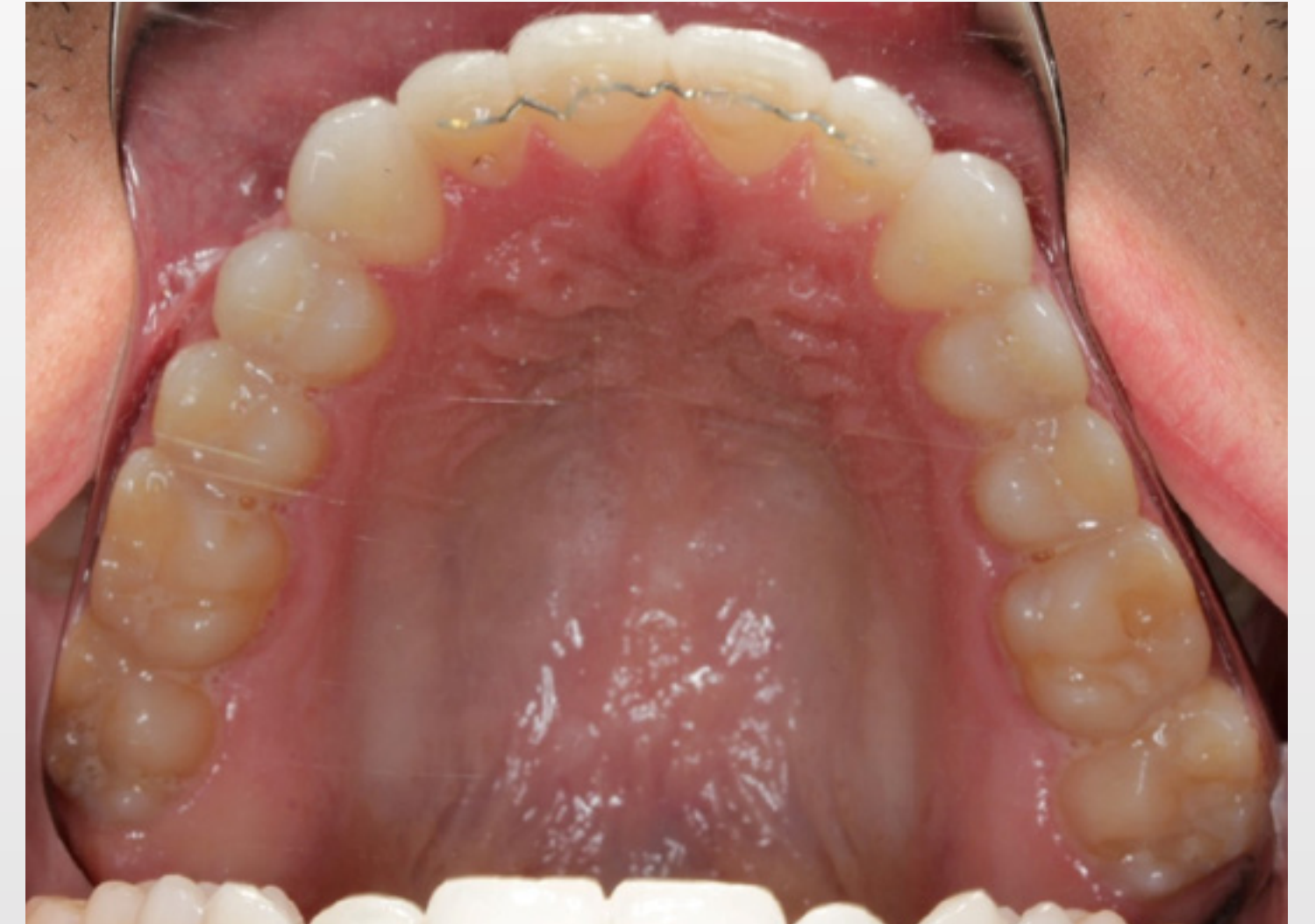
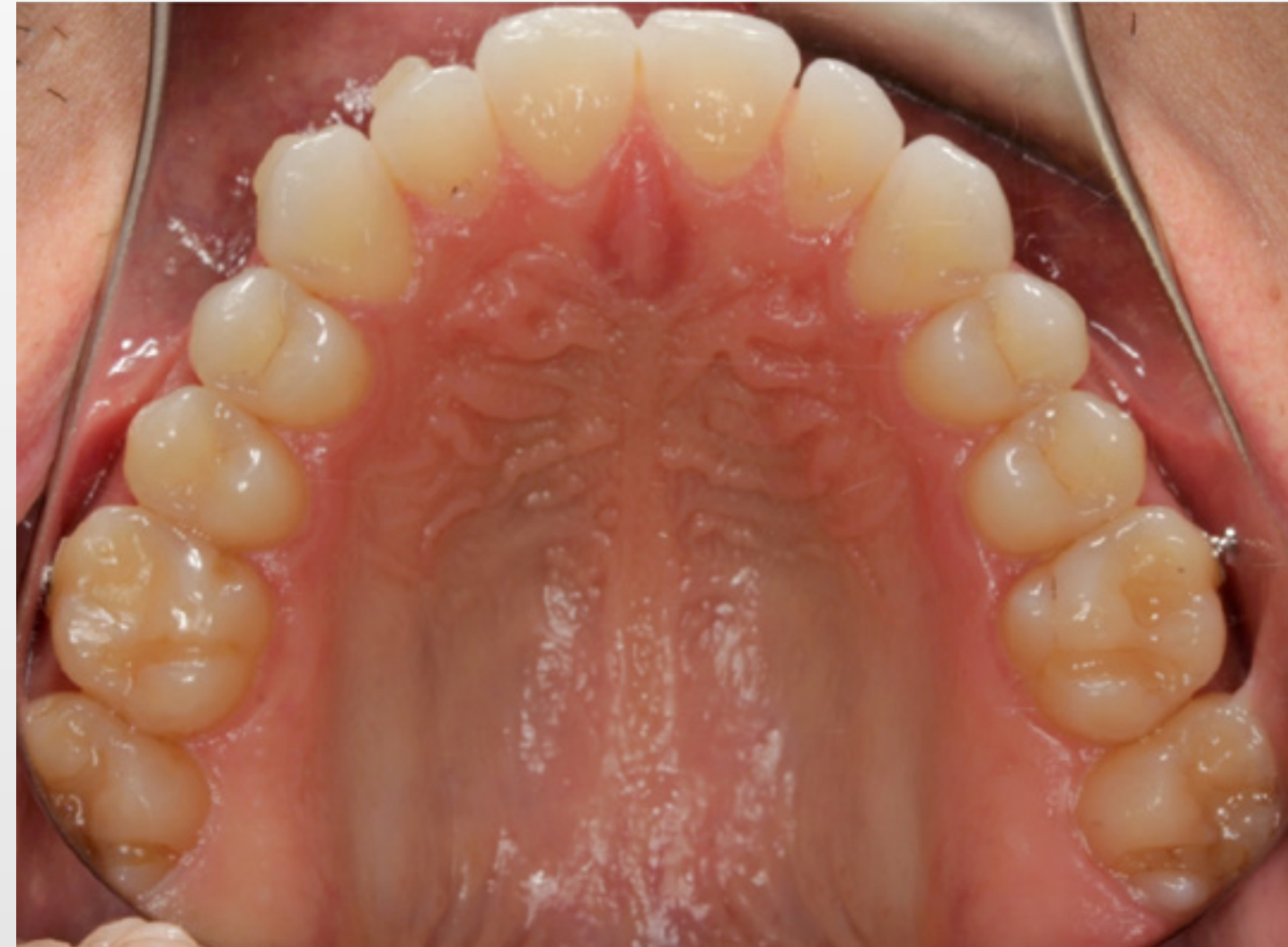
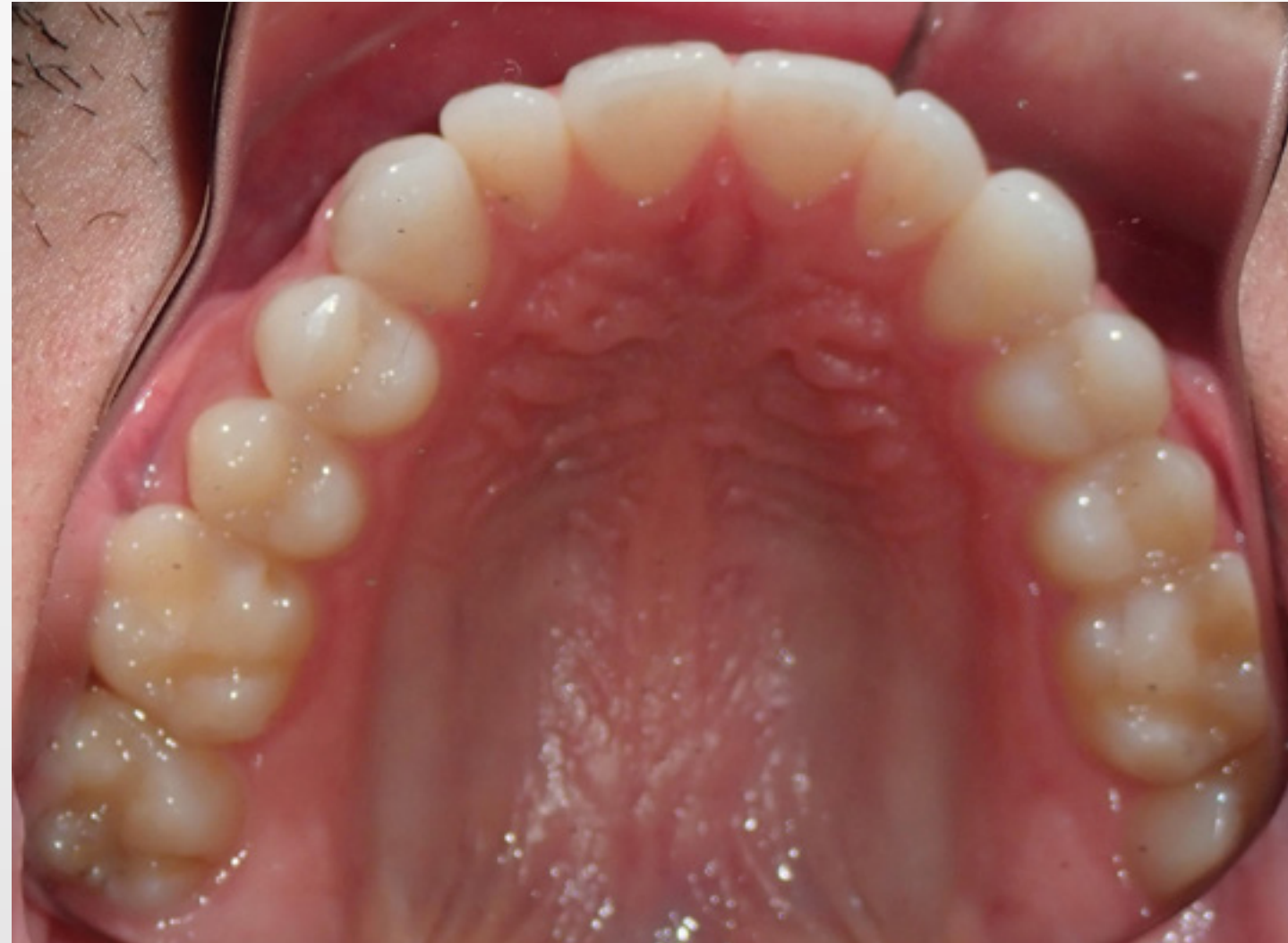**Initial**

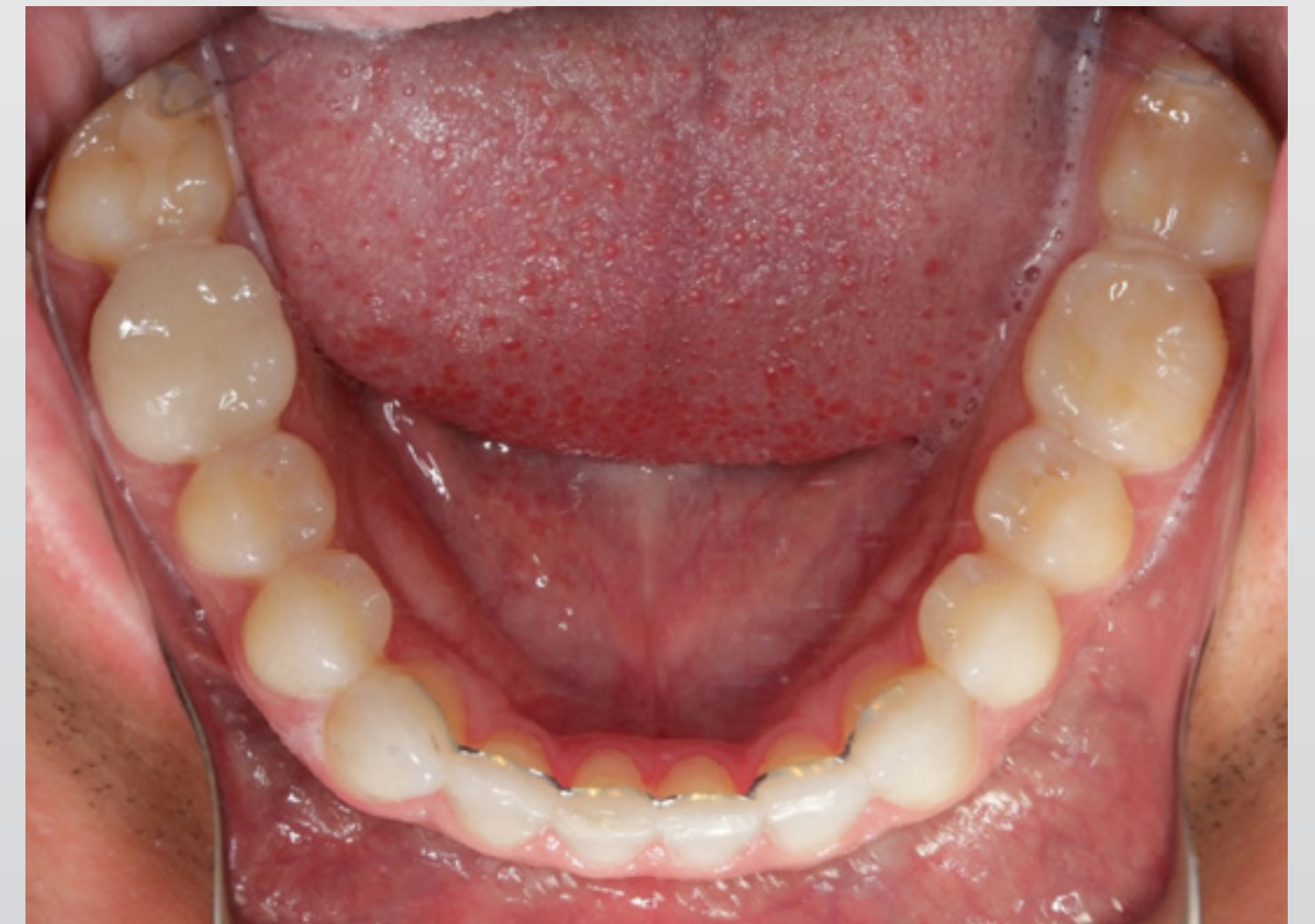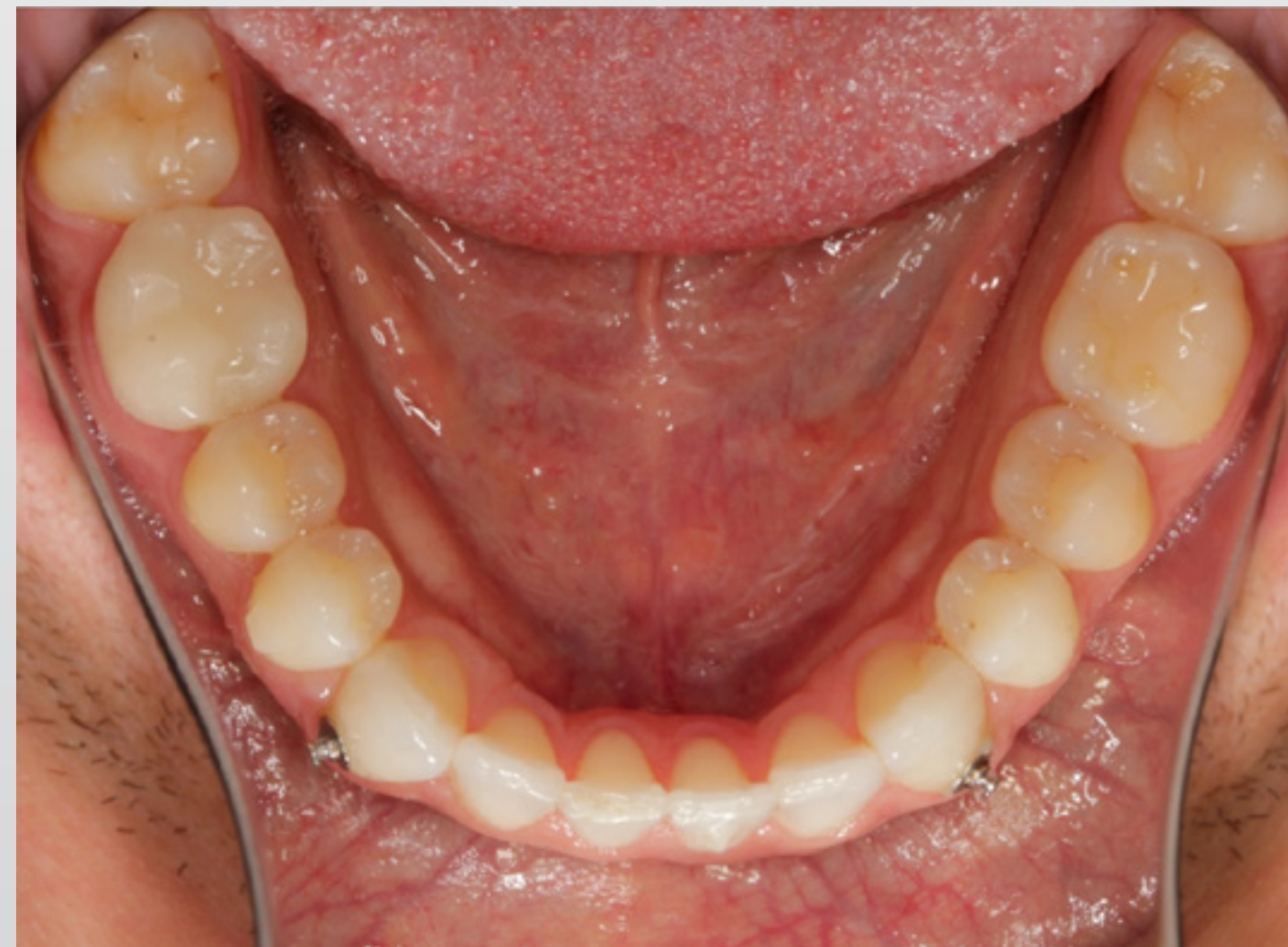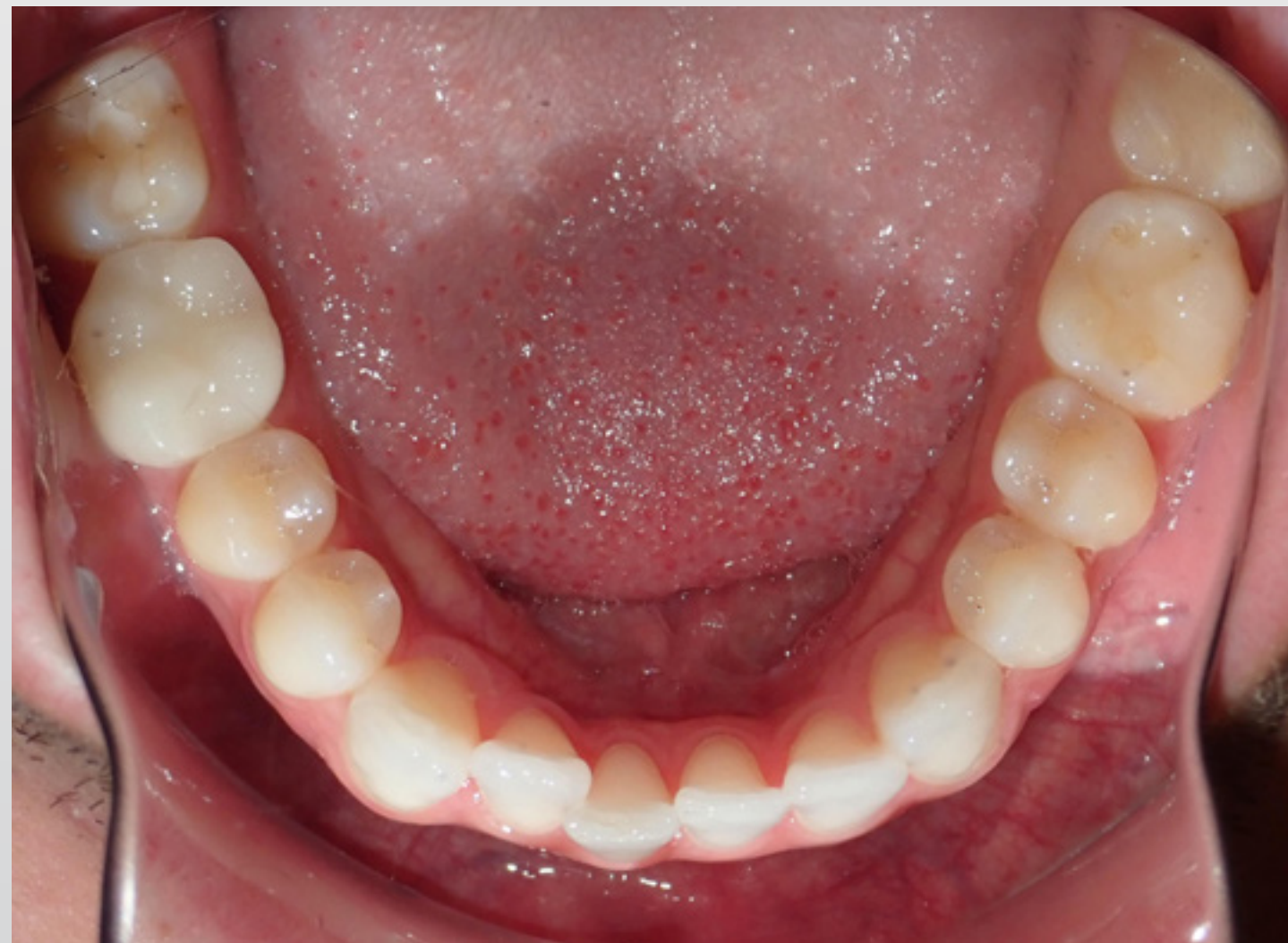**Progress - 1 year, 7 months**

**Final**

**Occlusal –  
maxillary**



**Occlusal –  
mandibular**



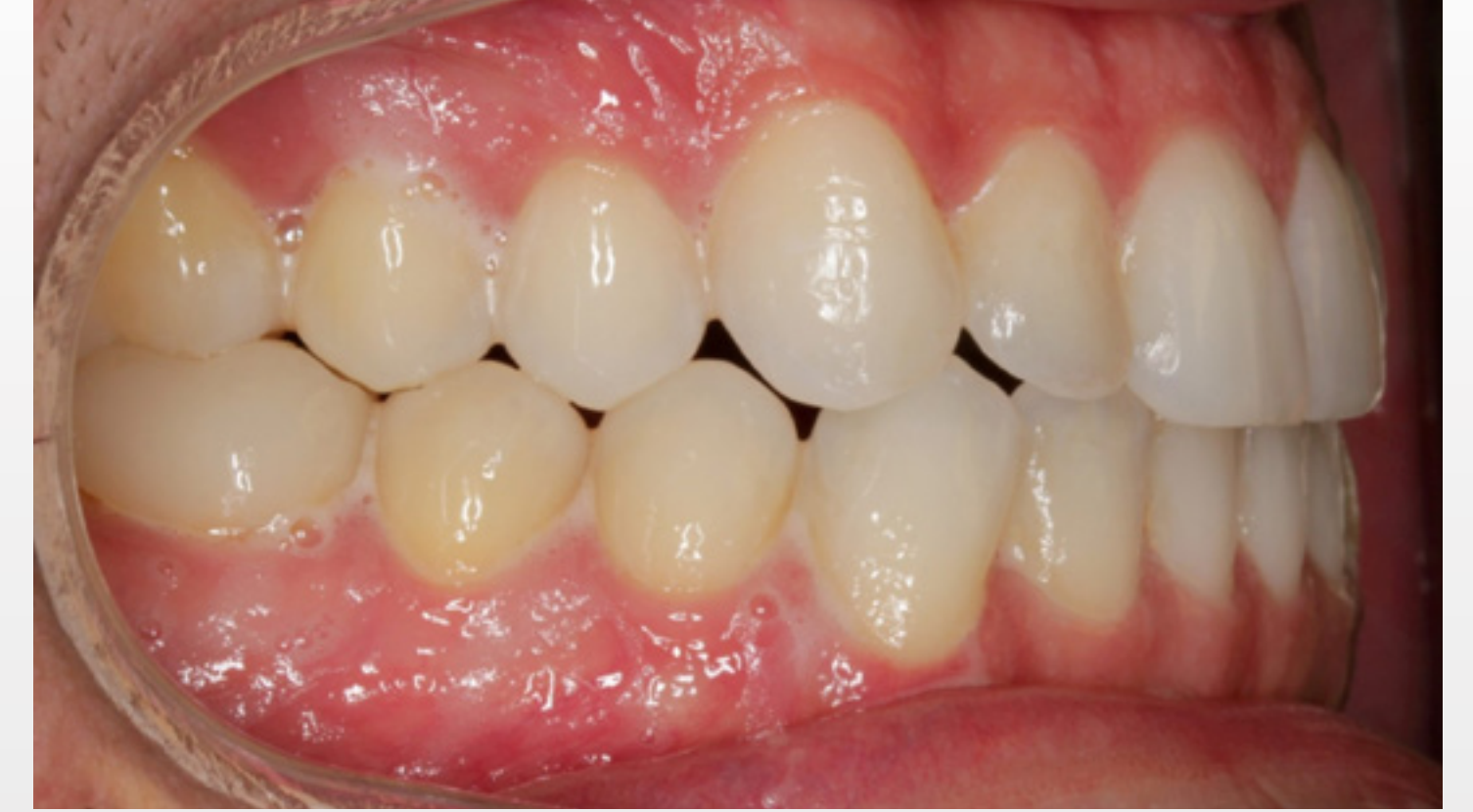
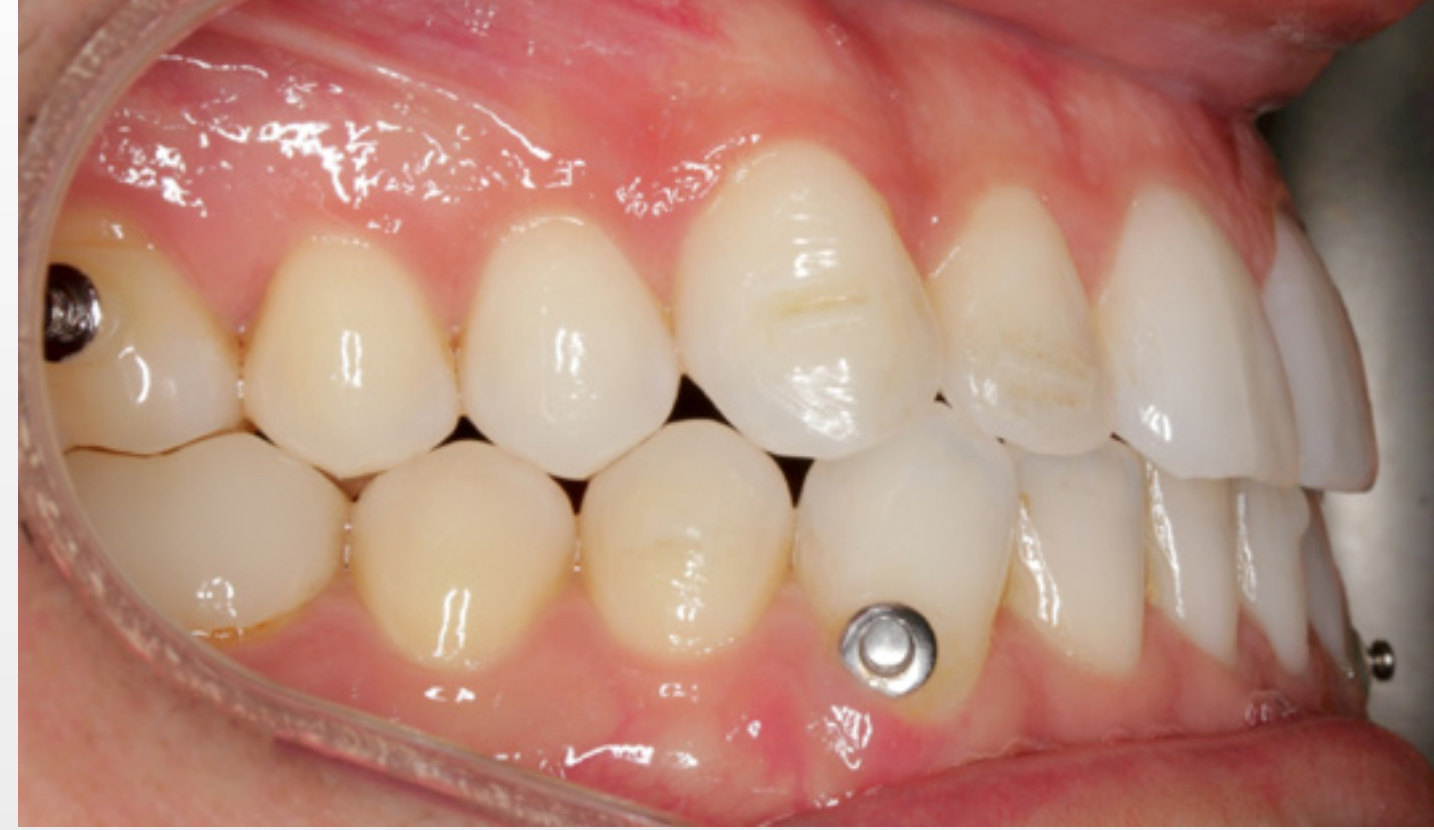
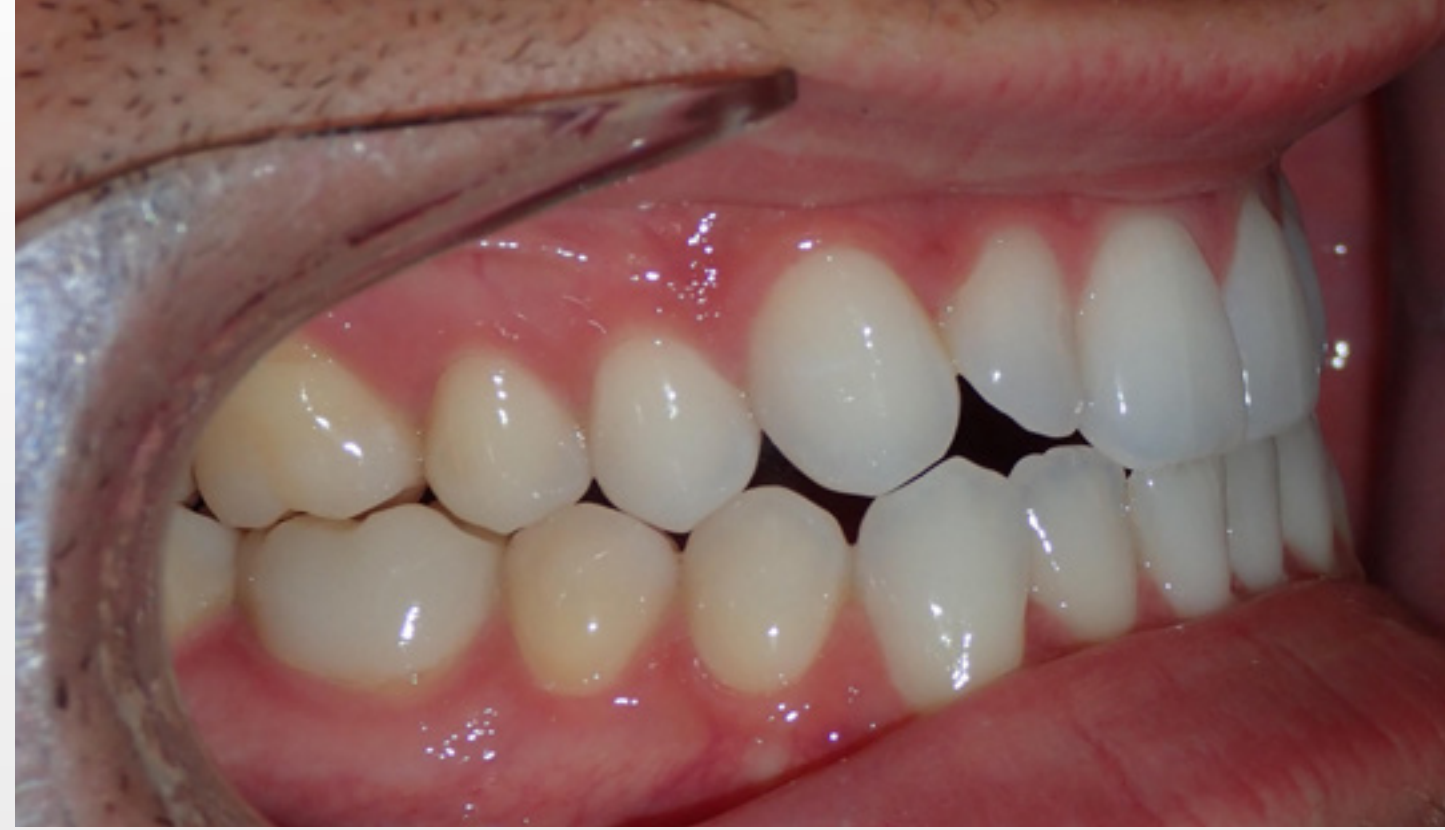**Initial**

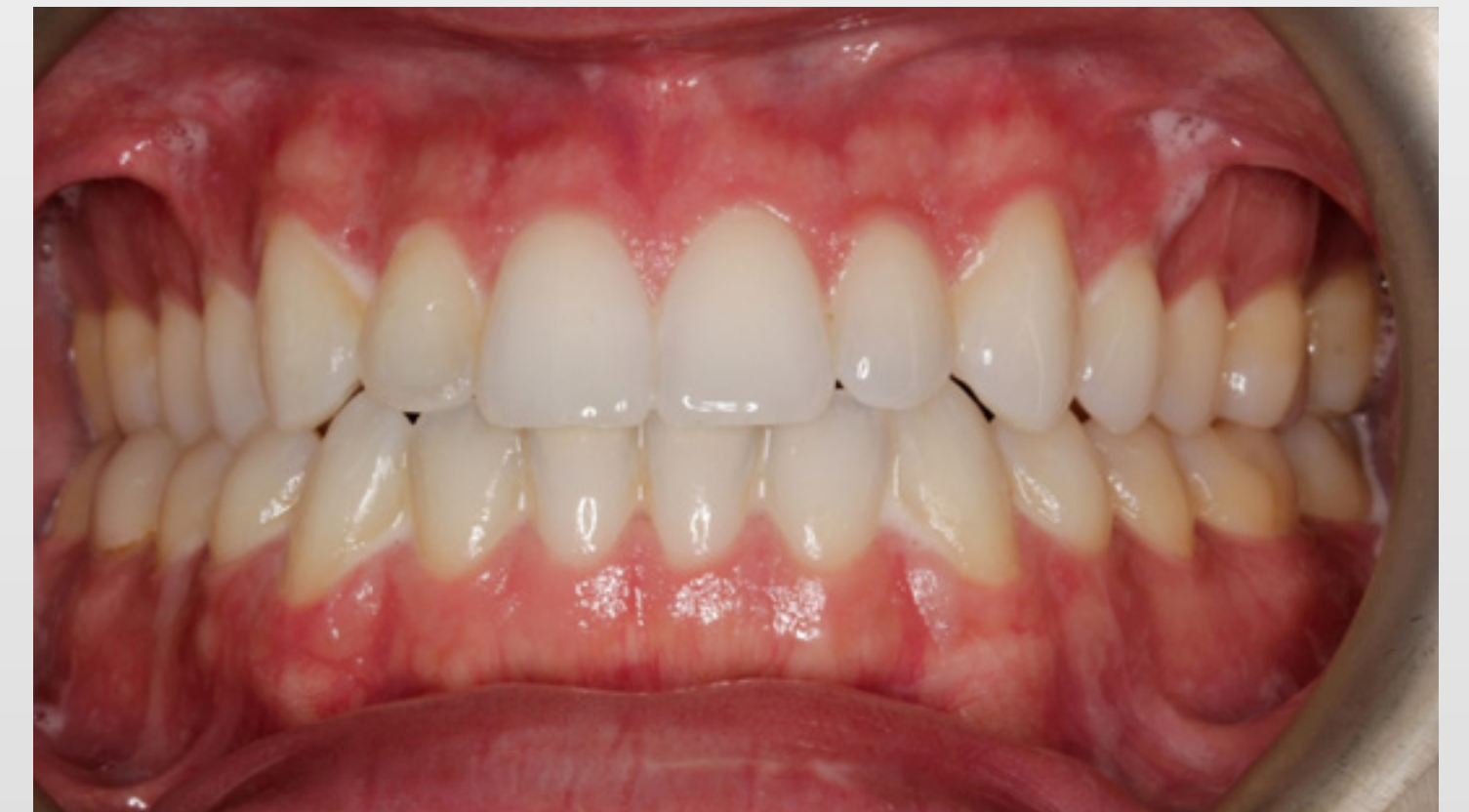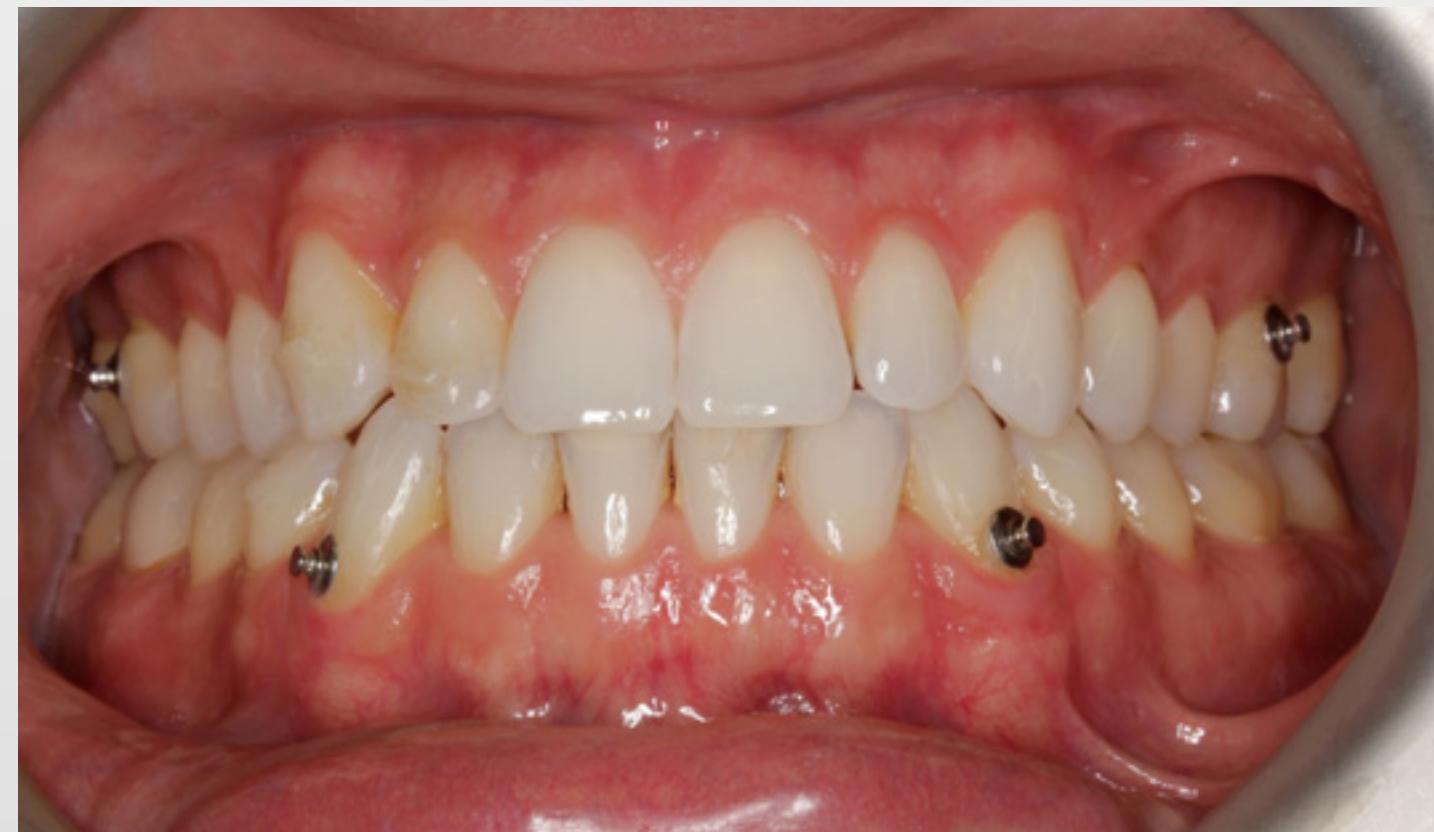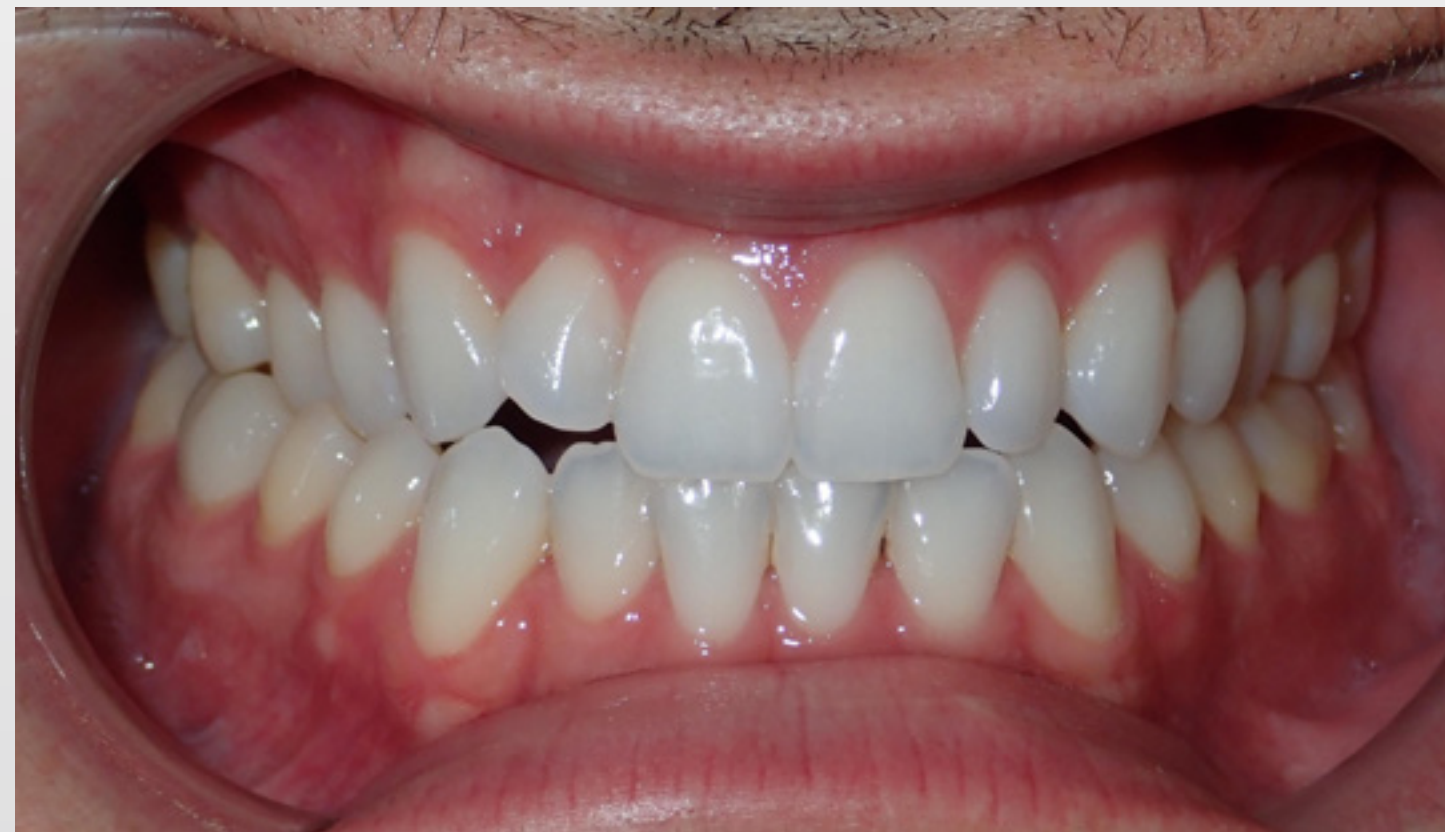**Progress - 1 year, 7 months**

**Final**

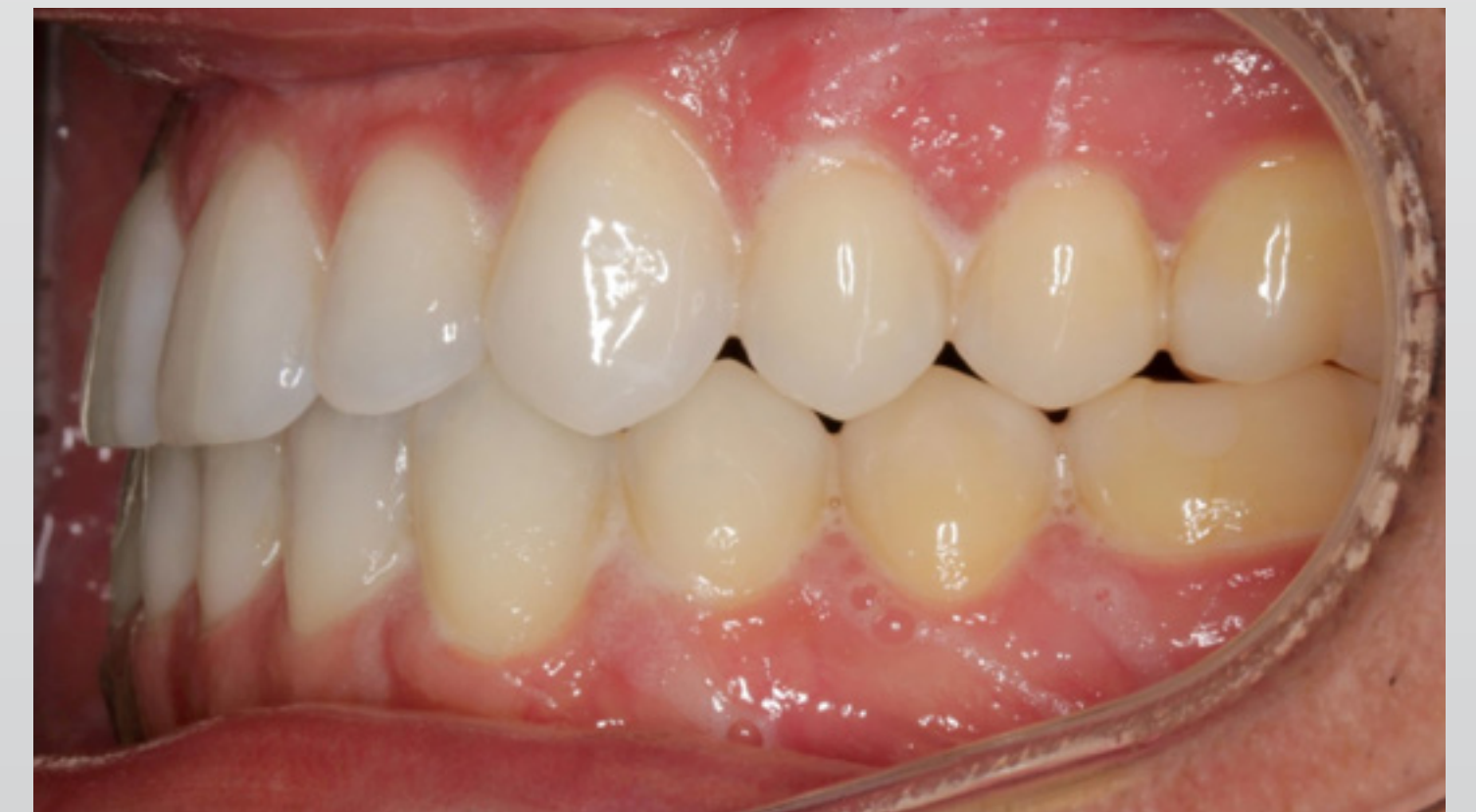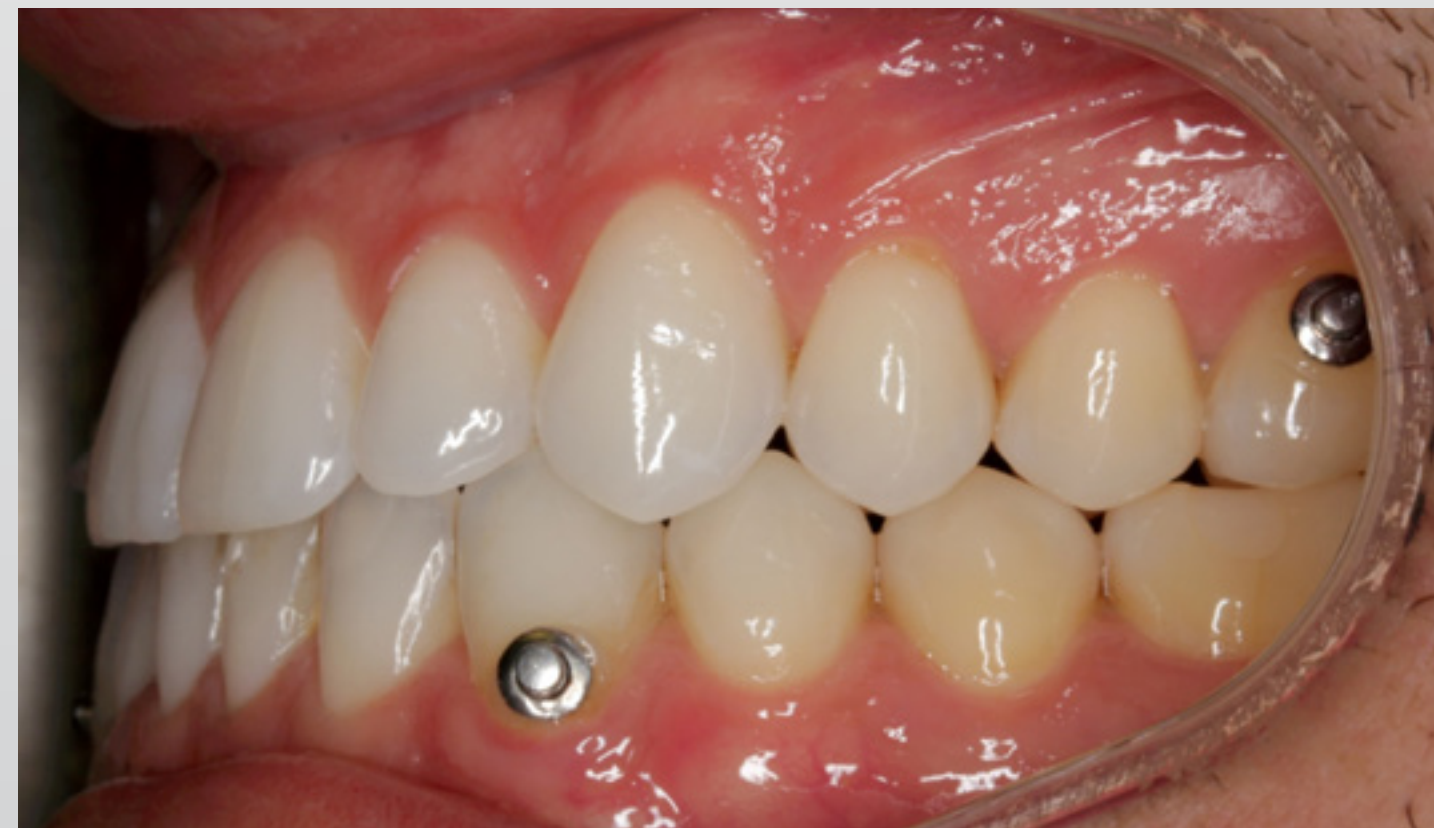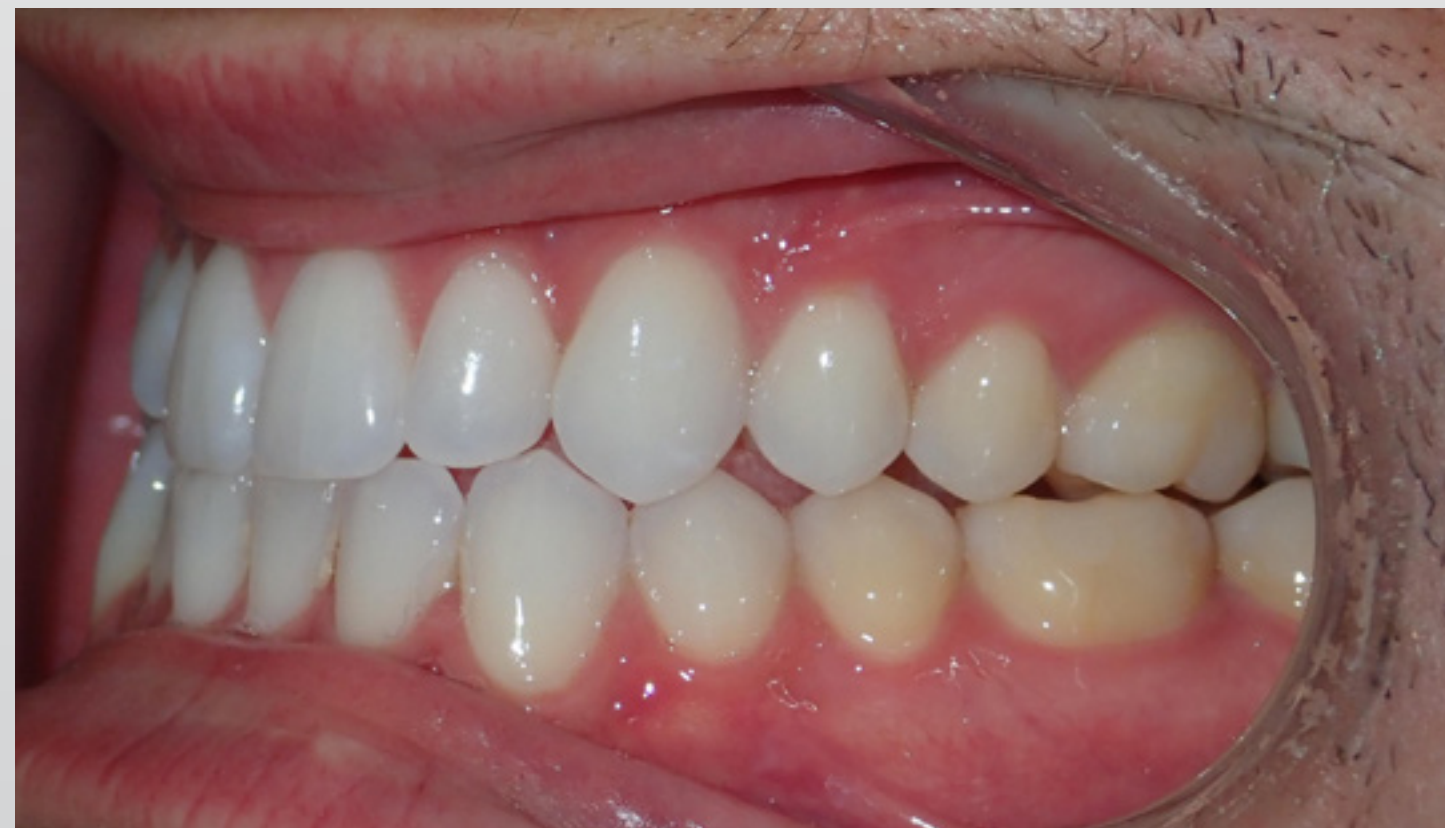**Retracted  
buccal – right**



**Retracted  
anterior  
biting**



**Retracted  
buccal – left**

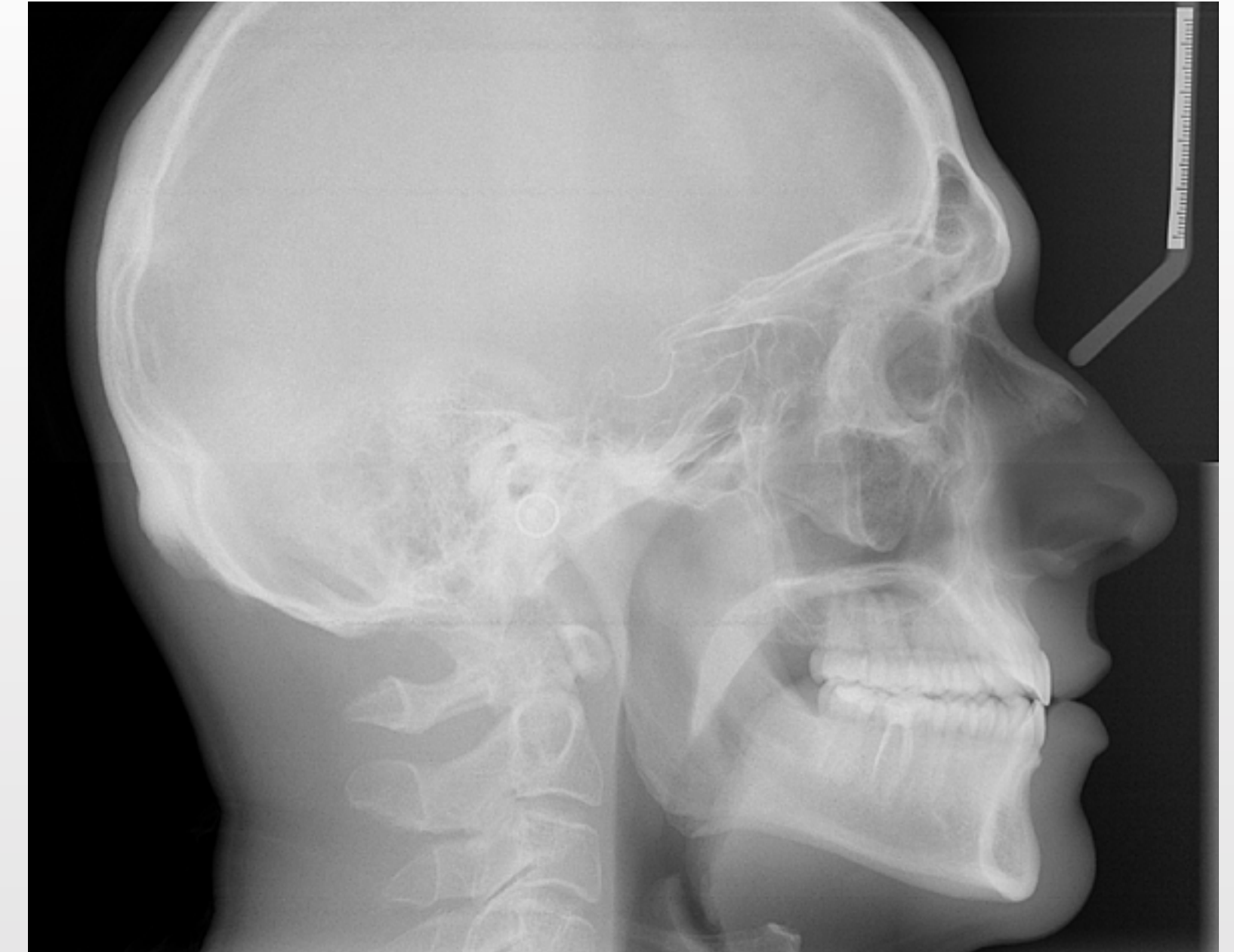
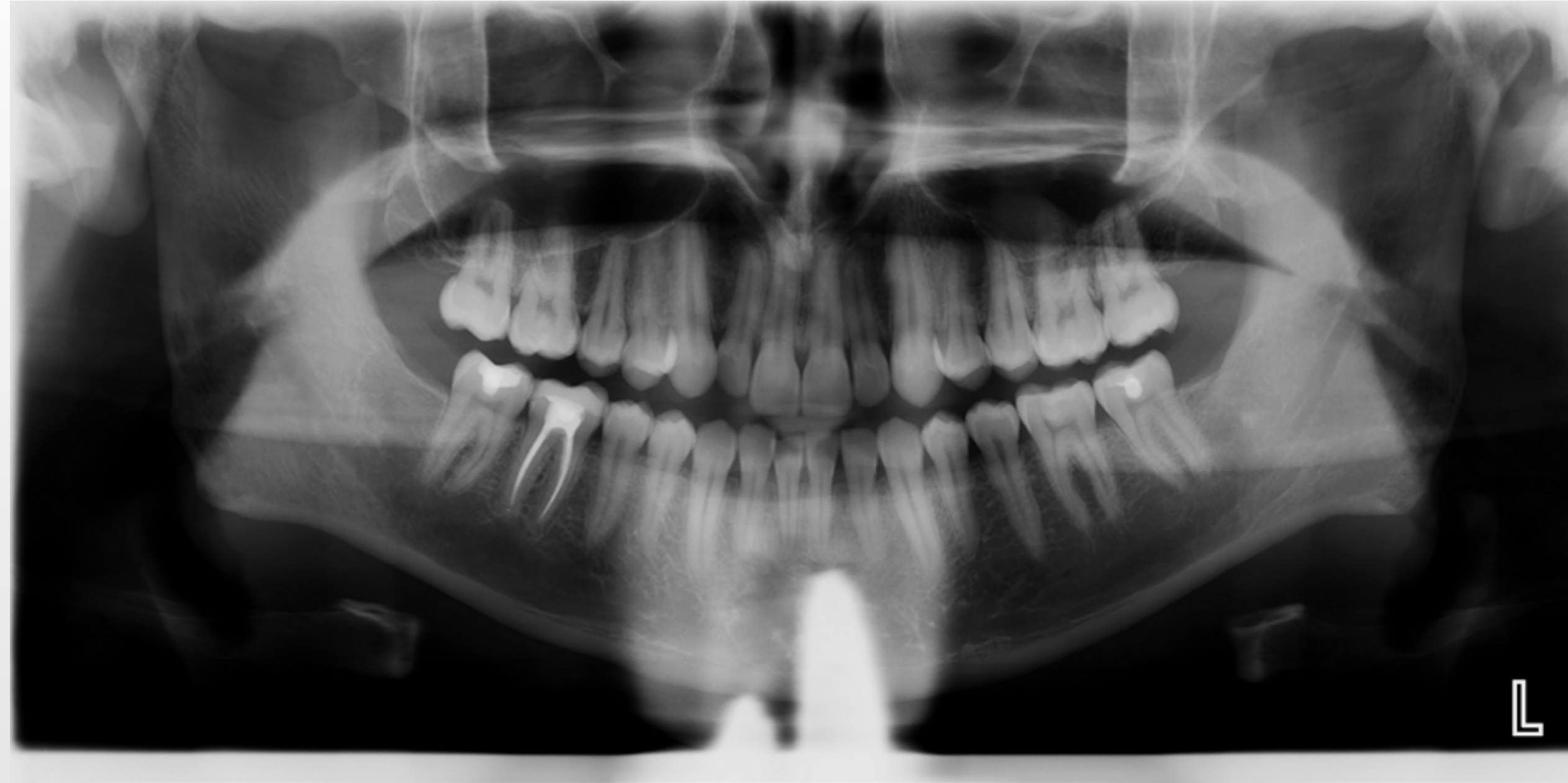



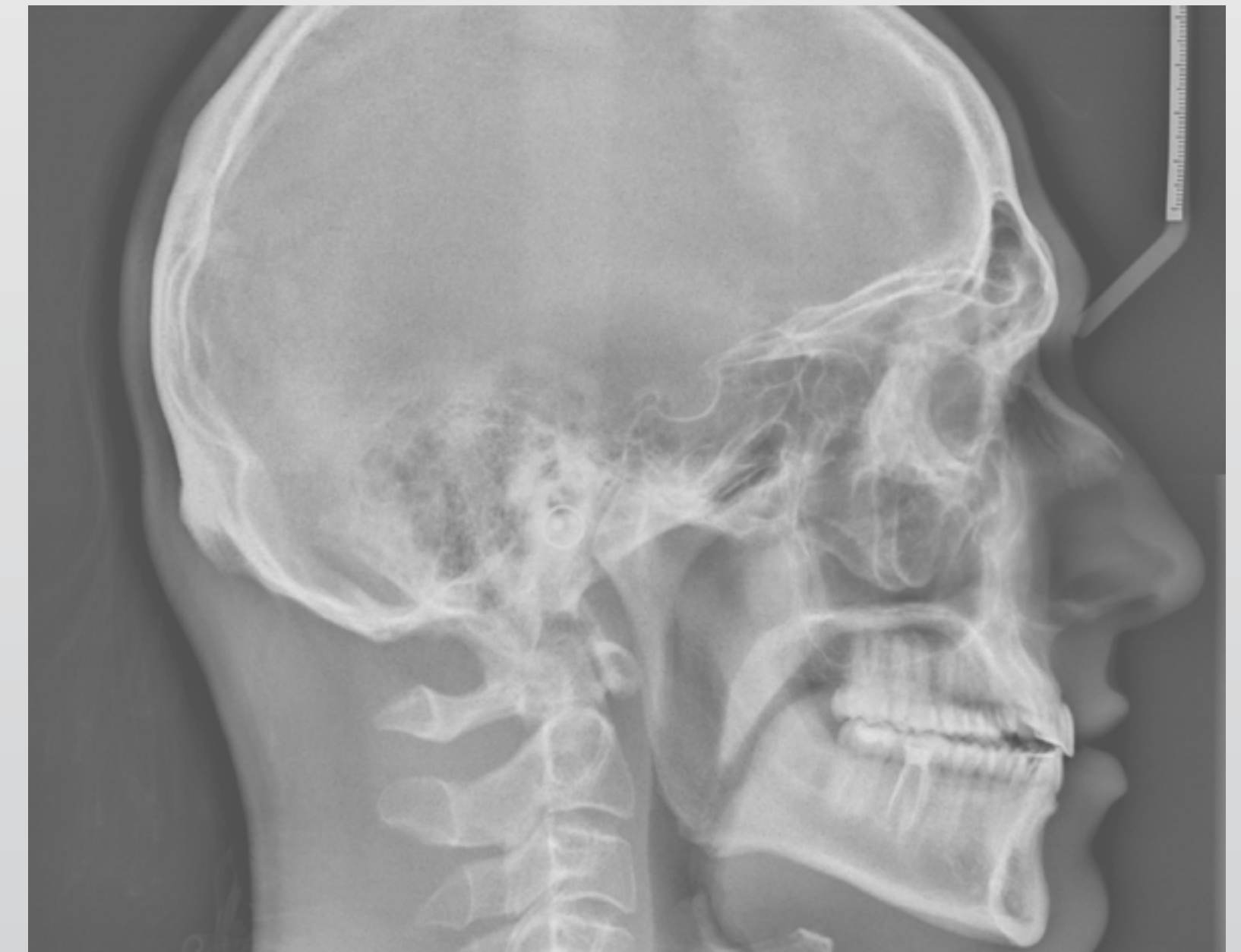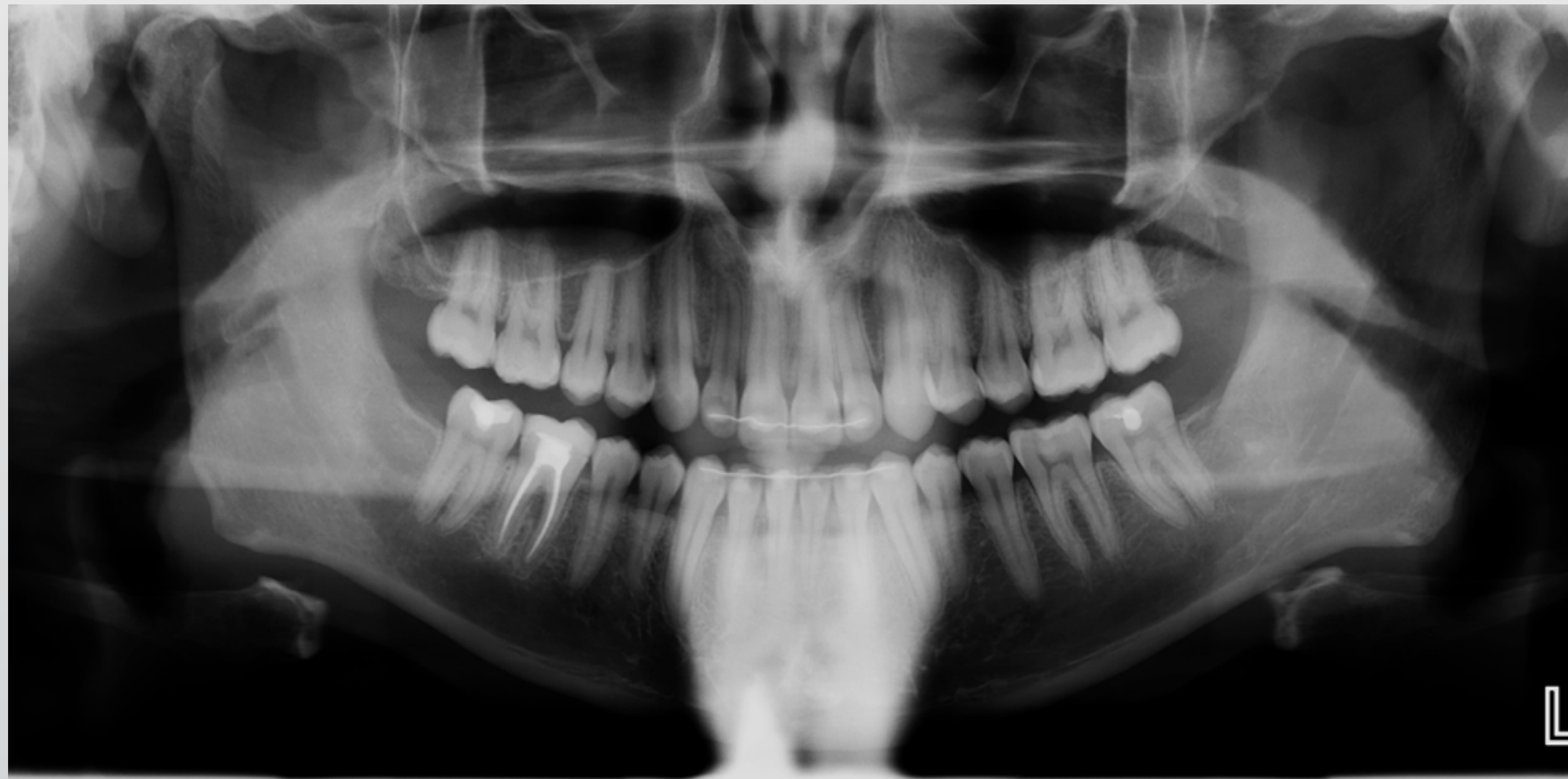Panoramic radiograph

Ceph.

Initial



Final



**Tx Design Video**

- Treatment Plan
- Attachment Strategy
- Key Movements
- Summary of Final Results

Learn more at **3M.com/ClarityCasesAU**  
and **3M.com/ClarityCasesNZ**