

Case Study: 3M<sup>TM</sup> Clarity<sup>TM</sup> Aligners

Correction of severe anterior spacing and flaring, tipped central incisors and missing upper left 3 with posterior constriction.

Age: 32

Original malocclusion: Class I right and Class II left

Total number of aligners: 30 (dual arch)

Wear interval: Weekly

Treatment time: 8 months

IPR: Total IPR Upper Arch = 0.4 mm  
Total IPR Lower Arch = 1.5 mm

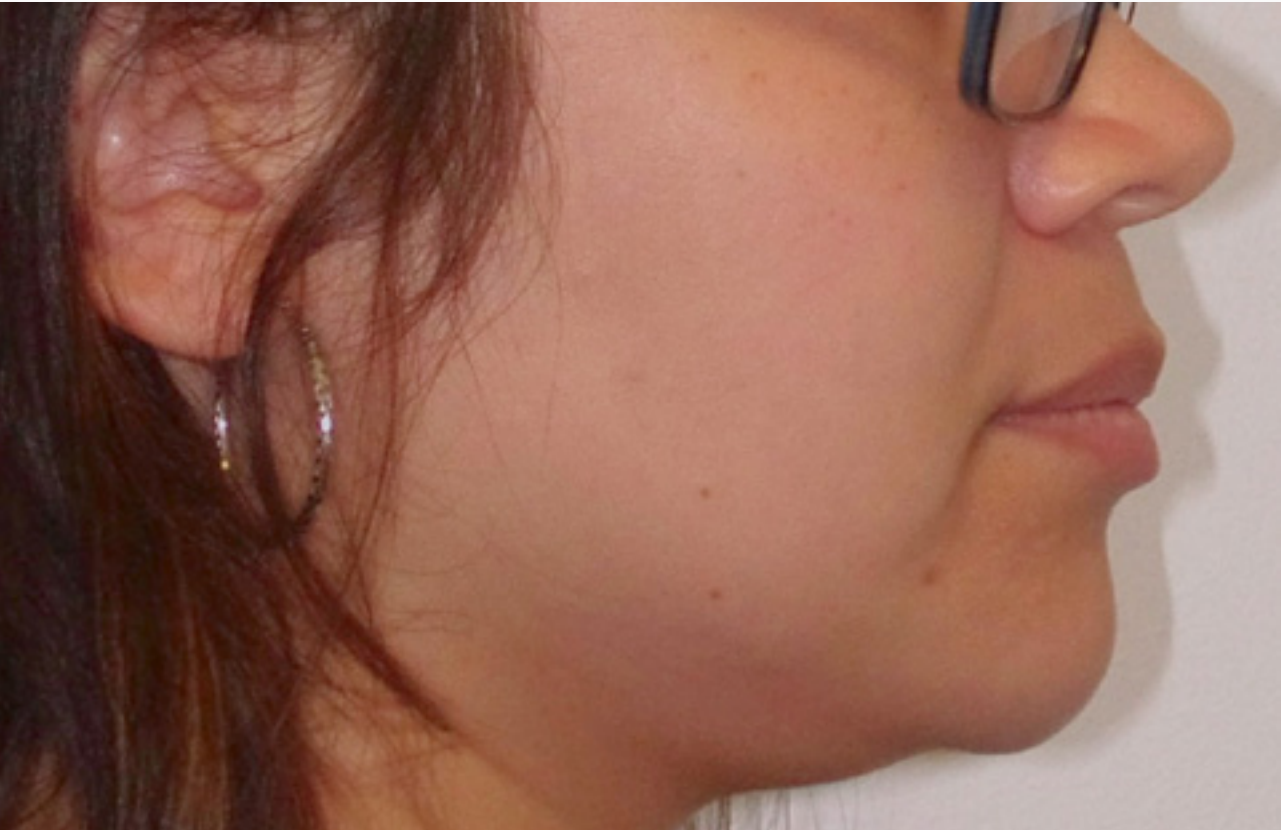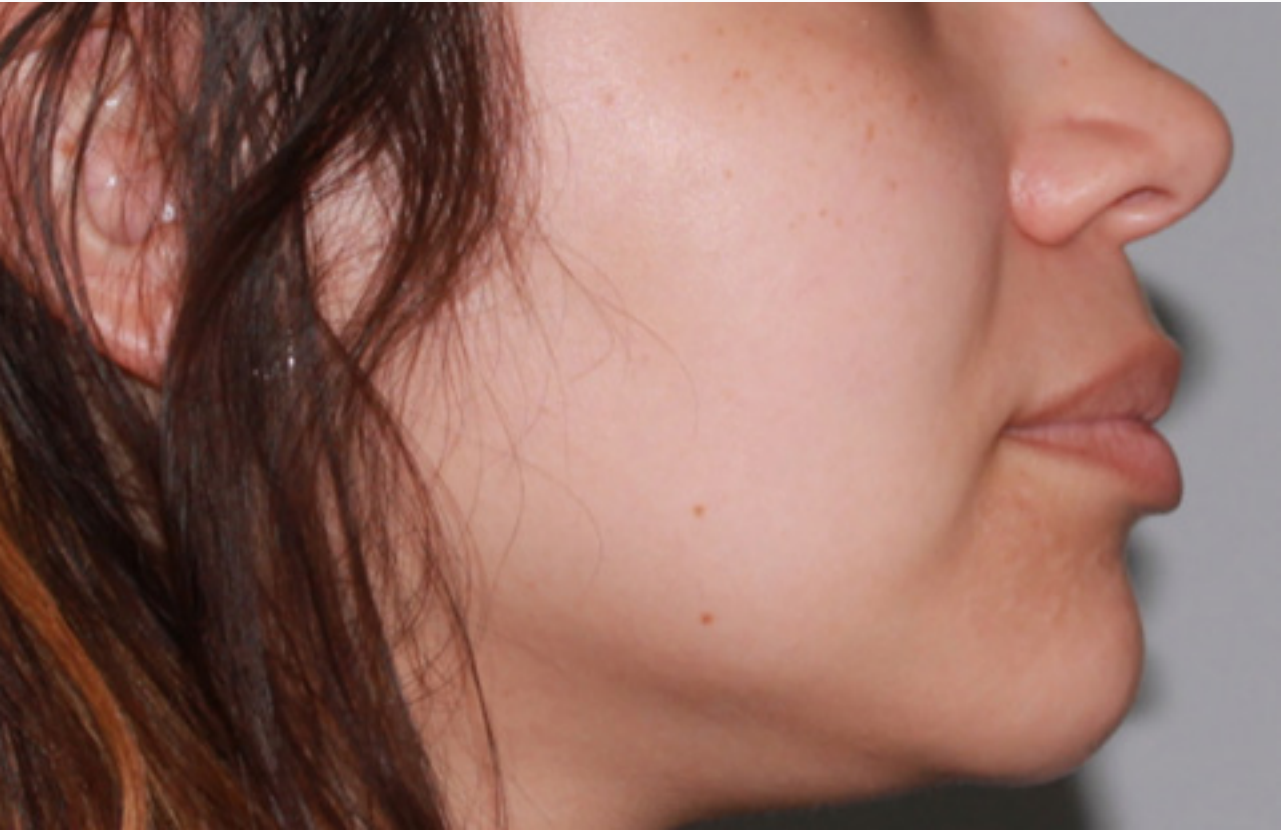By Stage	Entire Case		Total IPR Upper Arch = 0.4mm					Total IPR Lower Arch = 1.5mm									
	R8	R7	R6	R5	R4	R3	R2	R1	L1	L2	L3	L4	L5	L6	L7	L8	
Upper Arch								.4									
Lower Arch					.3	.5	.5	.2									

Case courtesy of:  
Dr. Adam Schuhof  
Oradell, NJ – USA

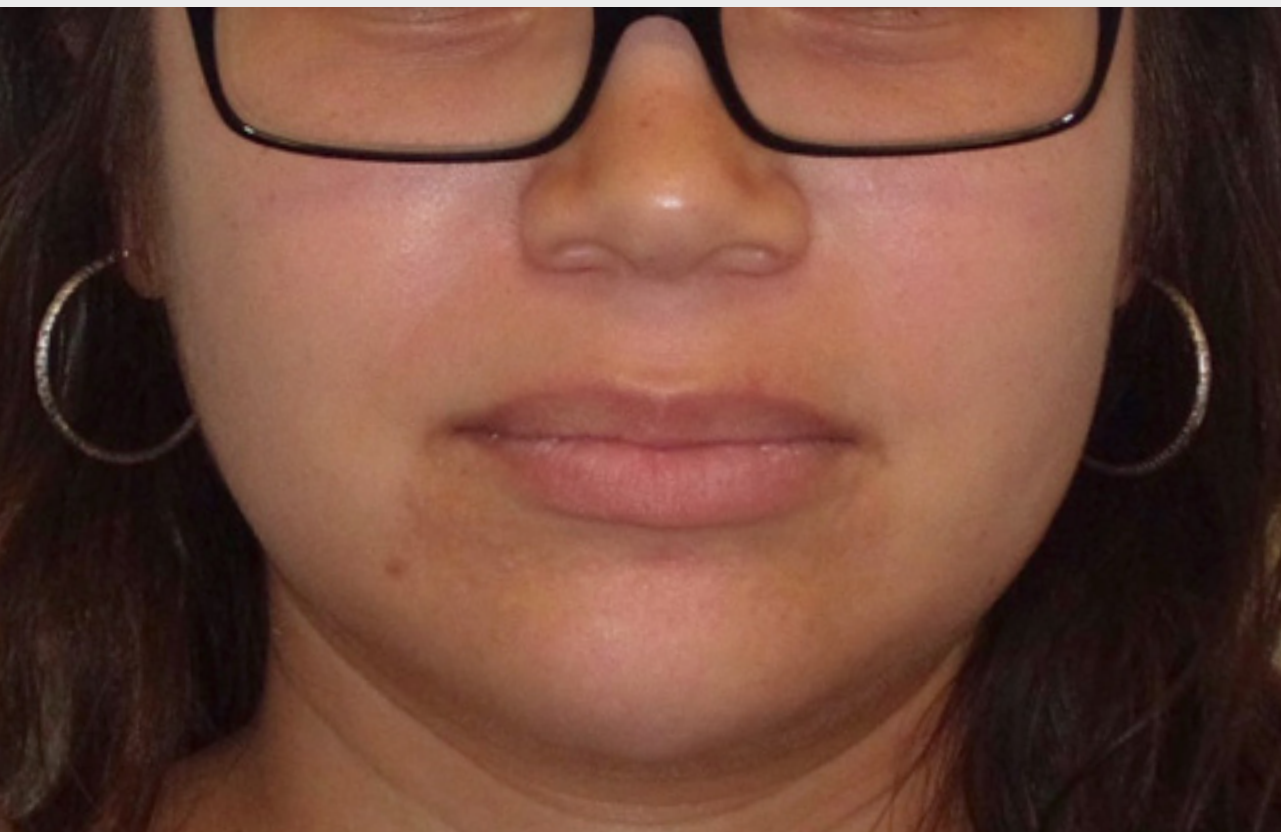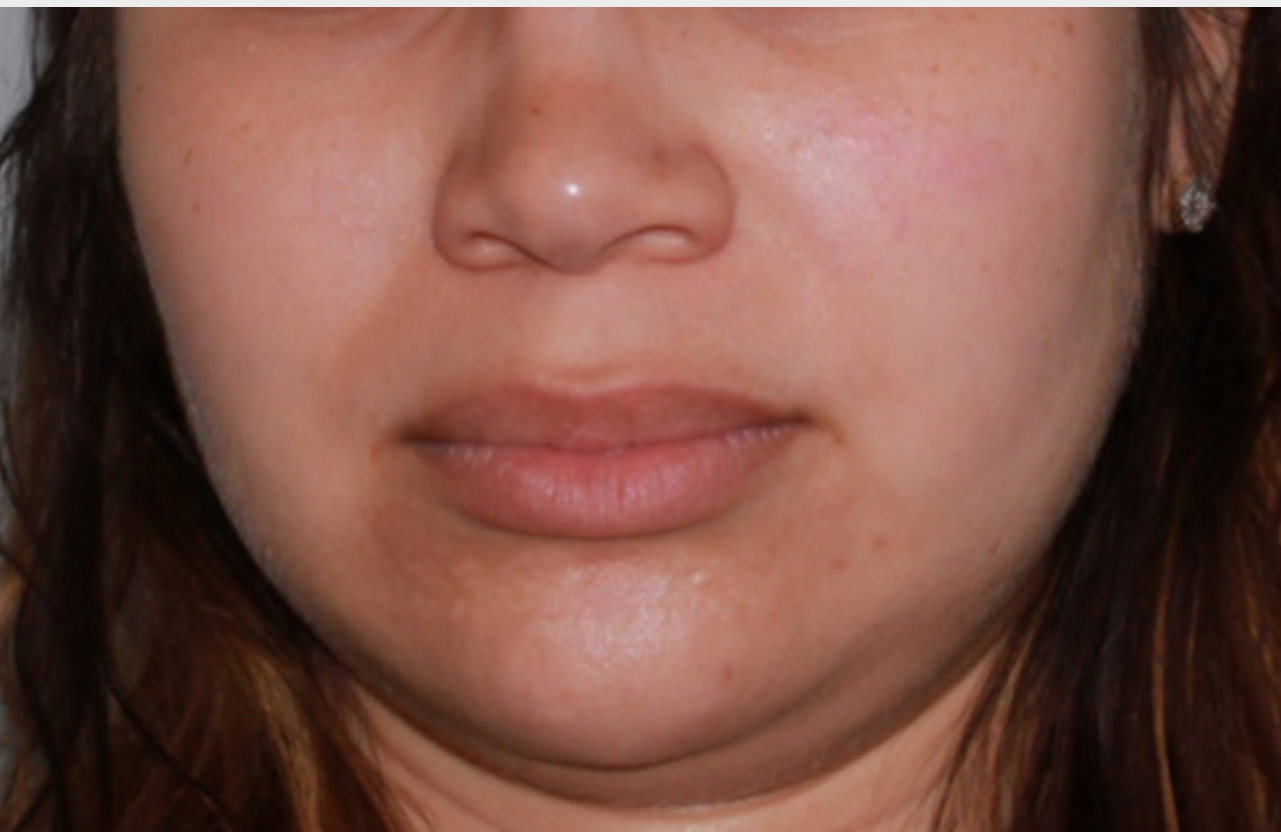Initial

Final

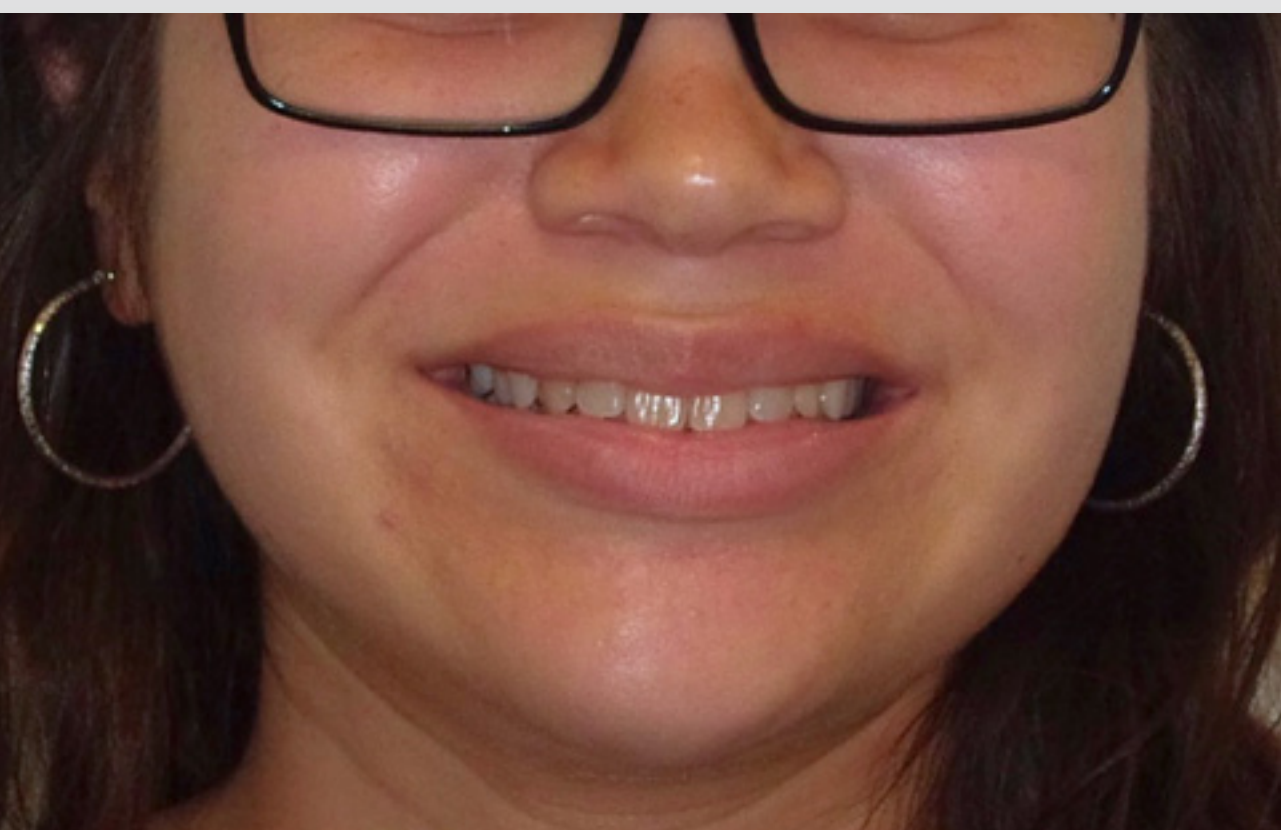
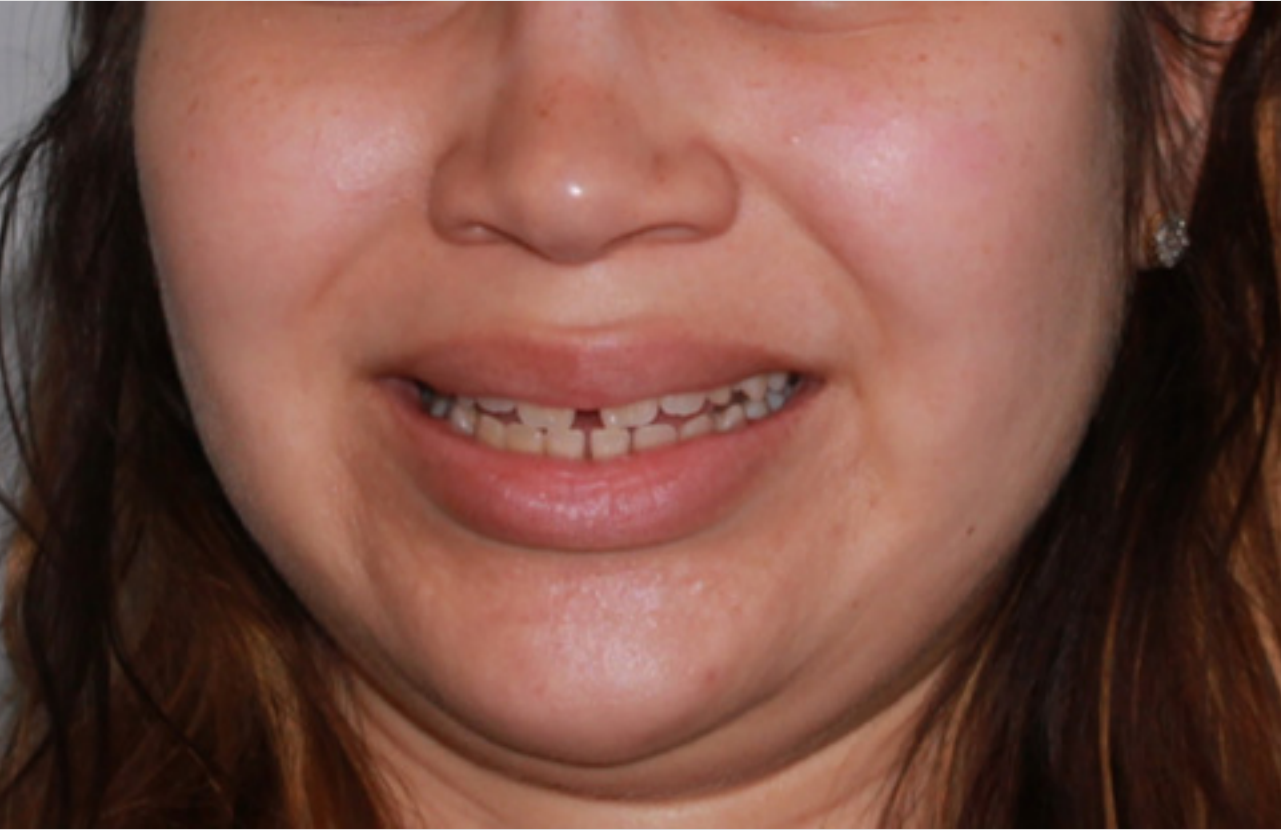Profile at rest



Face at rest



Face smiling

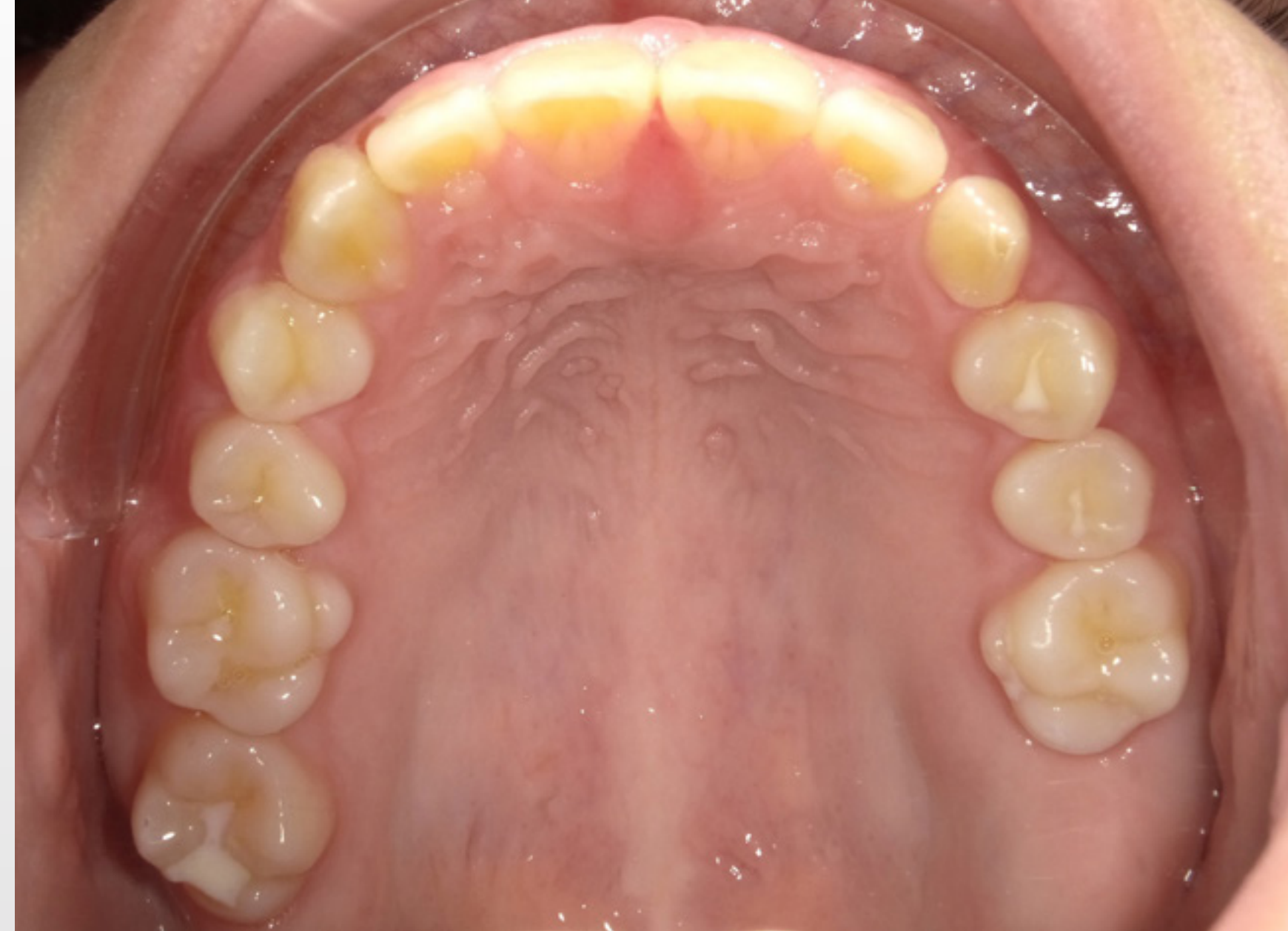
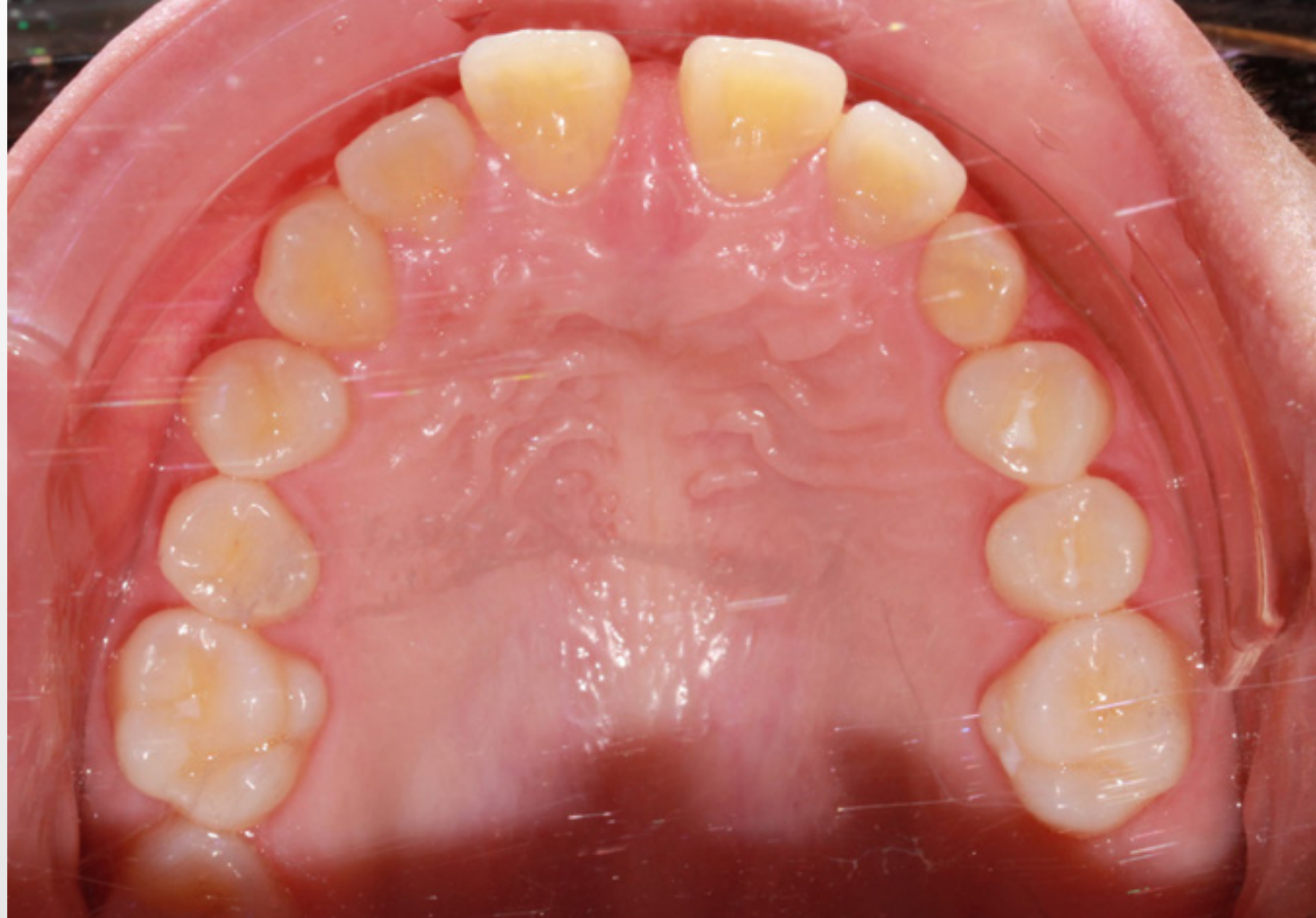


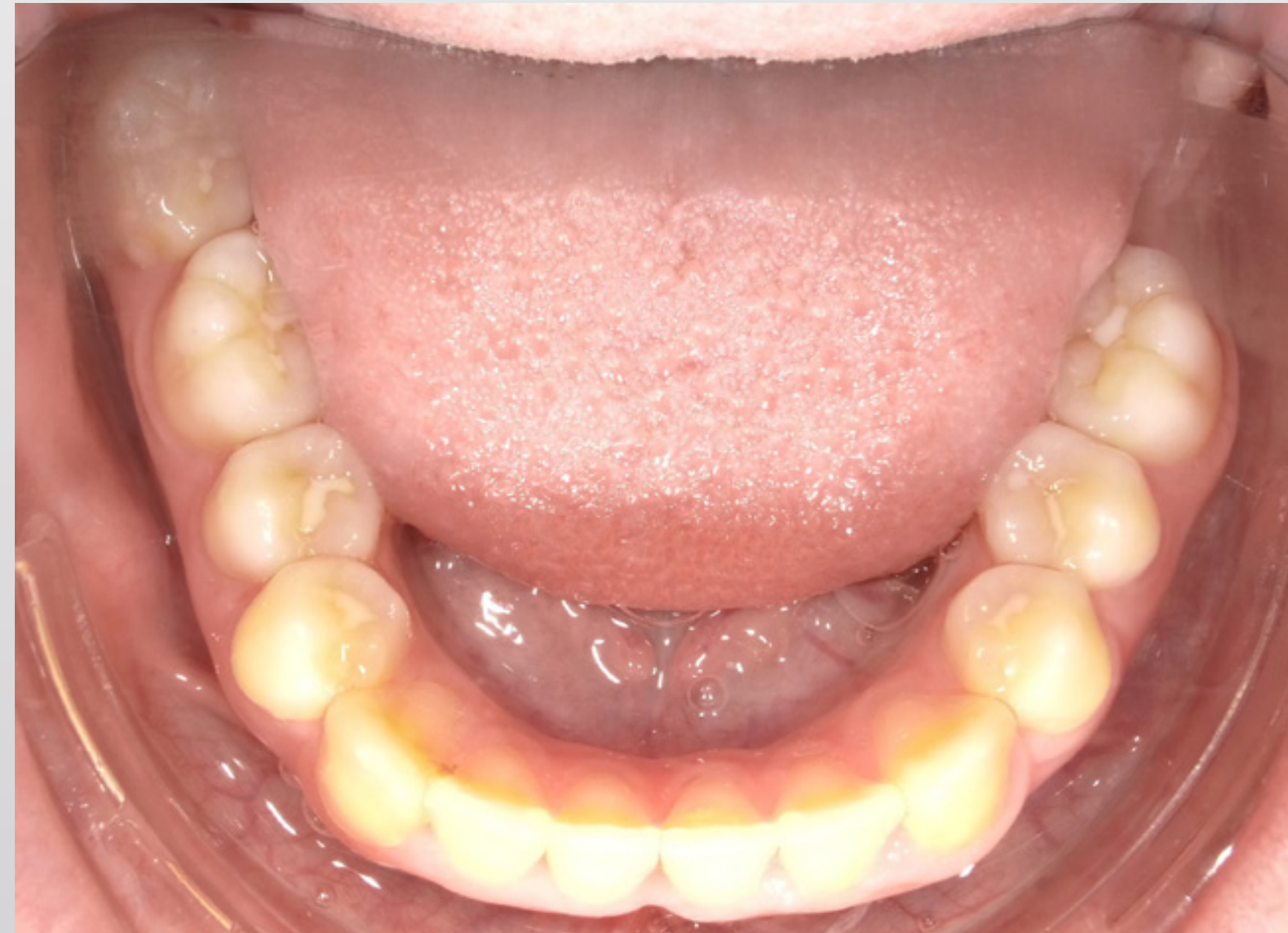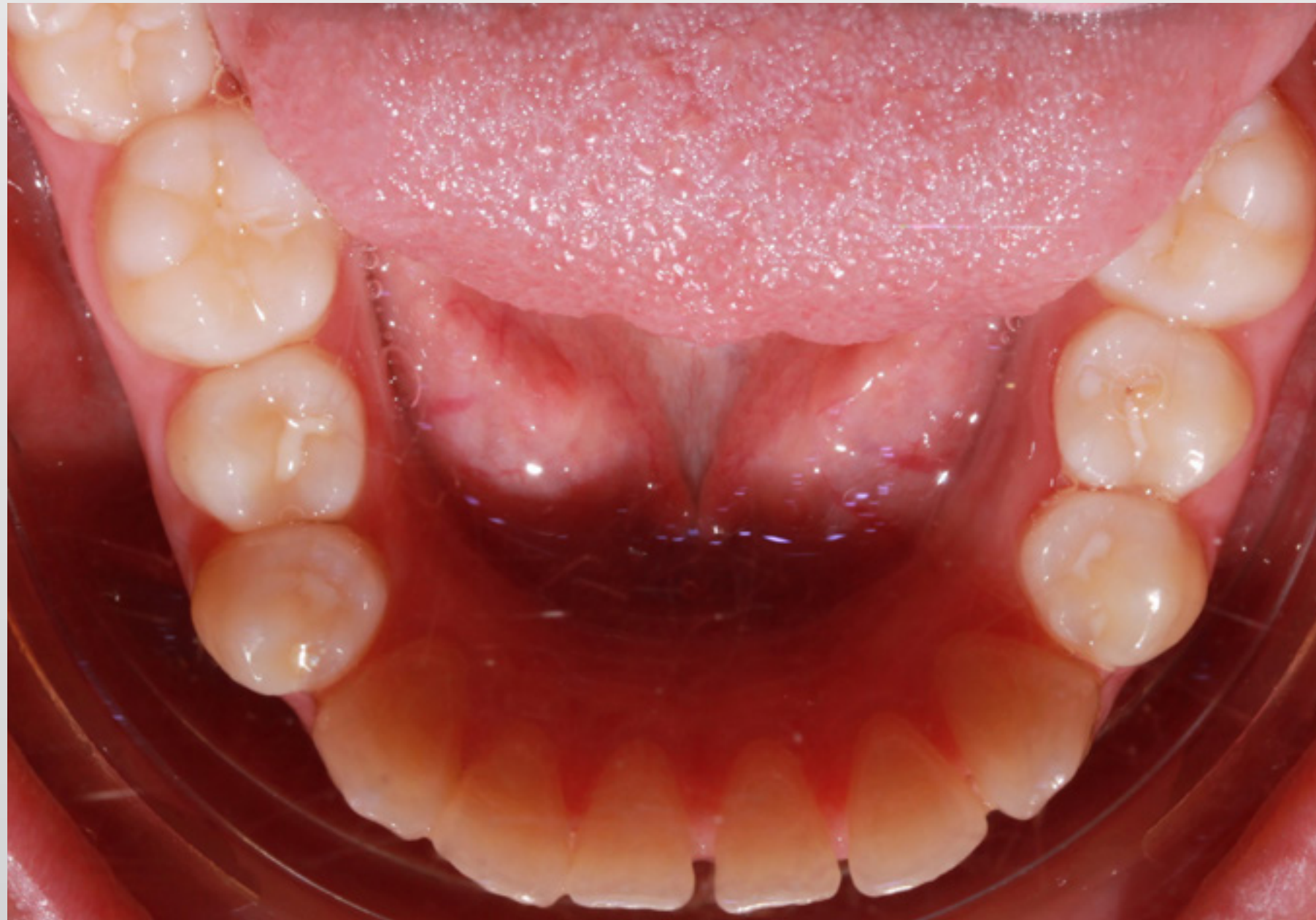**Initial**

**Final**

**Occlusal –  
maxillary**



**Occlusal –  
mandibular**

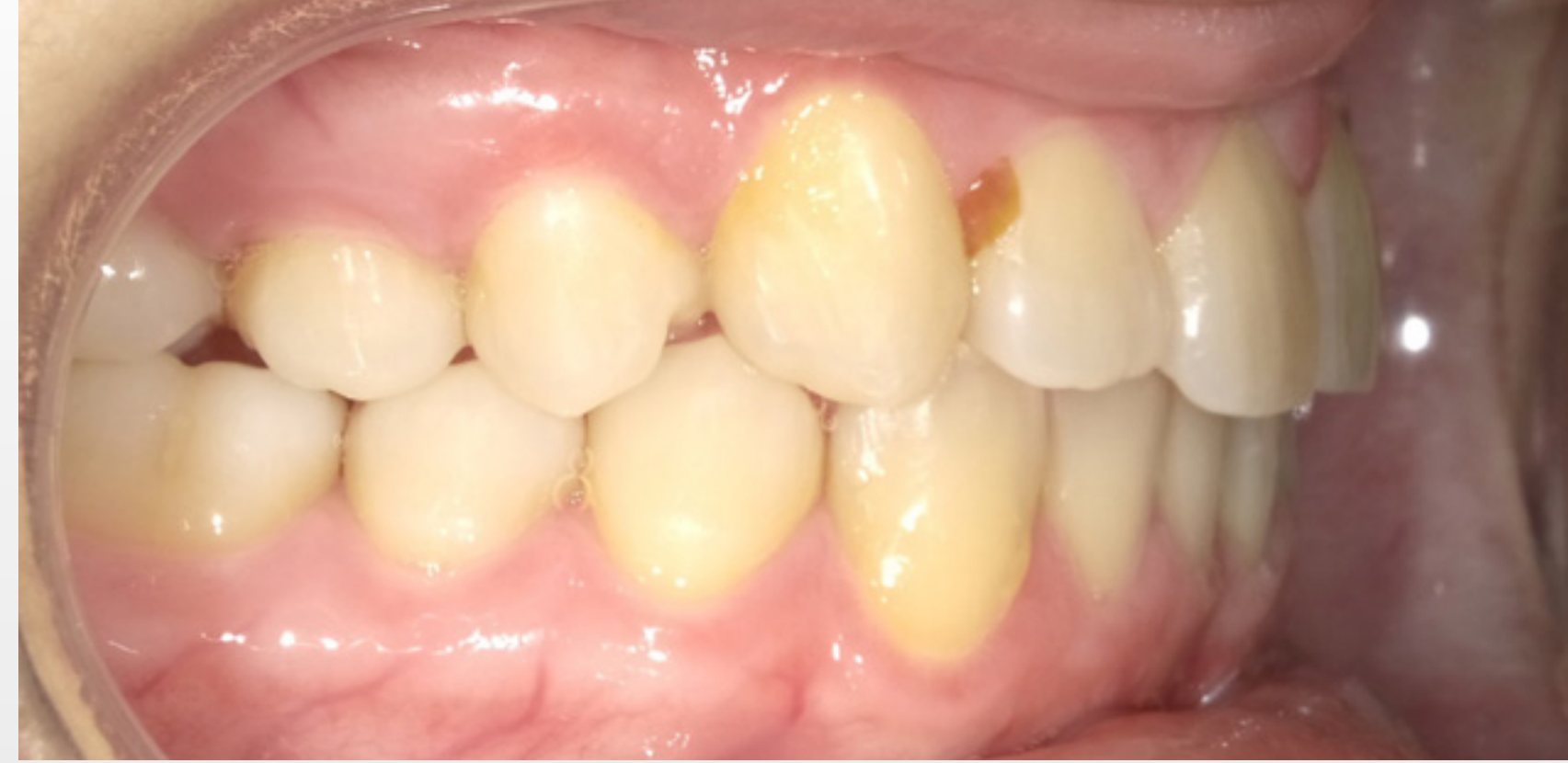
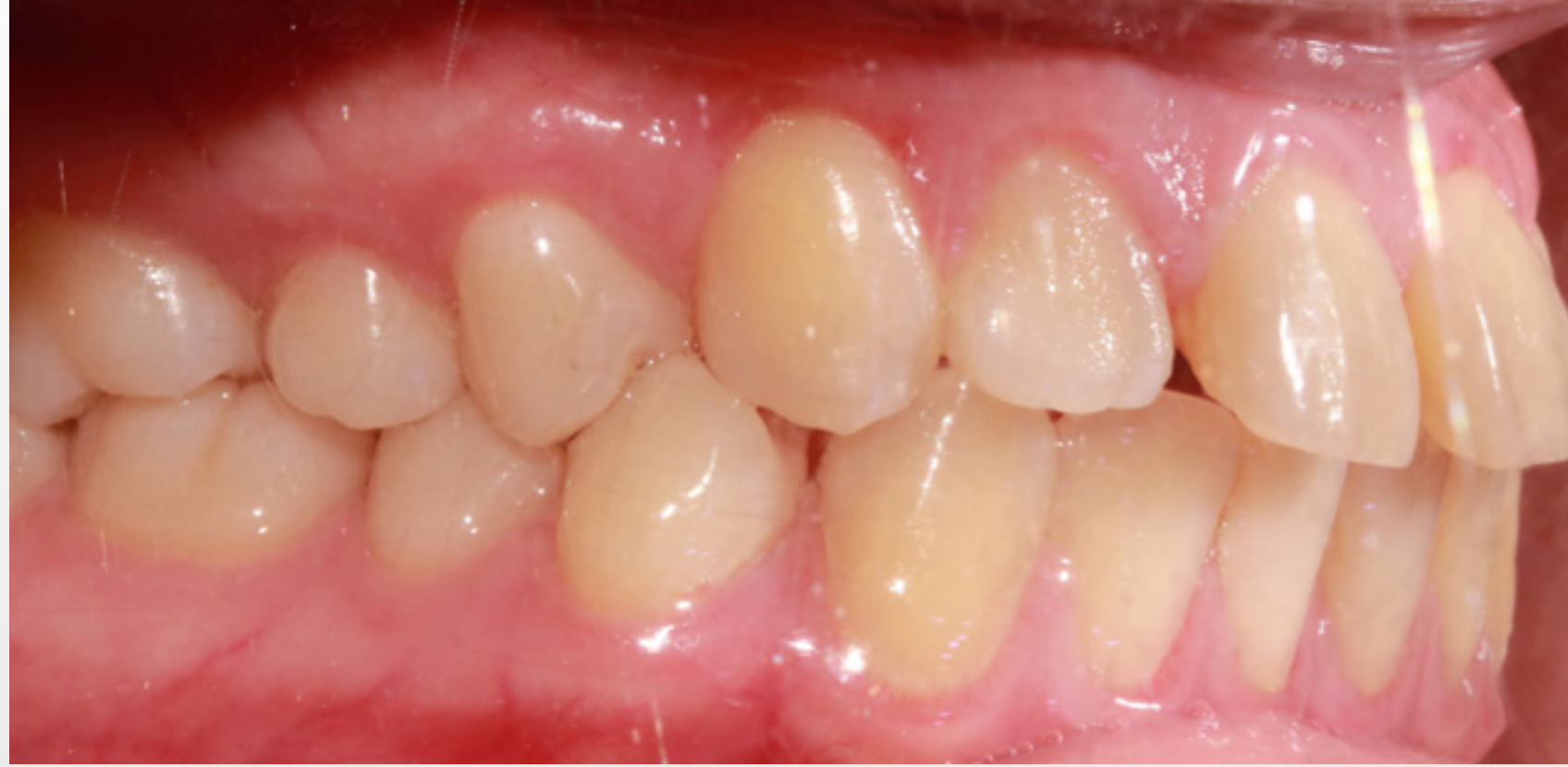


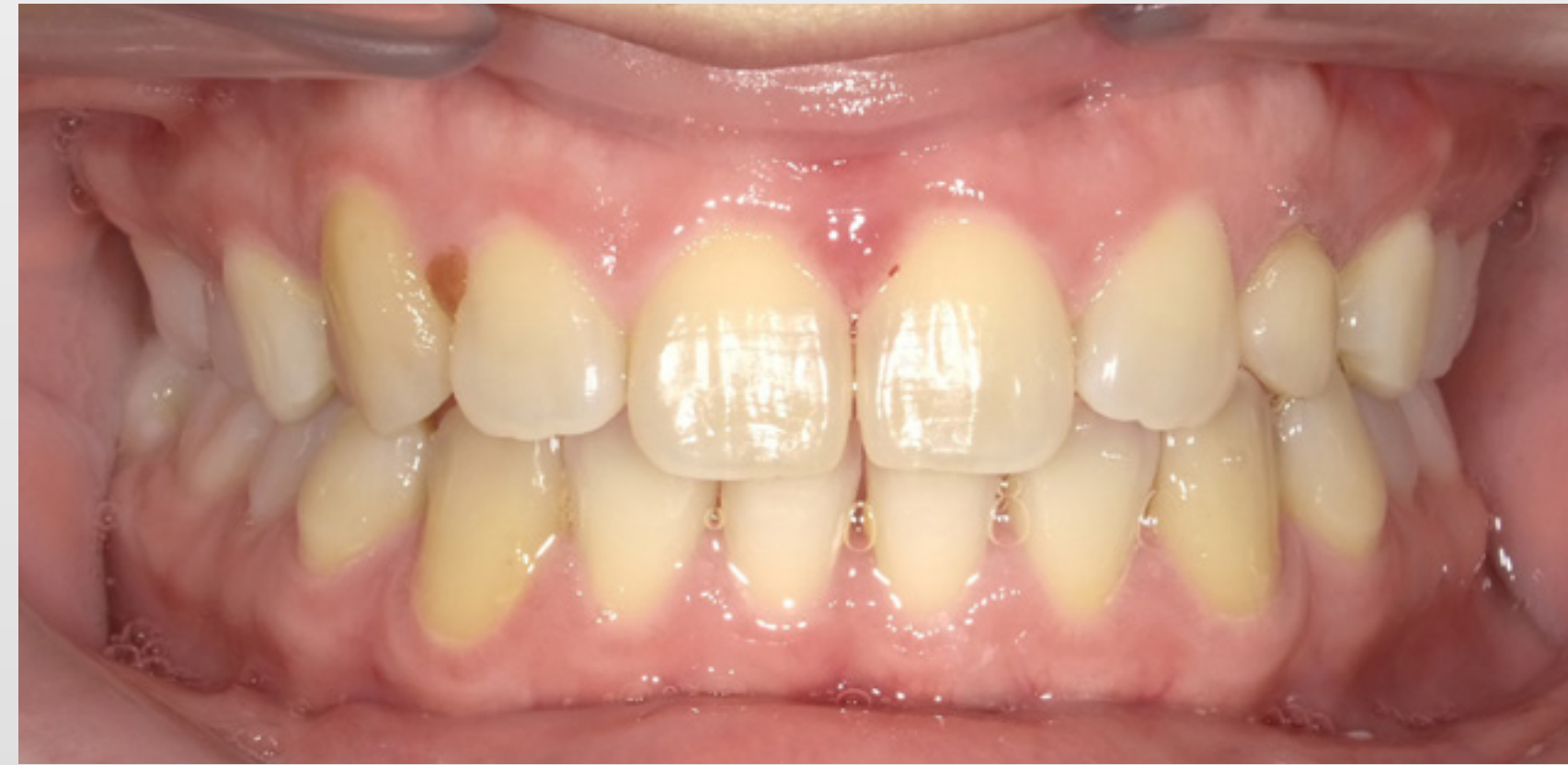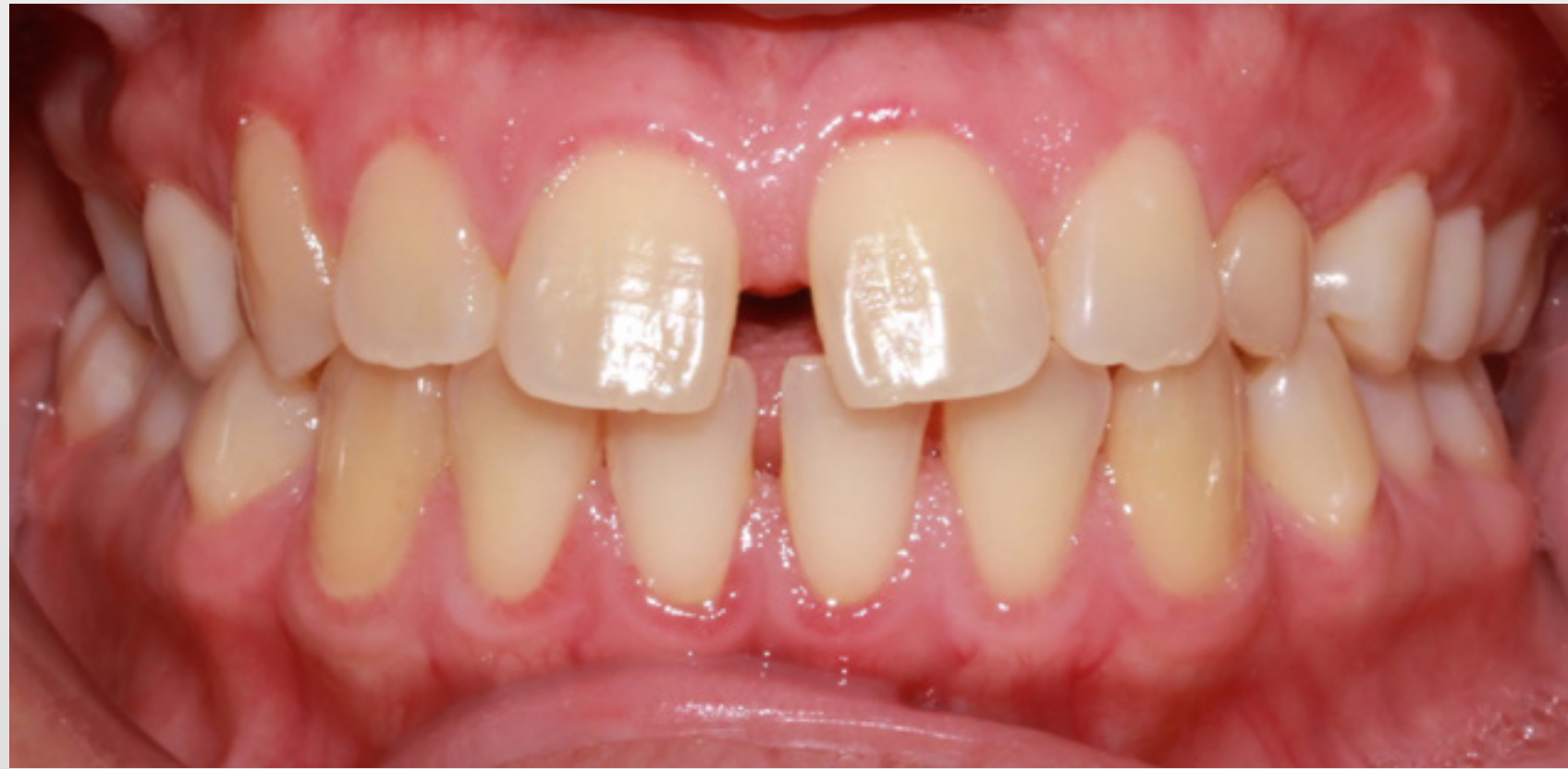**Initial**

**Final**

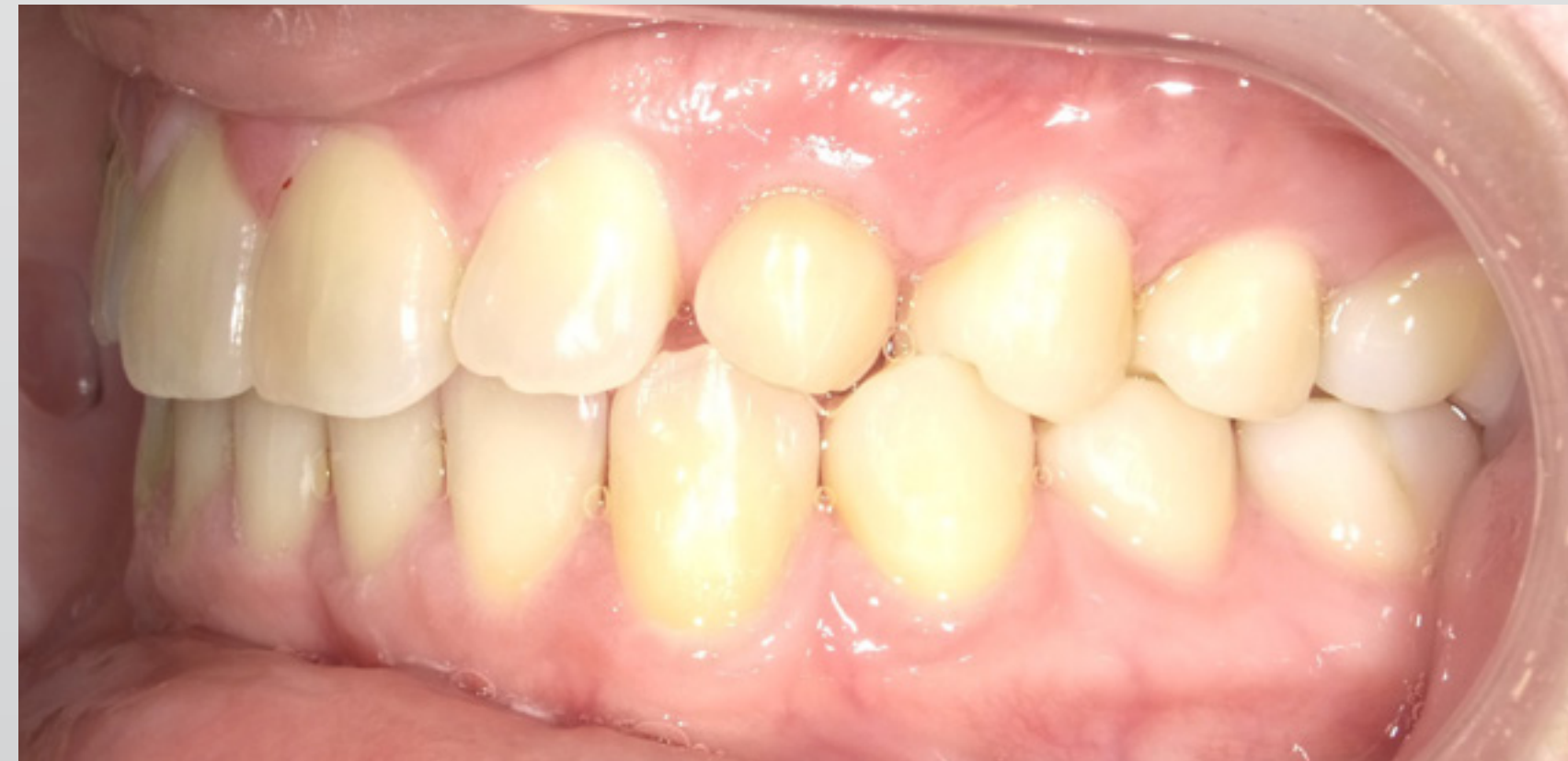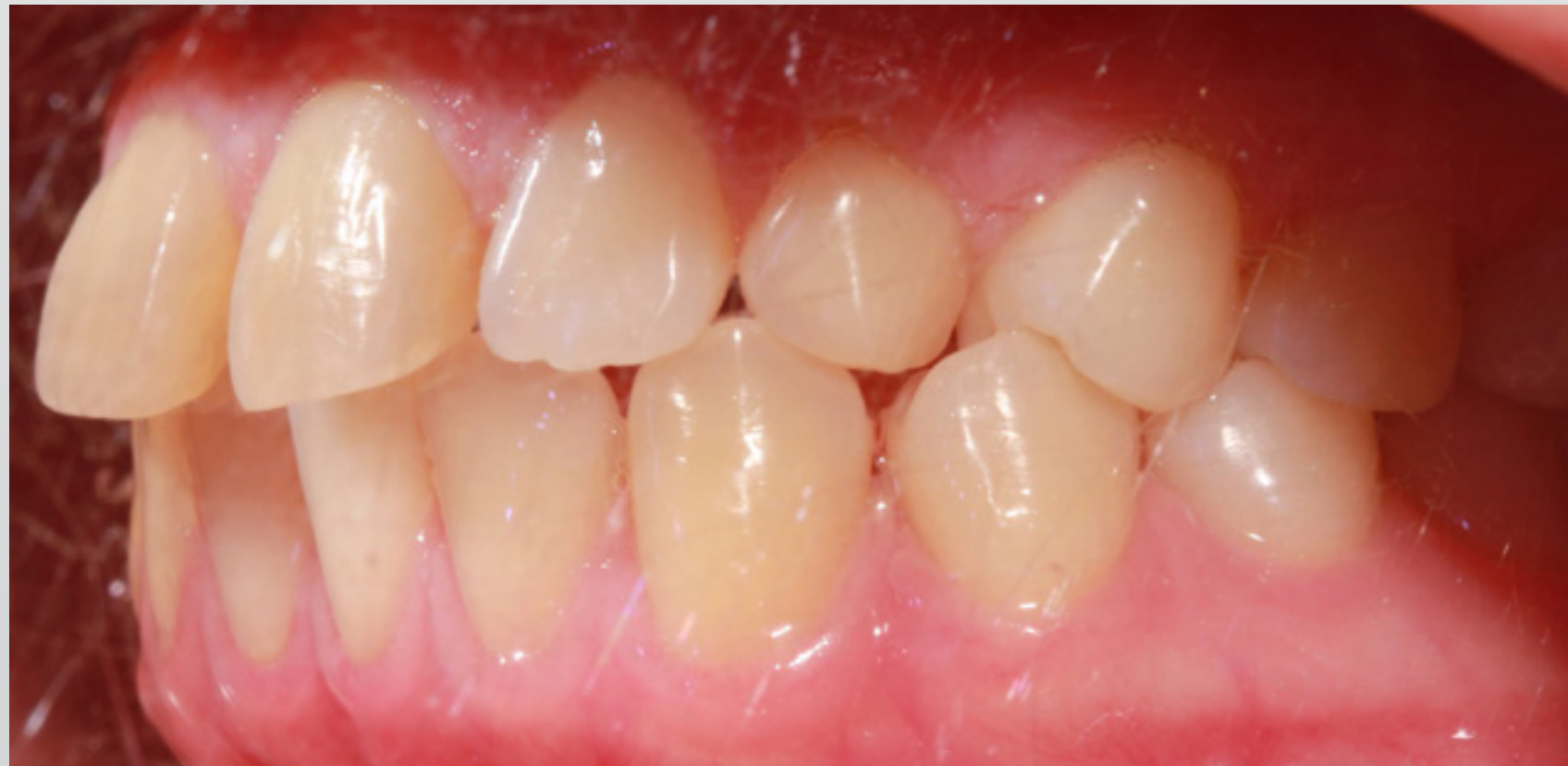**Retracted  
buccal – right**



**Retracted  
anterior biting**



**Retracted  
buccal – left**

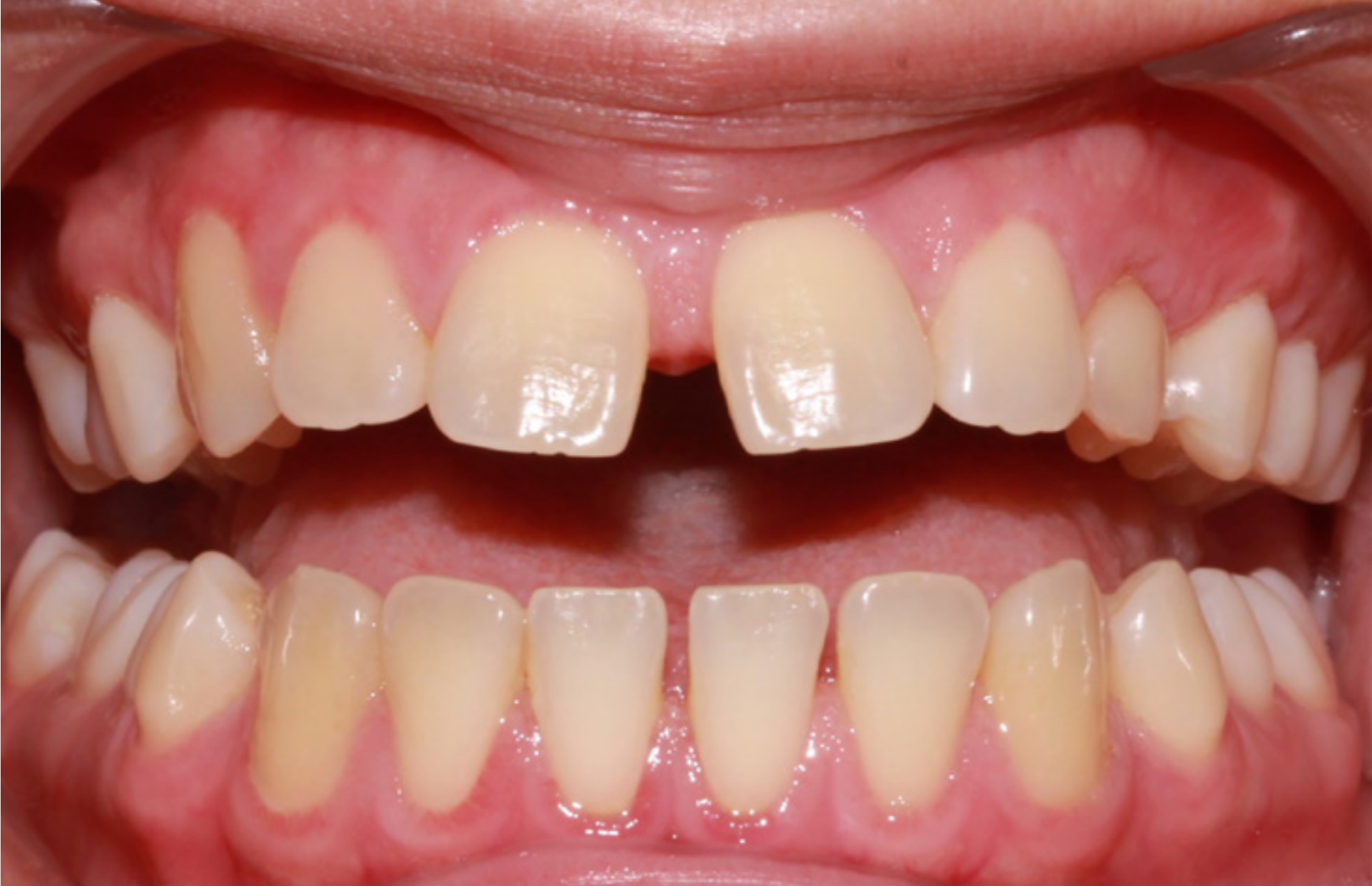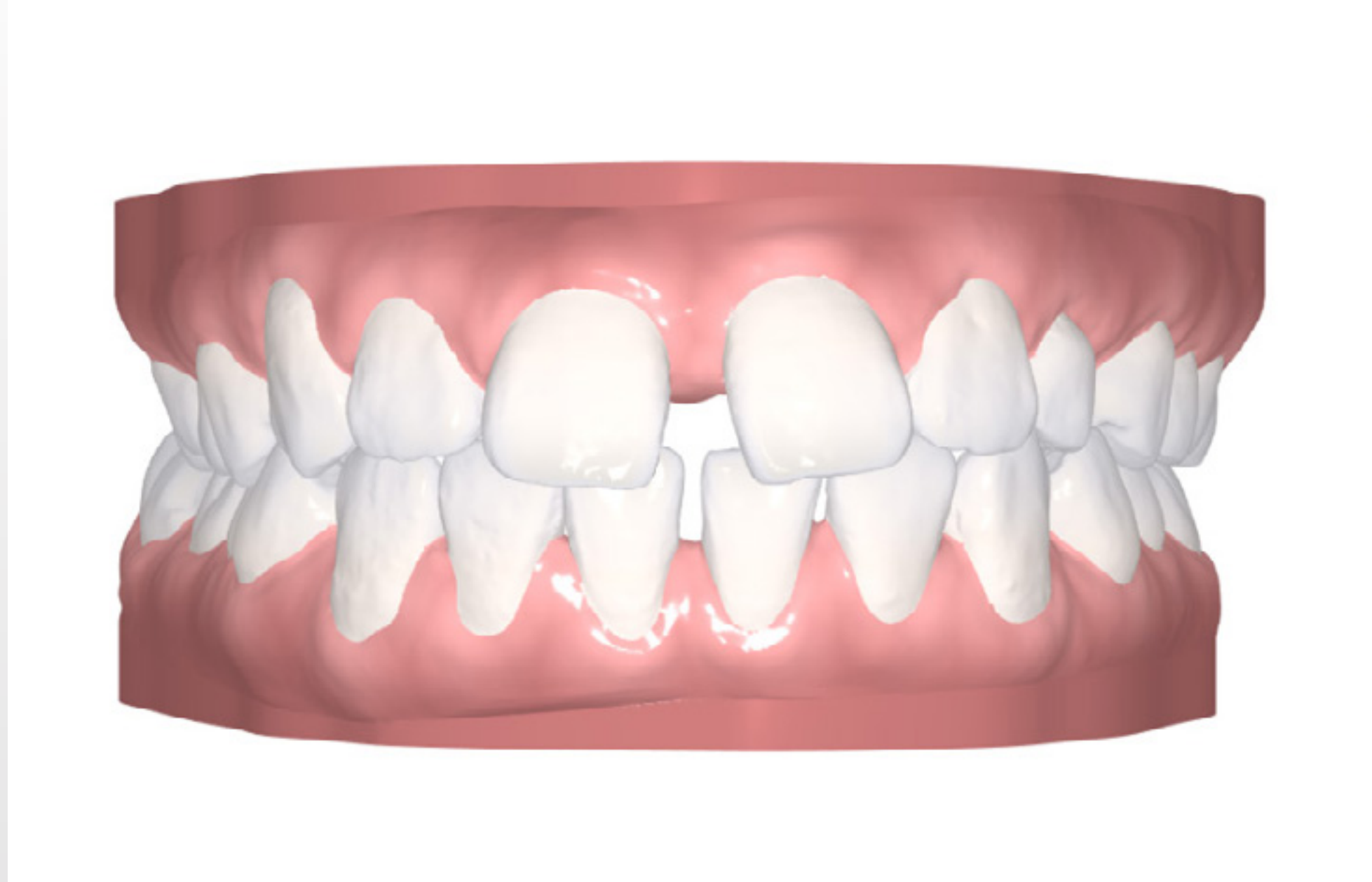




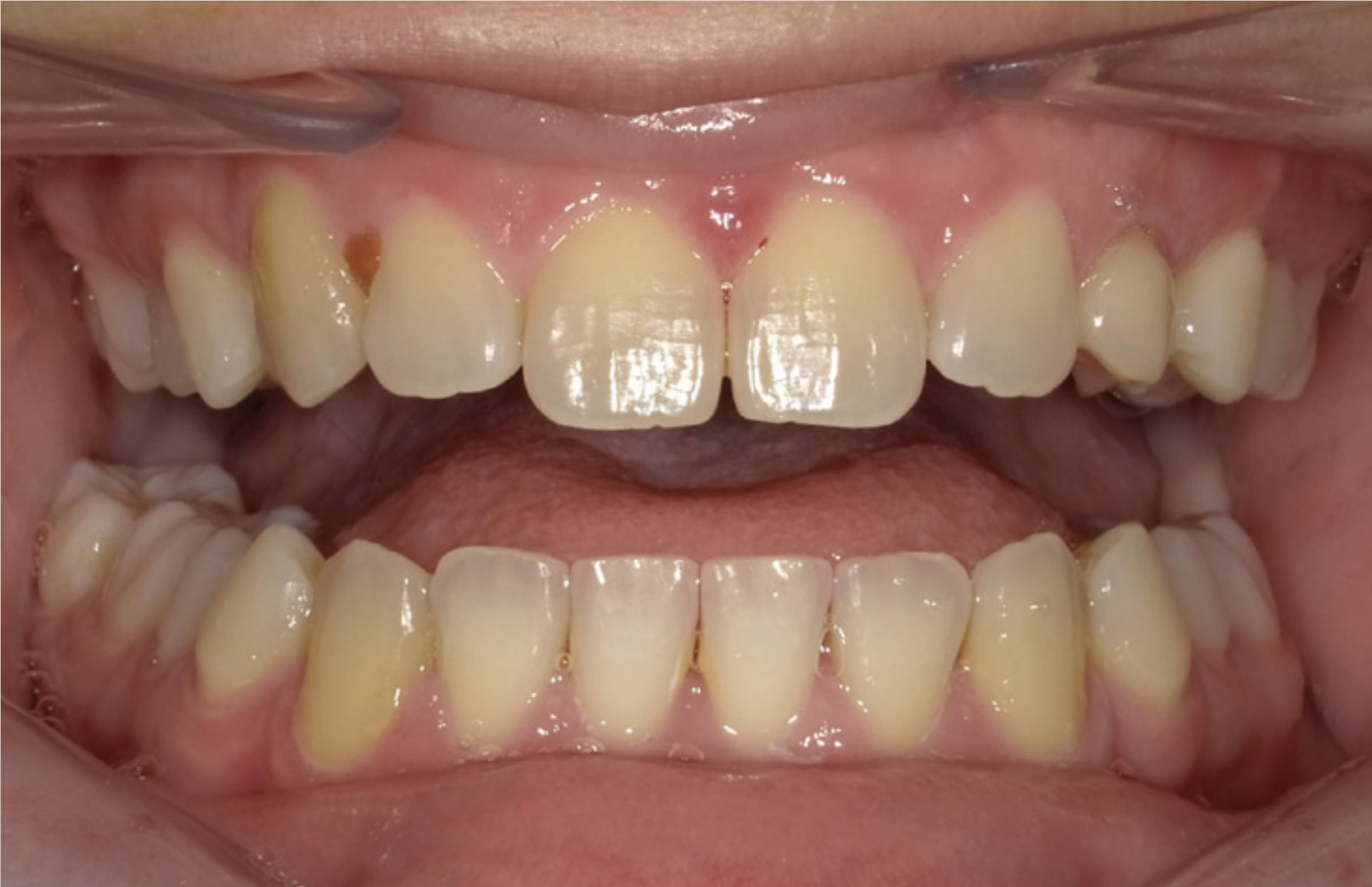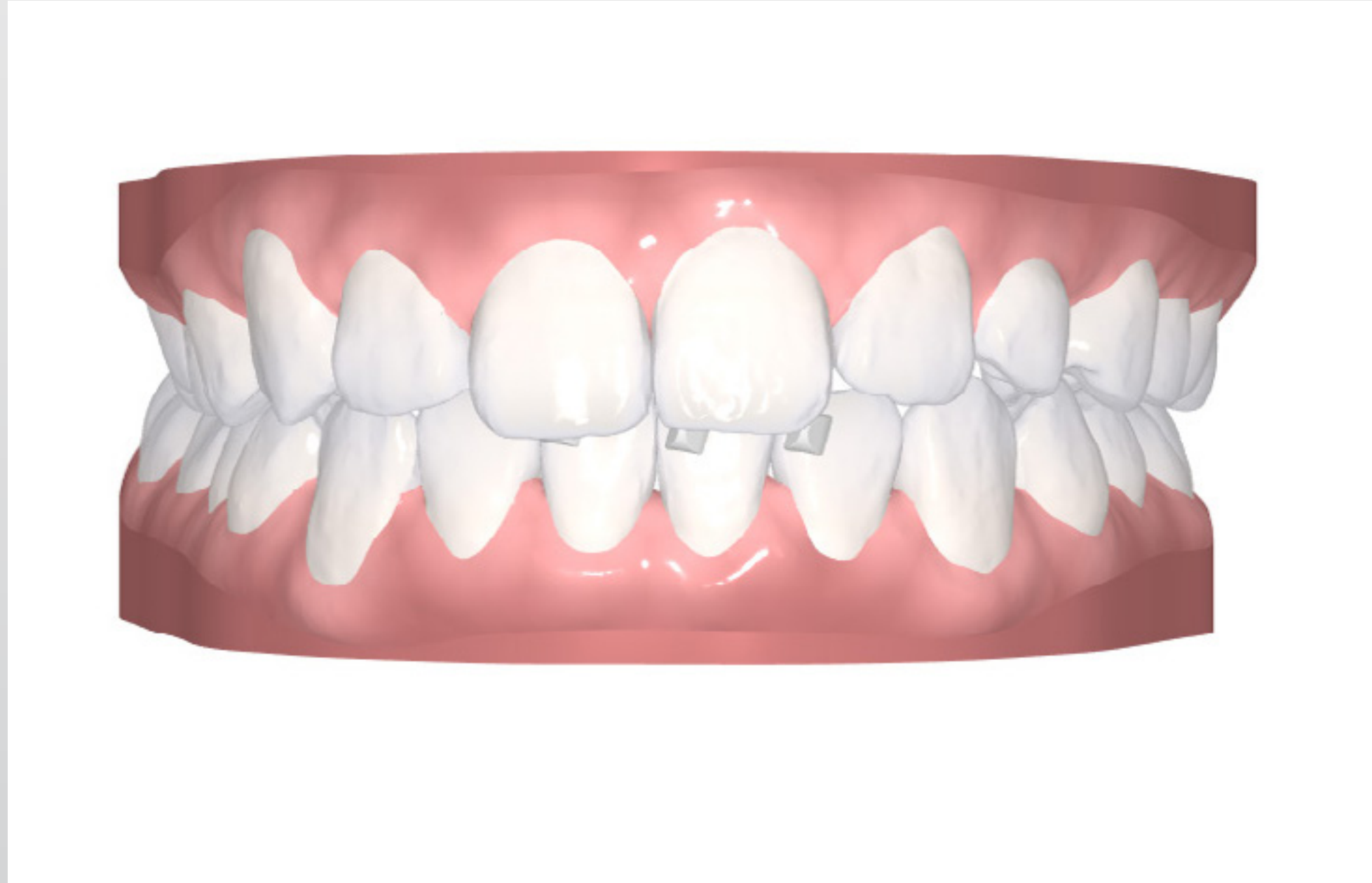Tx design

Anterior open

Initial



Final



Learn more at **3M.com/ClarityCasesAU**  
and **3M.com/ClarityCasesNZ**