

Case Study: 3M™ Clarity™ Aligners Flex + Force

Lateral incisor control.

Age: 46

Chief concern: I don't care about my overbite; I just don't like my top front teeth and want to fix them as fast as possible

Case diagnostics: Skeletal Class II, dental Class II subdivision right (1/2 cusp), 50% OB, 4mm OJ, mild upper and lower crowding

Total number of aligners: Initial Tx Design: 24 aligners
3M™ Clarity™ Aligners Flex:
Stages 1-17 upper and lower arches
3M™ Clarity™ Aligners Force:
Stages 18-24 upper and lower arches

Refinement 1 – Tx Design: 6 aligners
3M™ Clarity™ Aligners Flex:
Stages 24-27 upper and lower arches
3M™ Clarity™ Aligners Force:
Stages 28-29 upper and lower arches

Wear interval: 7 days

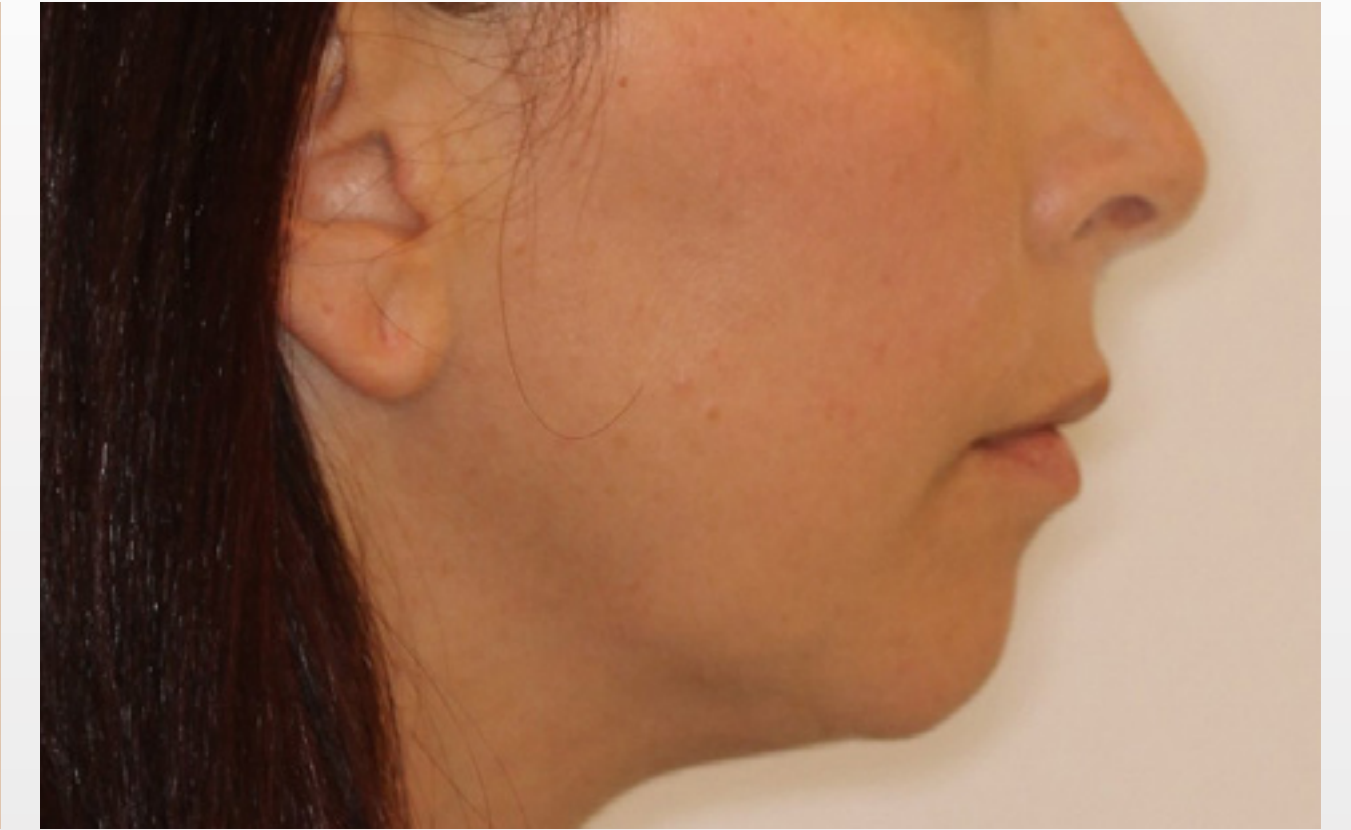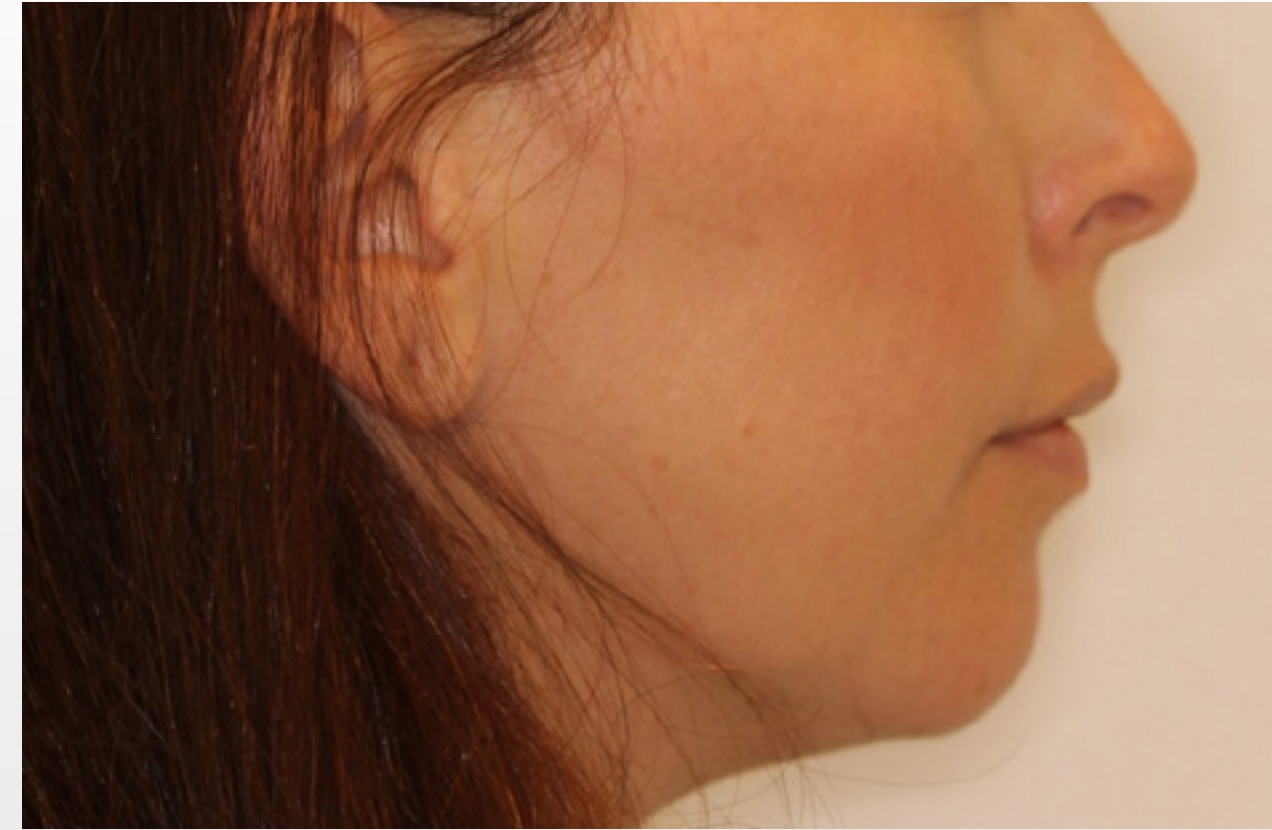Treatment time: 7 months

Case courtesy of:
Dr. Doug Palaganas
Great Neck, NY – USA

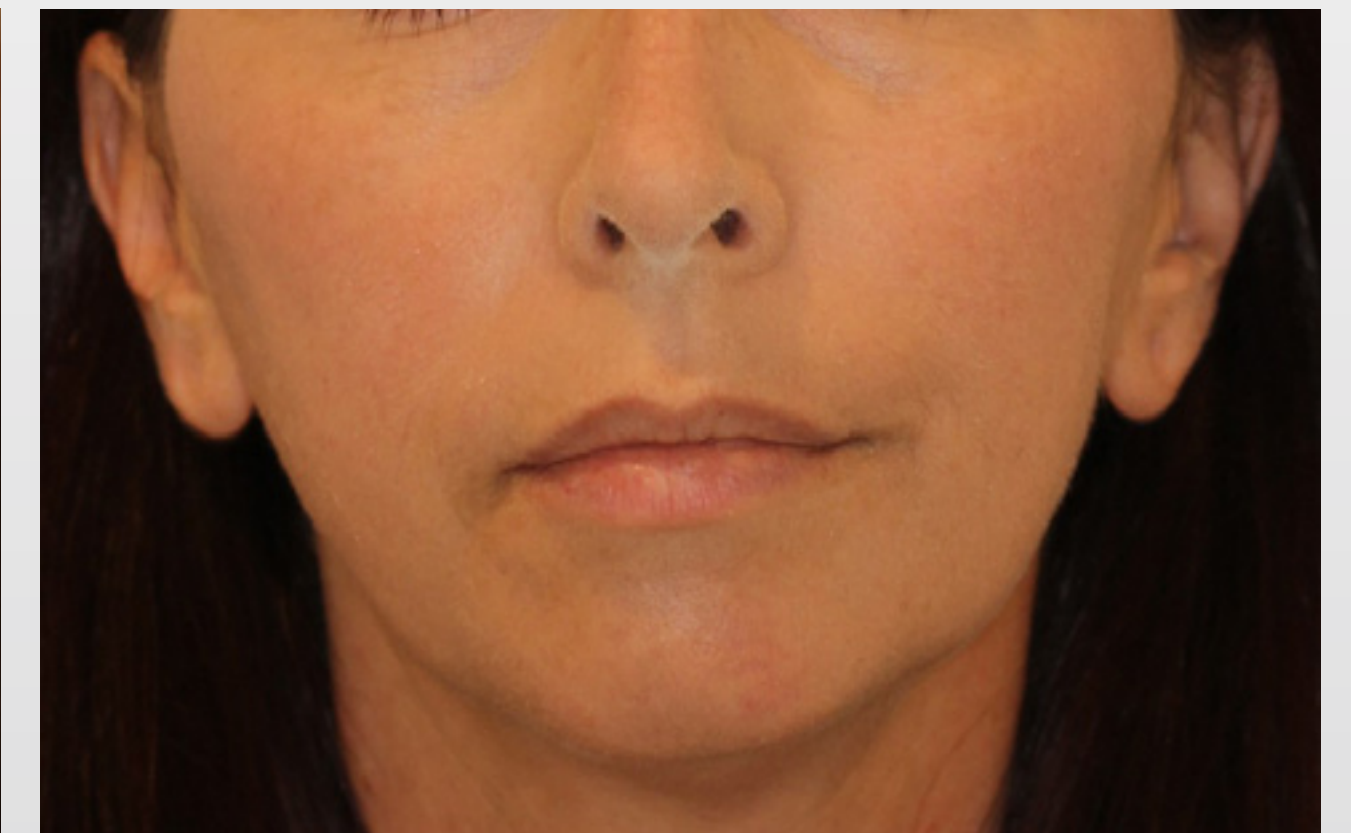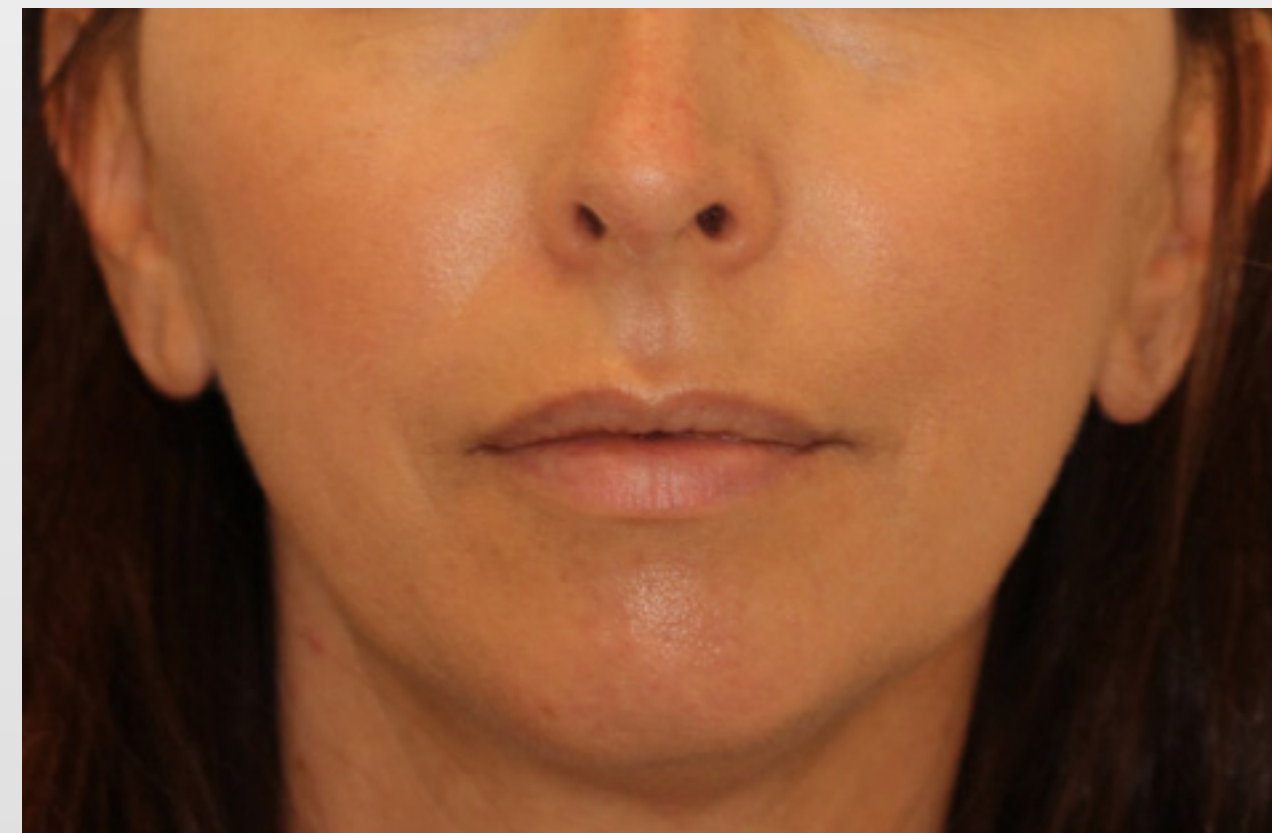Initial

Final

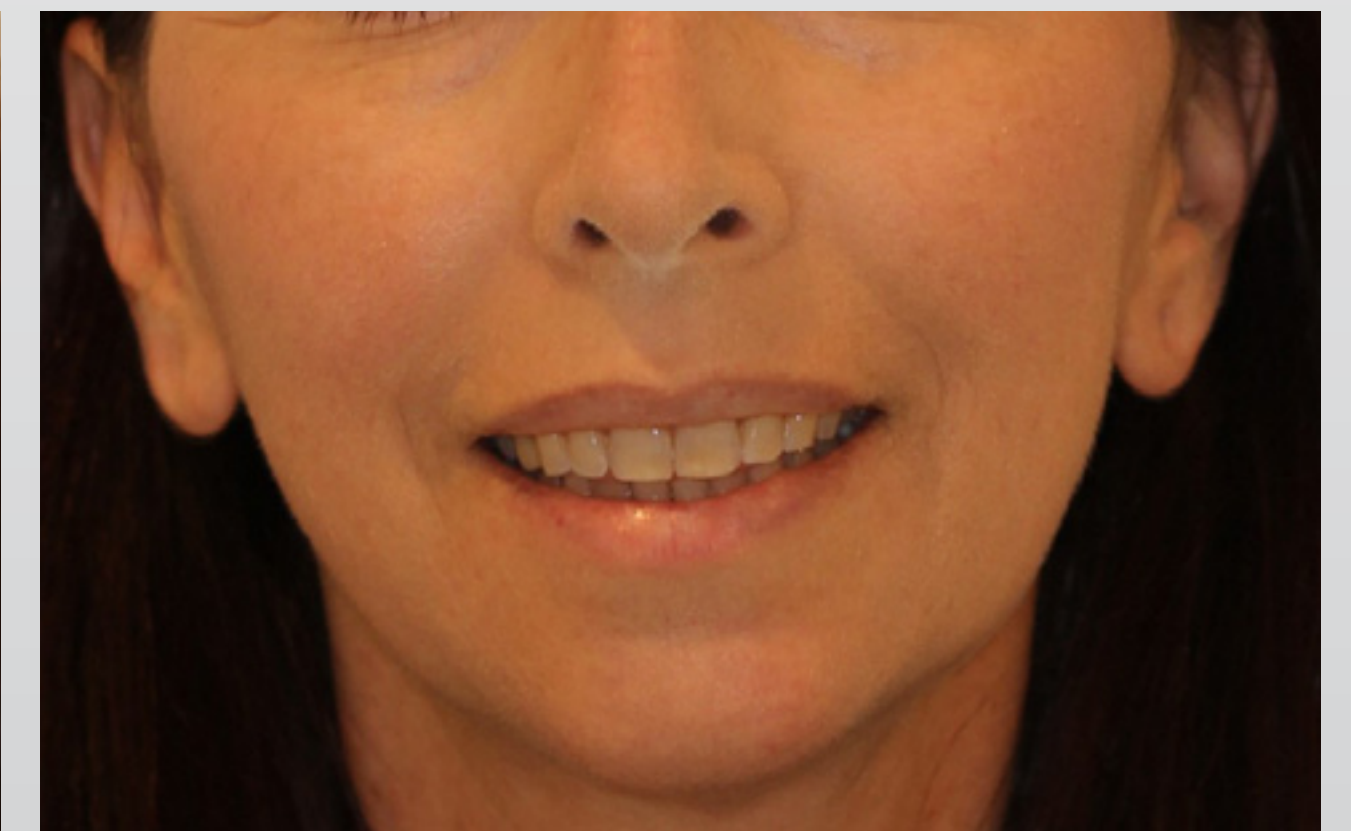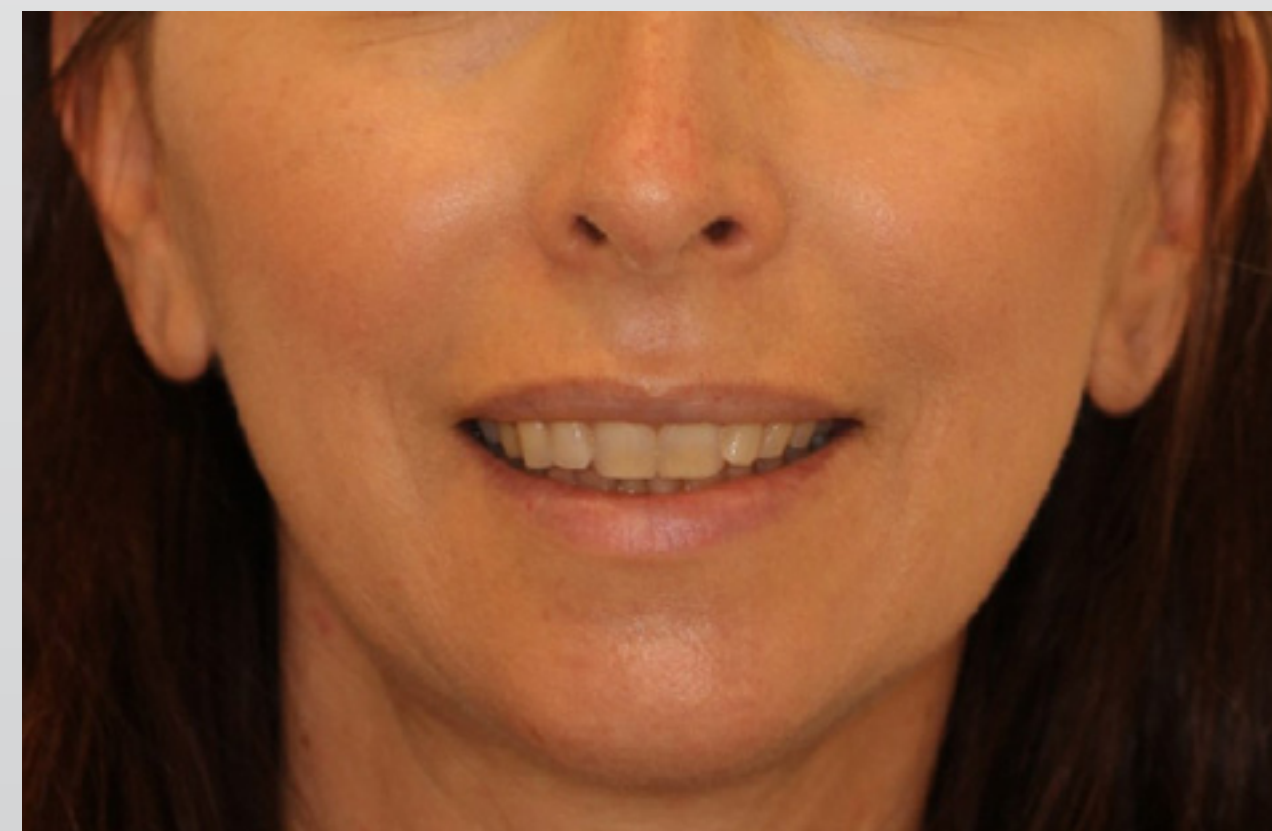Profile at rest



Face at rest



Face smiling

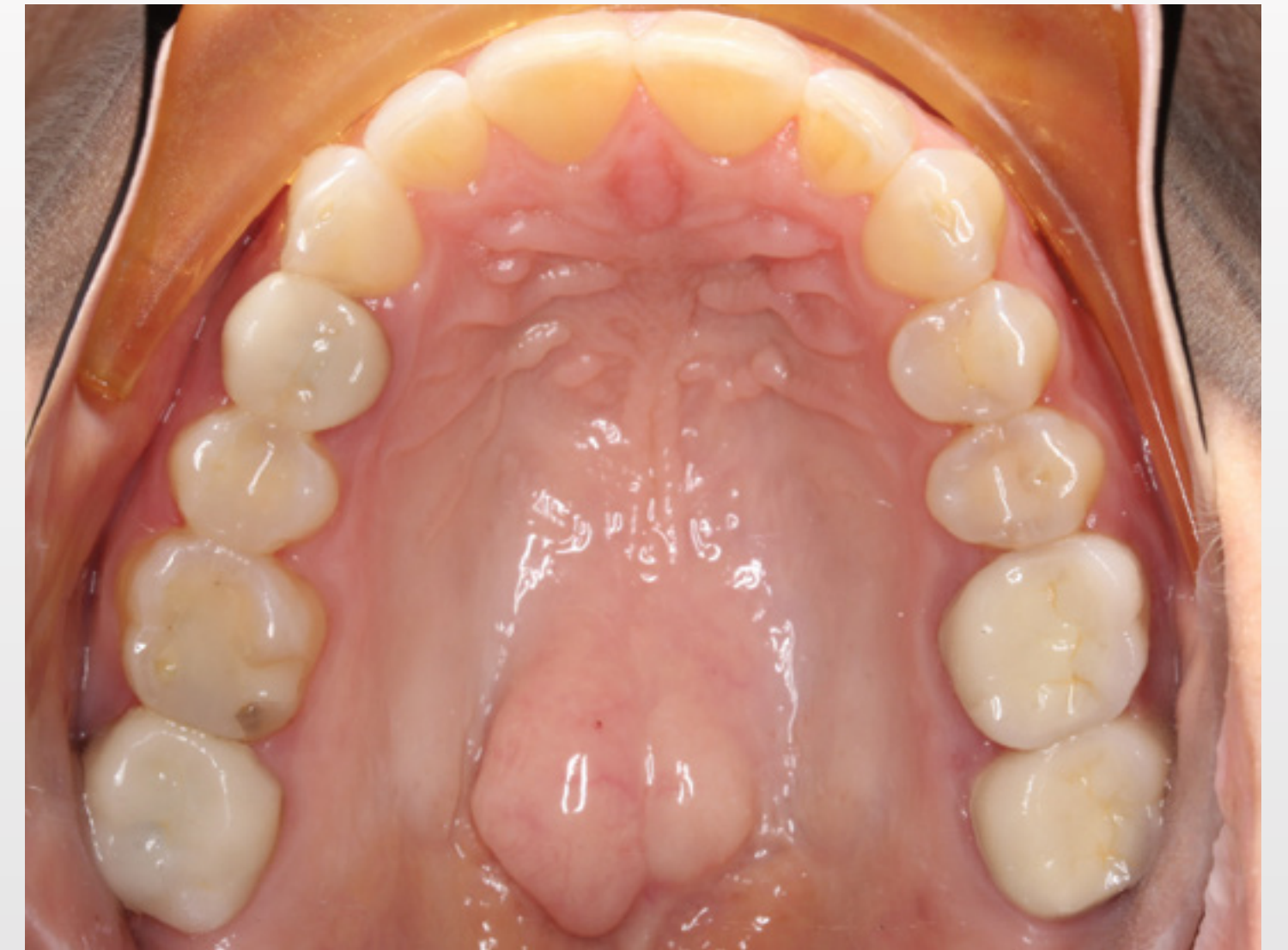
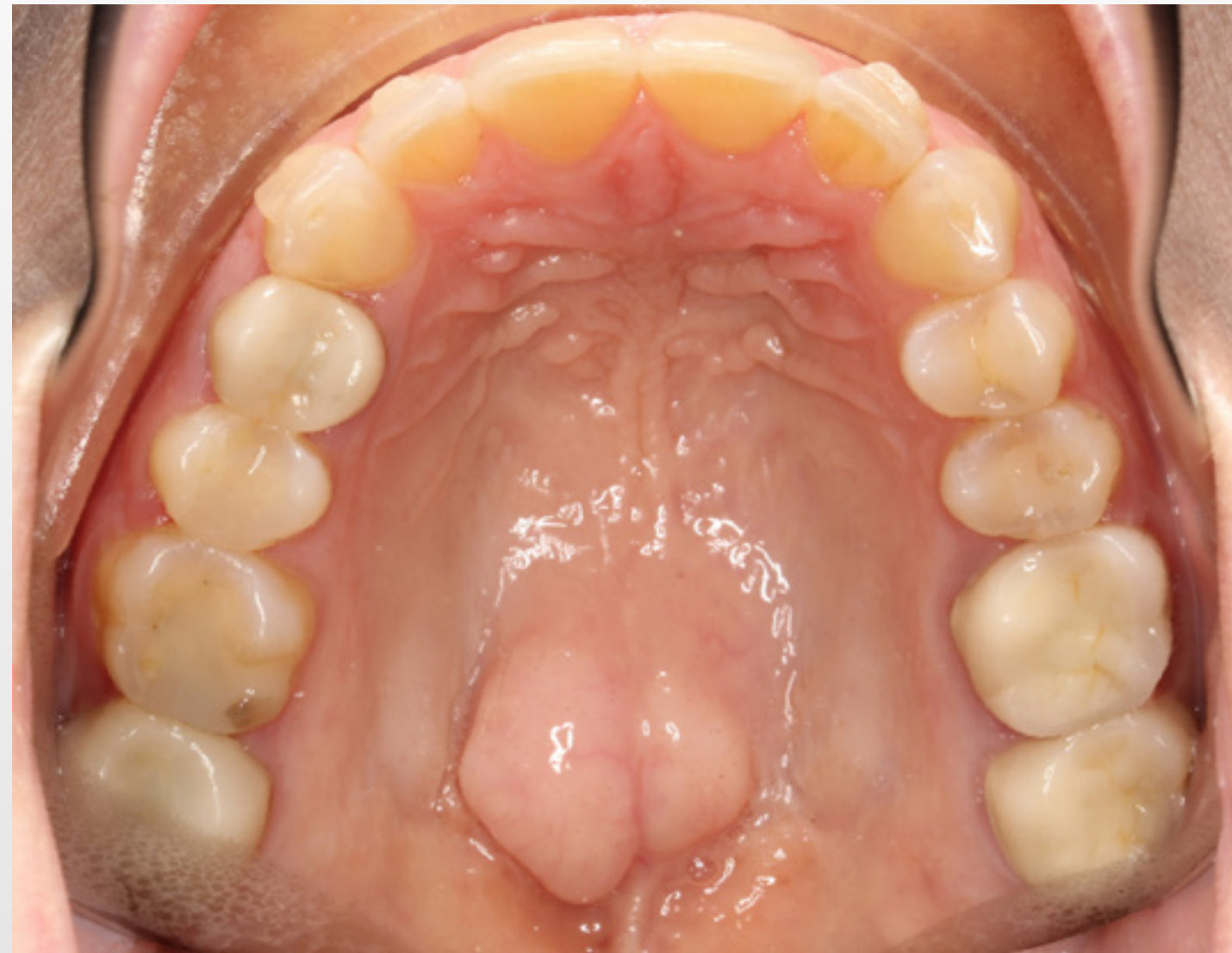
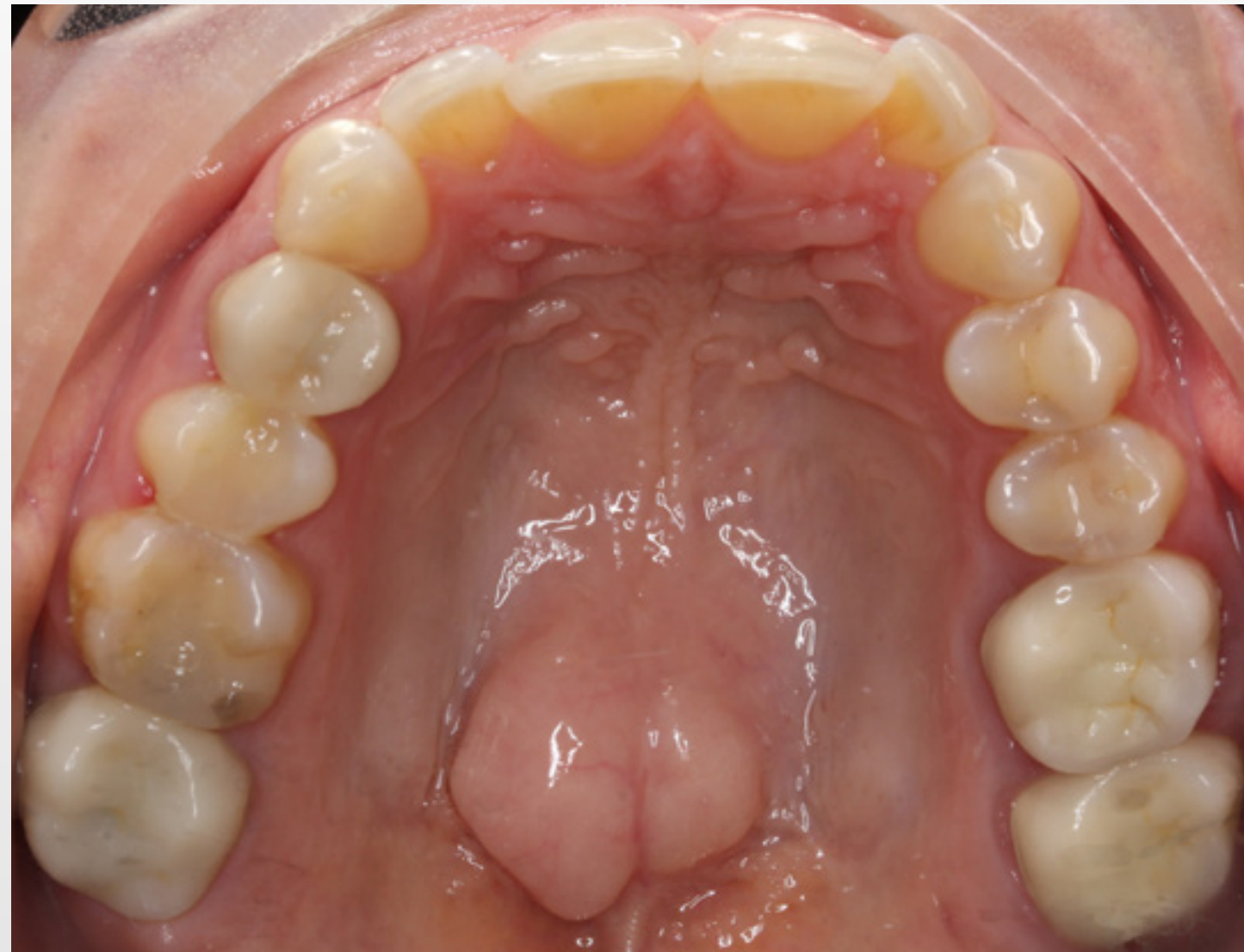Initial

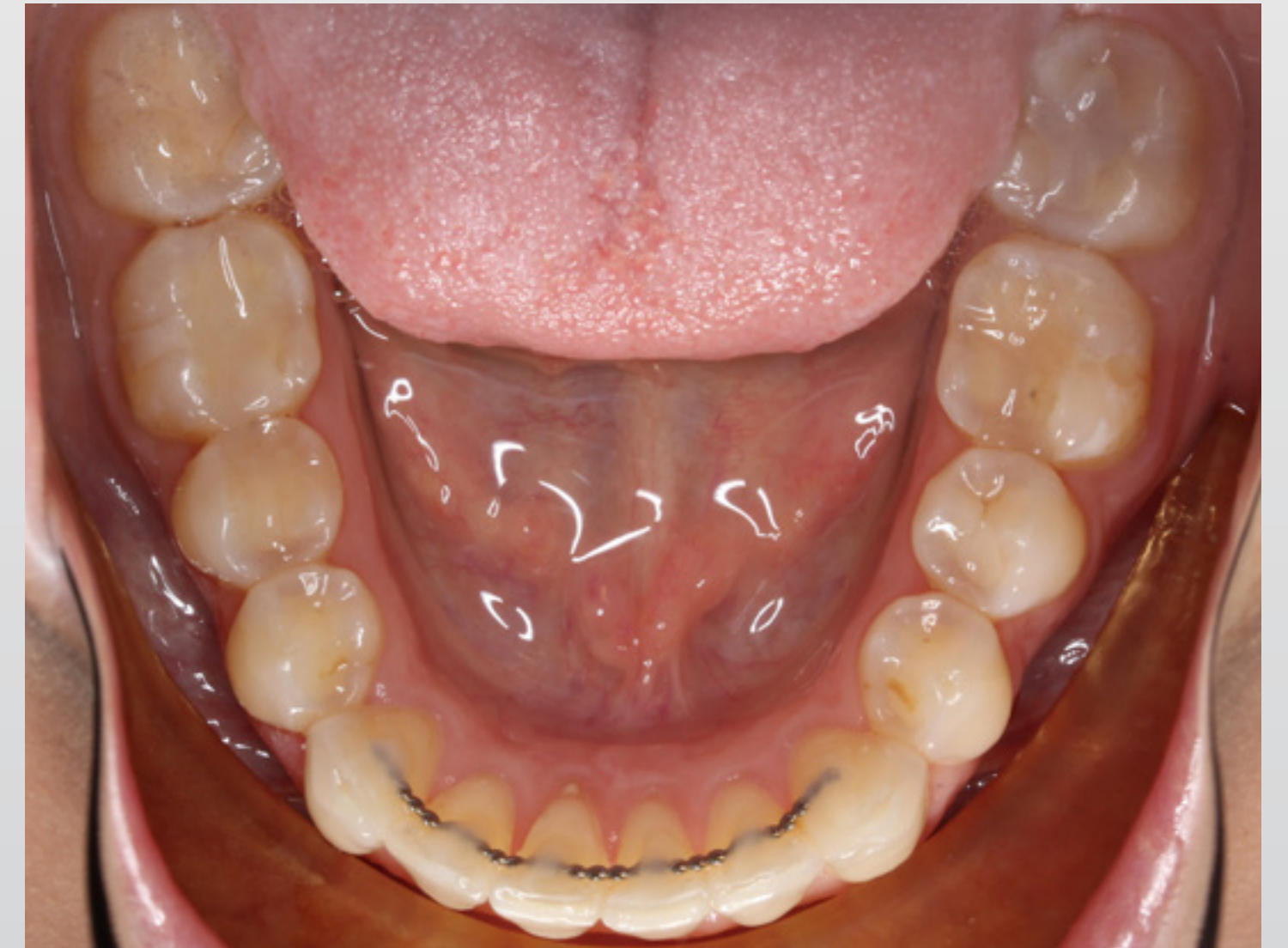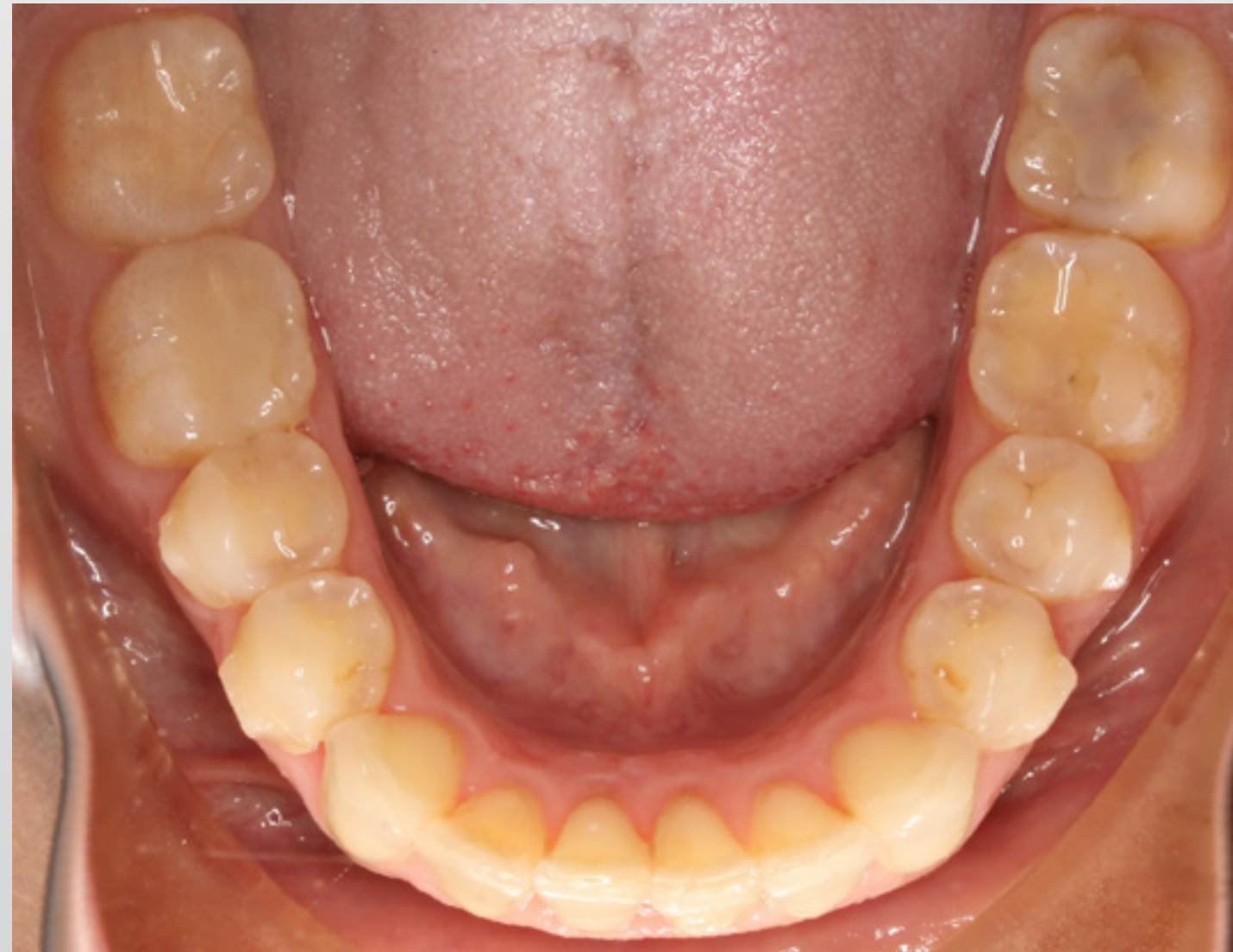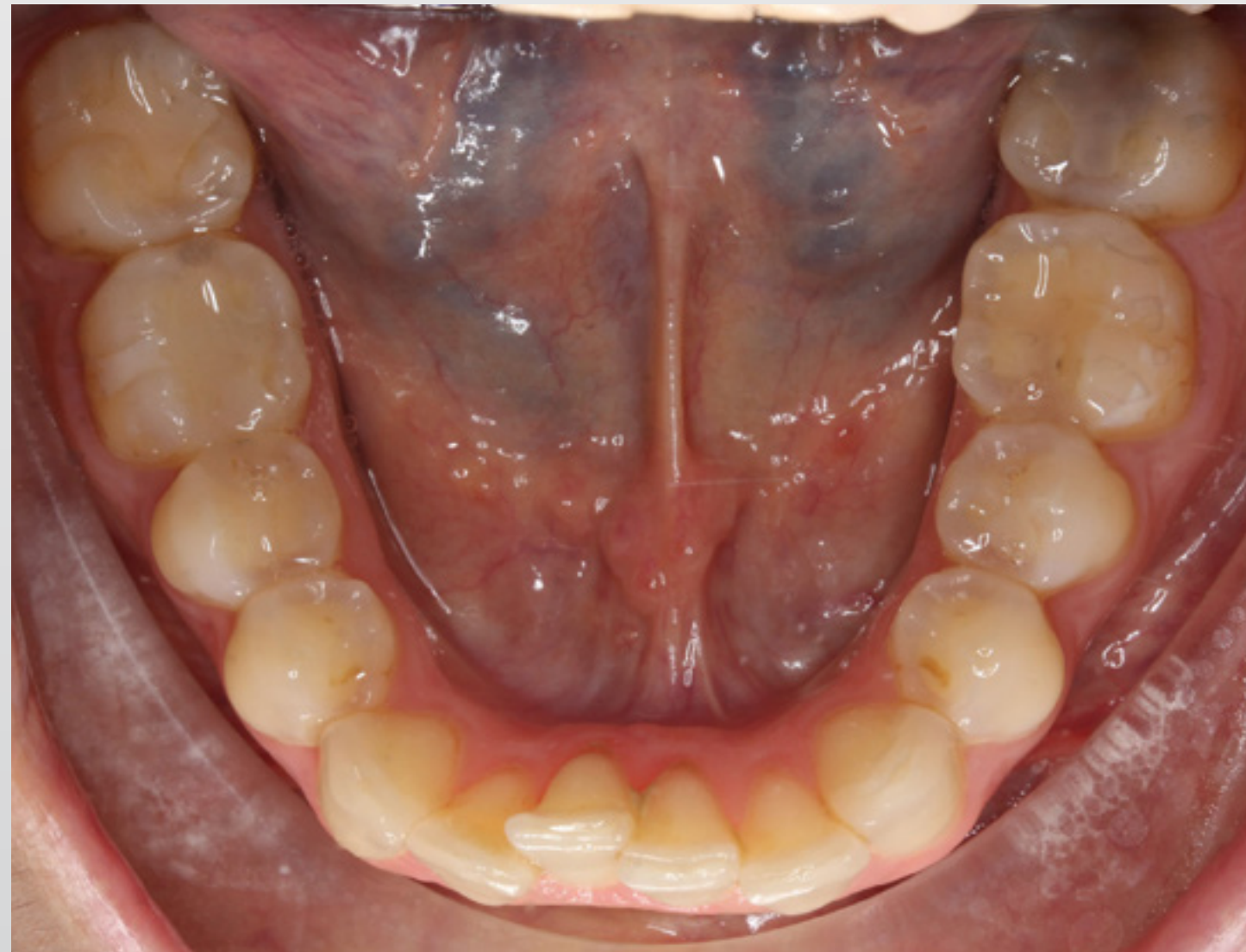Progress - Aligner 24

Final

**Occlusal -
maxillary**



**Occlusal -
mandibular**

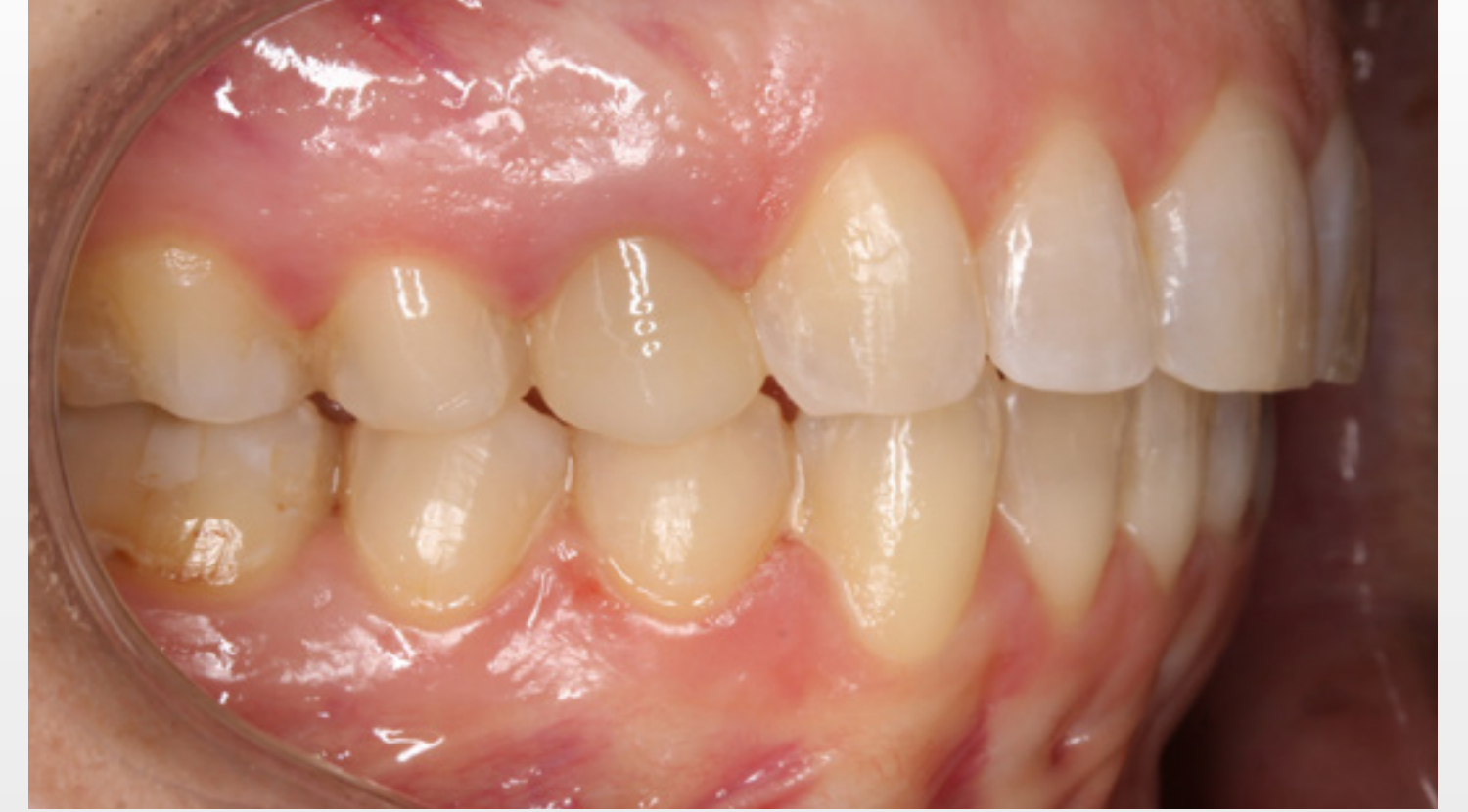
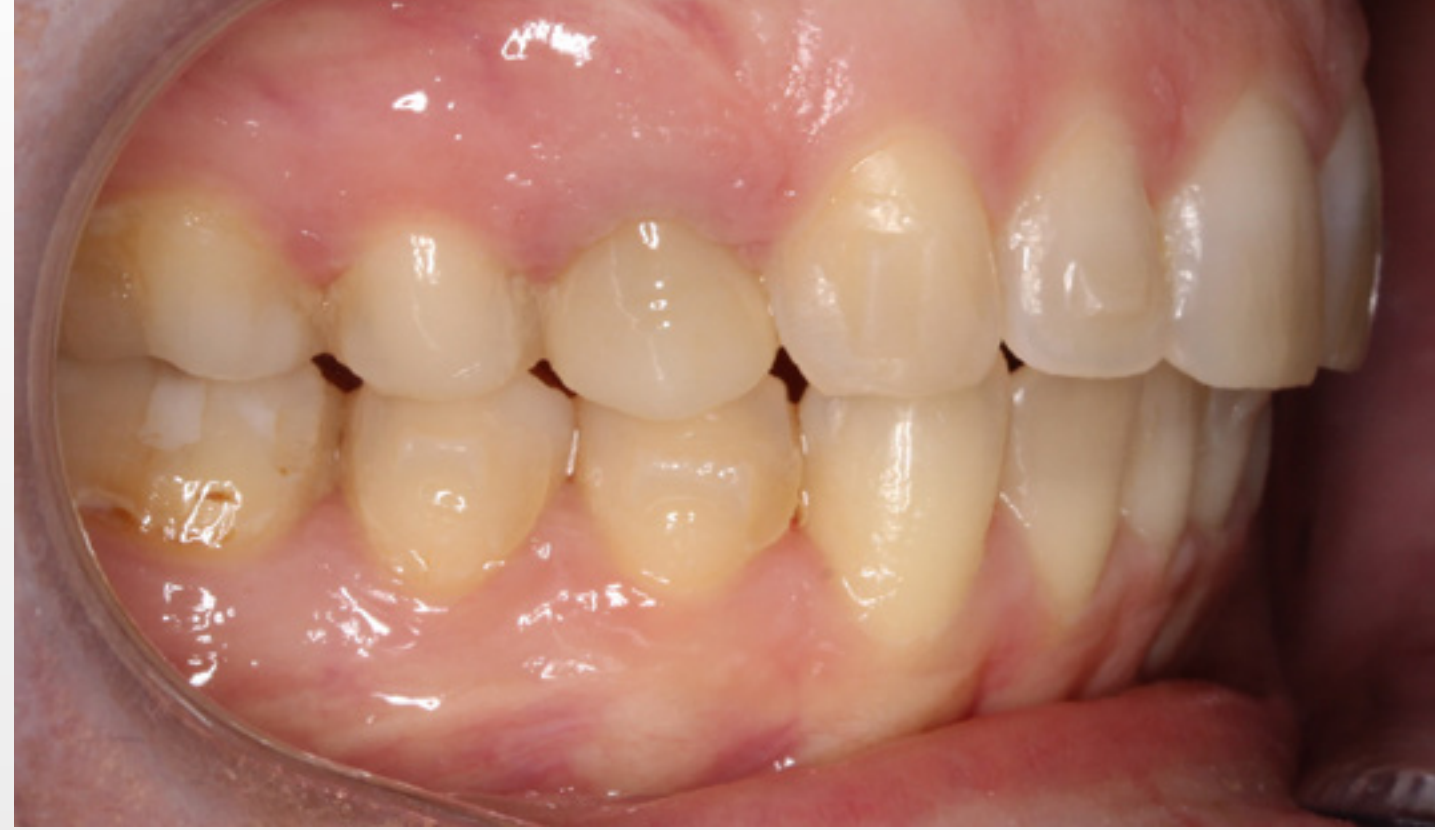
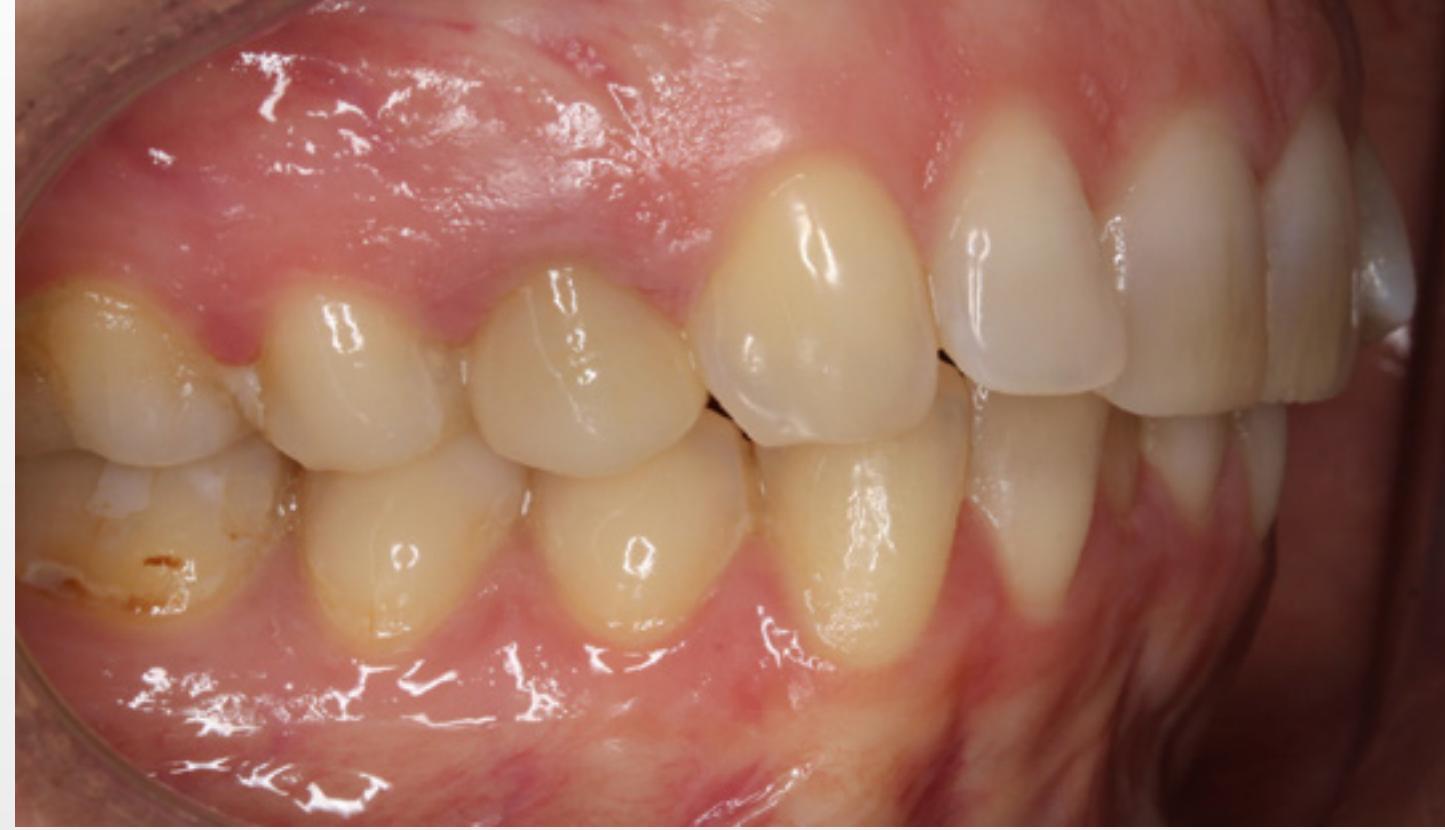Initial

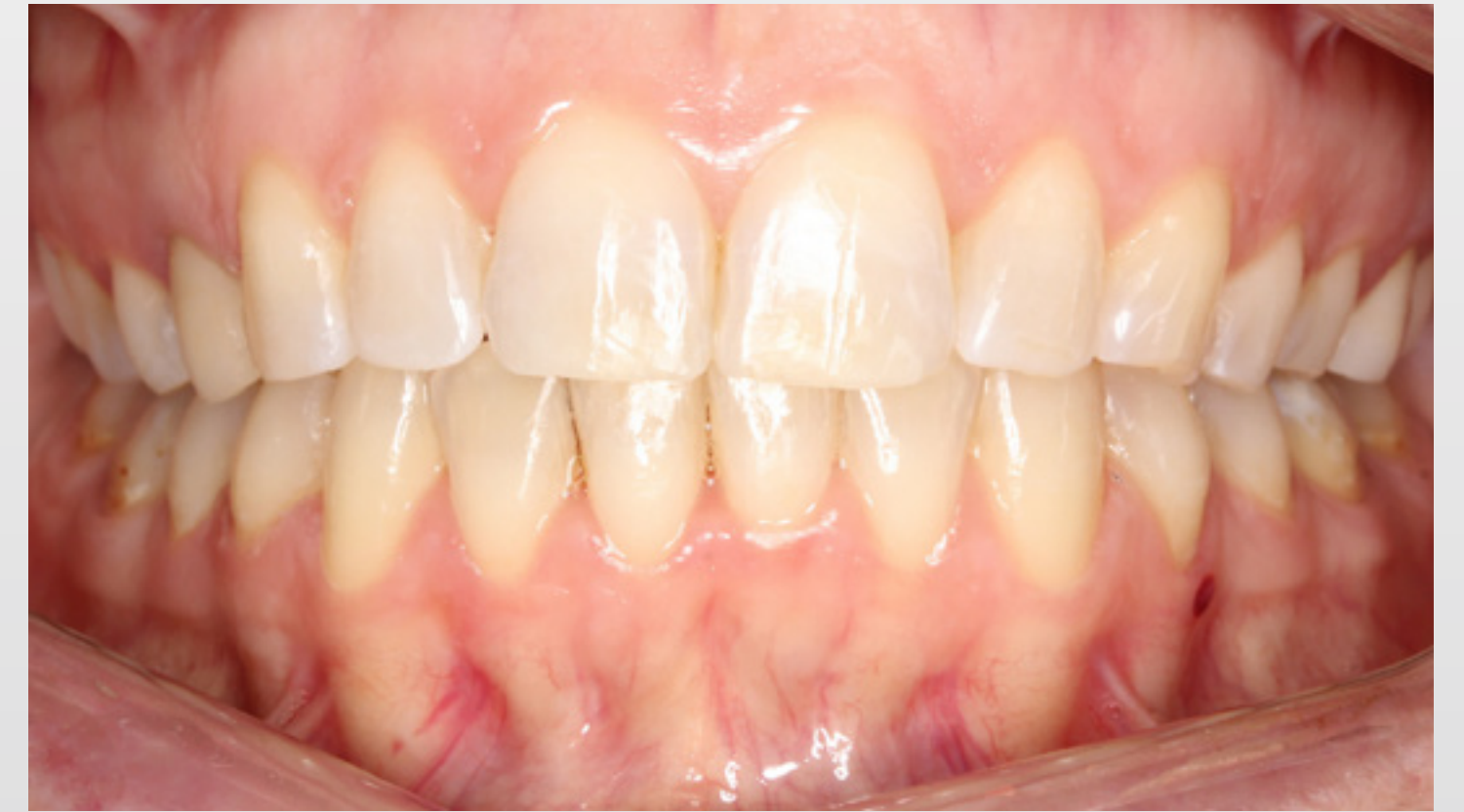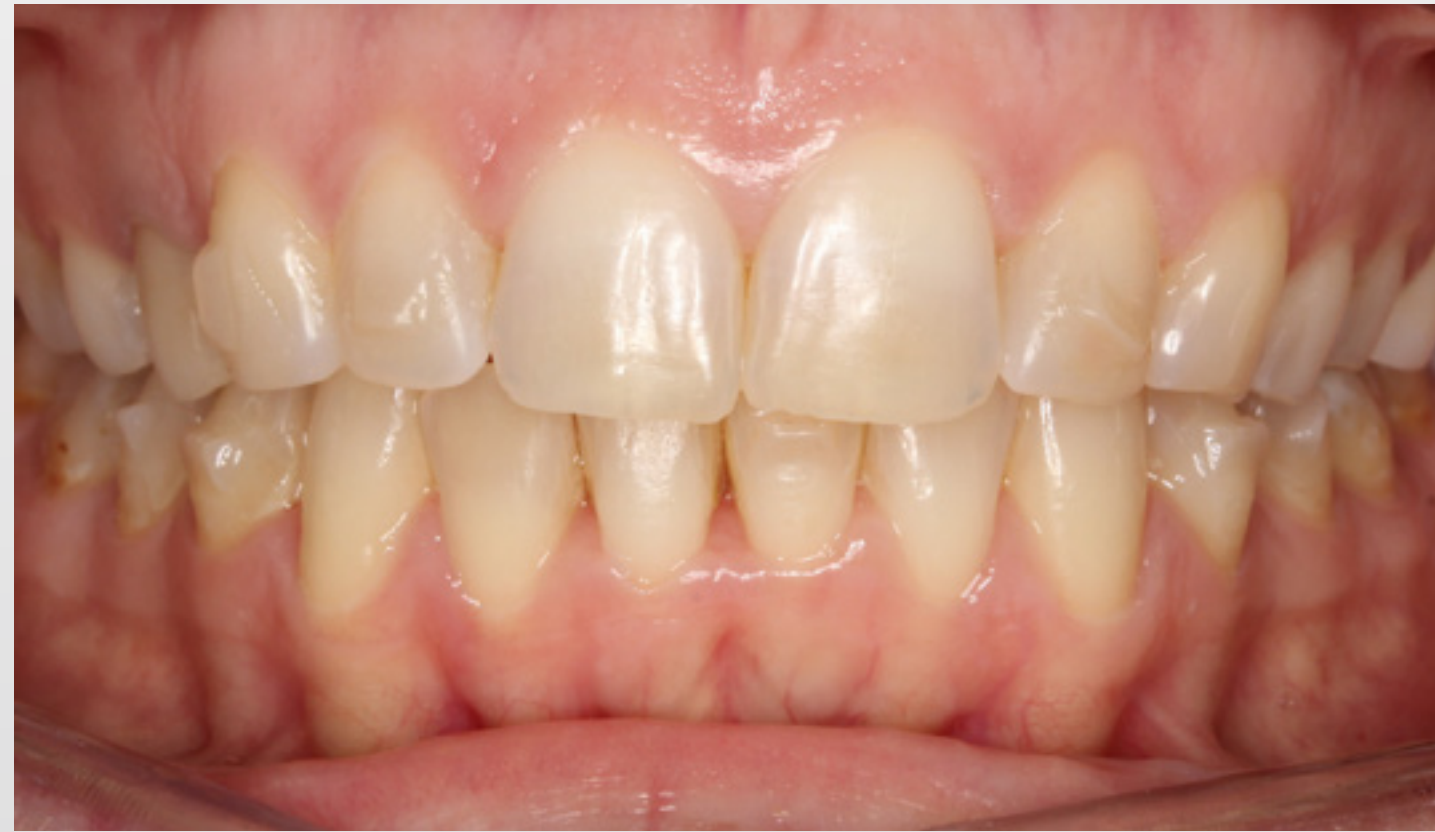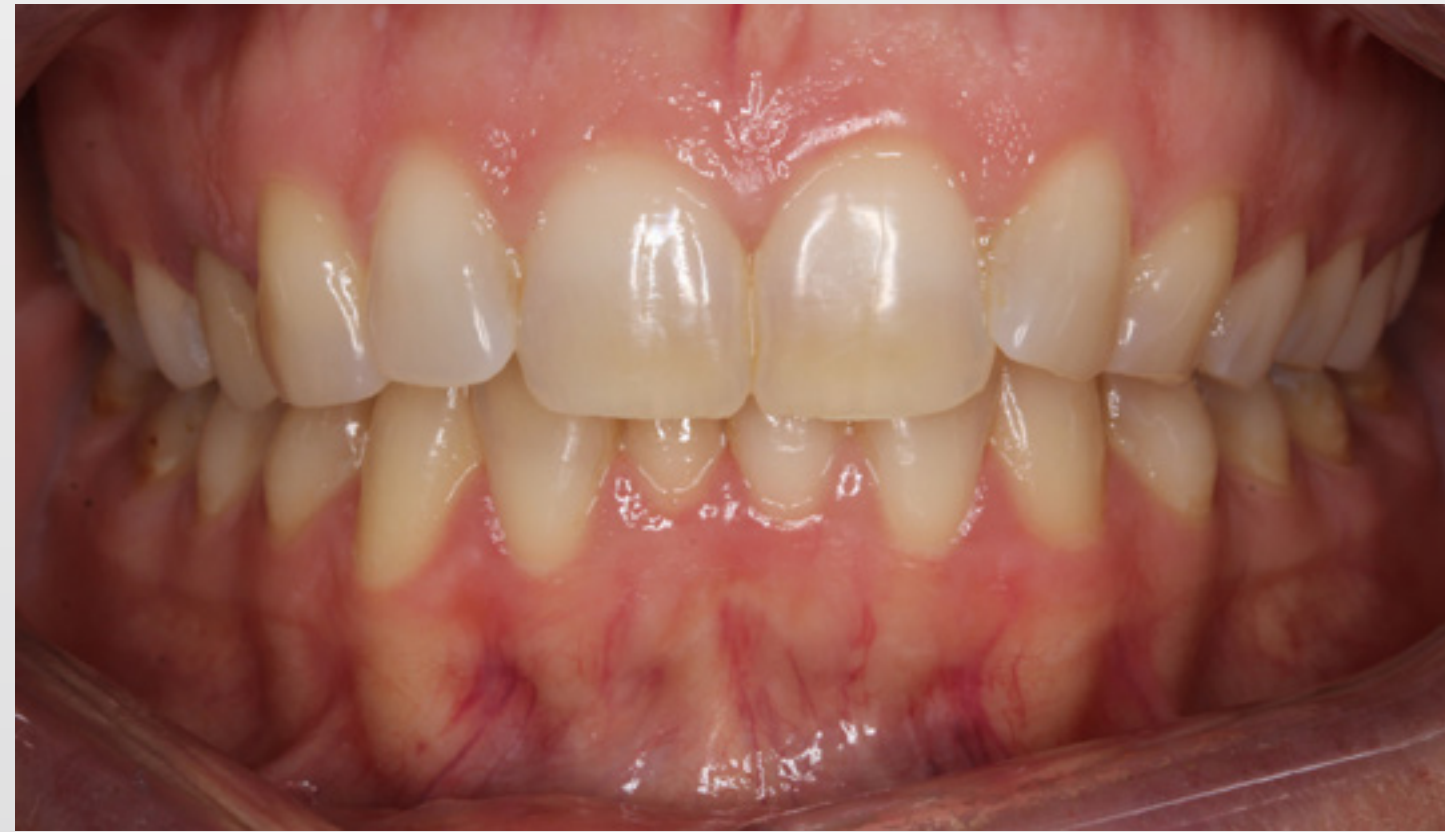Progress - Aligner 24

Final

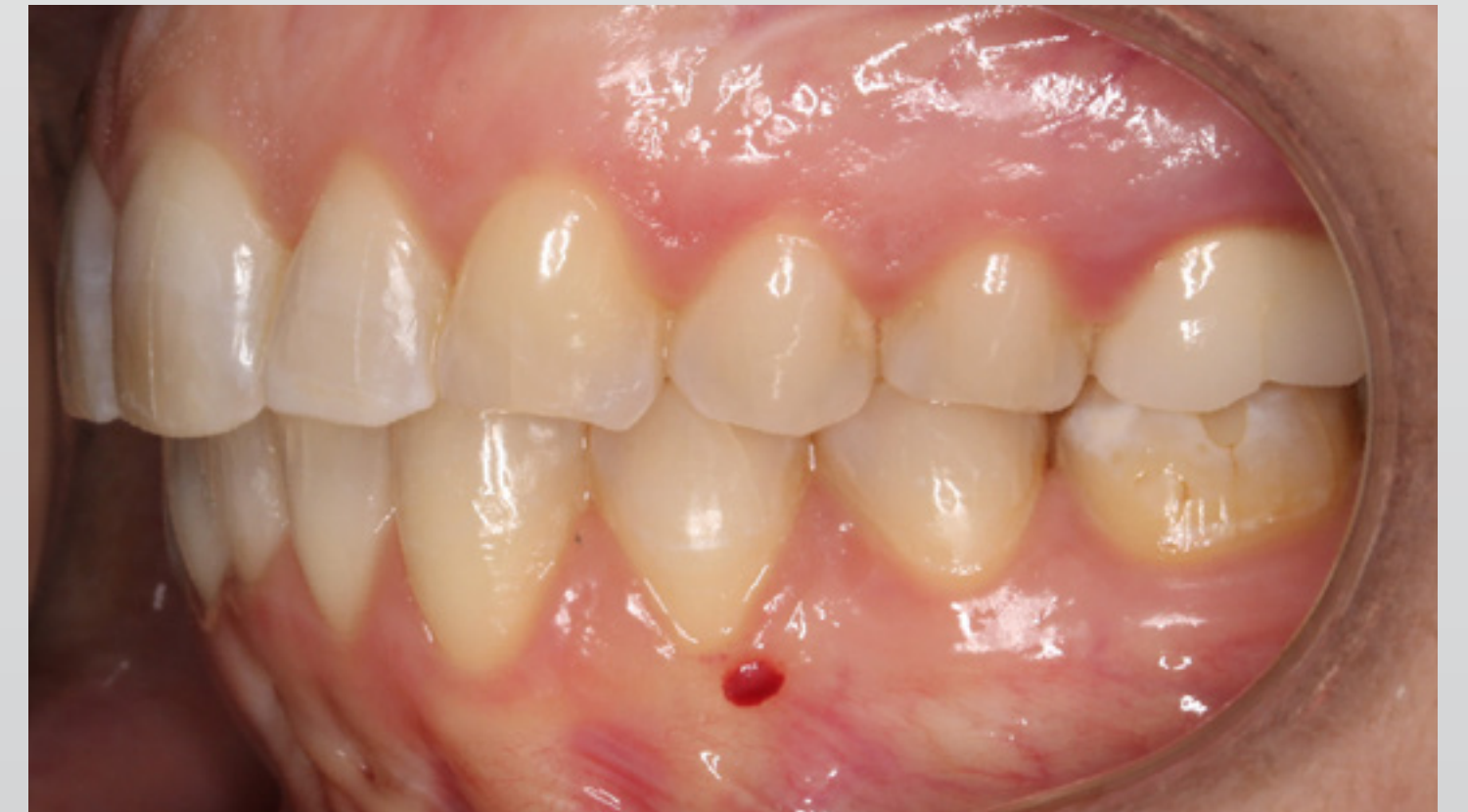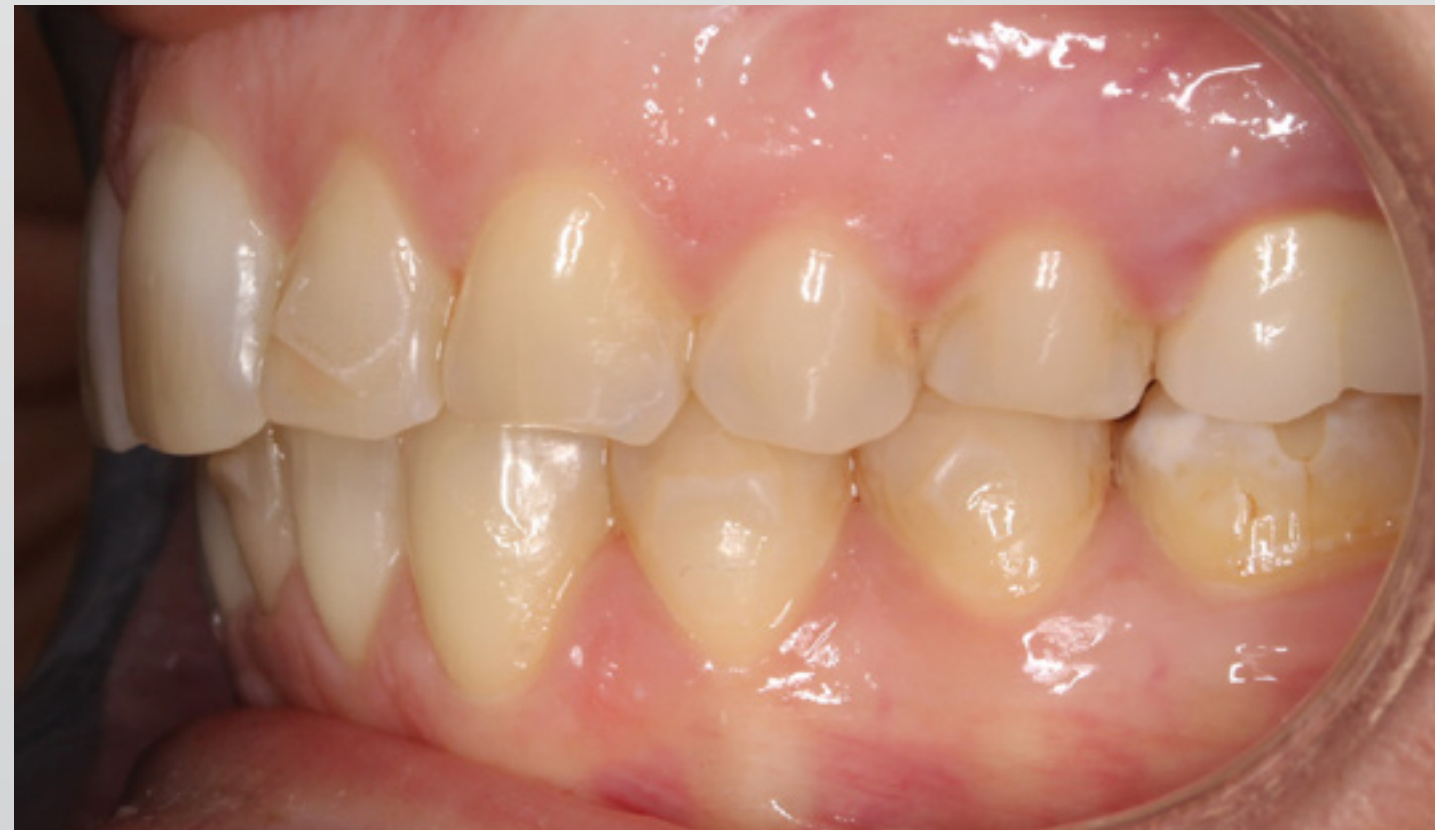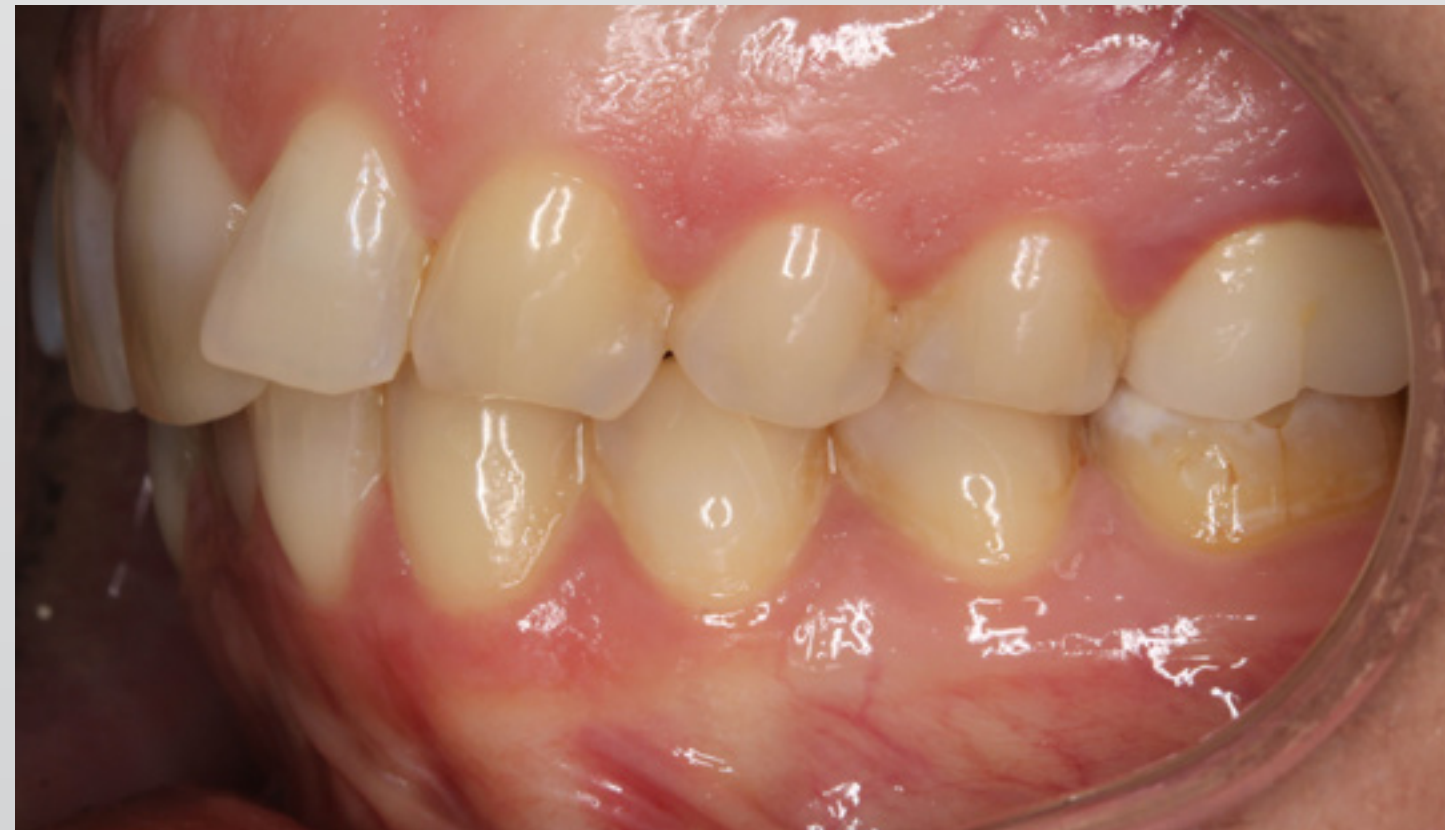**Retracted
buccal – right**



**Retracted
anterior
biting**

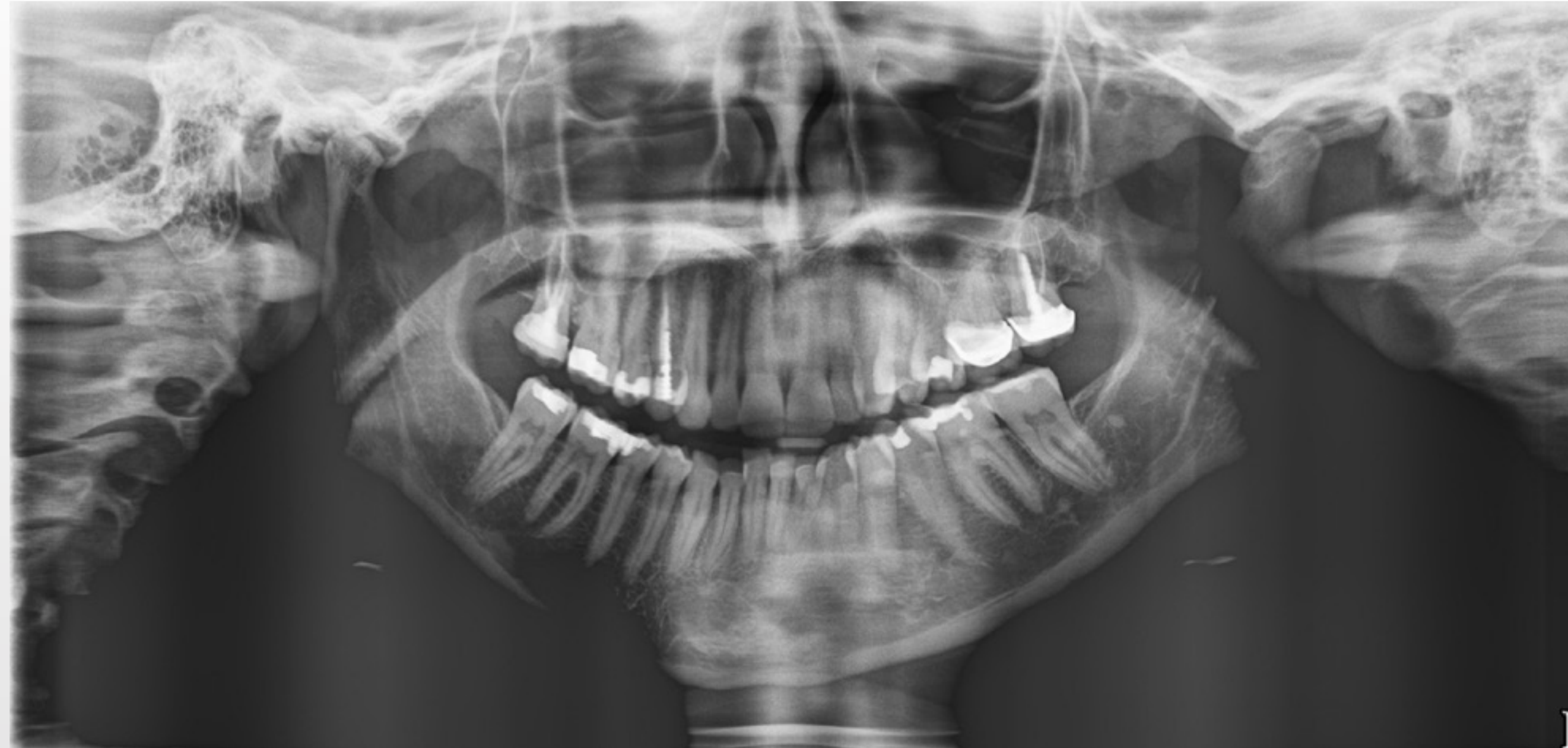

**Retracted
buccal – left**

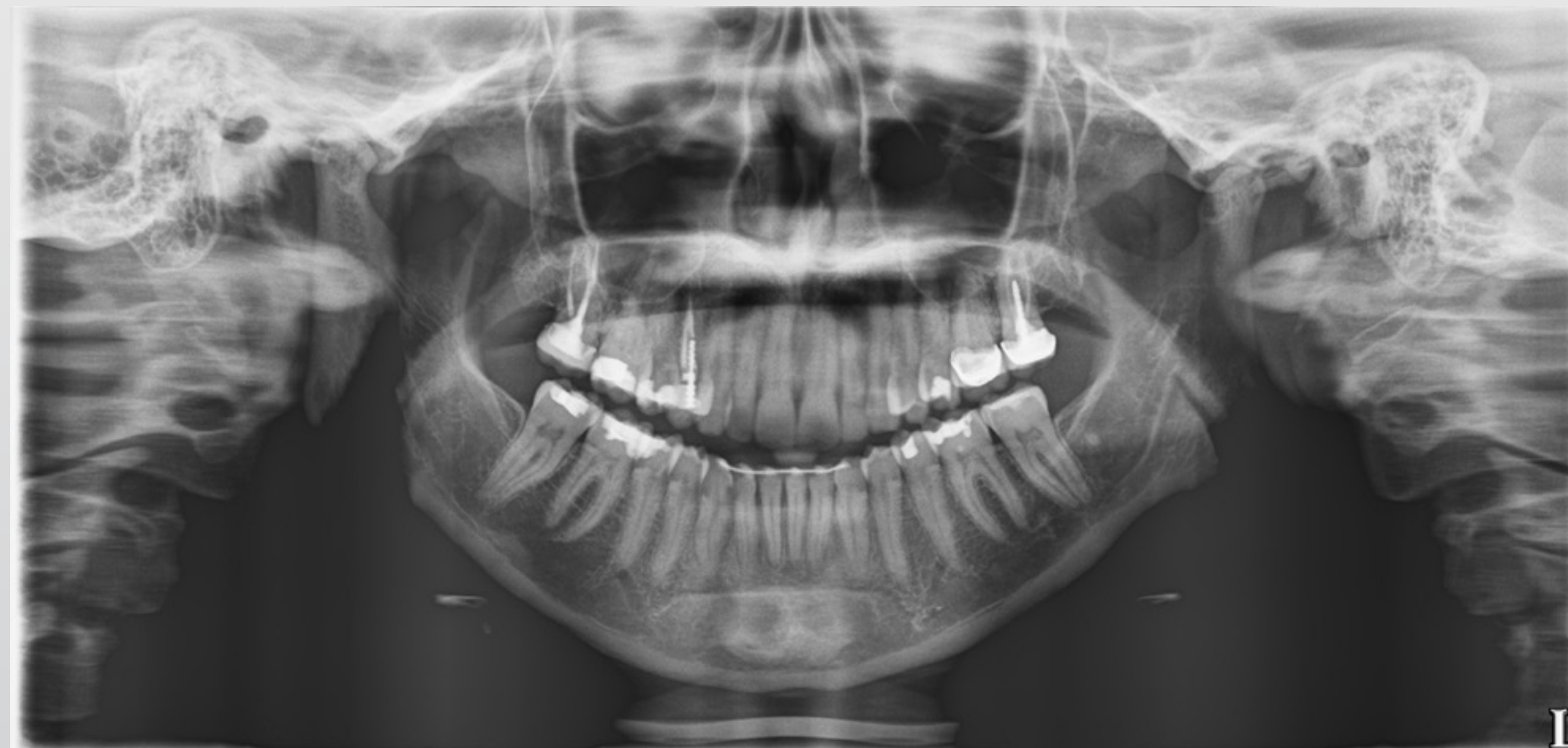

Panoramic radiograph

Initial



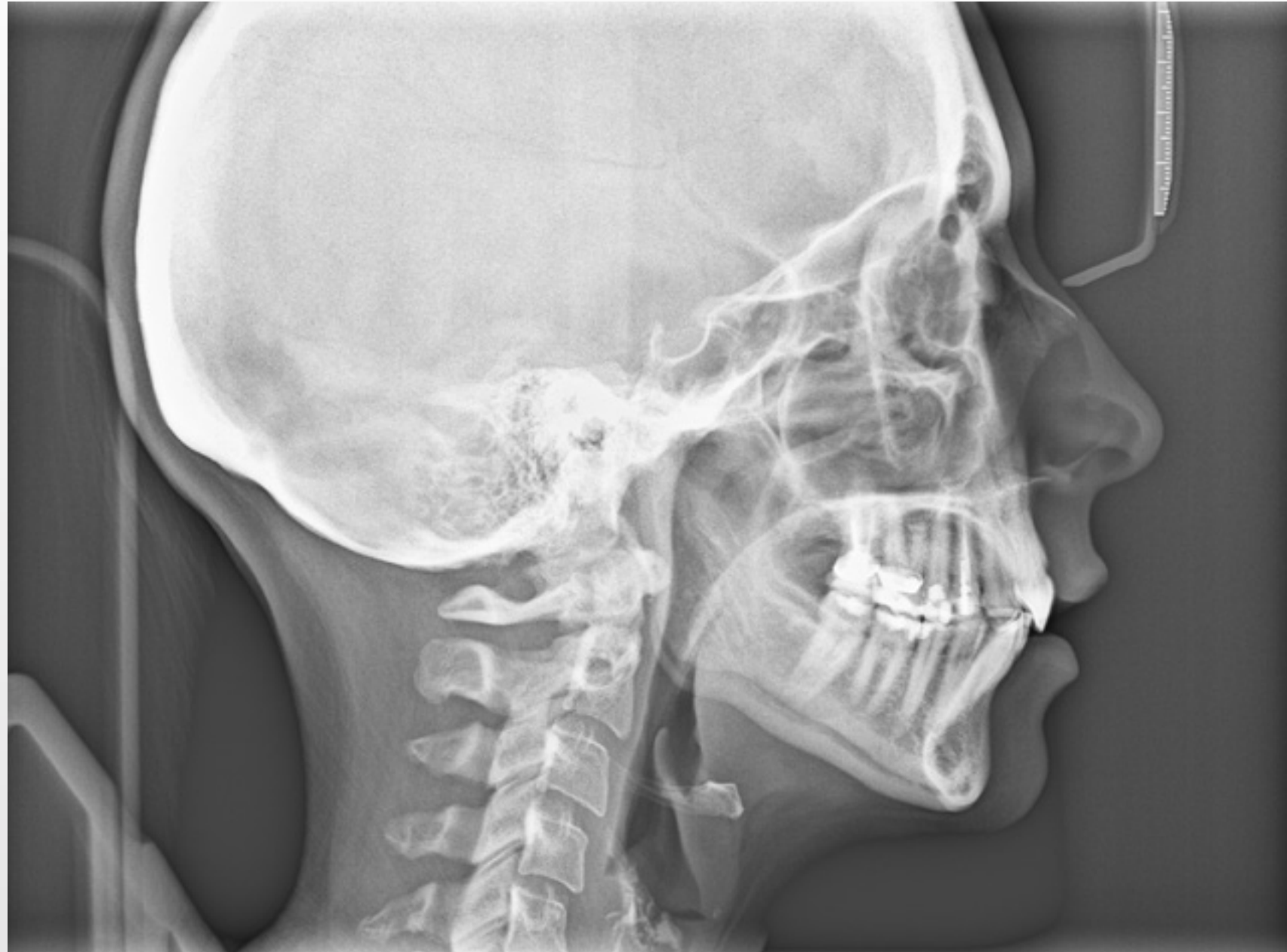Final



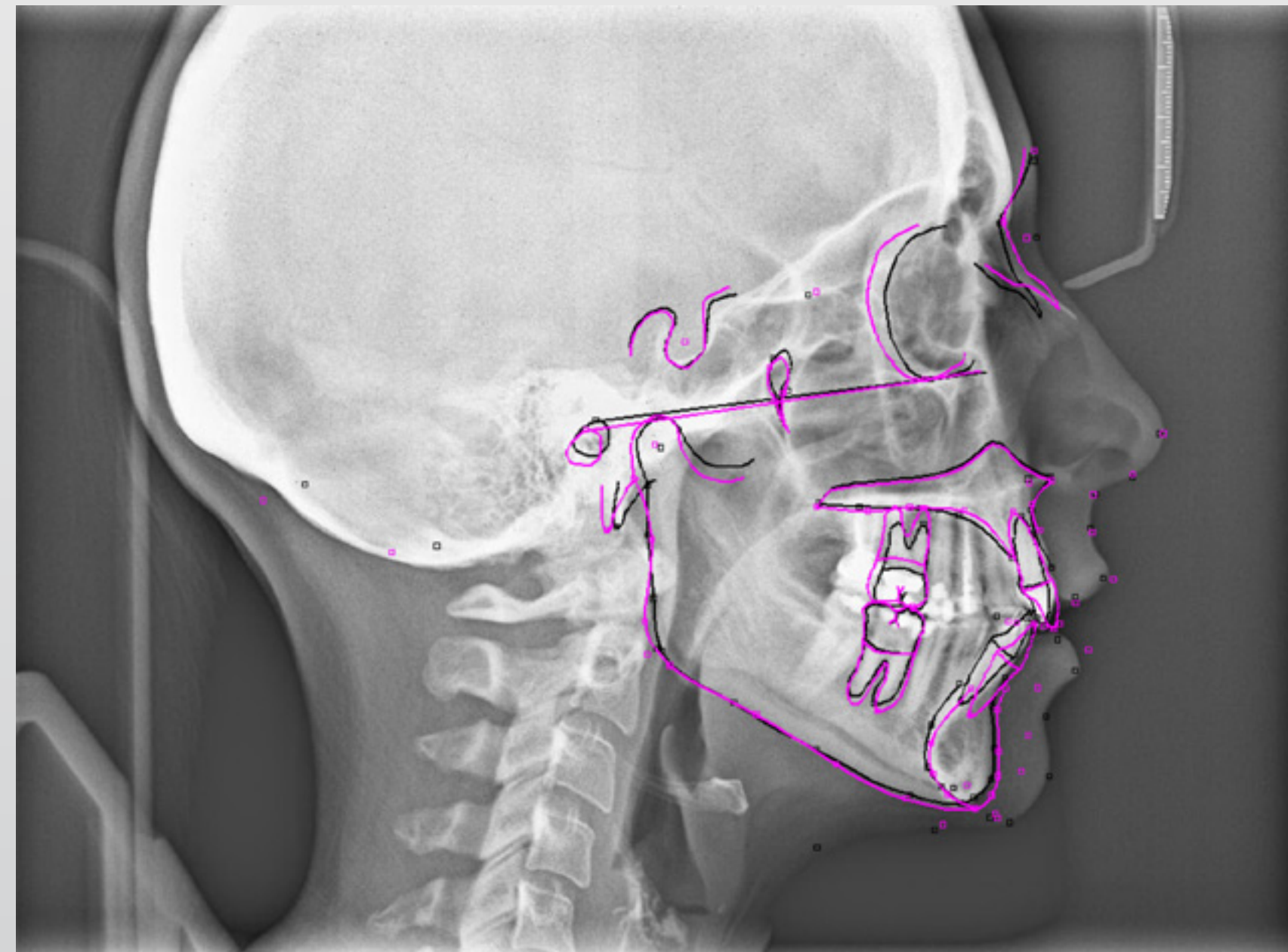
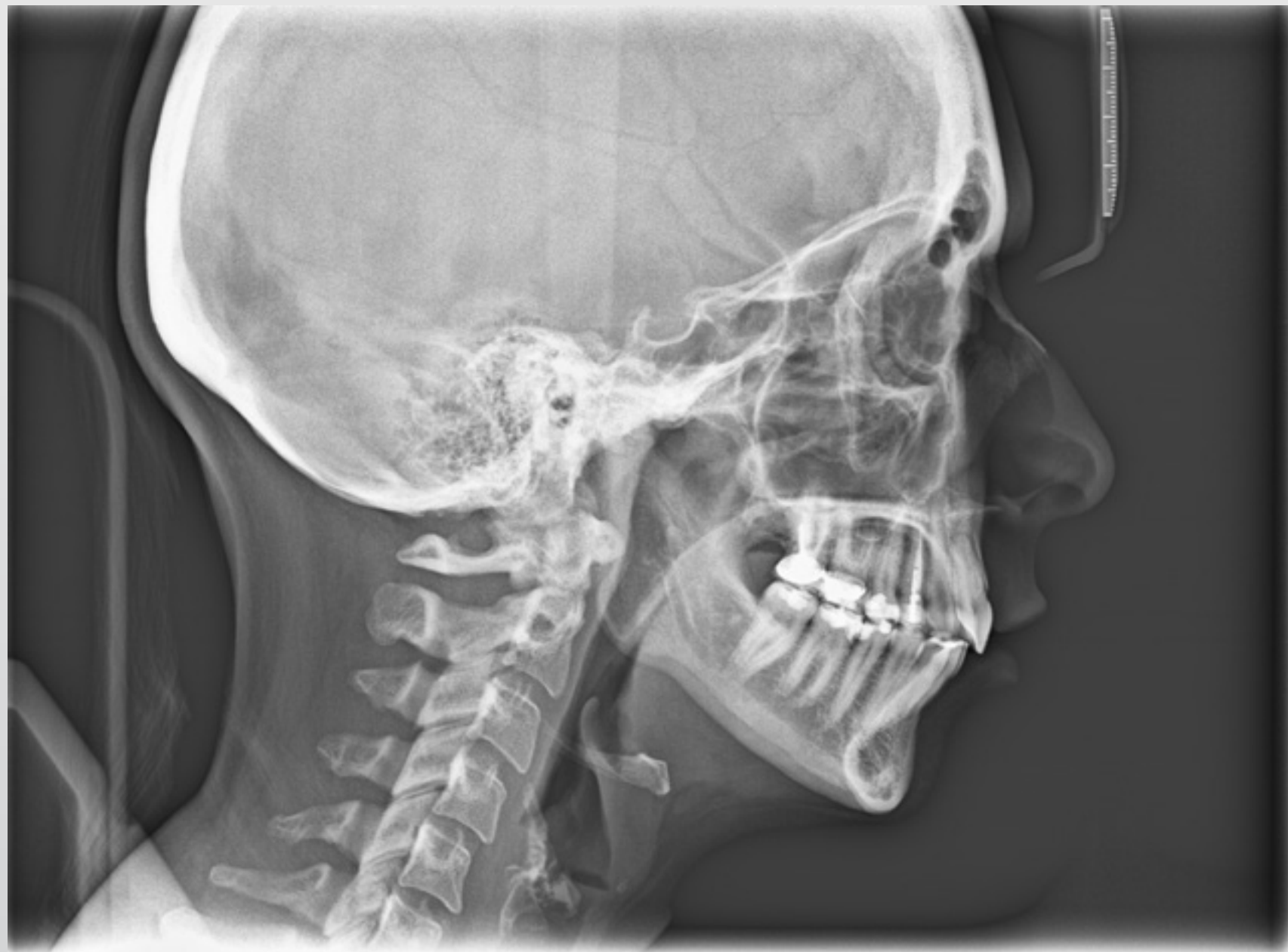Cephalometric radiograph



Initial



Final





Clarity™
Esthetic Orthodontic Solutions

Lateral Incisor Control

3M™ Clarity™ Aligners
Flex + Force



Tx Design Video

Treatment Plan
Attachment Strategy
Key Movements
Summary of Final Results

[Click here](#) to watch
10 minute video.

Ready to learn more?



Discover our proprietary new Clarity Aligners Flex Material!



See more cases from your peers on our Clinical Cases website!



Learn more about the Clarity Aligners system!



Rediscover the Oral Care Portal, submit a case today!