

Case Study: 3M™ Clarity™ Aligners

Treating a deep bite with mild crowding.

Age: 12

Chief concern: Mild upper crowding and lower crowding with a deep bite

Case diagnostics: Slight Class I malocclusion, overbite 100%, overjet of 2mm, mild crowding upper and lower, slightly narrow both upper and lower, mildly excessive gingival display, slightly retrognathic skeletally

Total number of aligners: 36 active aligners + 3 passive aligners

Wear interval: 7 days

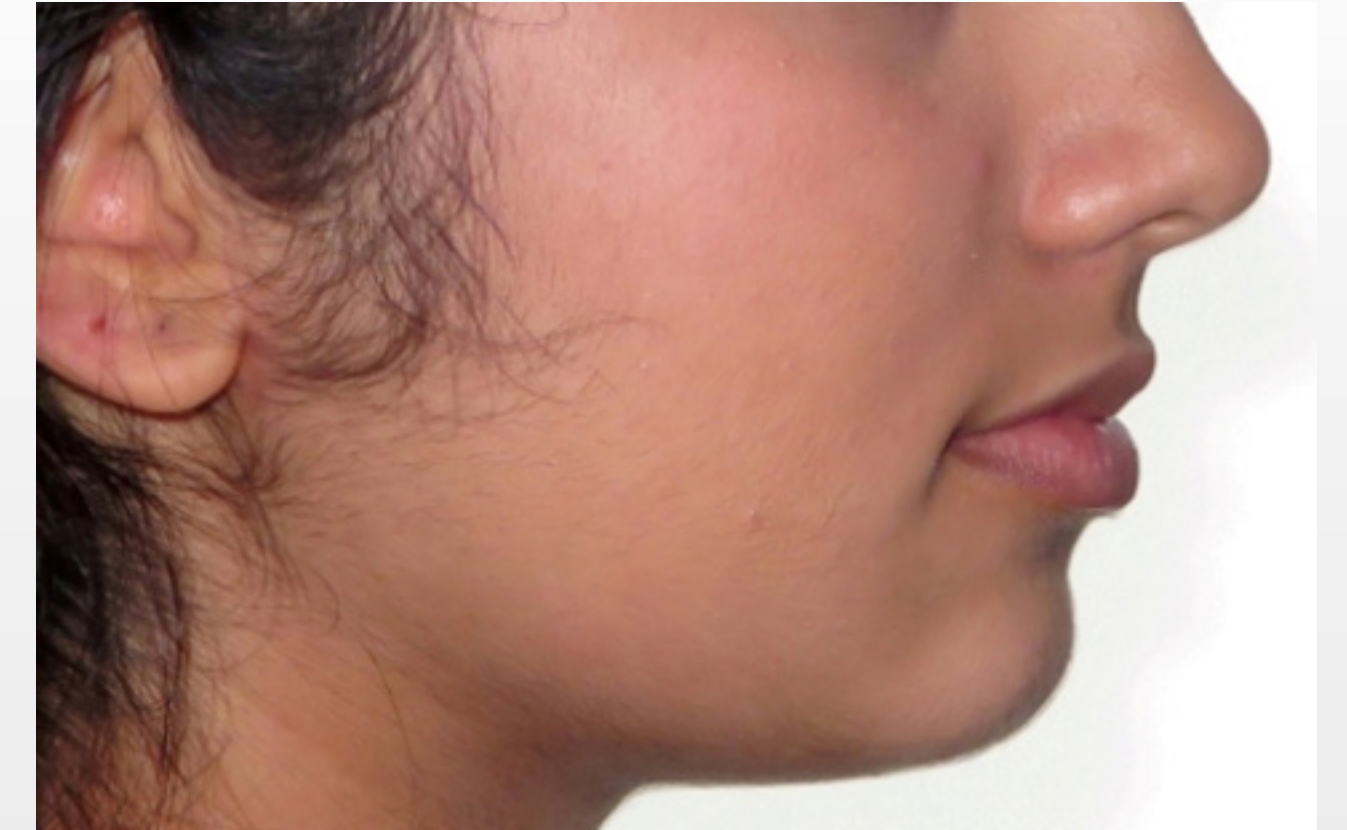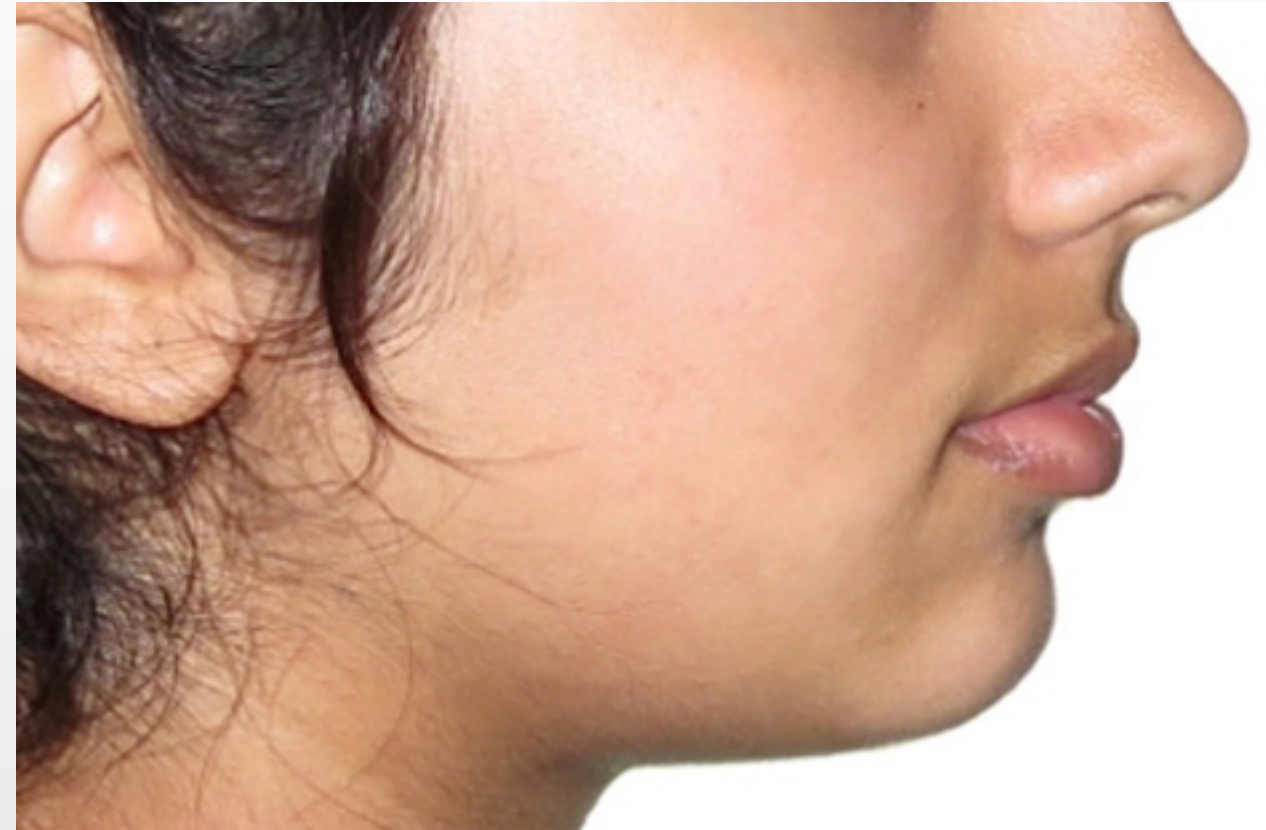Treatment time: 16 months

Case courtesy of:
Dr. Christian Groth
Birmingham, MI – USA

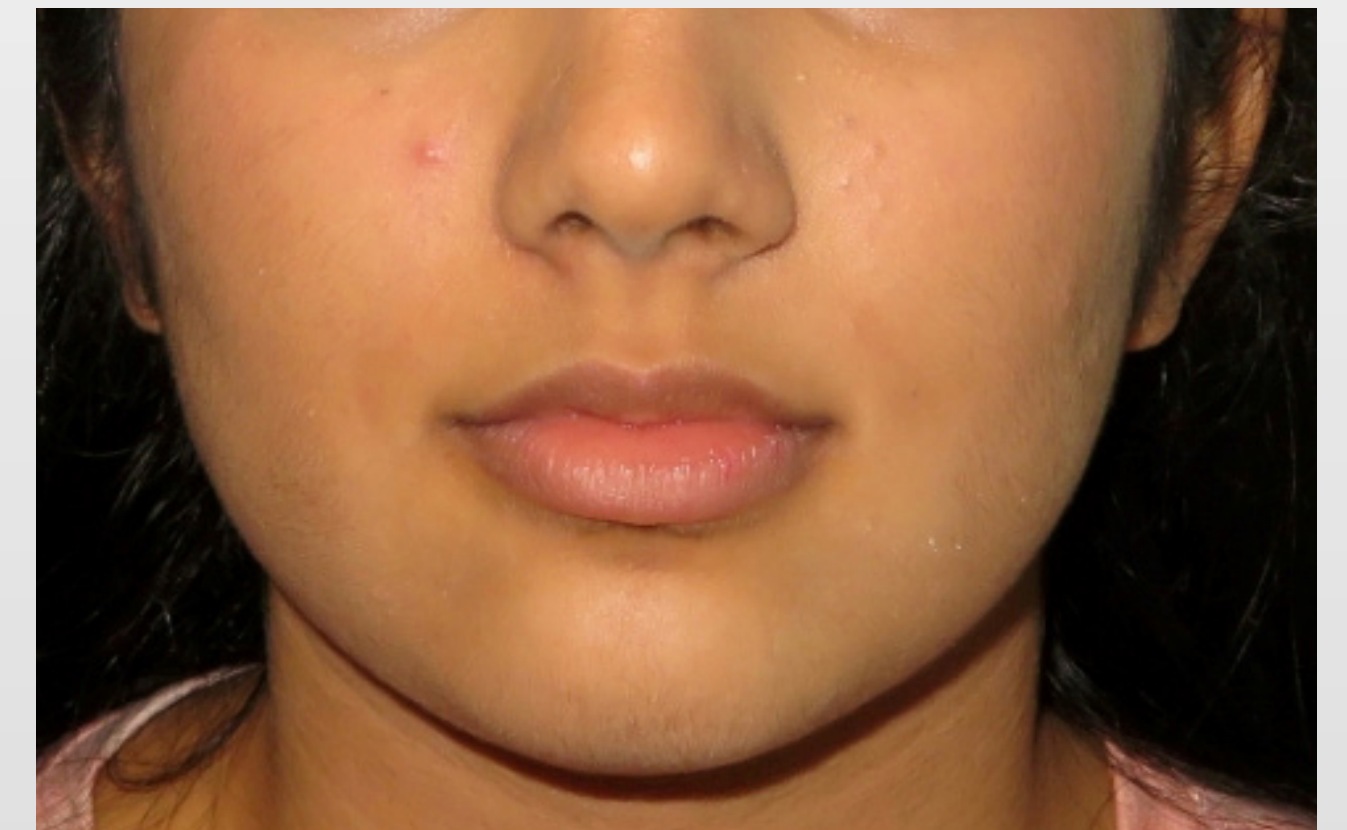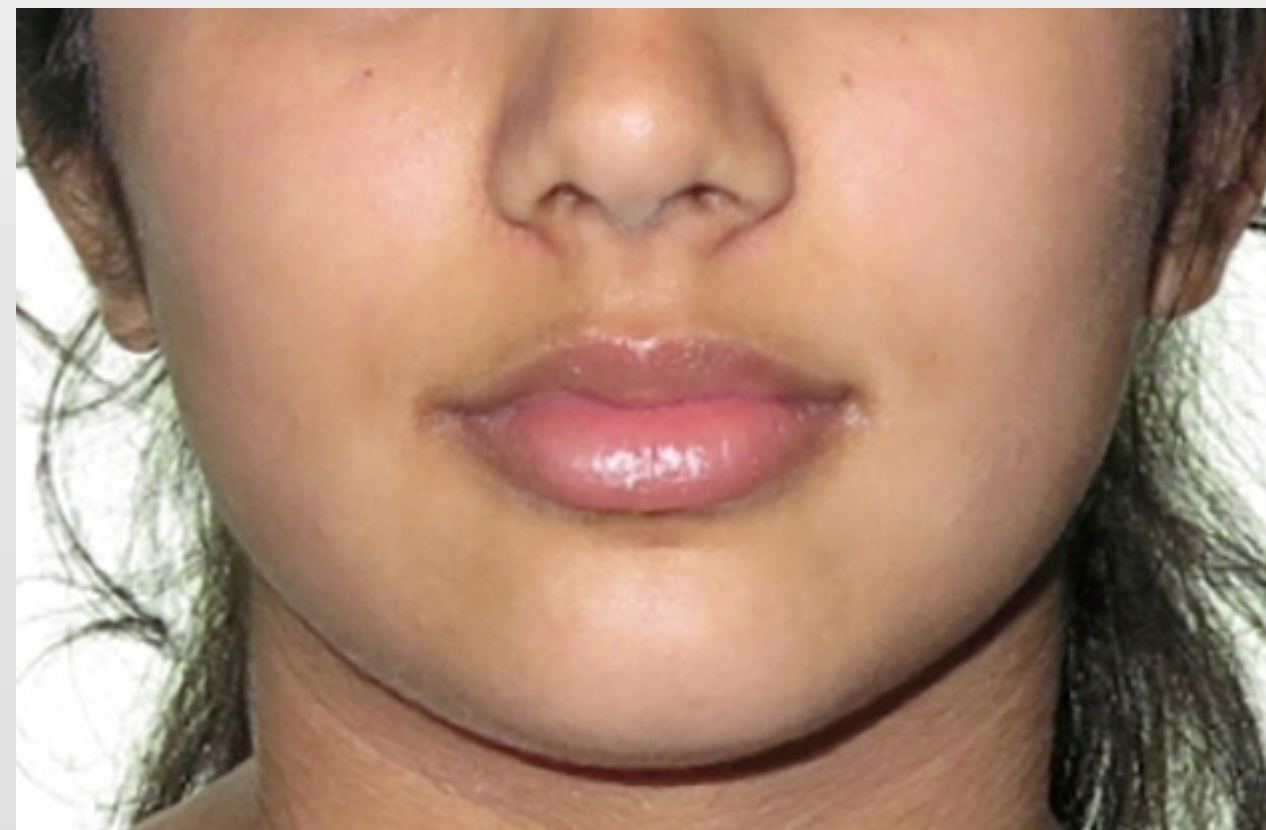Initial

Final

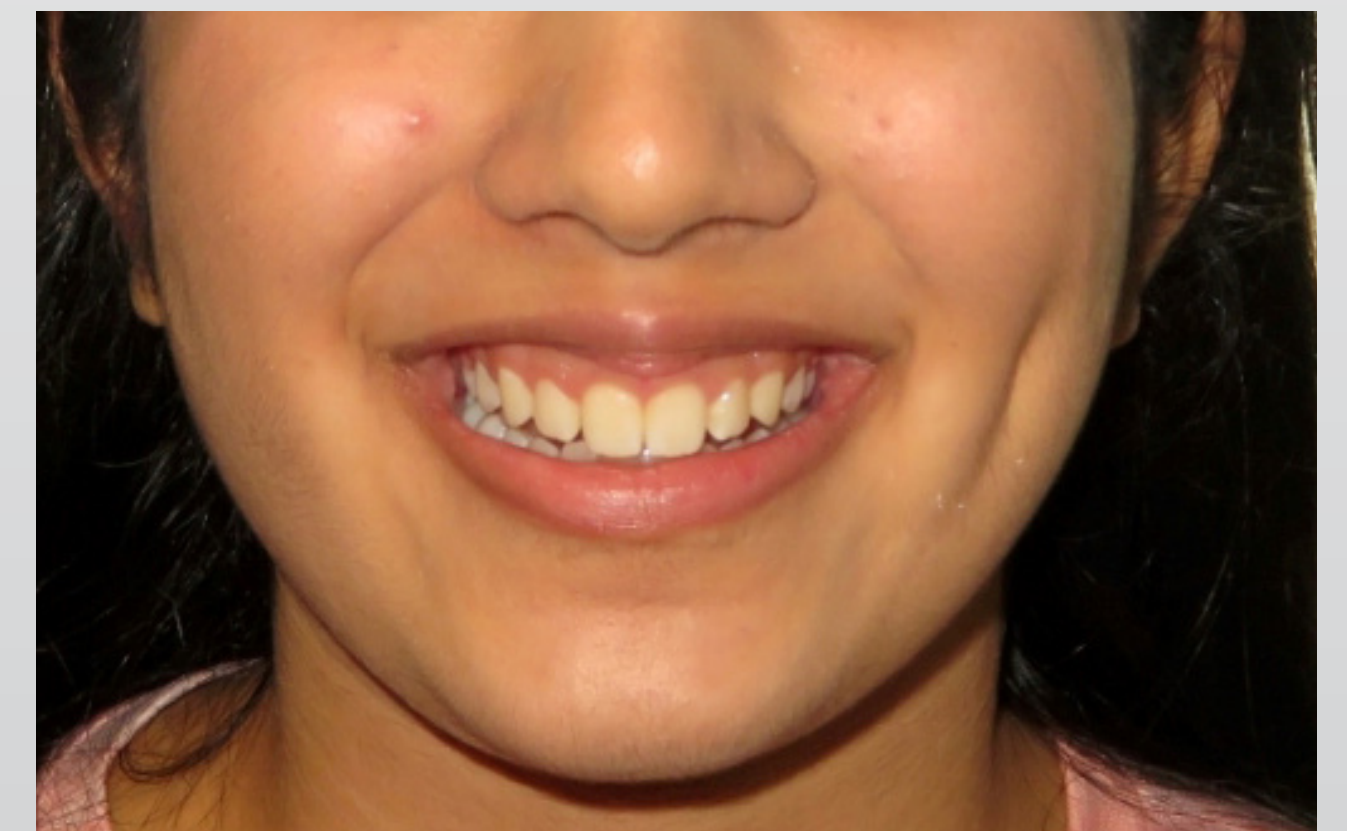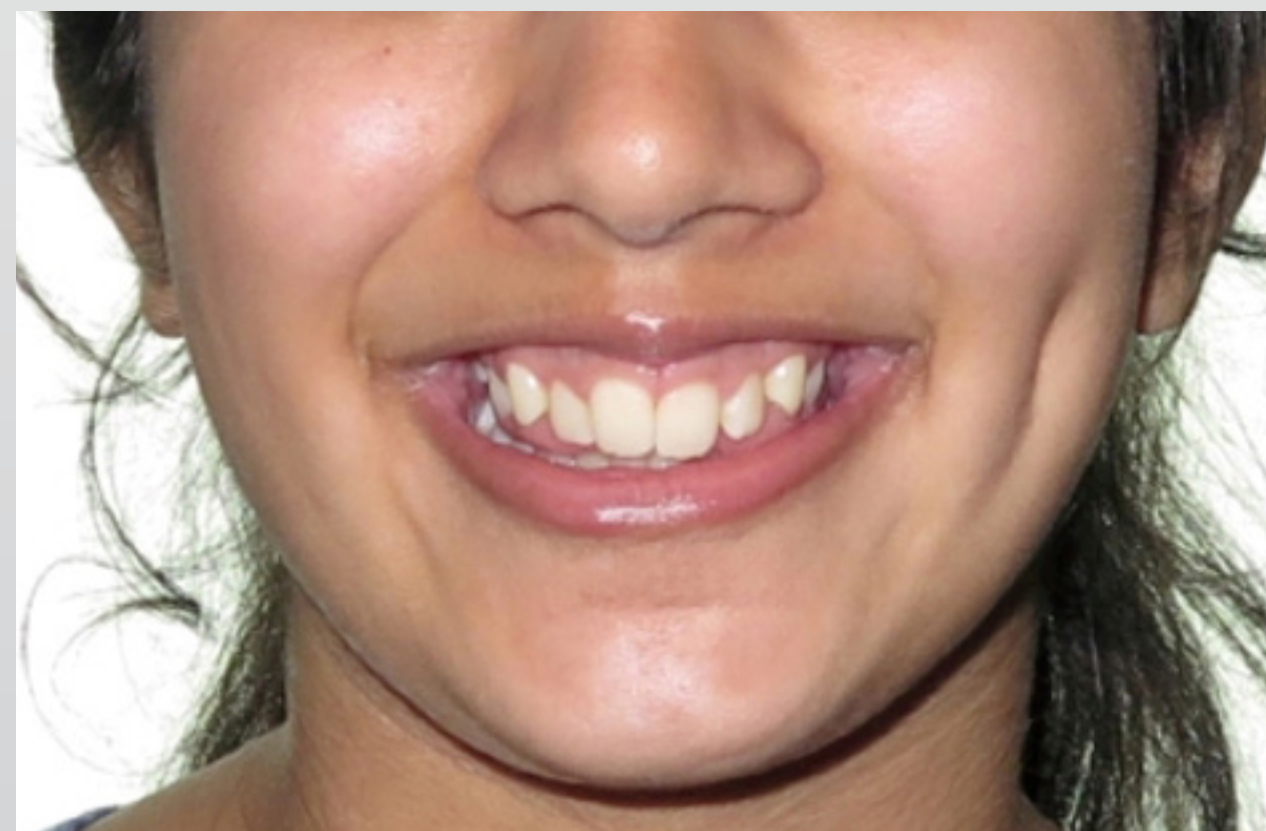Profile at rest



Face at rest



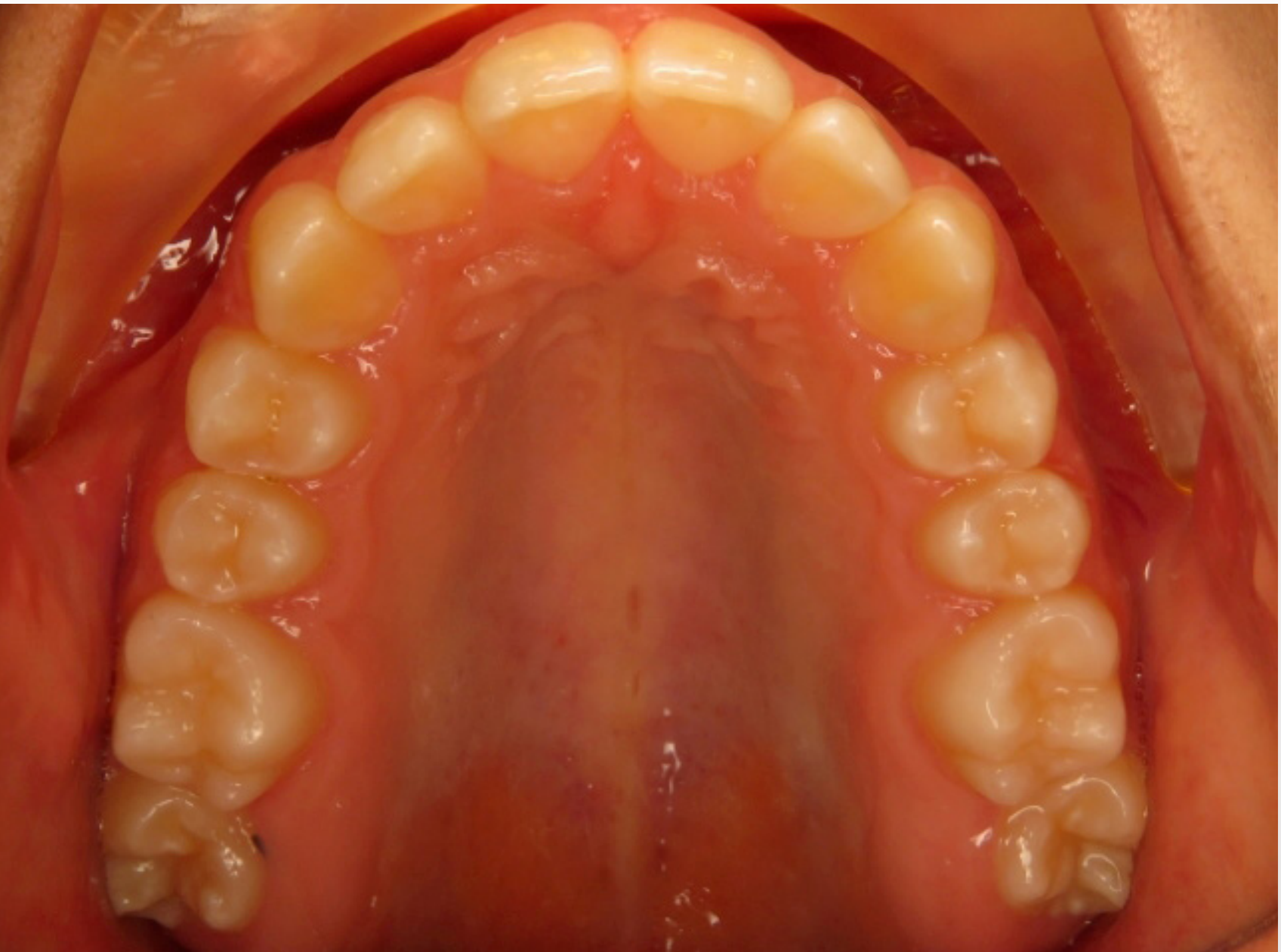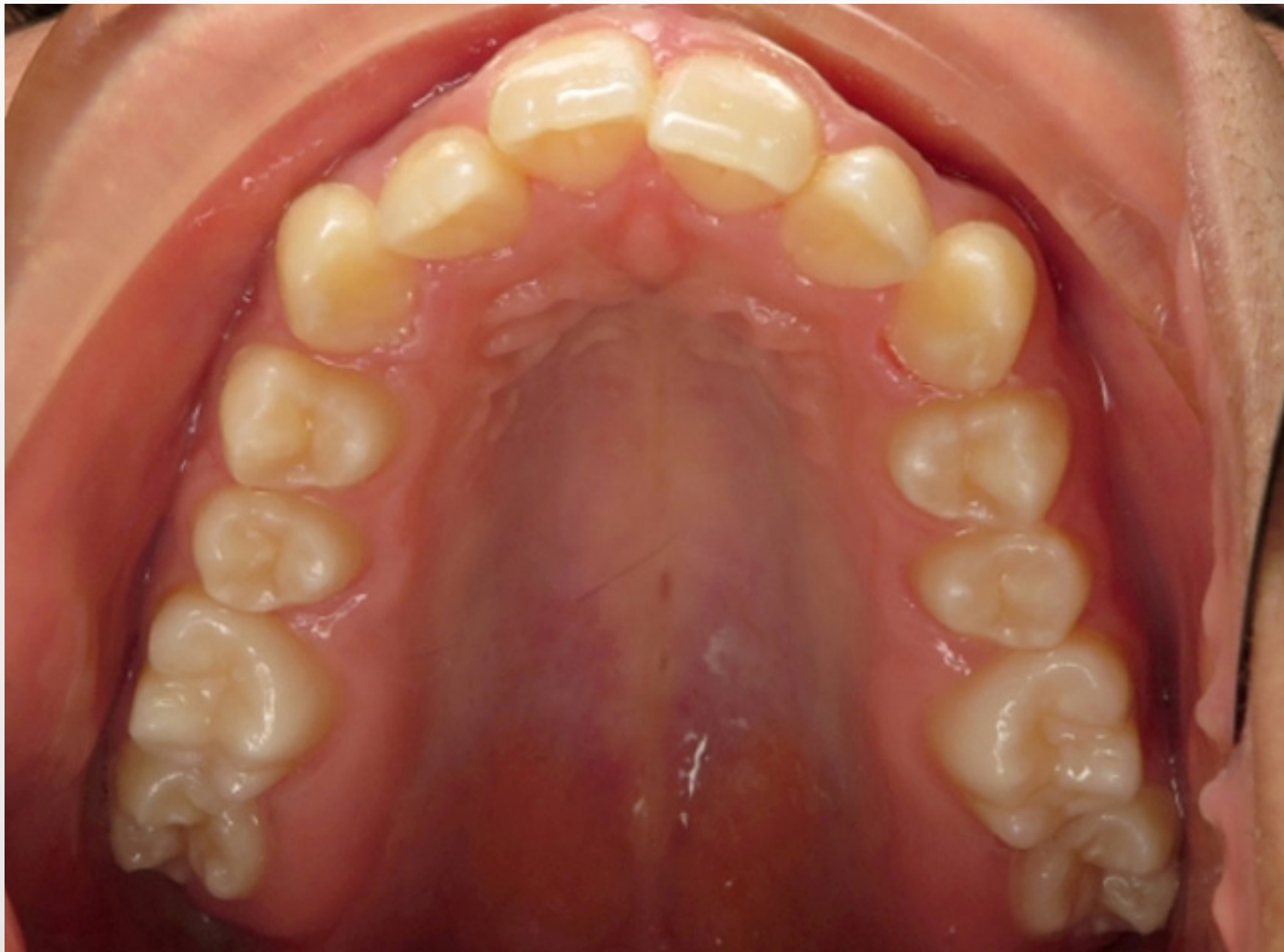Face smiling



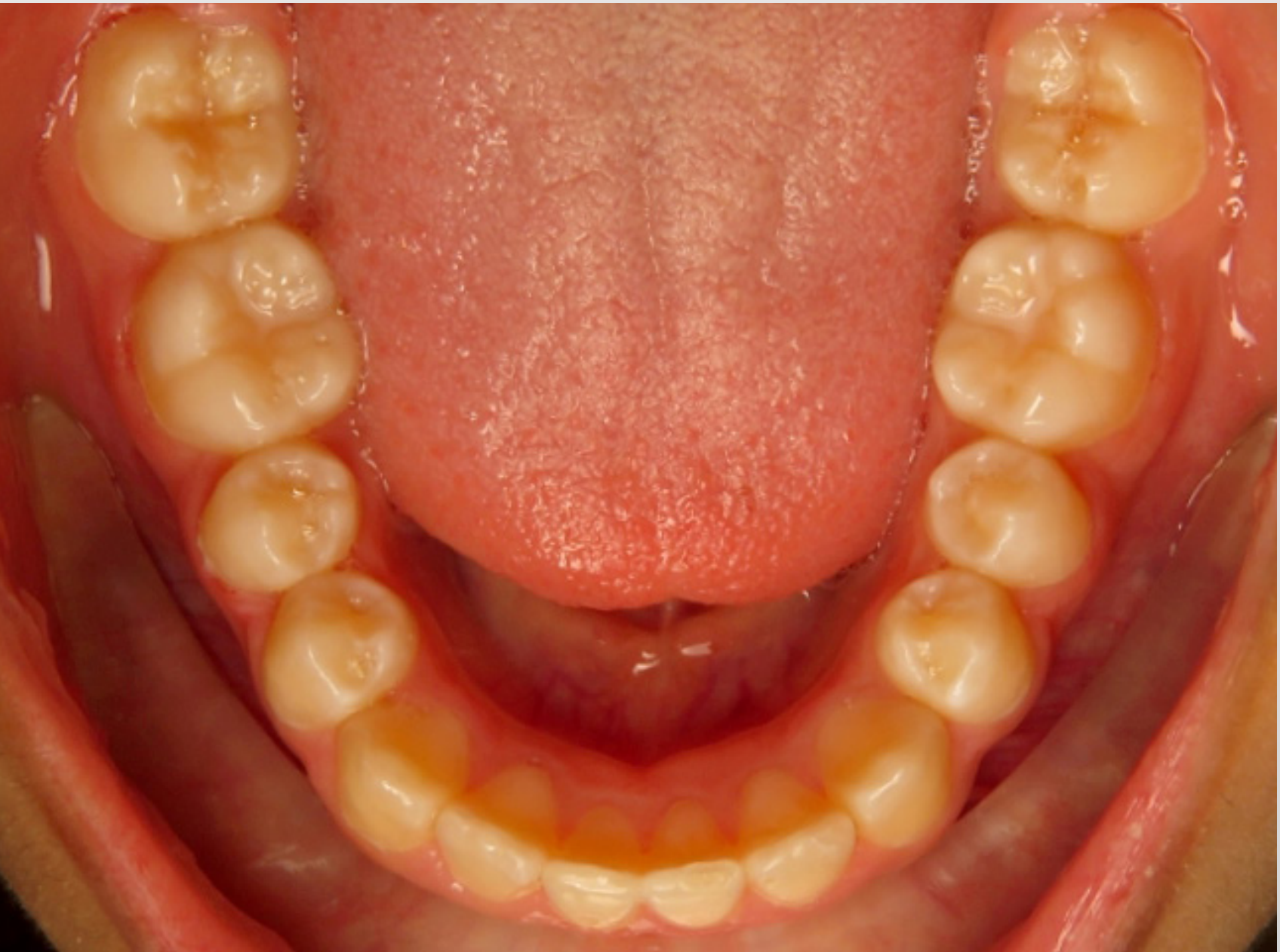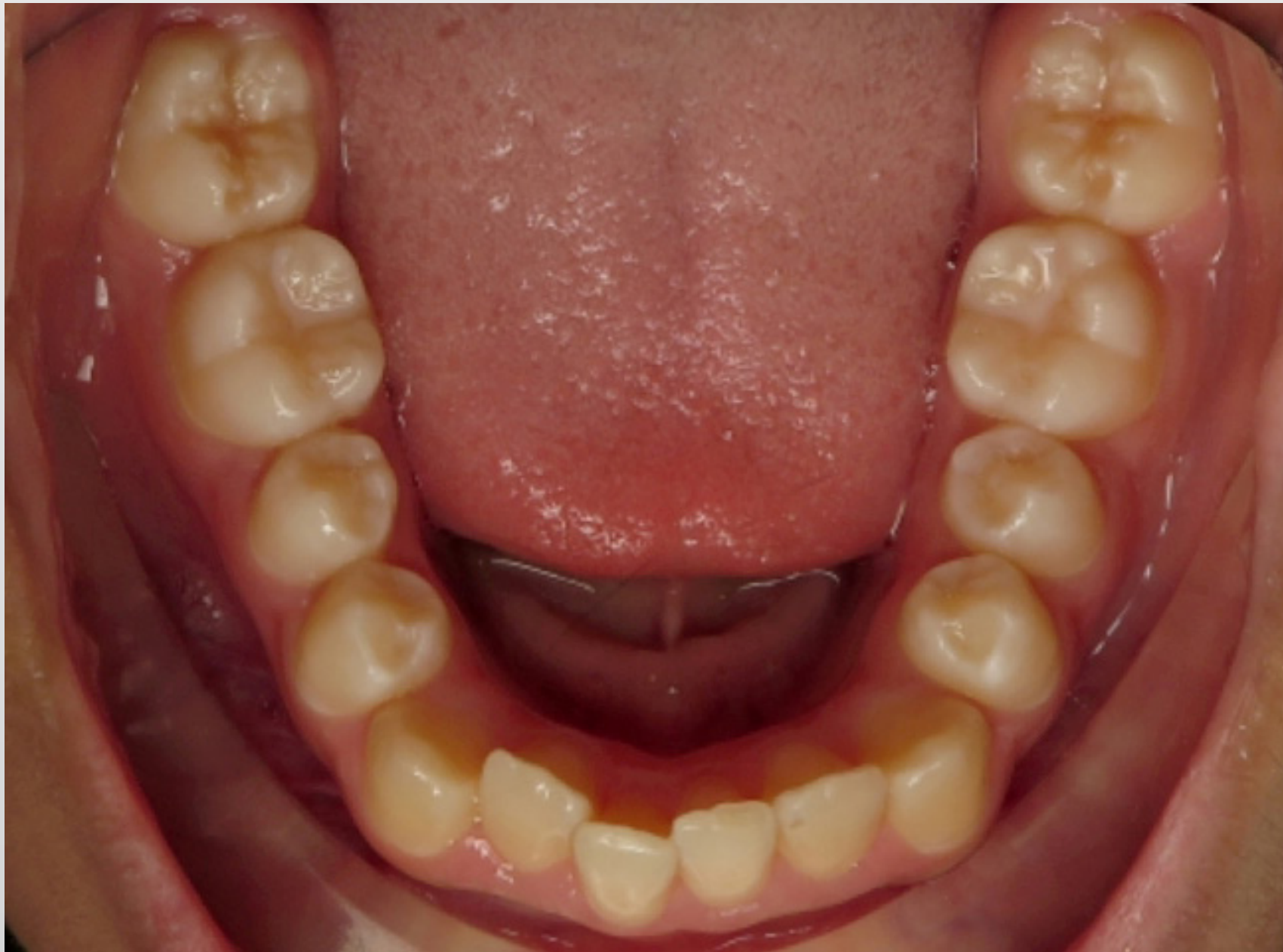
Initial

Final

**Occlusal –
maxillary**



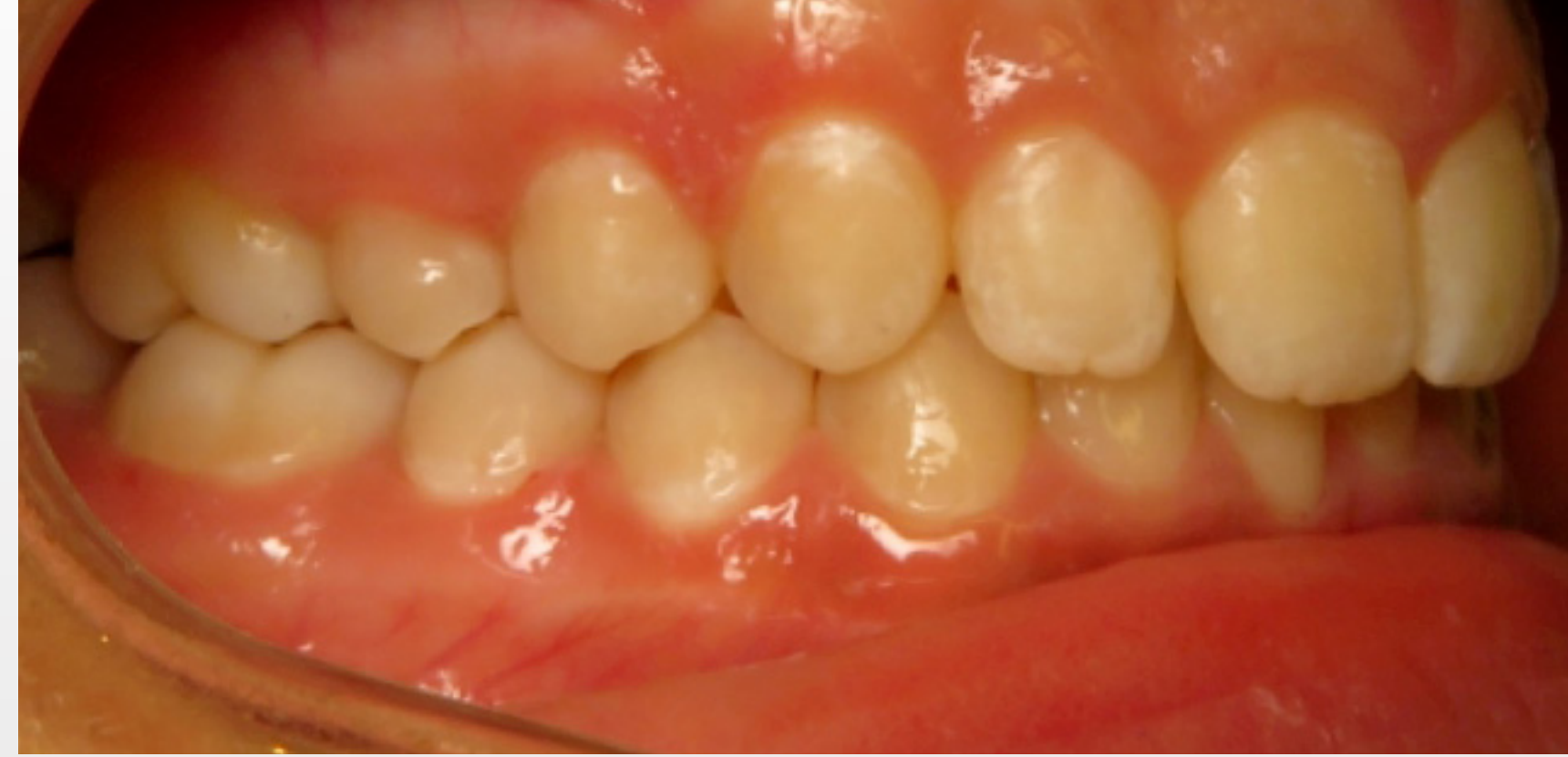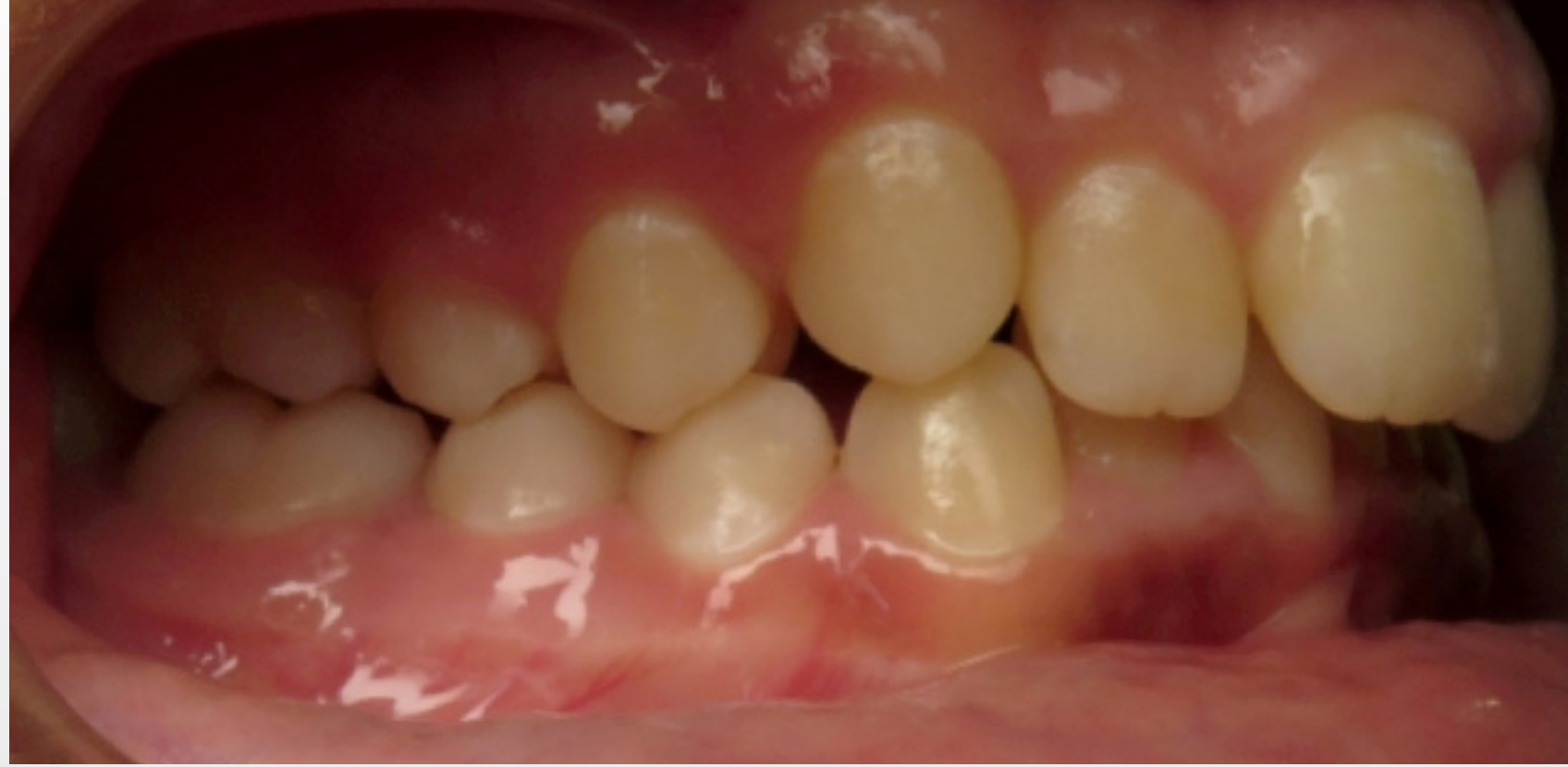**Occlusal –
mandibular**



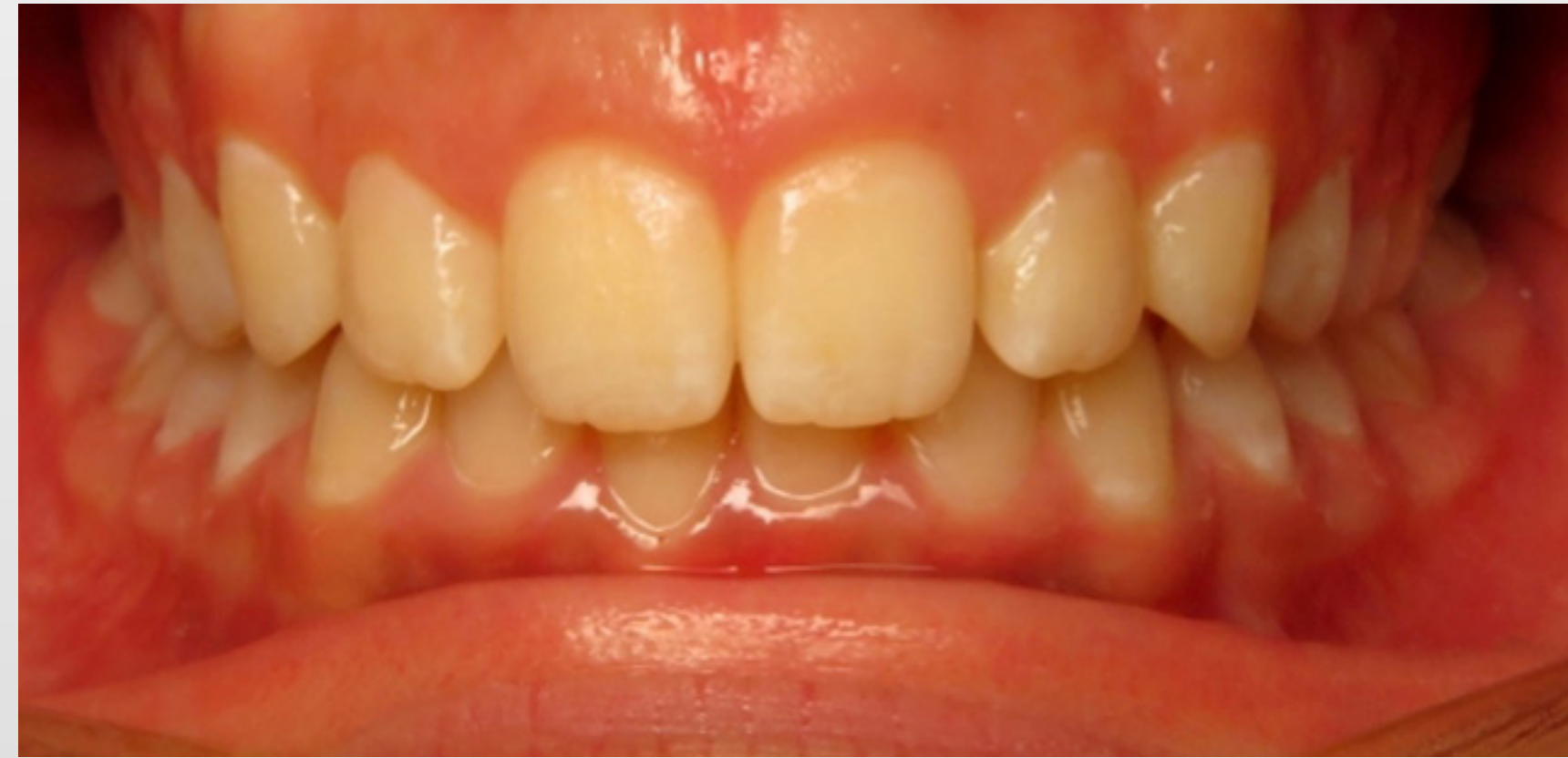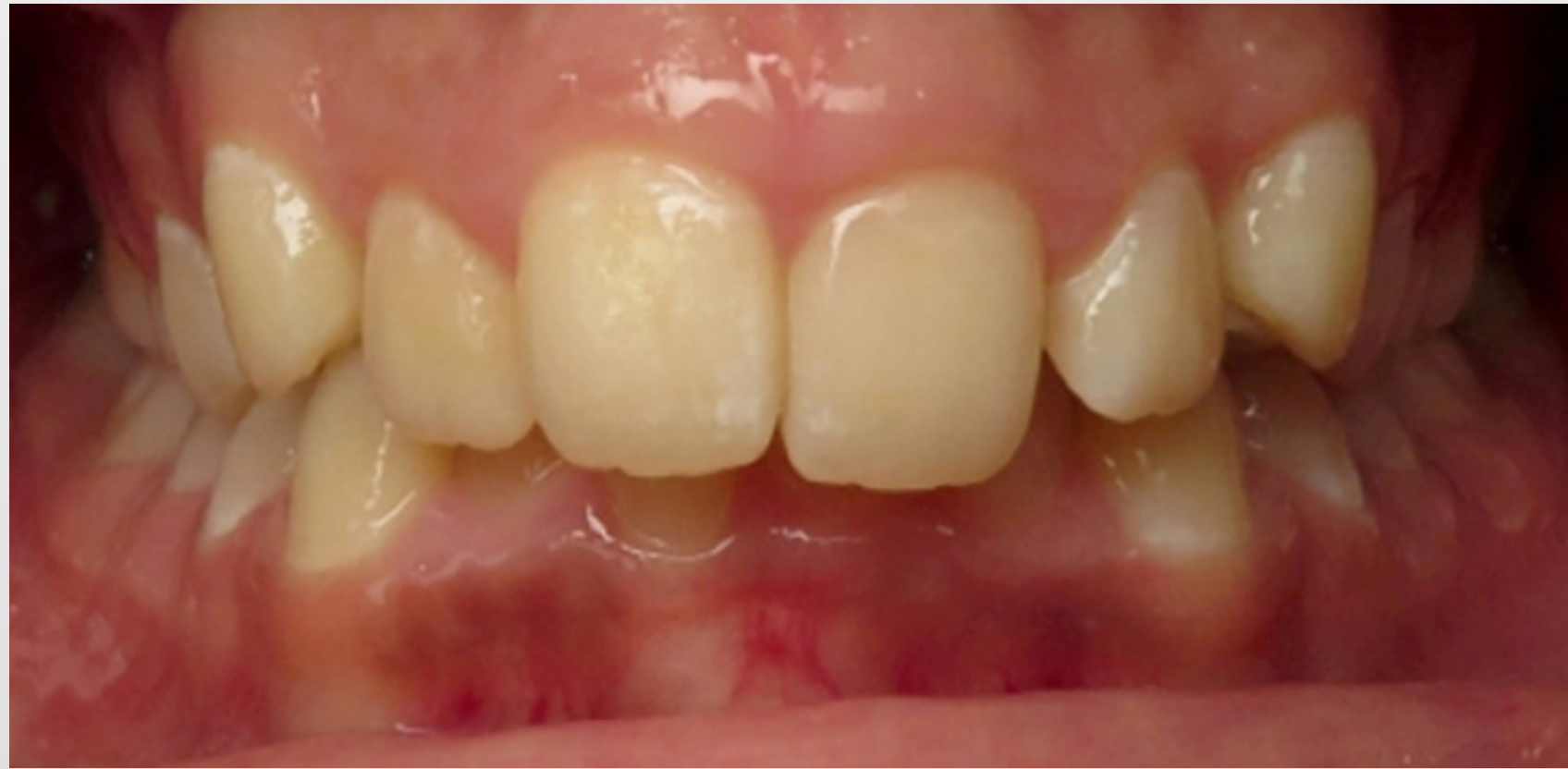Initial

Final

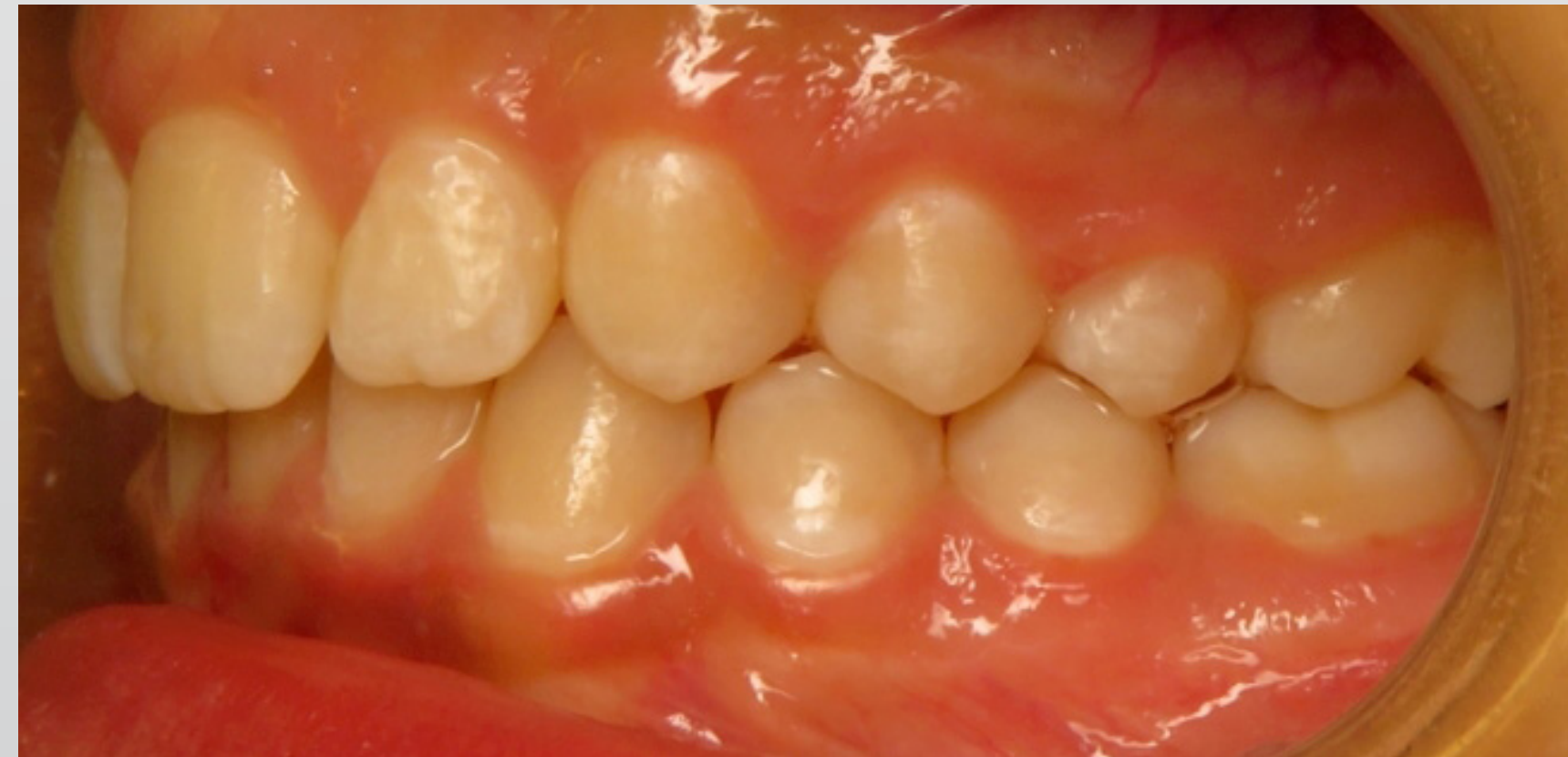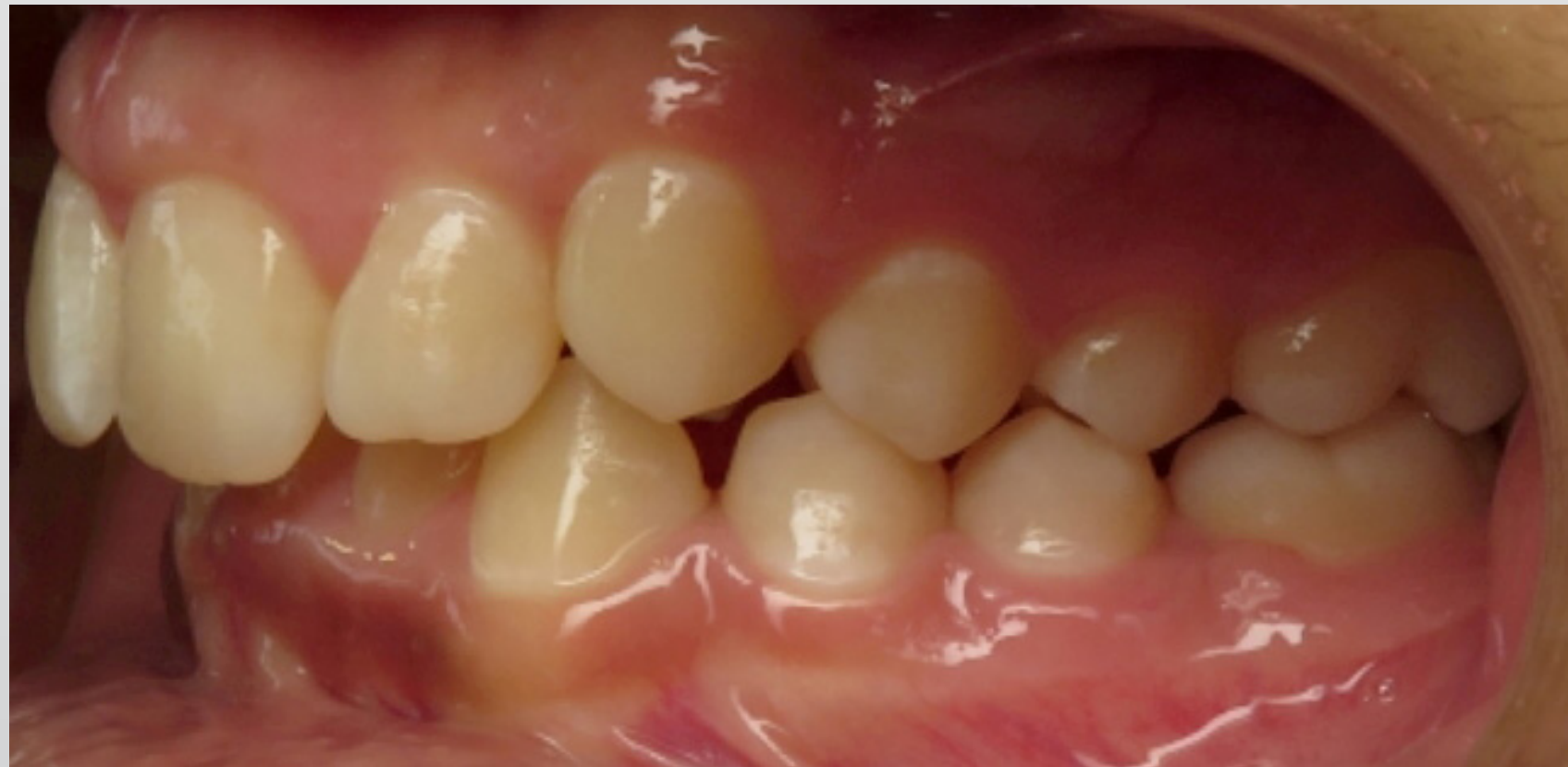**Retracted
buccal – right**



**Retracted
anterior biting**



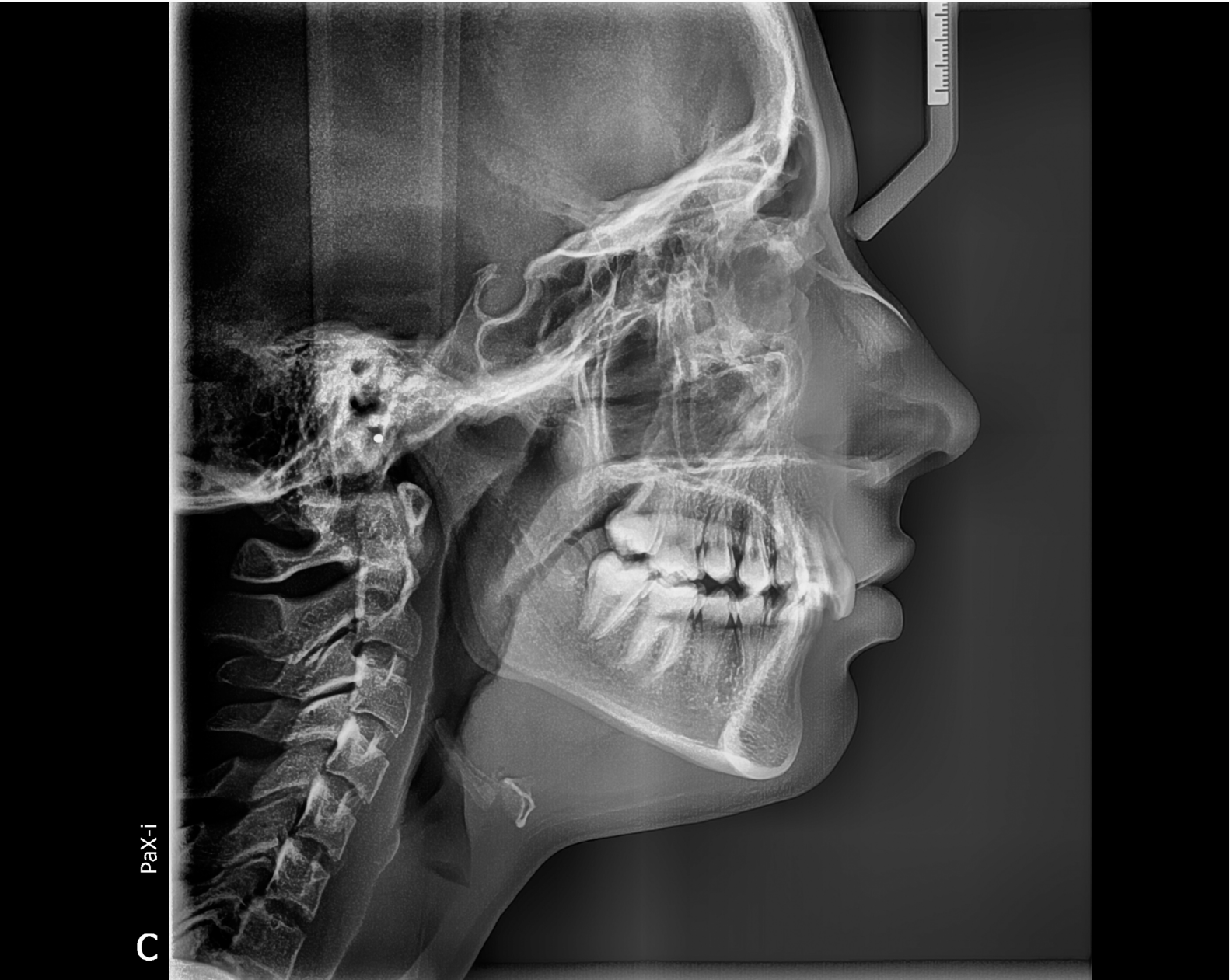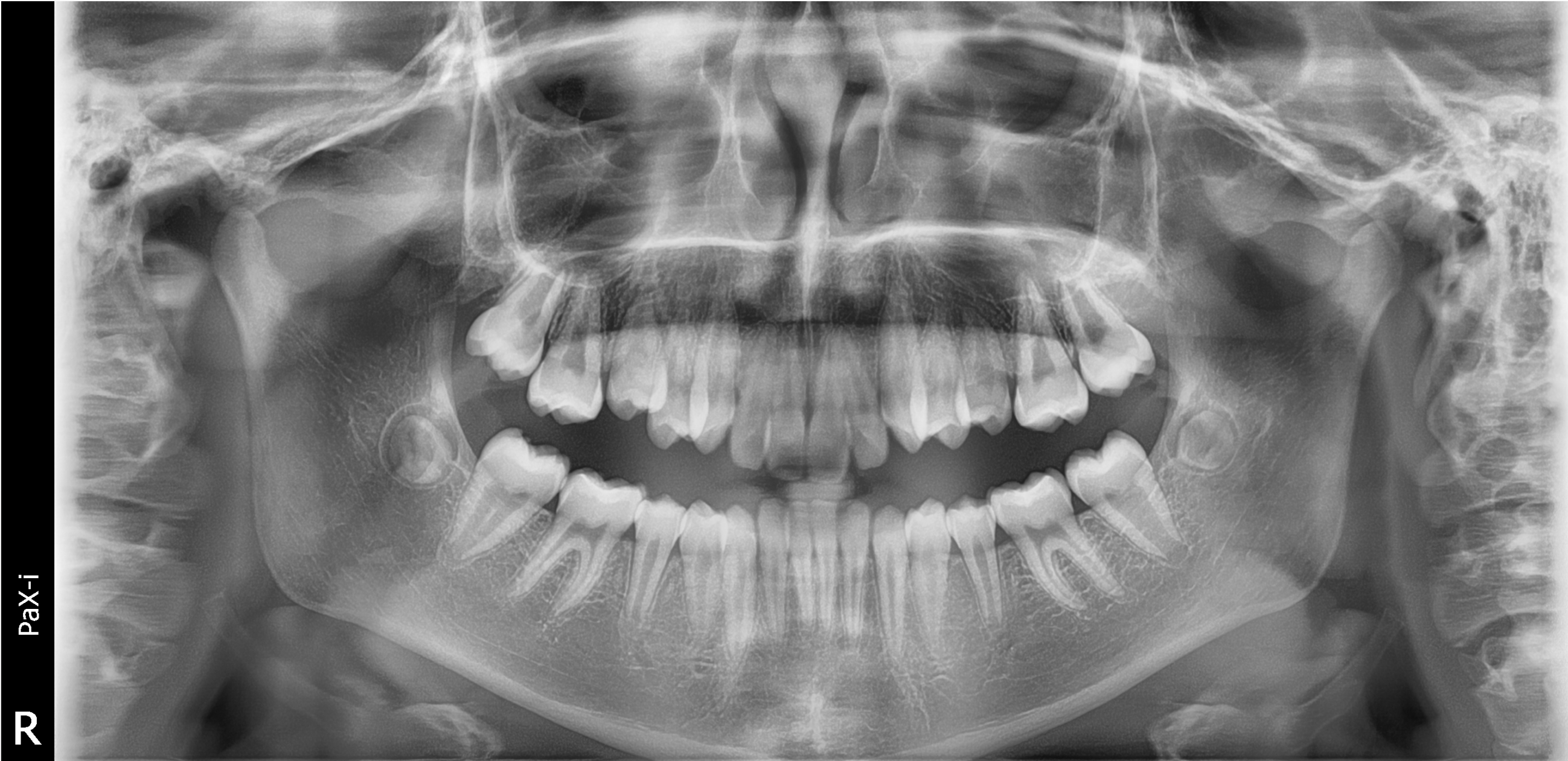**Retracted
buccal – left**



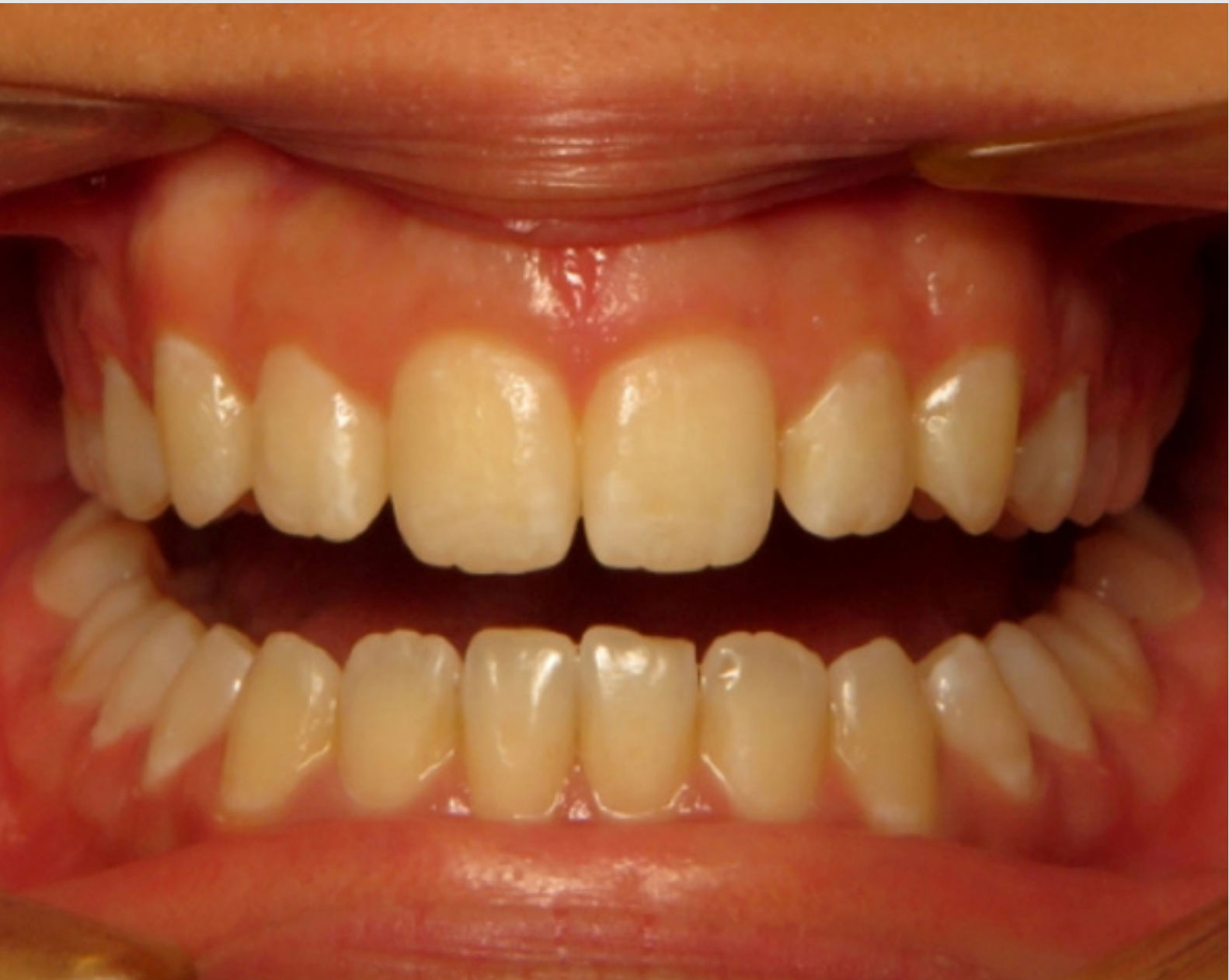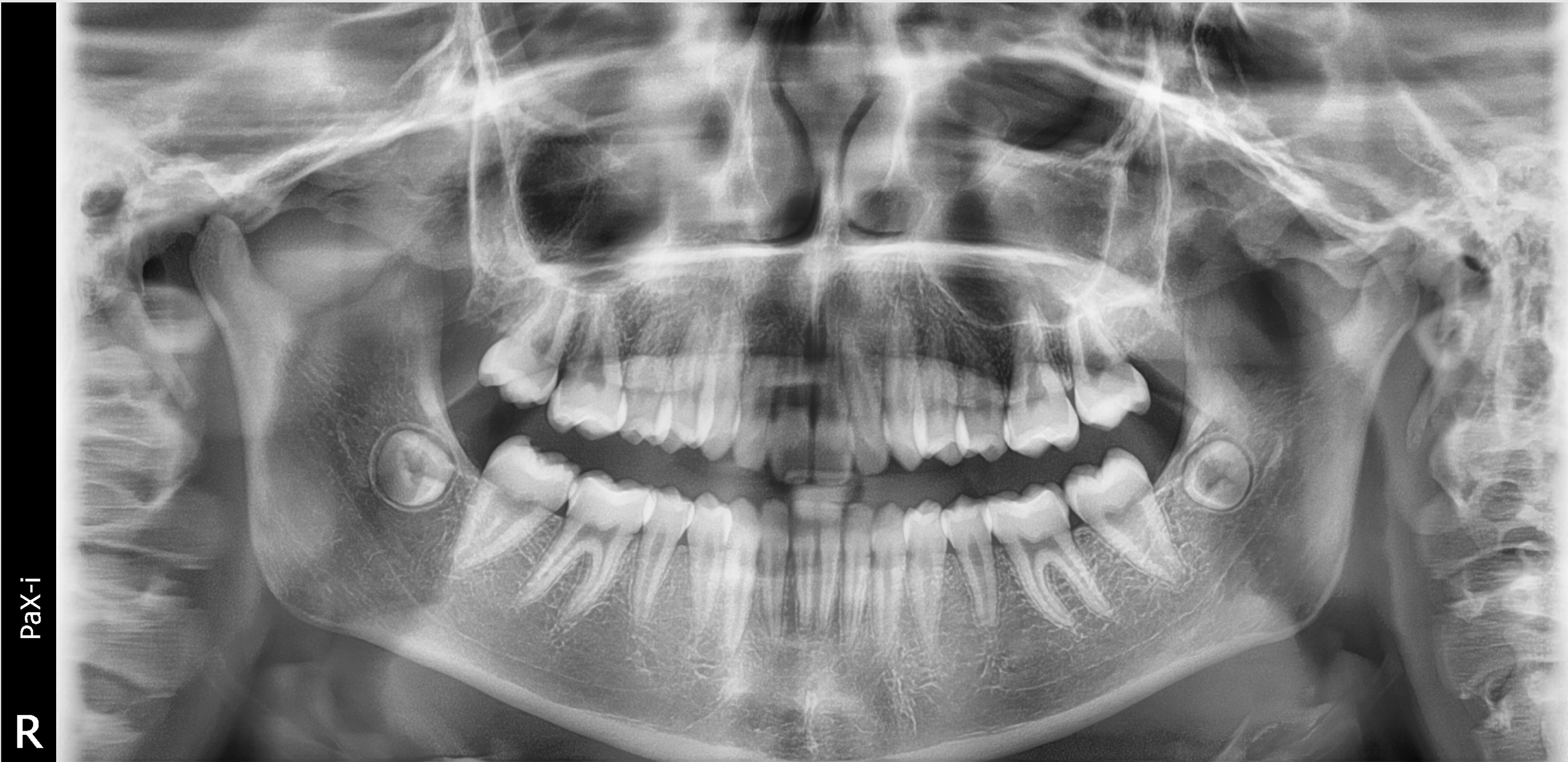Panoramic radiograph

Ceph. / Anterior open

Initial



Final



Tx Design Video

- Treatment Plan
- Attachment Strategy
- Key Movements
- Summary of Final Results

