

Case Study: 3M™ Clarity™ Aligners

Correction of relapsed anterior open bite with reverse smile arc

Age: 25

Chief concern: My teeth don't touch in the front and having trouble eating

Case diagnostics: Facial: Good facial symmetry and a balanced, orthognathic profile. Very mild lip incompetence. Esthetics: Insufficient gingival display and an inverted smile arc. Maxillary midline was aligned with the facial midline. Maxilla and Mandible: No crowding or spacing. Occlusion: End to end Class II on the right, and Class I on the left. Dentition: Healthy and great oral hygiene. Midline: The mandibular midline was 1 mm right of the maxillary midline. Radiographic Findings: Mild external resorption on the facial of #25.

Total number of aligners: 56 (42 initial Tx Design, 14 Refinement #1)

Wear interval: 7 days

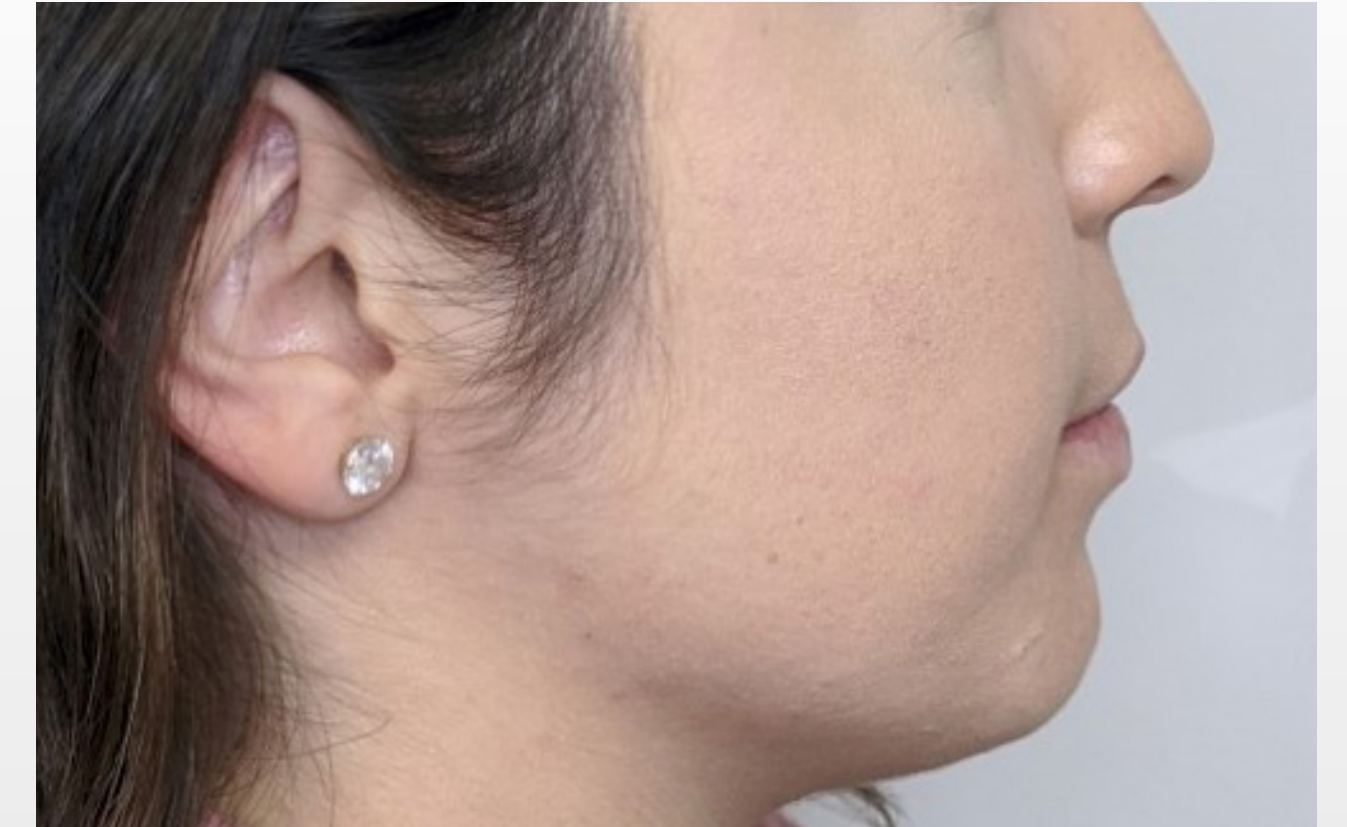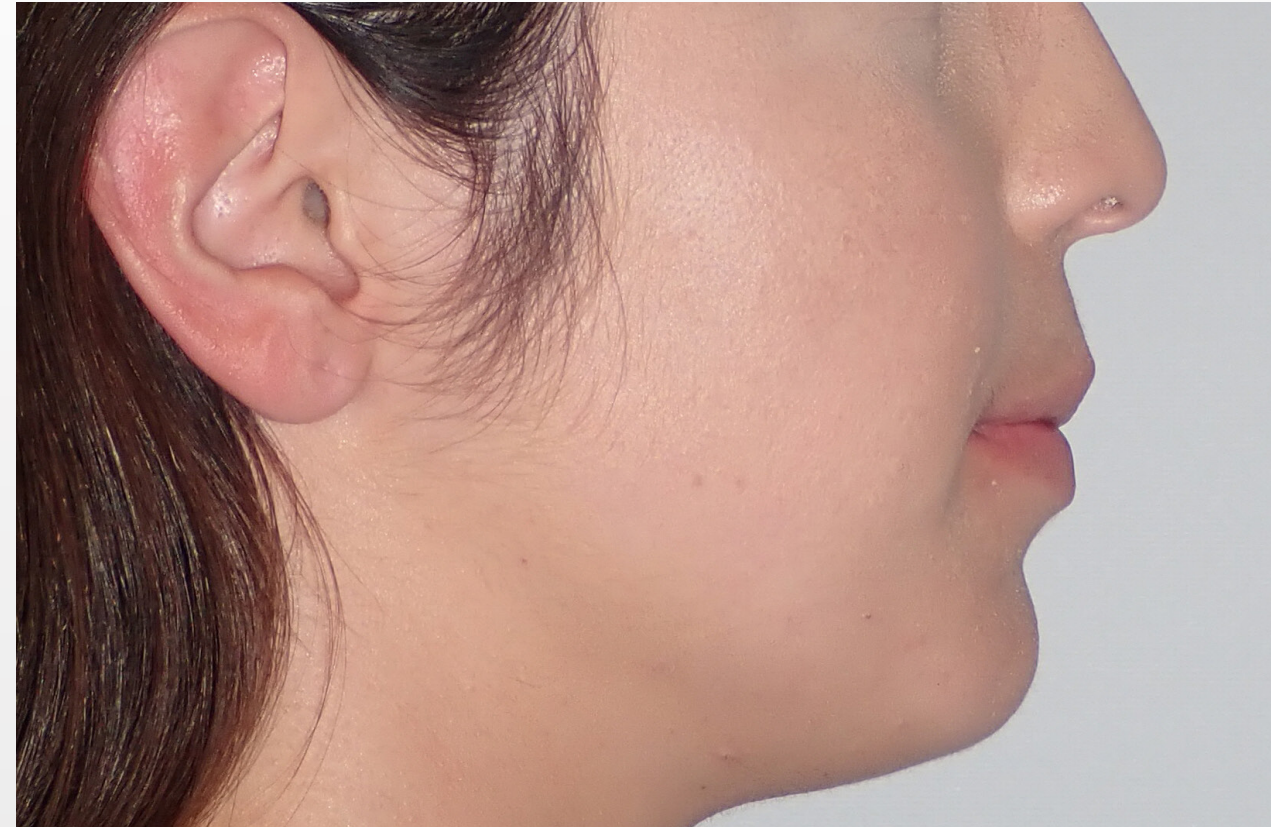Treatment time: 13 months

Case courtesy of:
Dr. Vanessa Peterson
Rancho Cucamonga, CA – USA

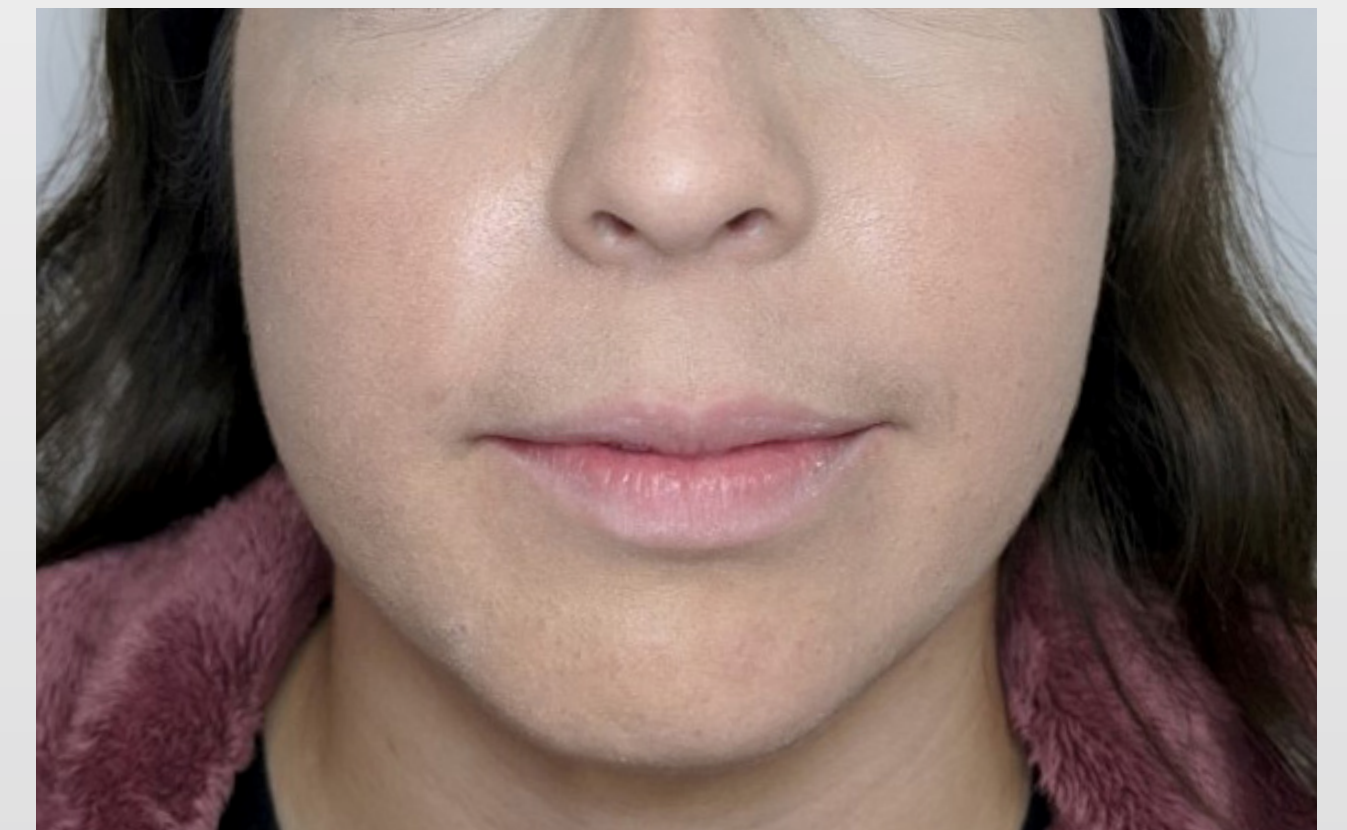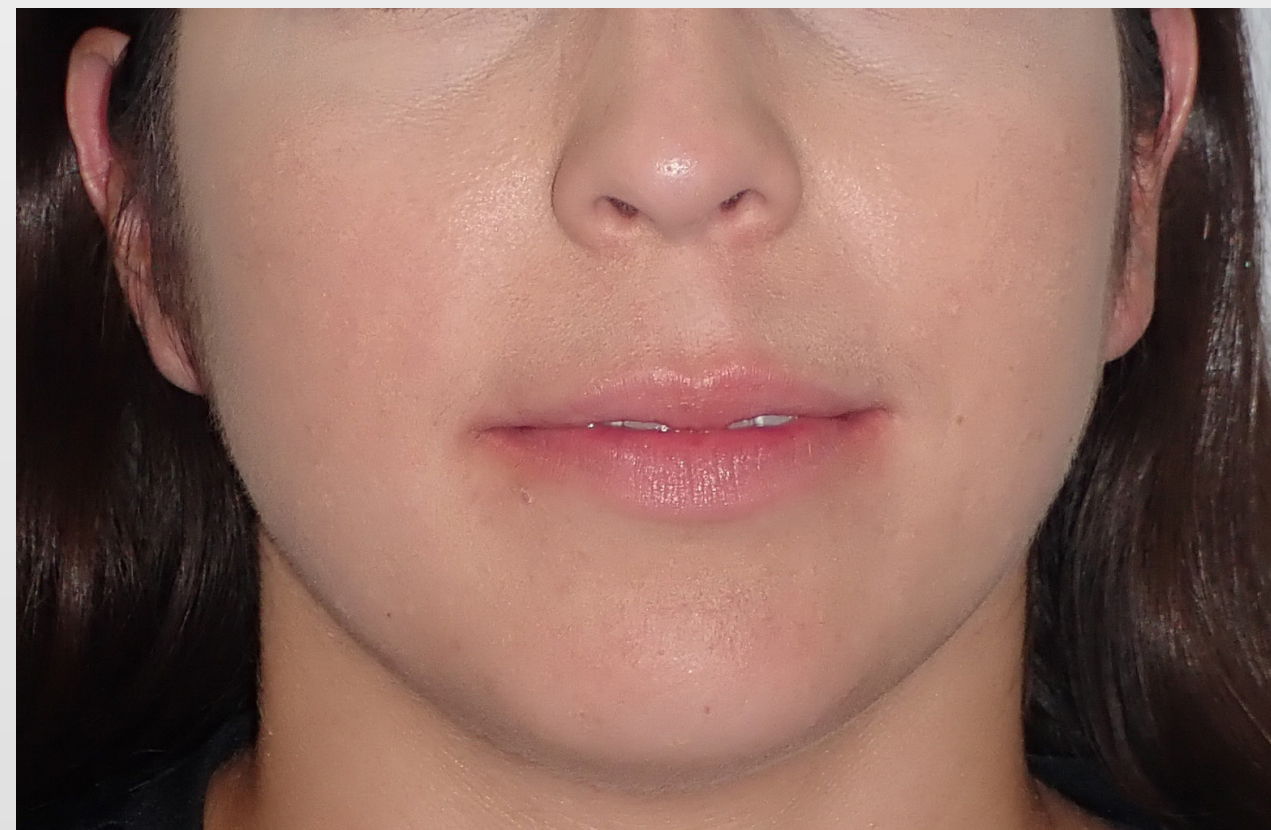Initial

Final

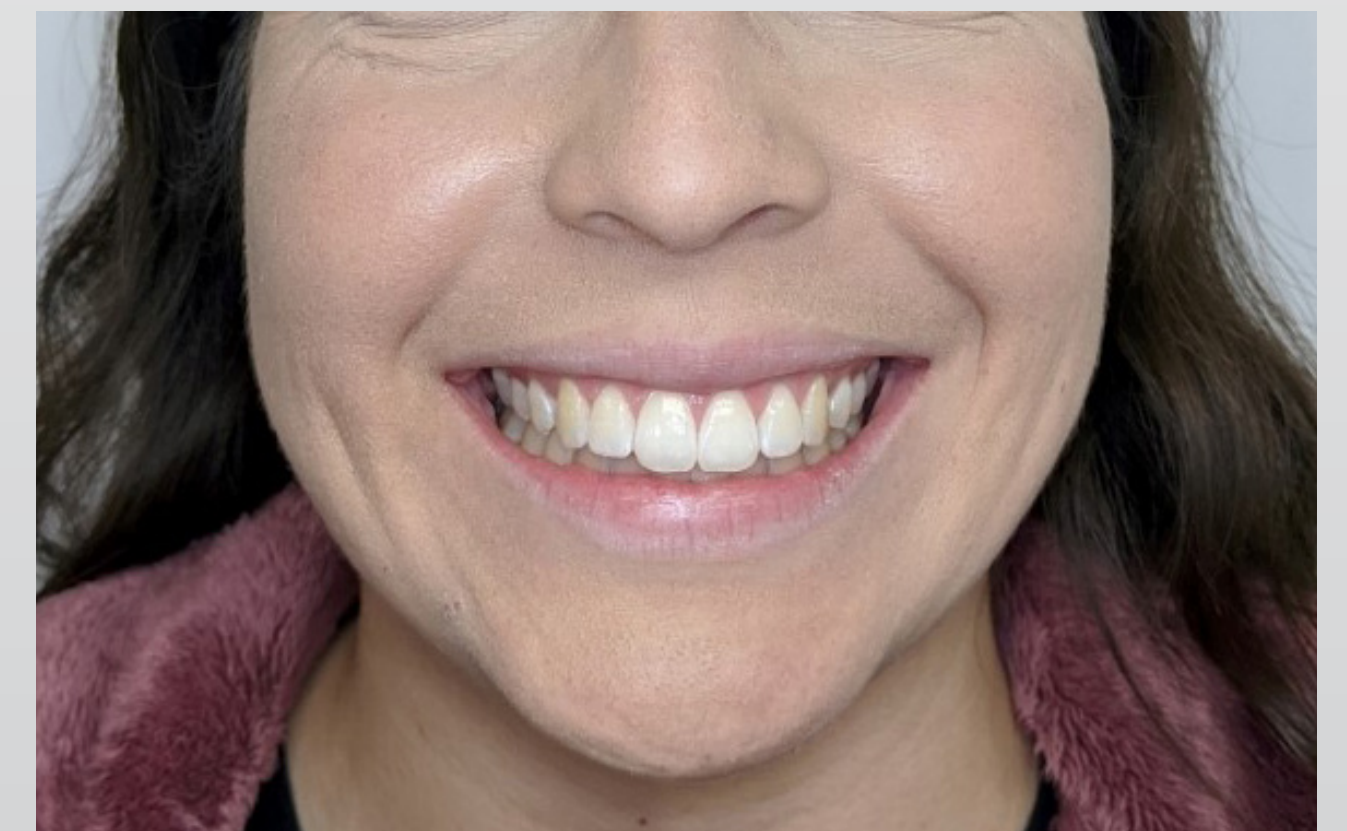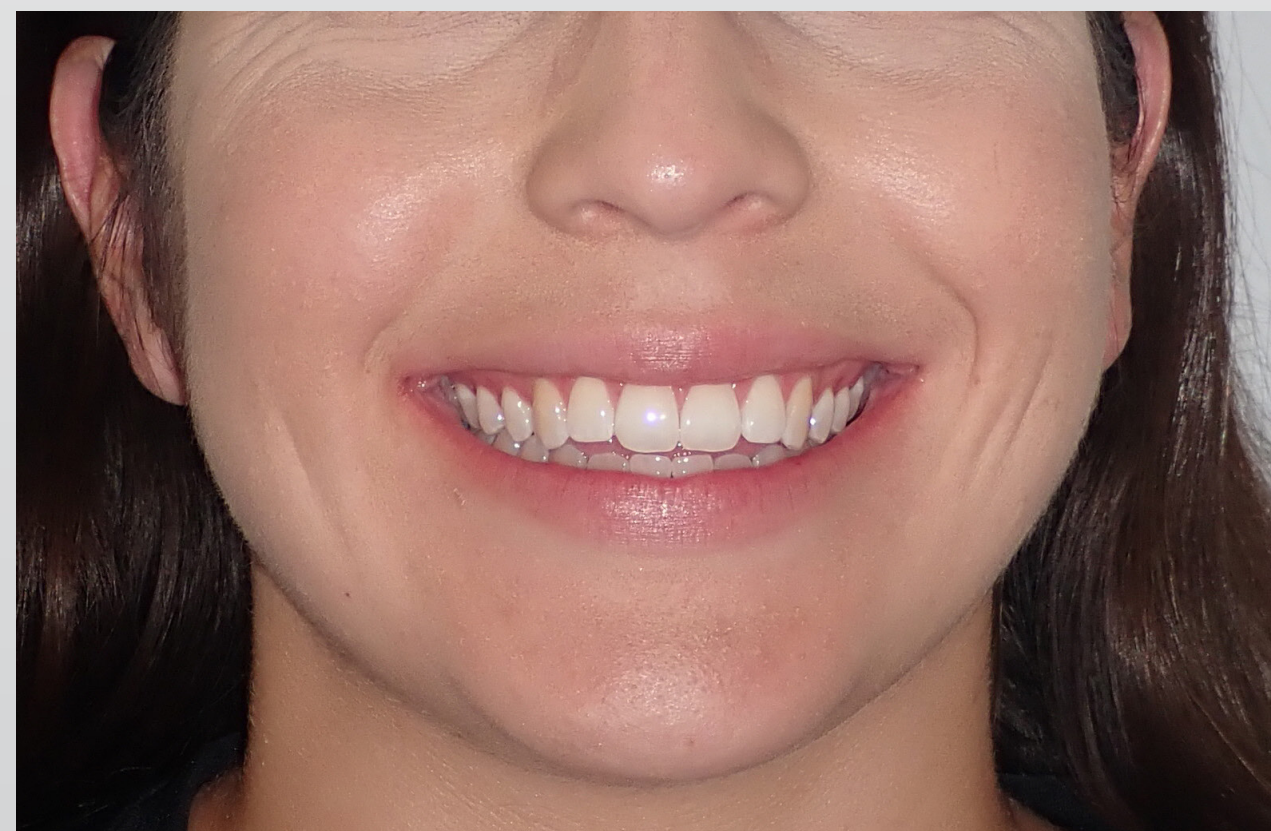Profile at rest



Face at rest



Face smiling

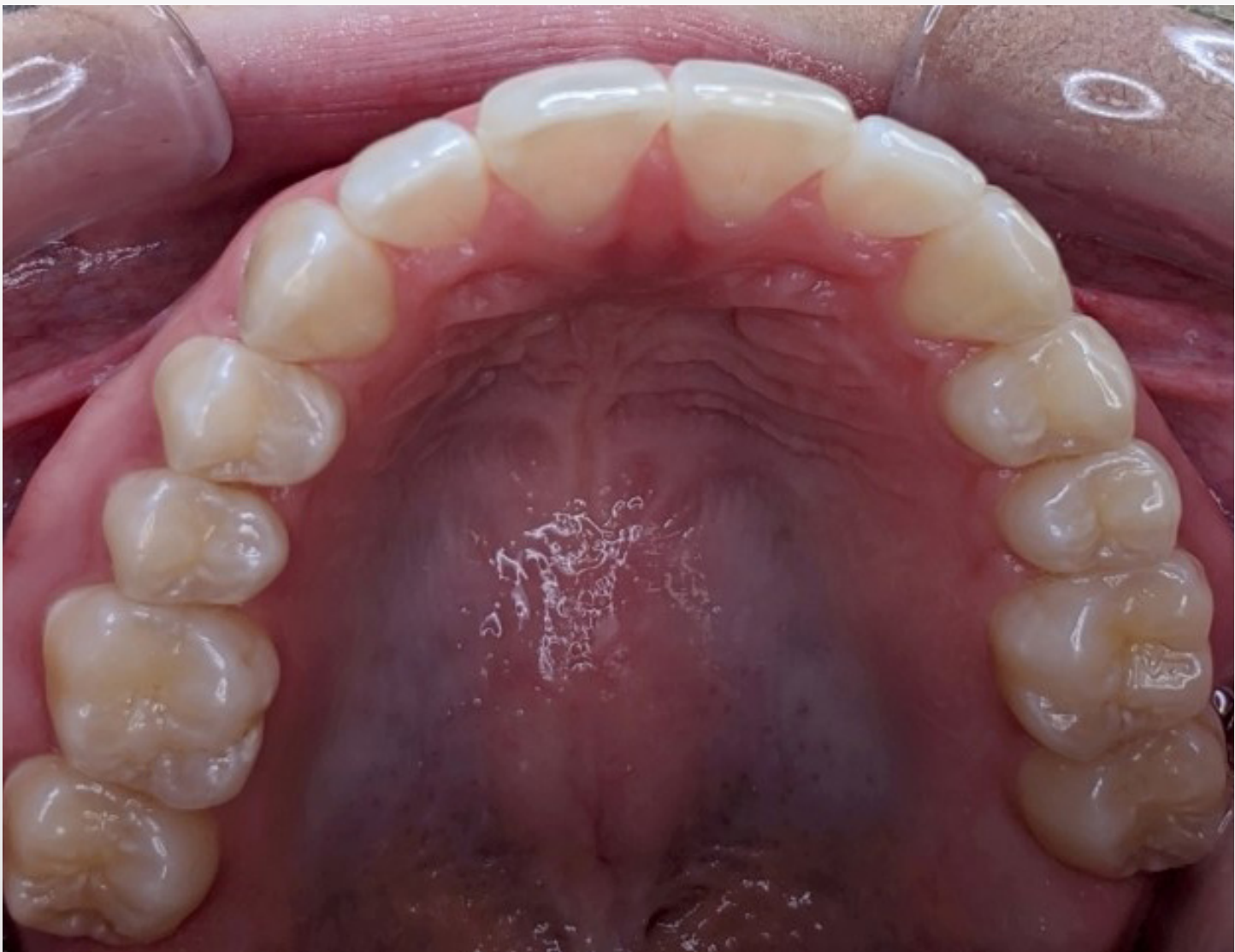
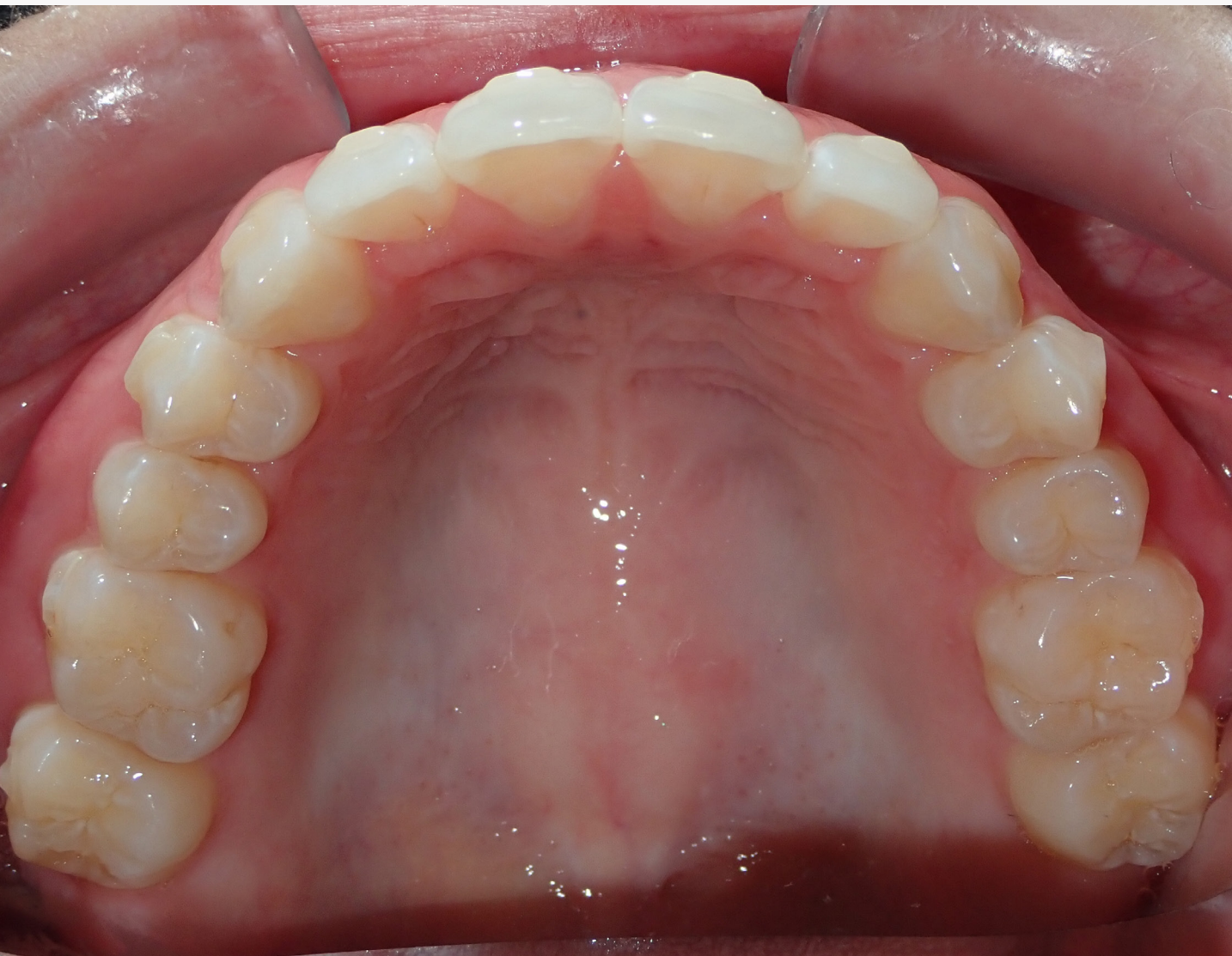
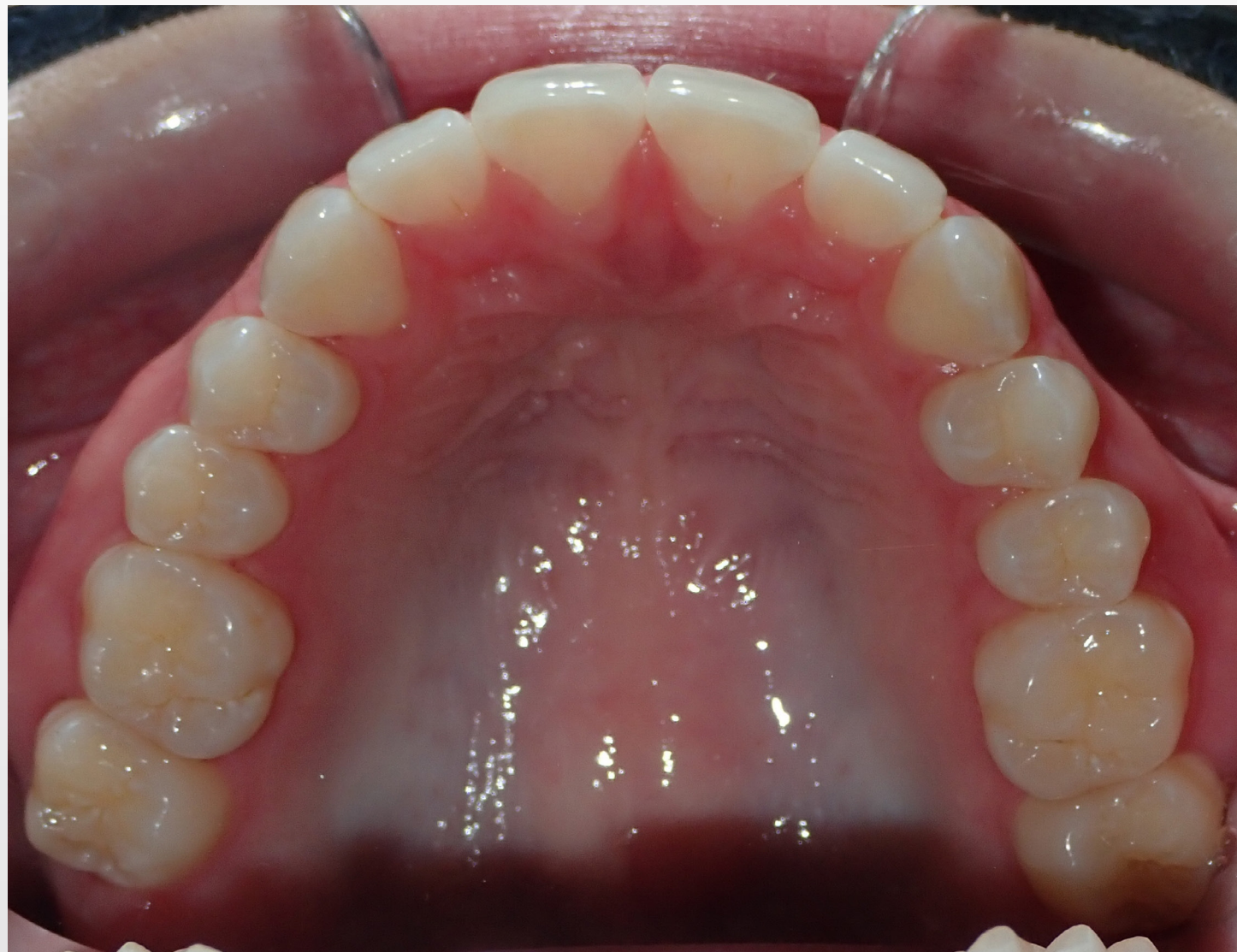Initial

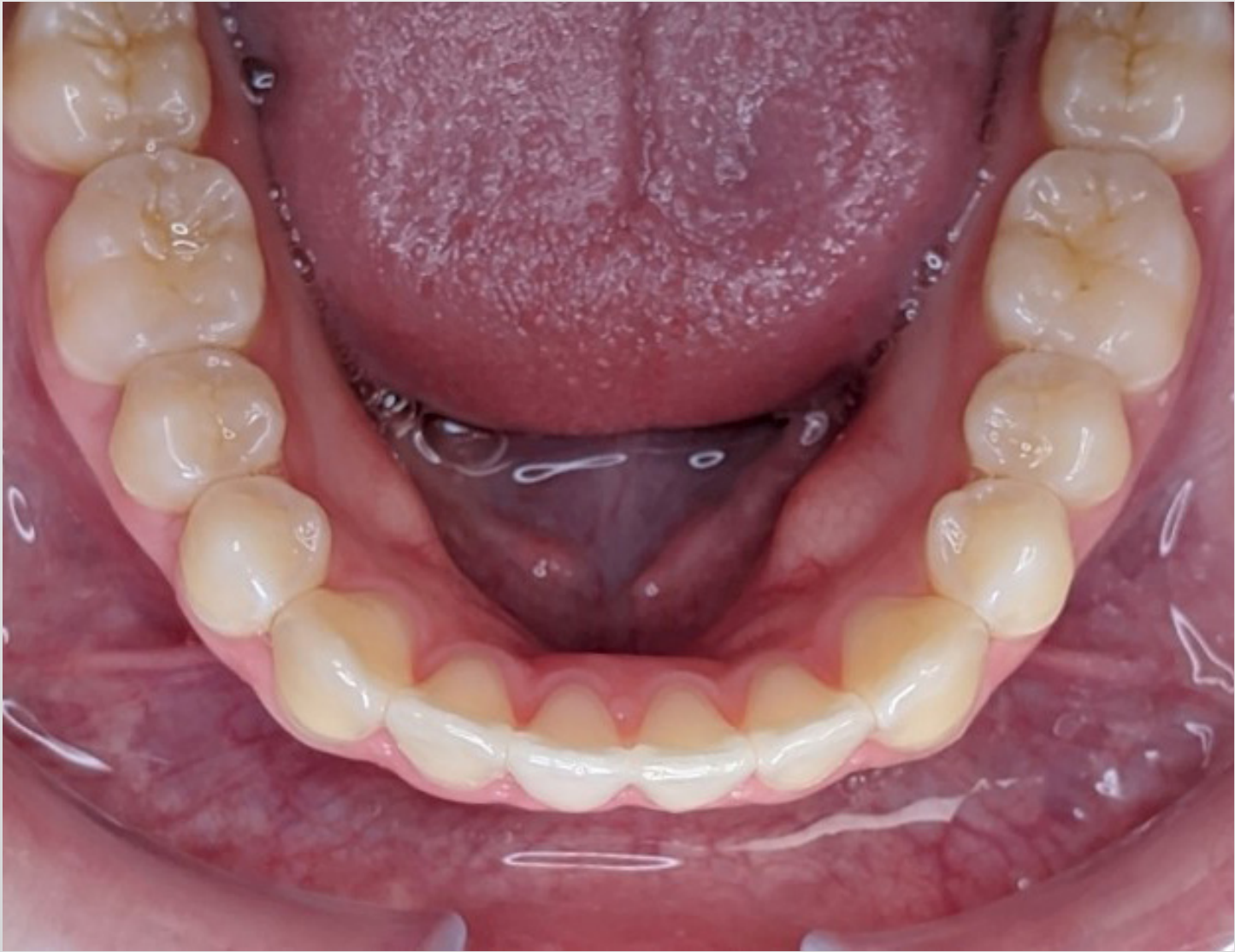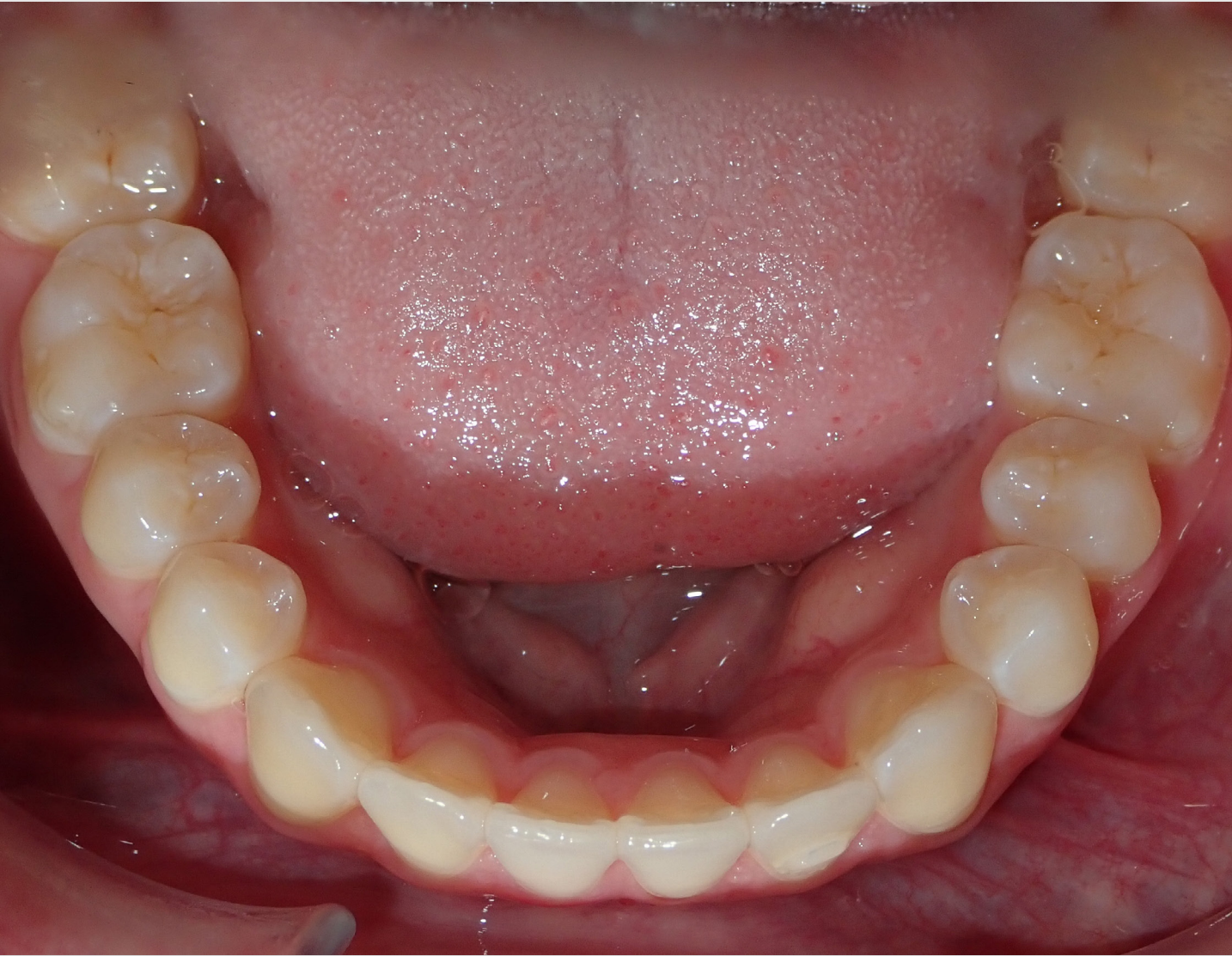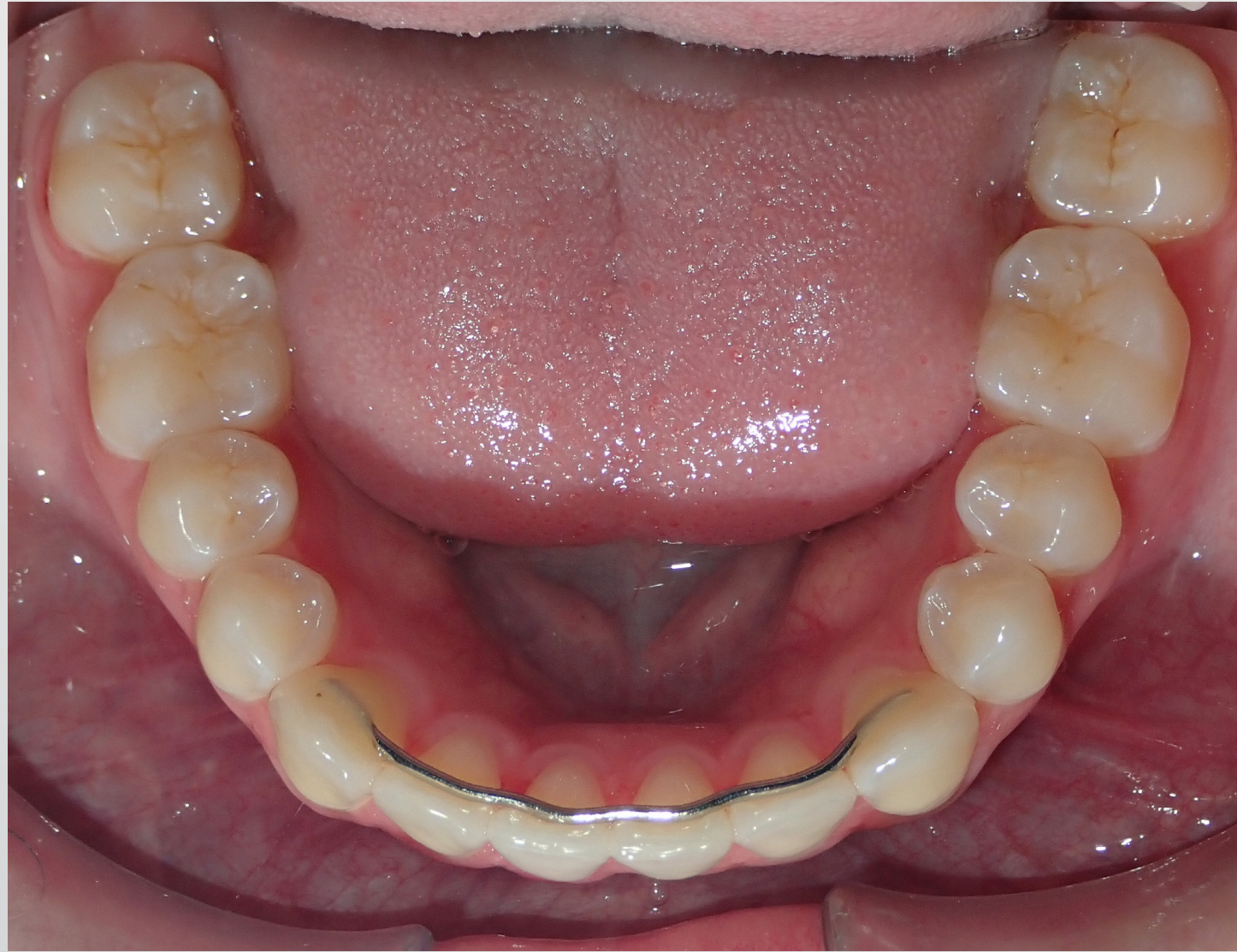Progress - 11 months

Final

**Occlusal –
maxillary**



**Occlusal –
mandibular**

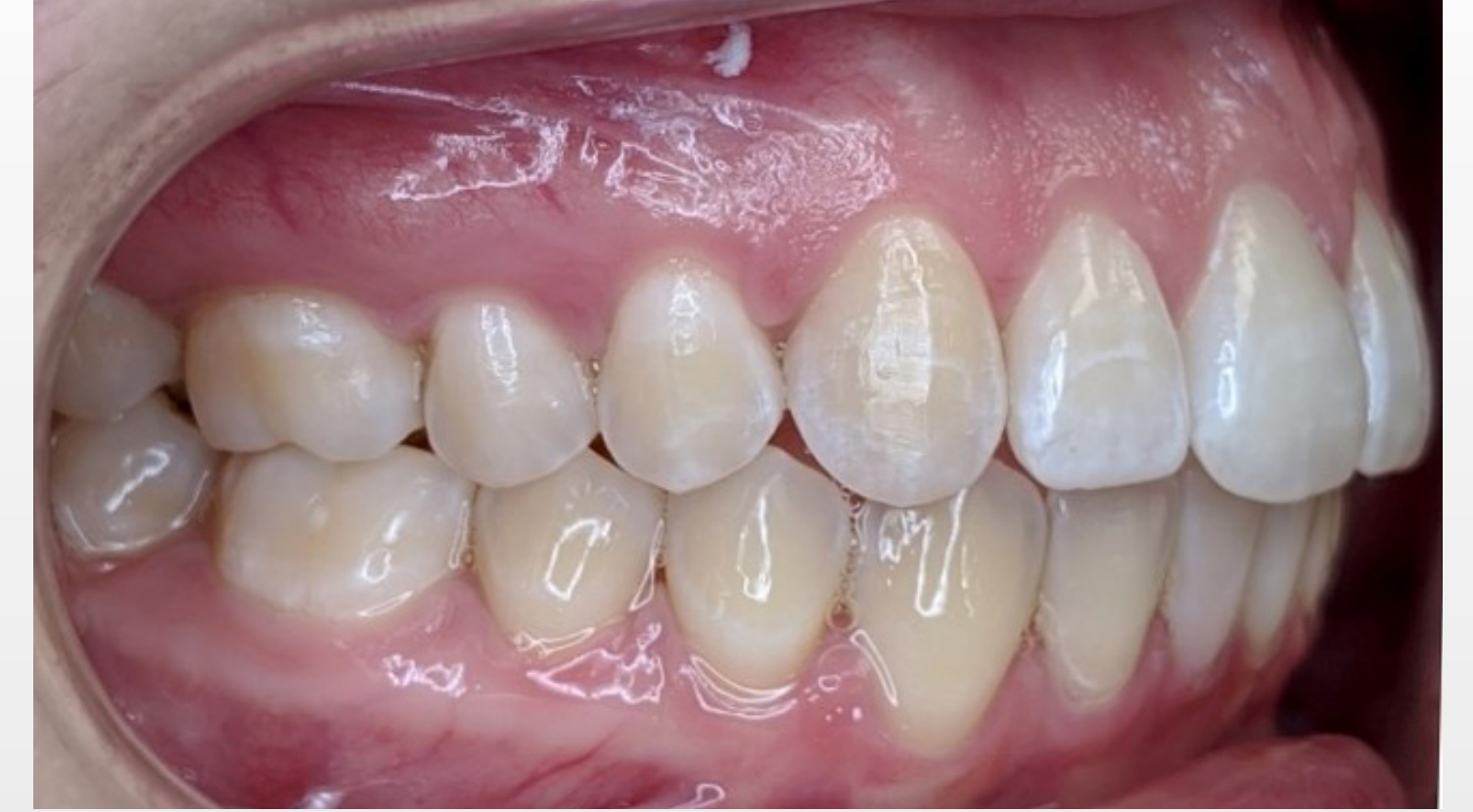
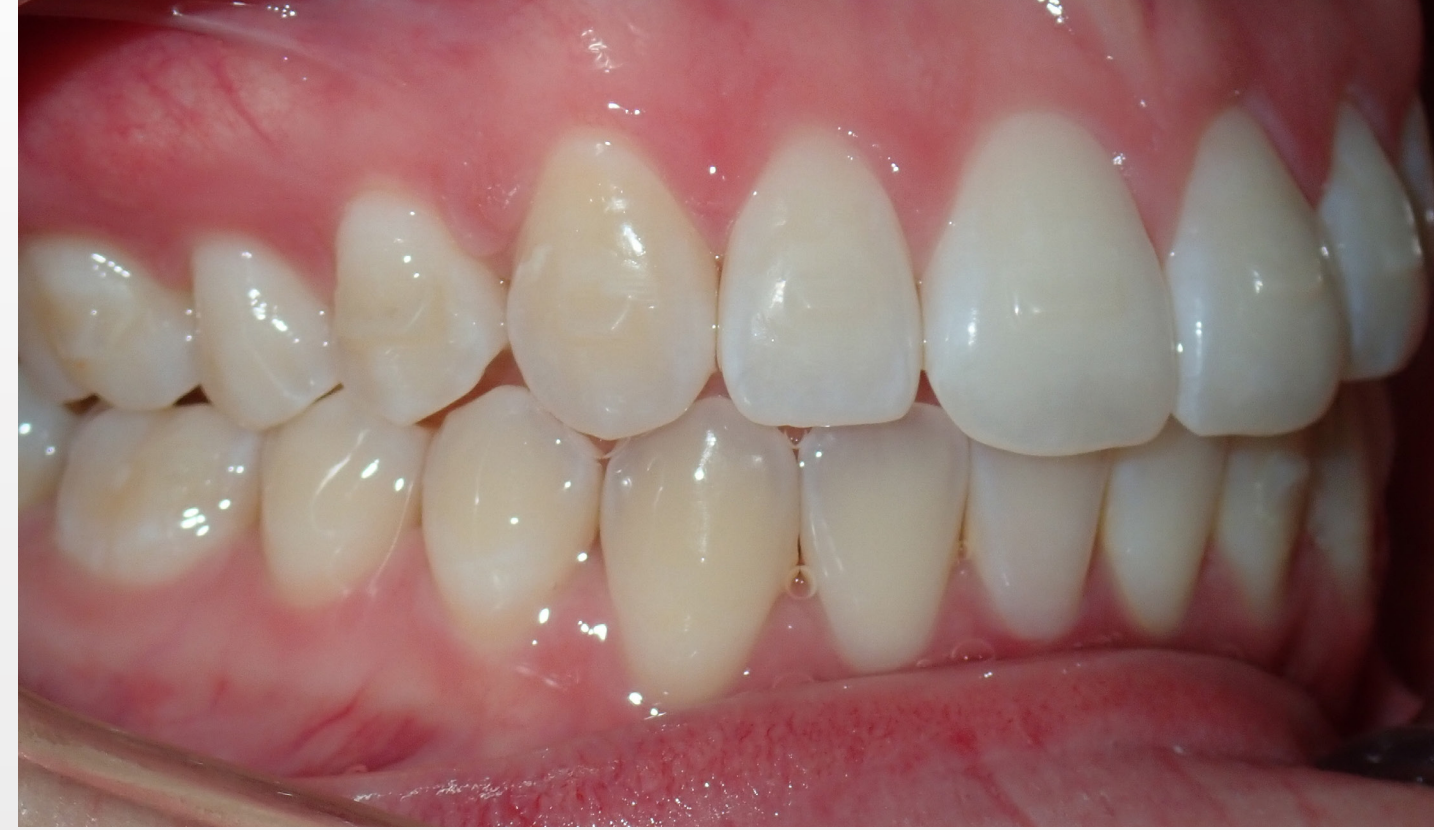
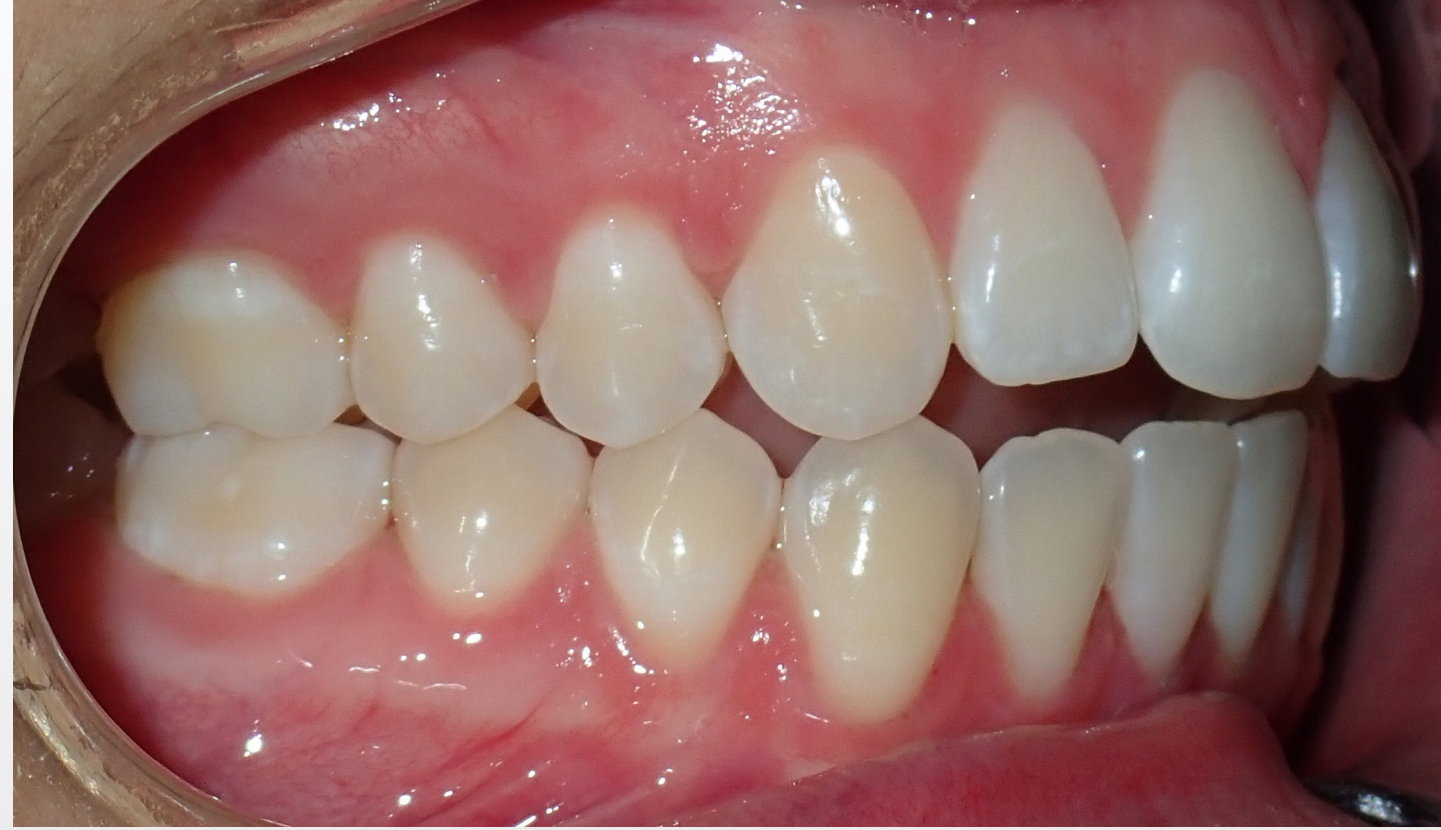Initial

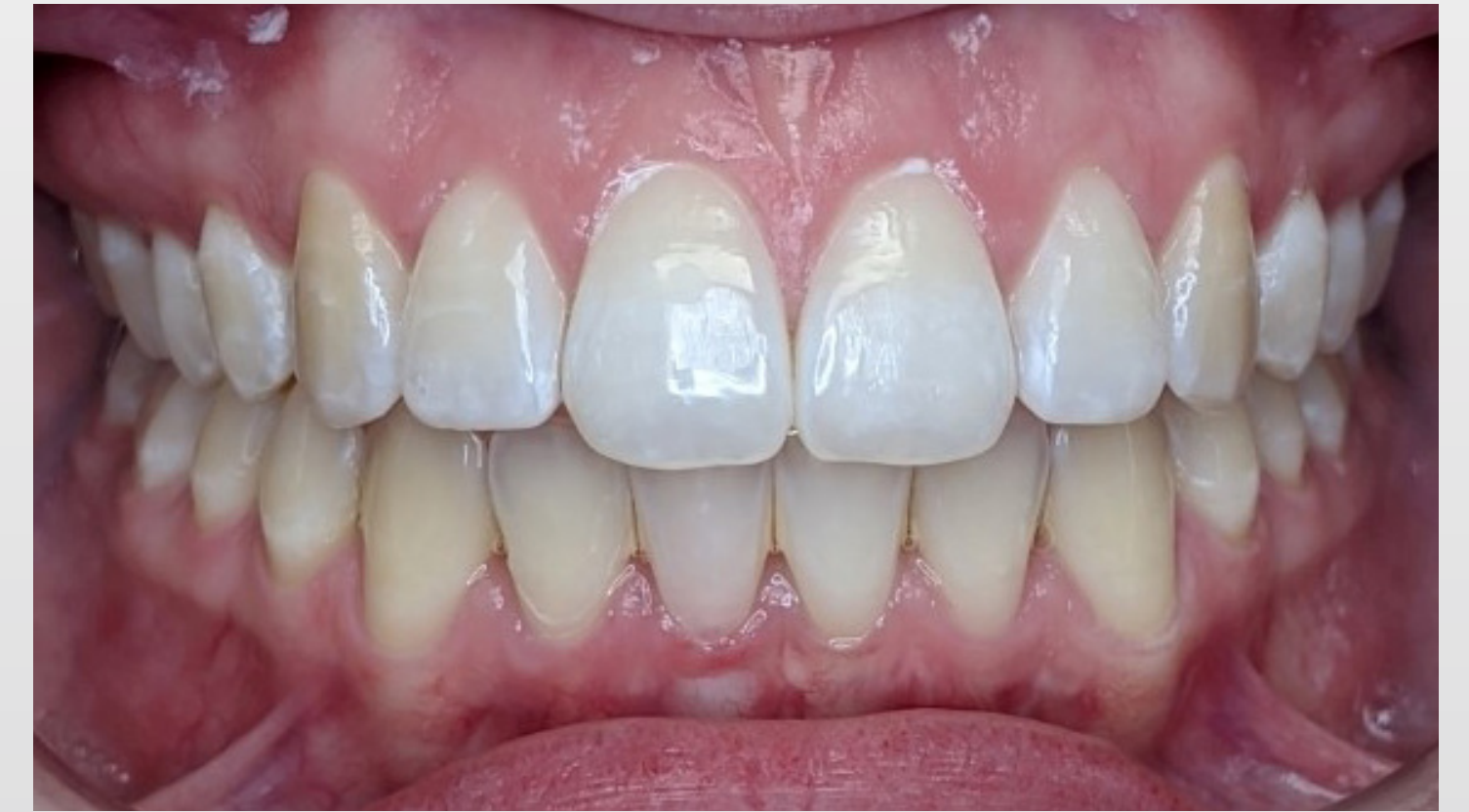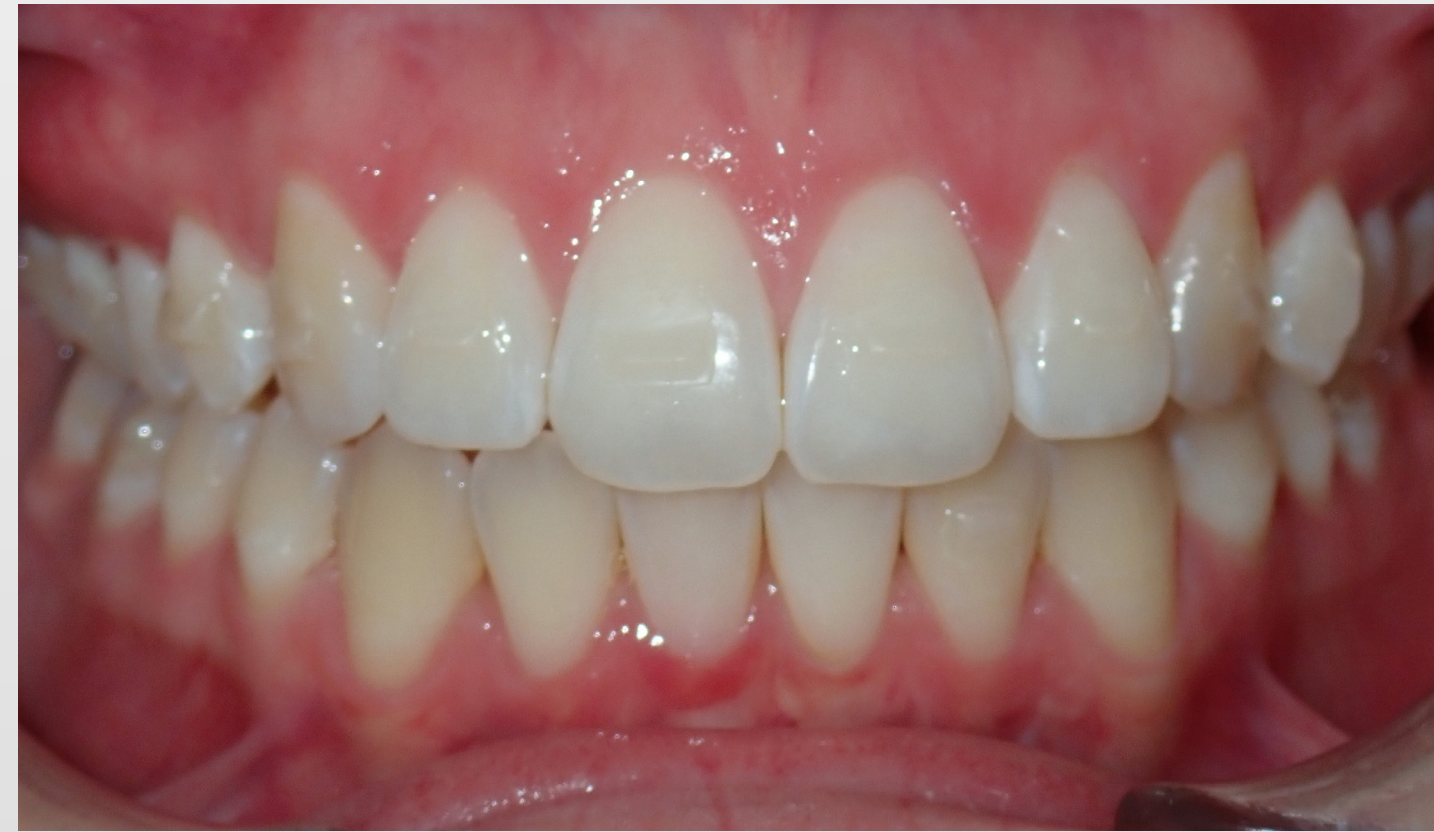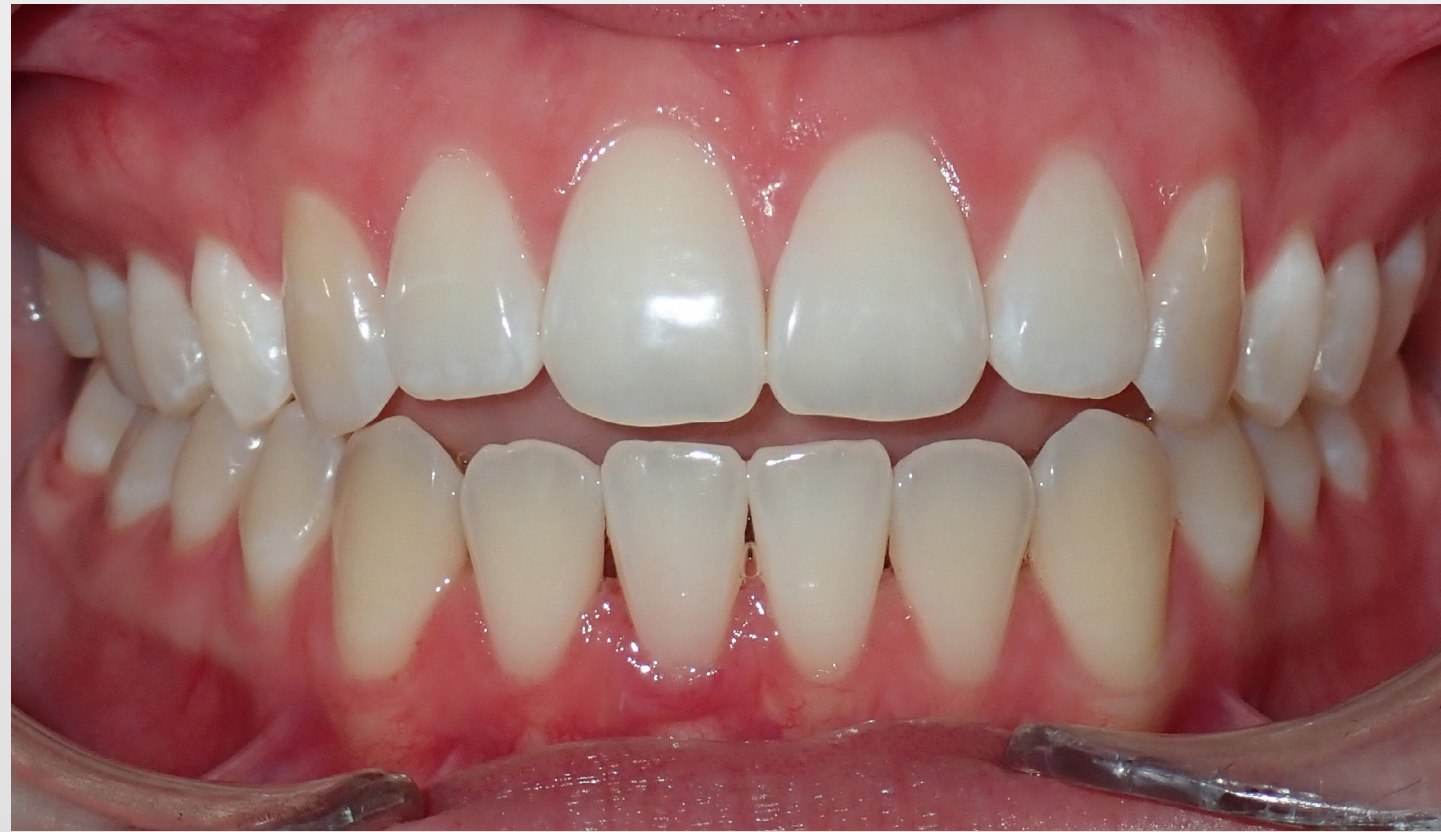Progress - 11 months

Final

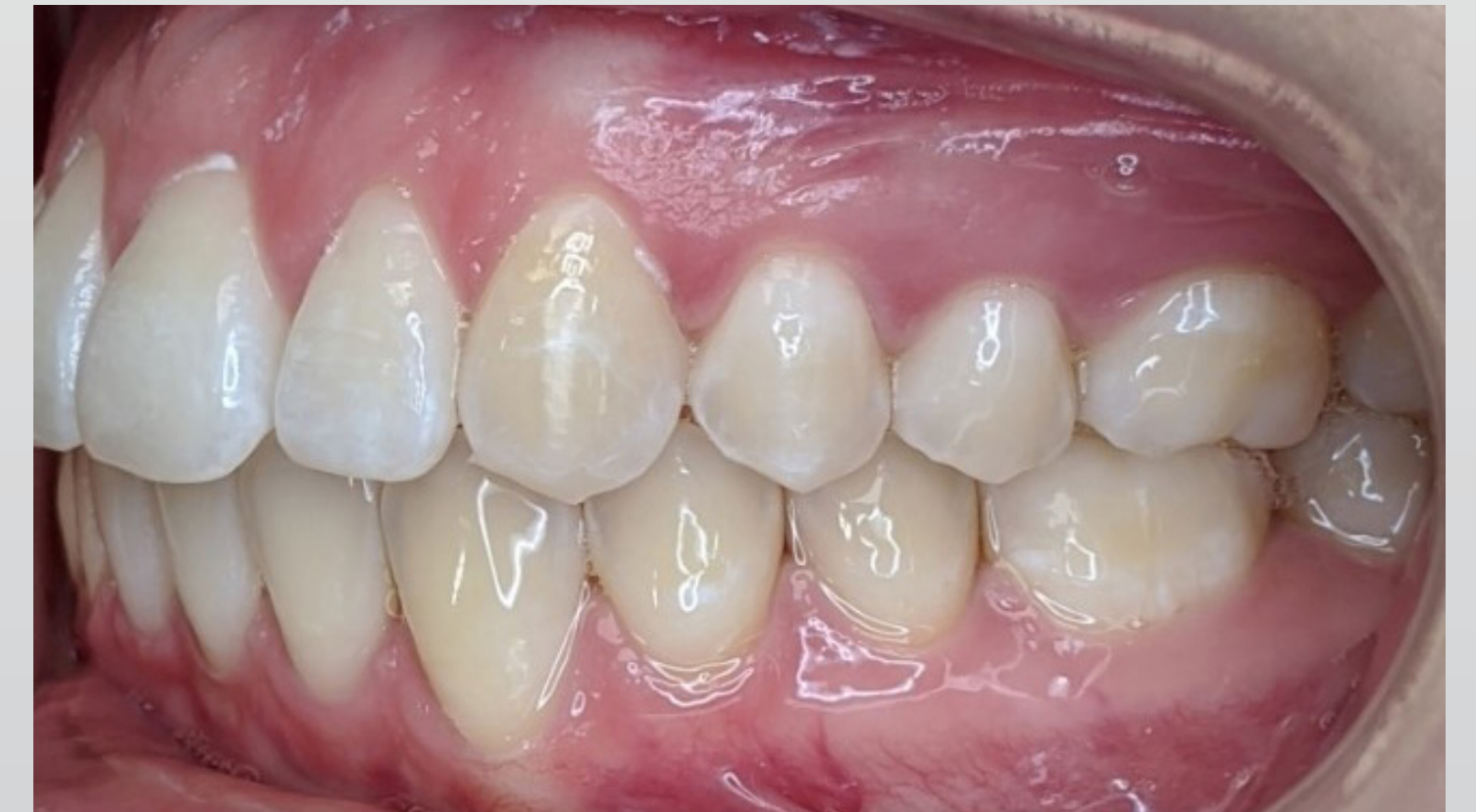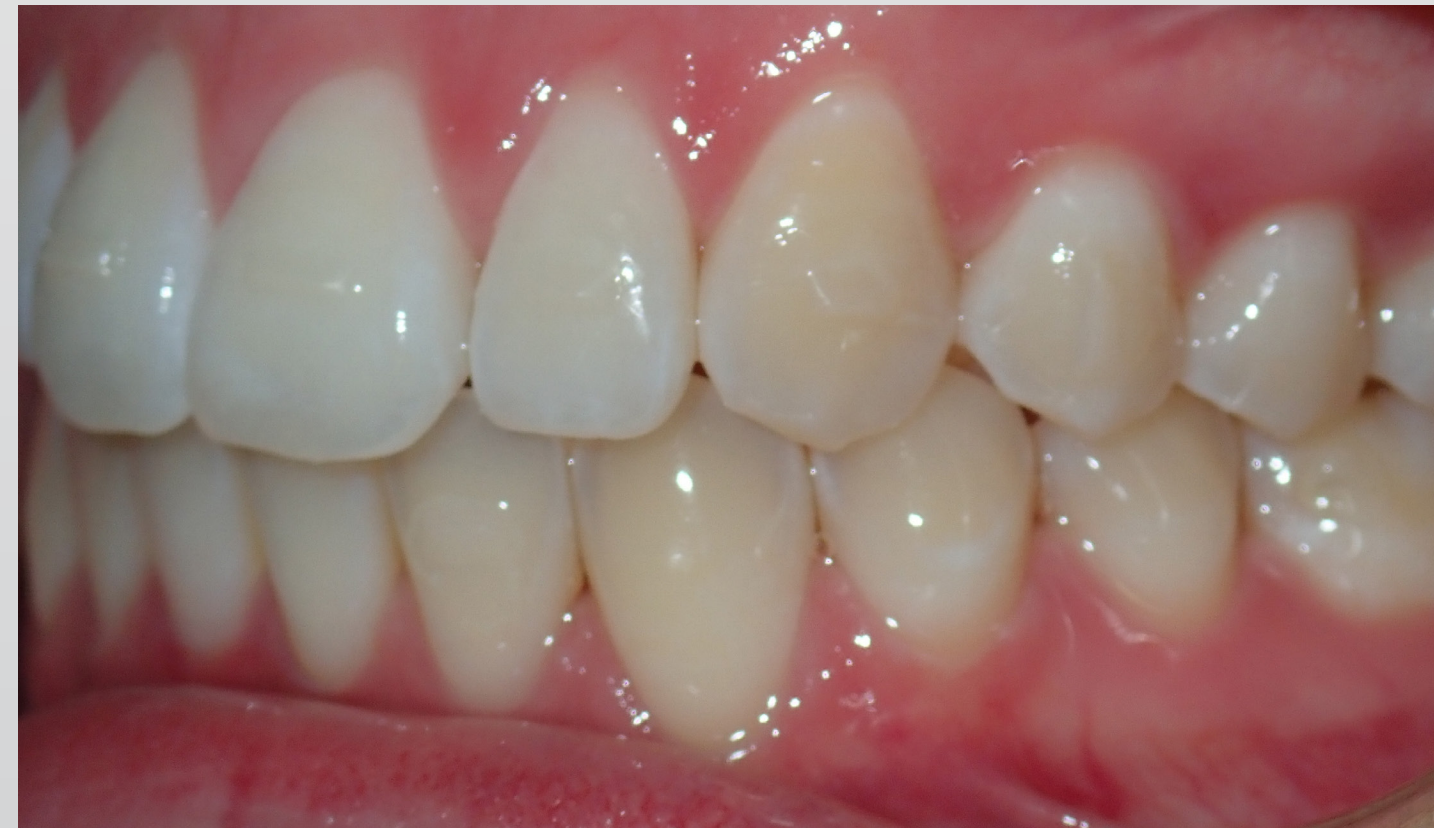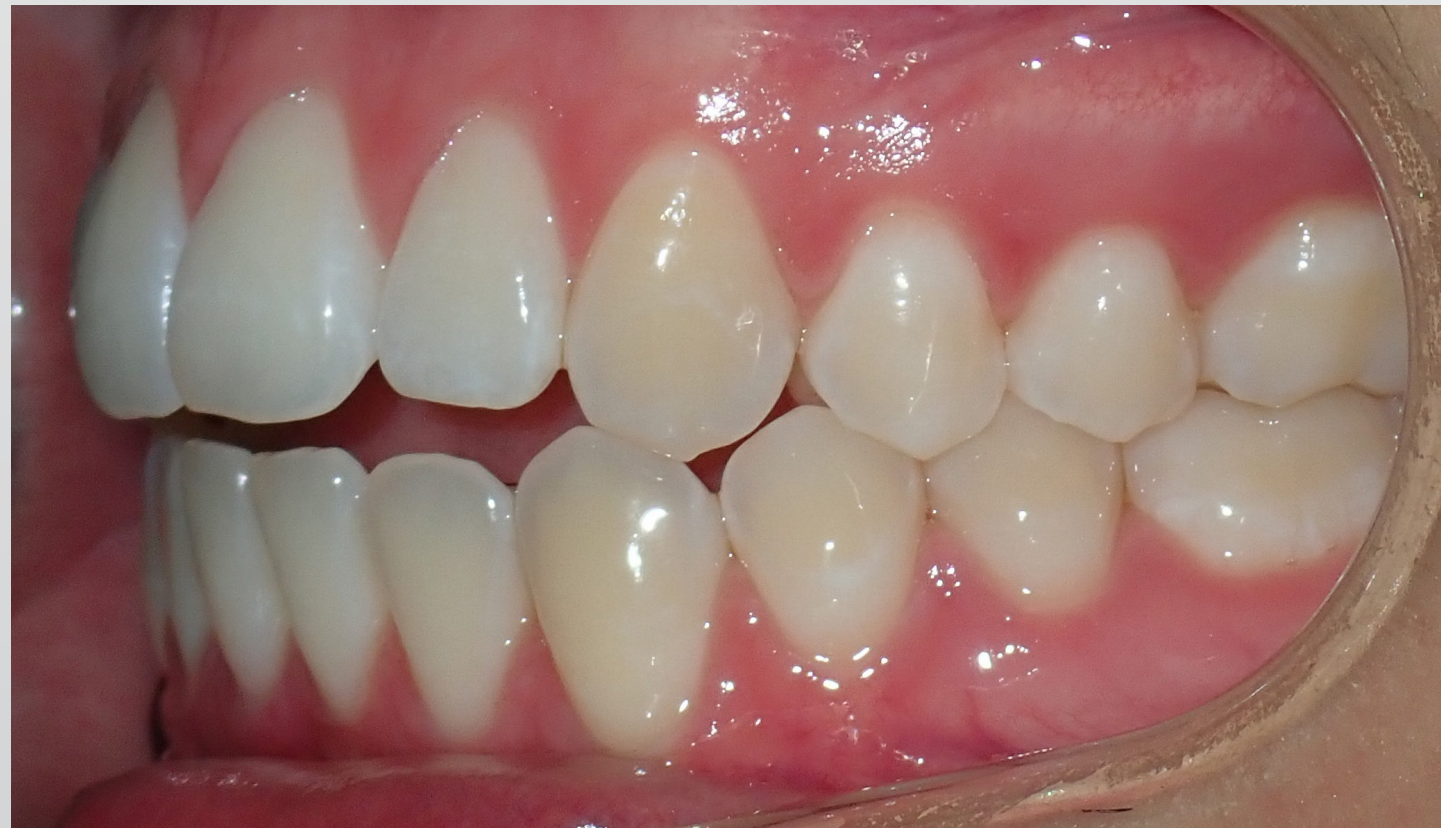**Retracted
buccal – right**



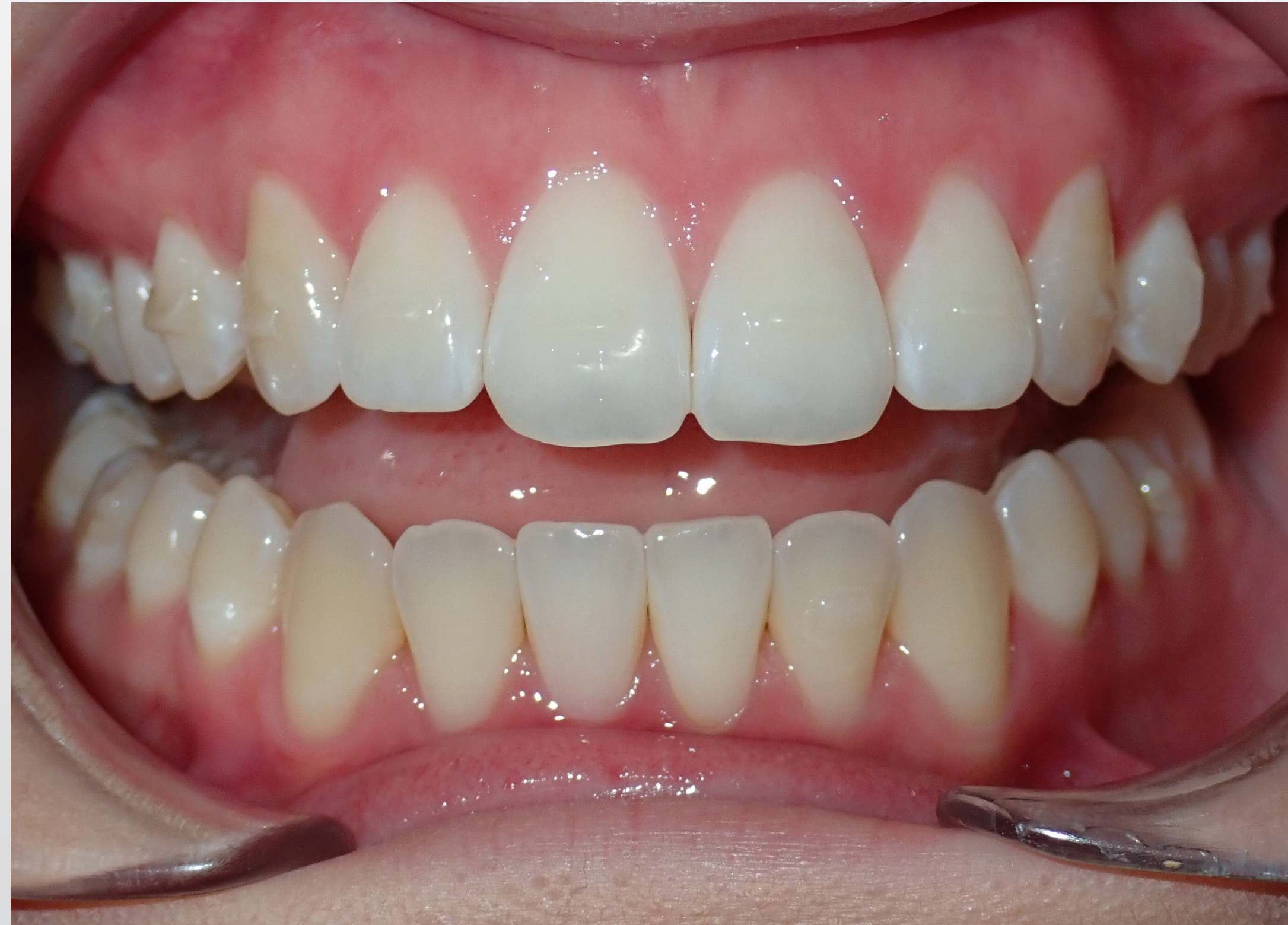**Retracted
anterior
biting**



**Retracted
buccal – left**

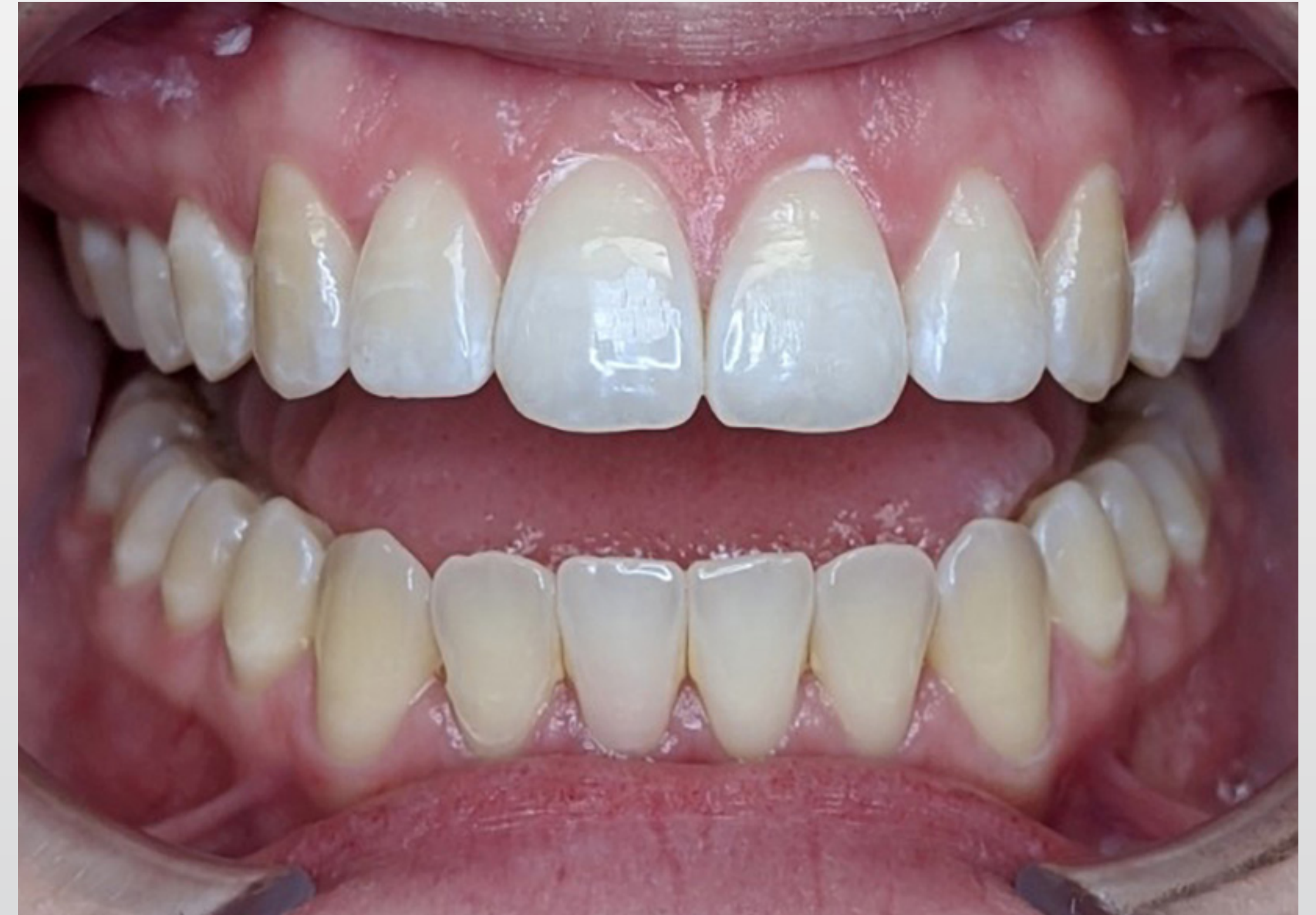

Progress - 11 months



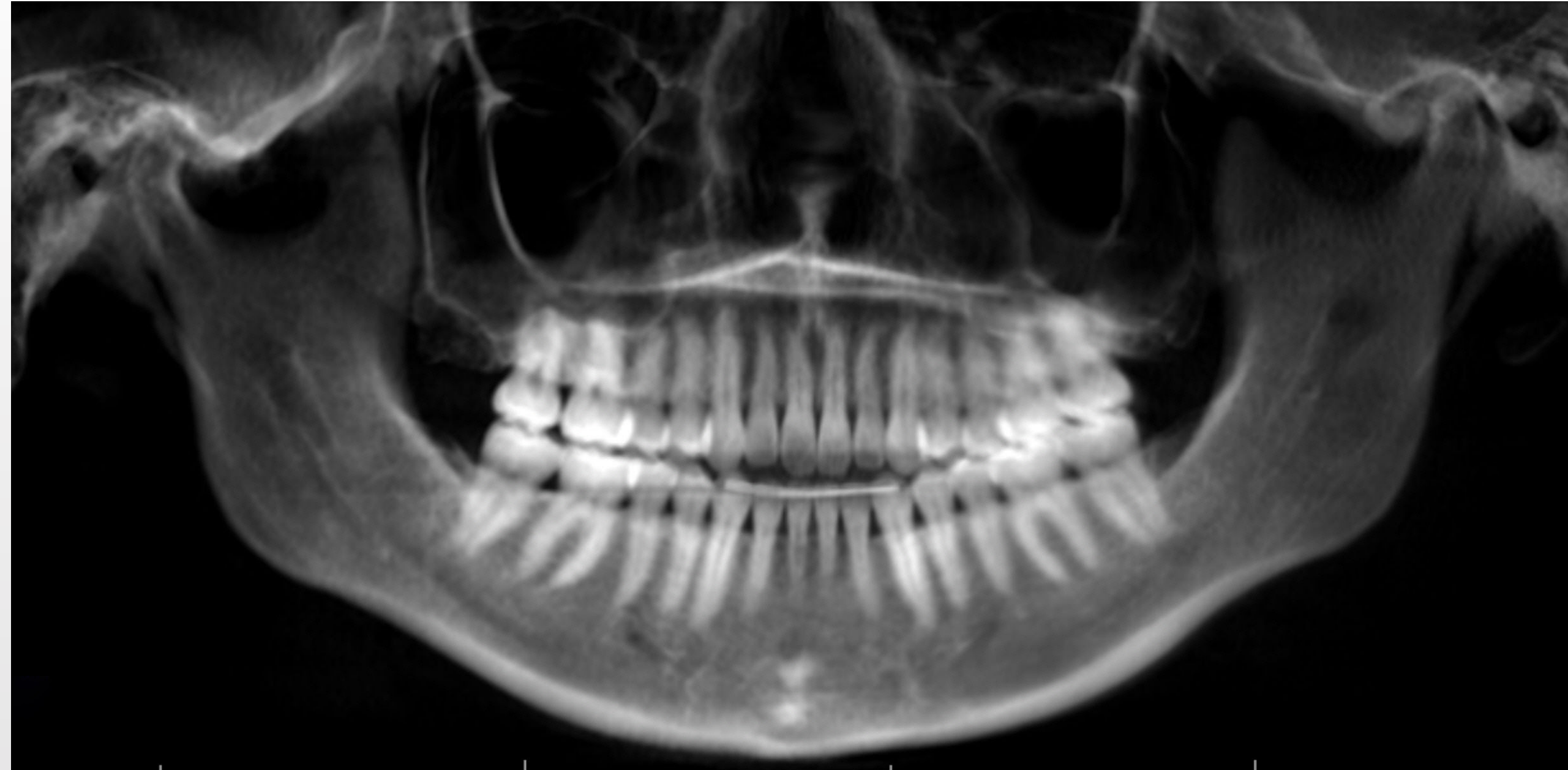**Anterior
open**

Final

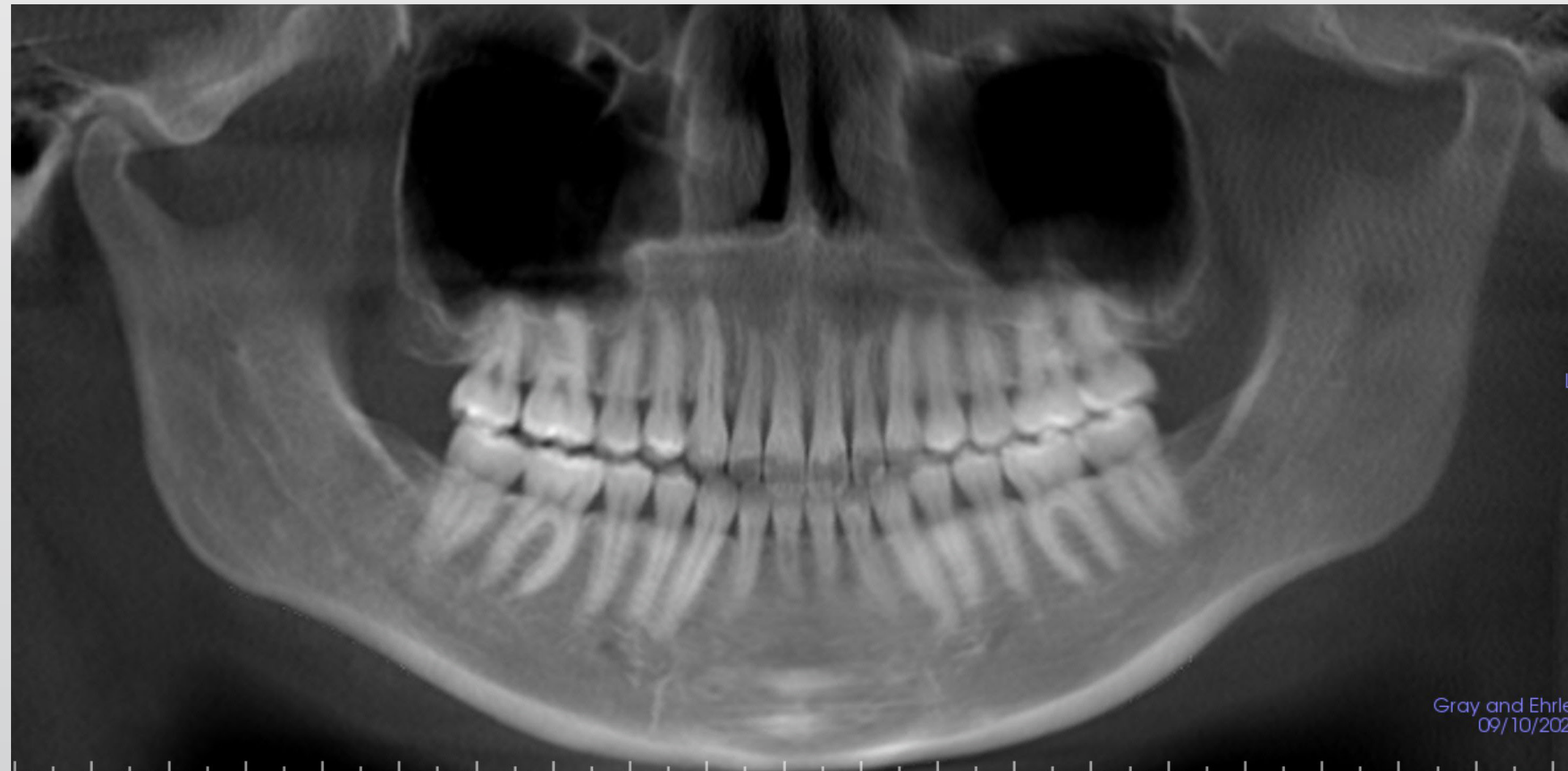

Panoramic radiograph

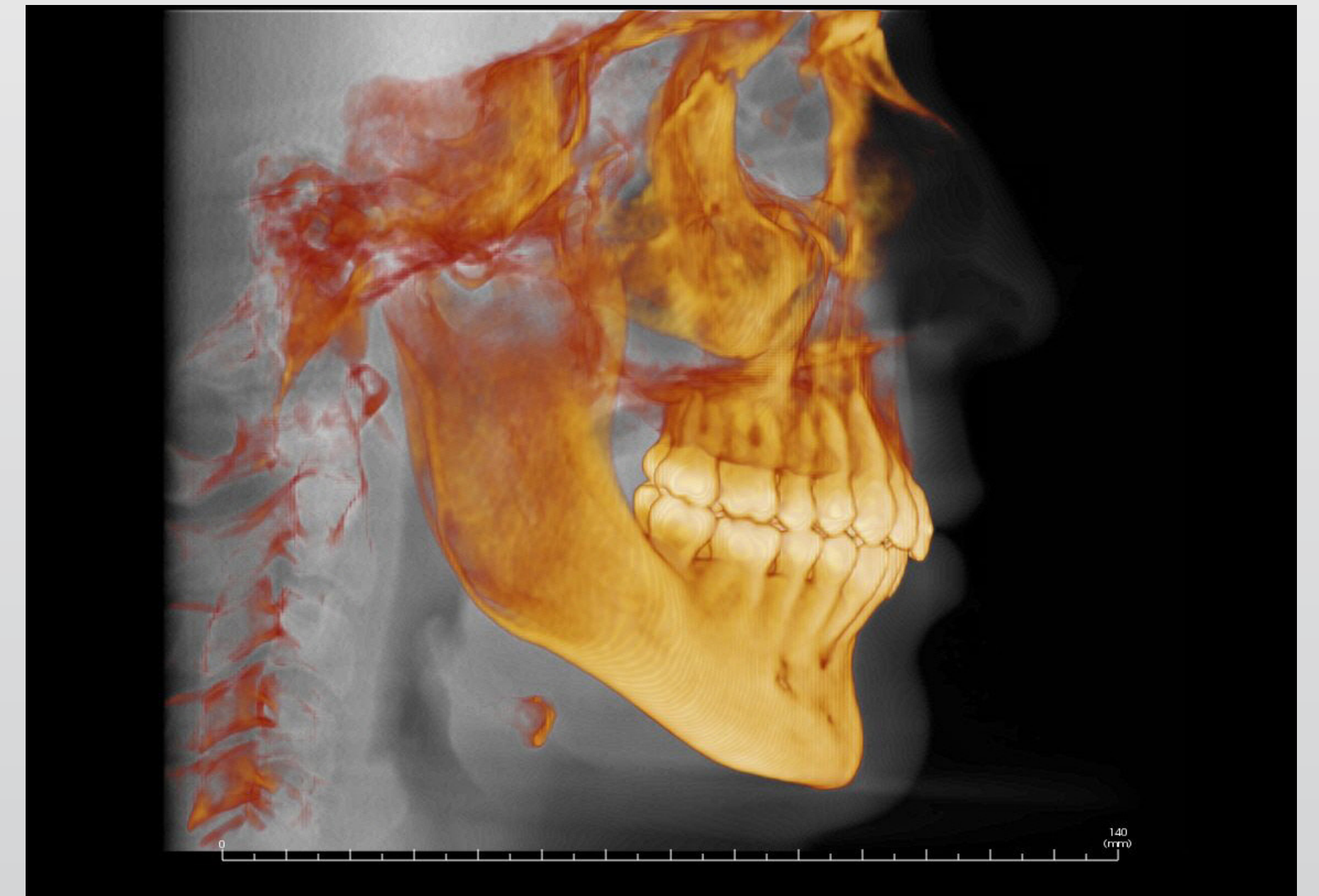
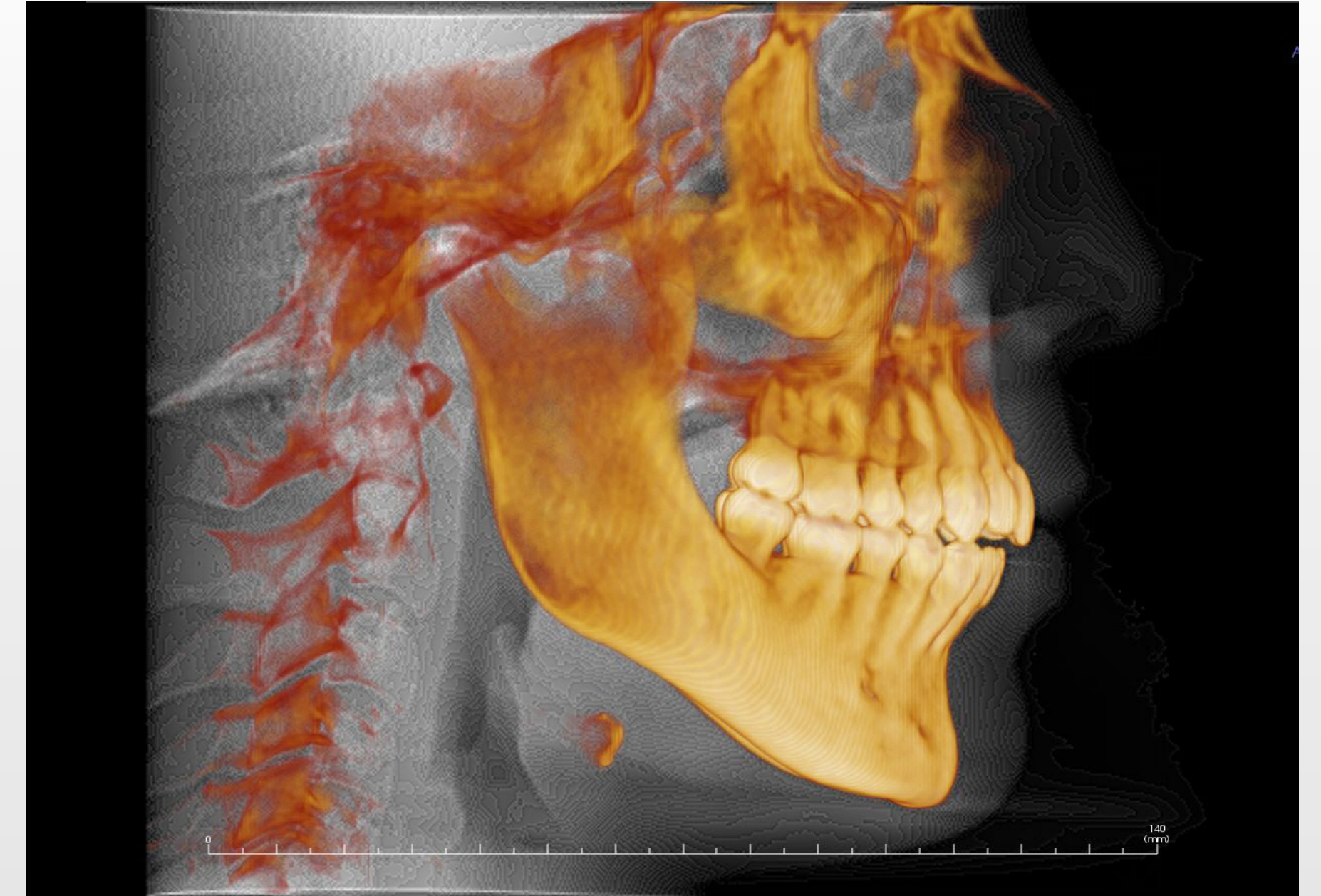
Initial



Progress -
11 months



Ceph.



Tx Design Video

- Treatment Plan
- Attachment Strategy
- Key Movements
- Summary of Final Results

Best Fit Overlay

