

Case Study: 3M™ Clarity™ Aligners

Crossbite correction

Age: 72

Chief concern: Biting lower lip and uncomfortable

Case diagnostics: Class I occlusion, moderate crowding lower arch and mild crowding on the upper arch. Crossbite on upper and lower right canine, 1st and 2nd premolars (4s, 5s, 6s). Midline deviation with the lower midline off 2 mm on the lower right. Lower left 1st molar (6) is an implant.

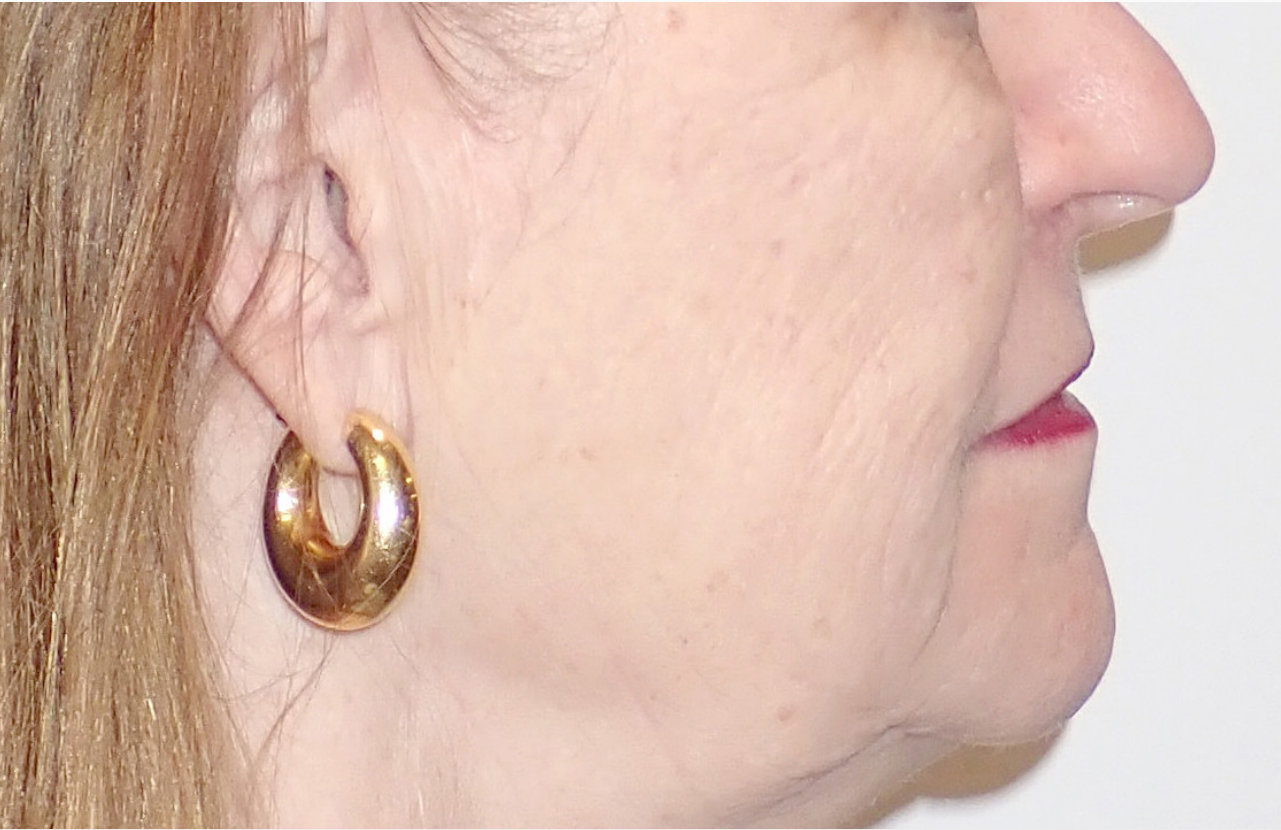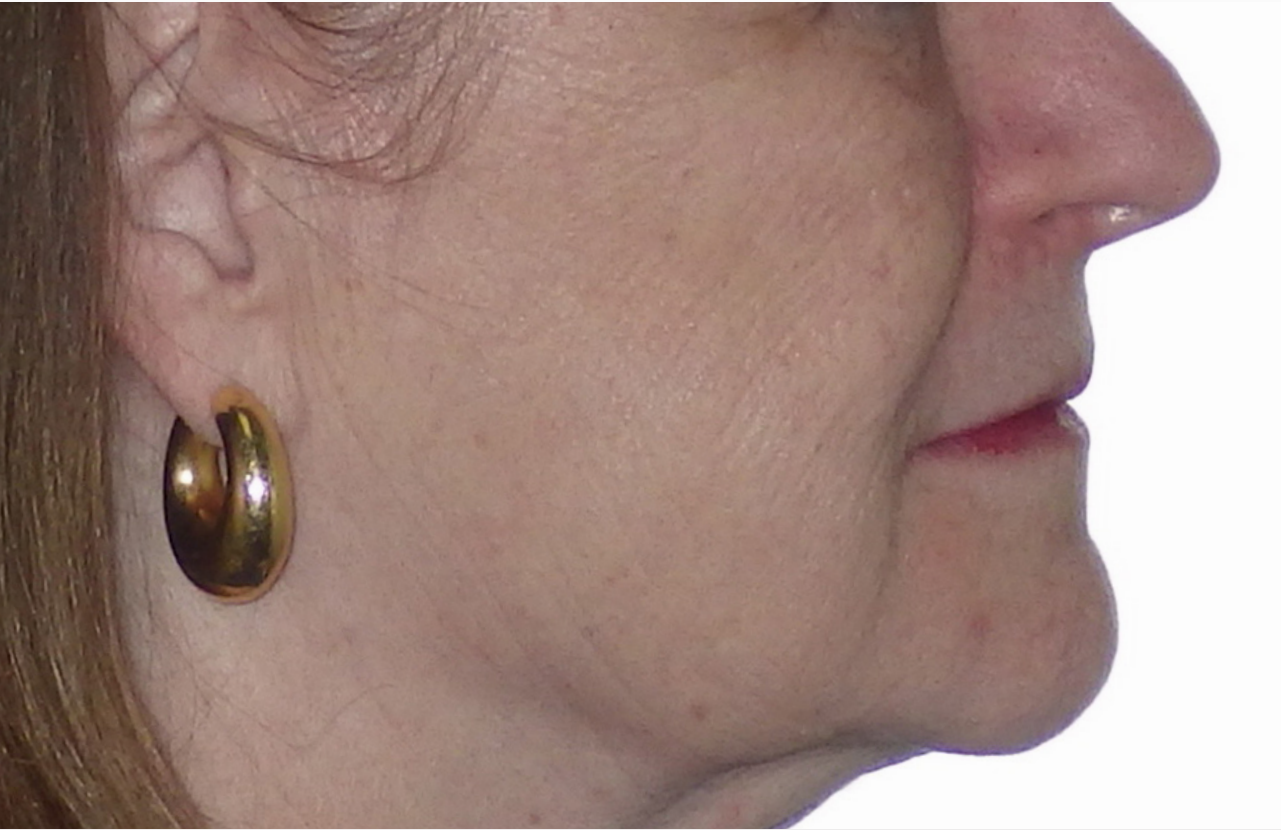Total number of aligners: 56 (1-40 Initial Tx), (41-48 Refinement 1), (49-56 Refinement 2)

Wear interval: 7 days

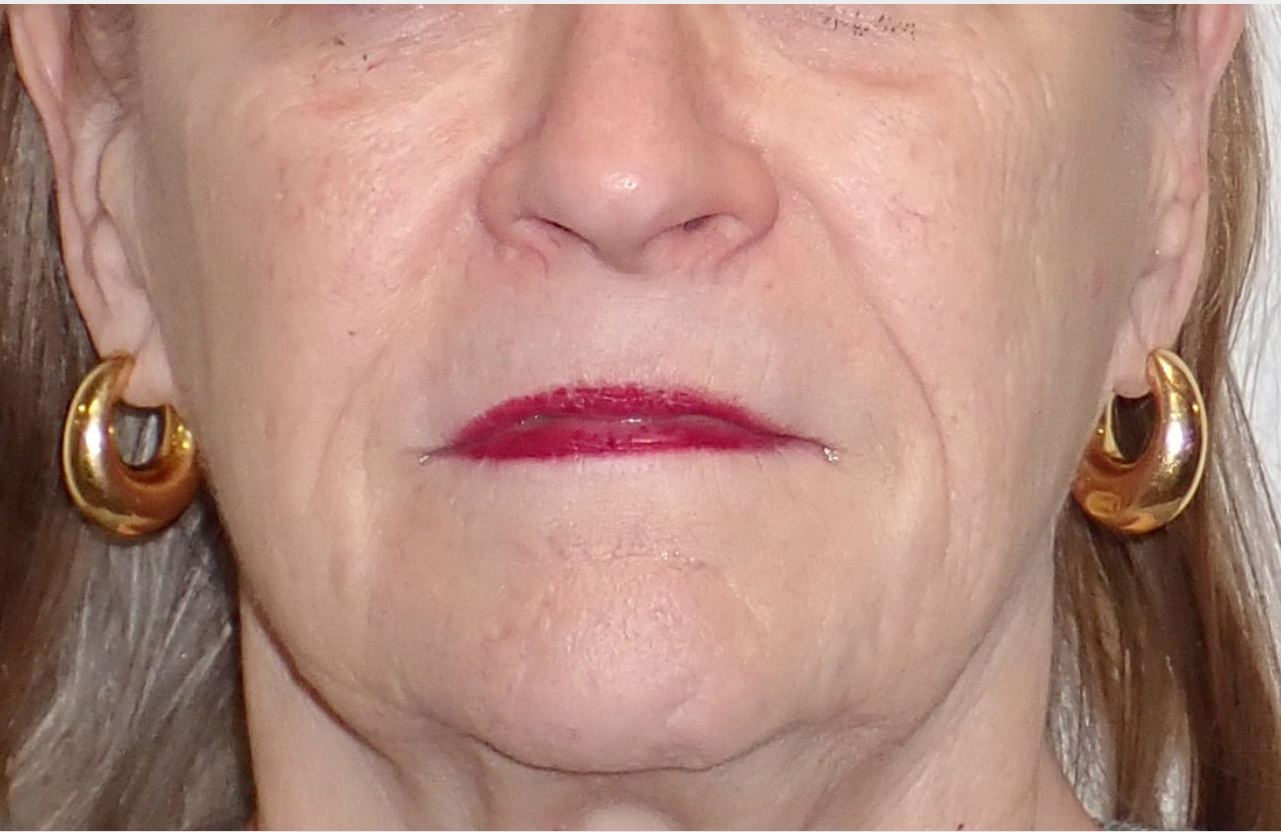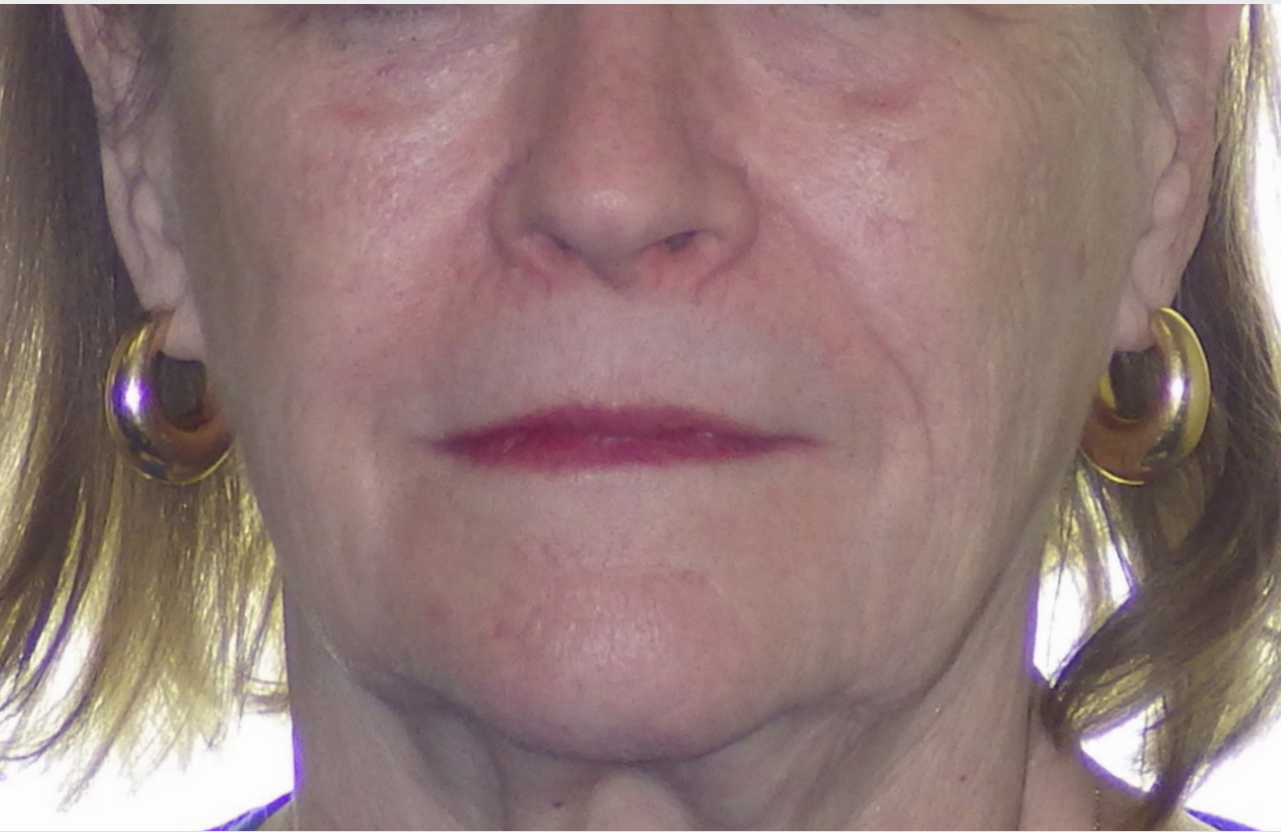Treatment time: 15 months

Case courtesy of:
Dr. Darin Iverson
Arlington, VA – USA

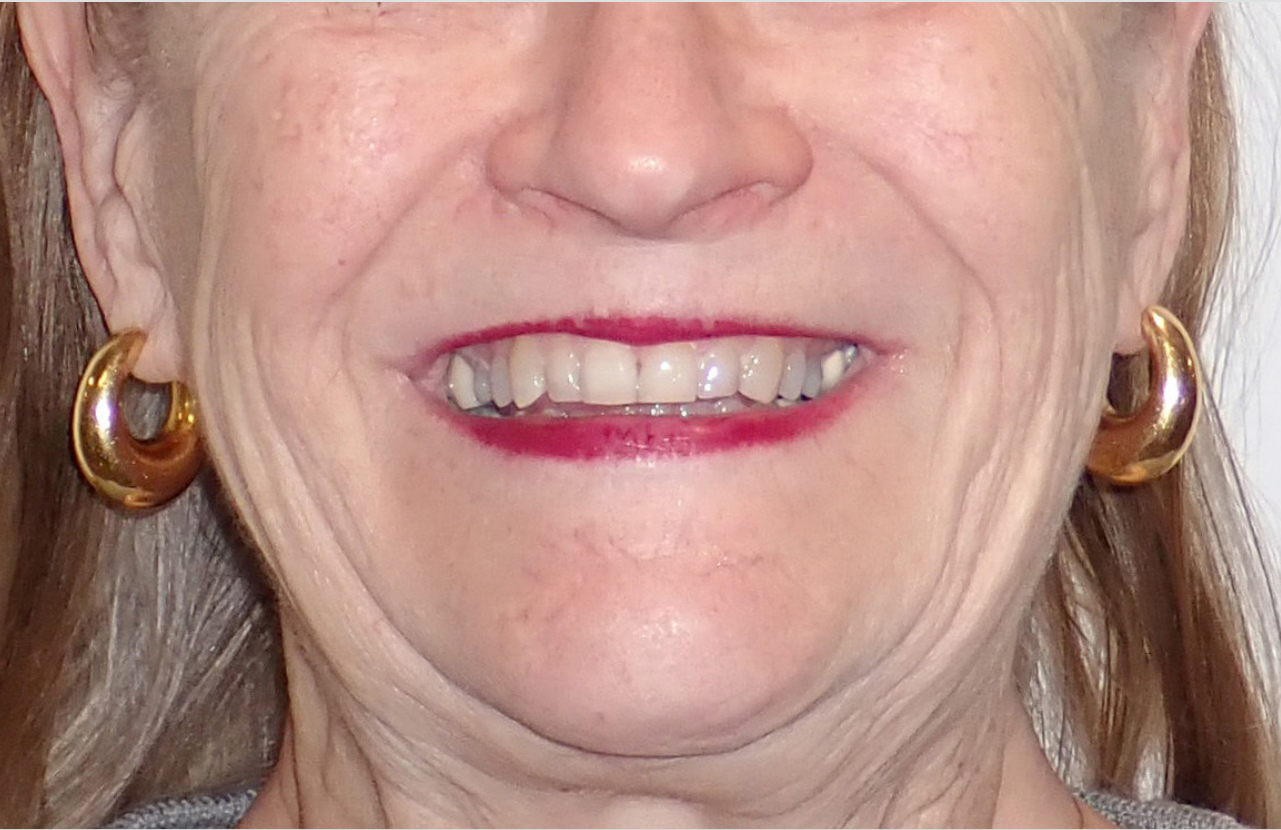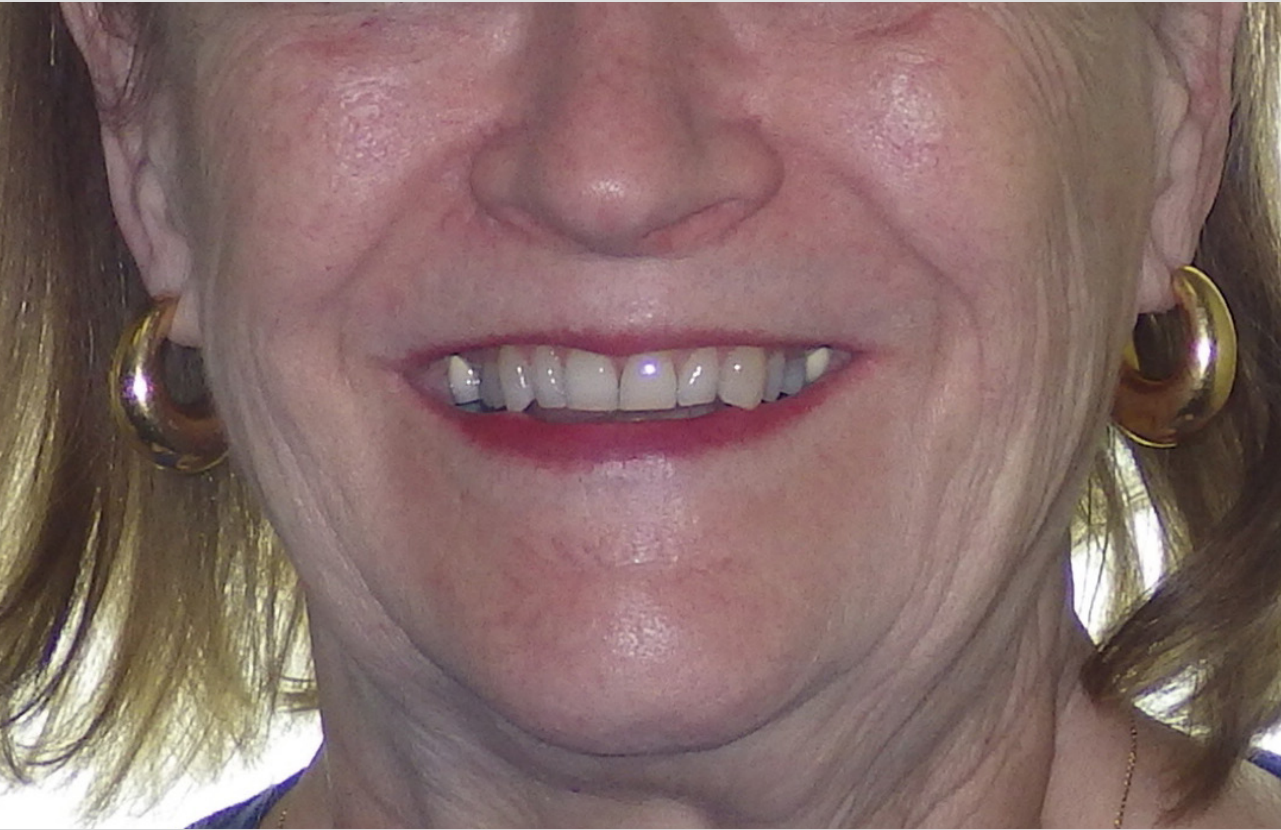Profile at rest



Face at rest



Face smiling

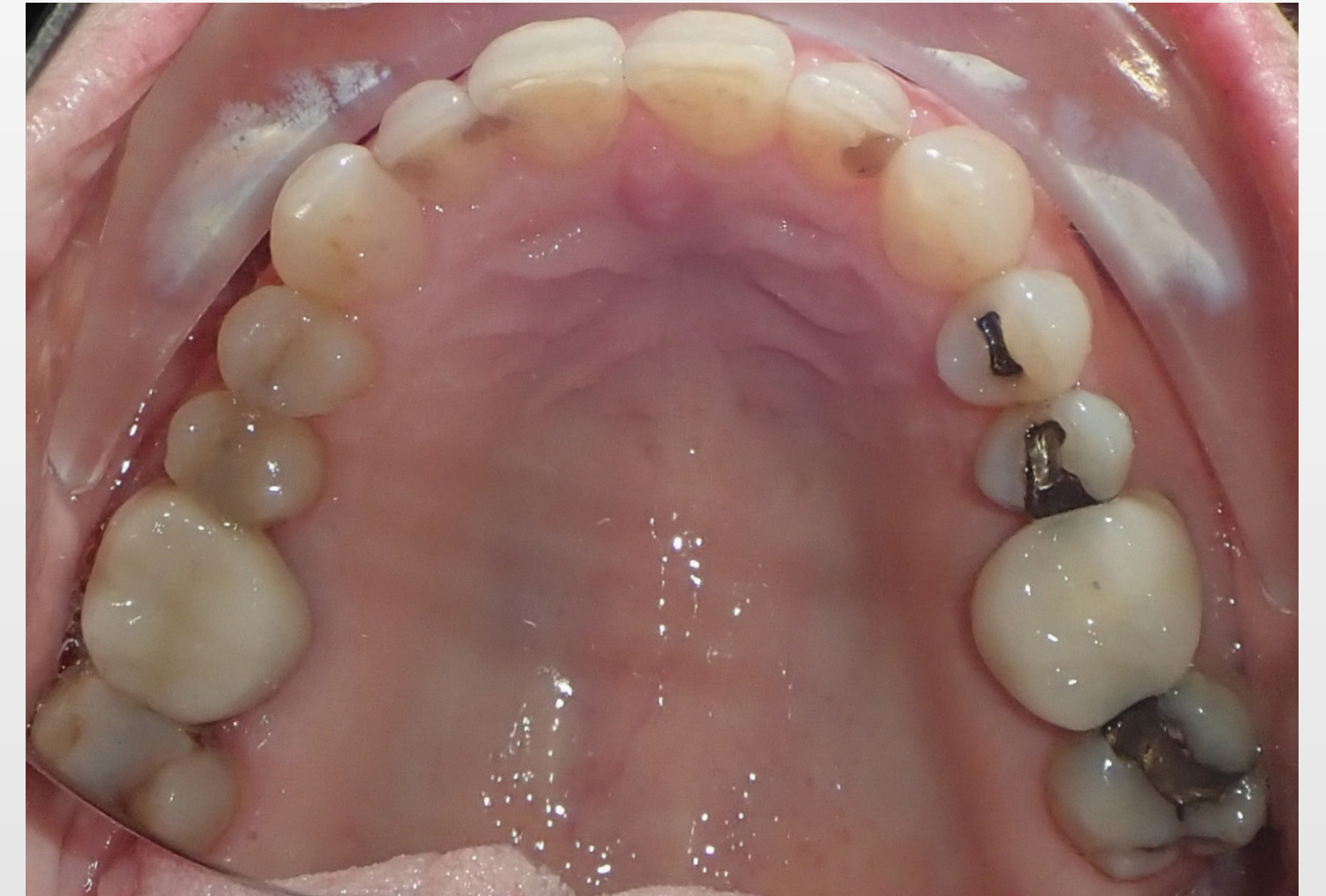
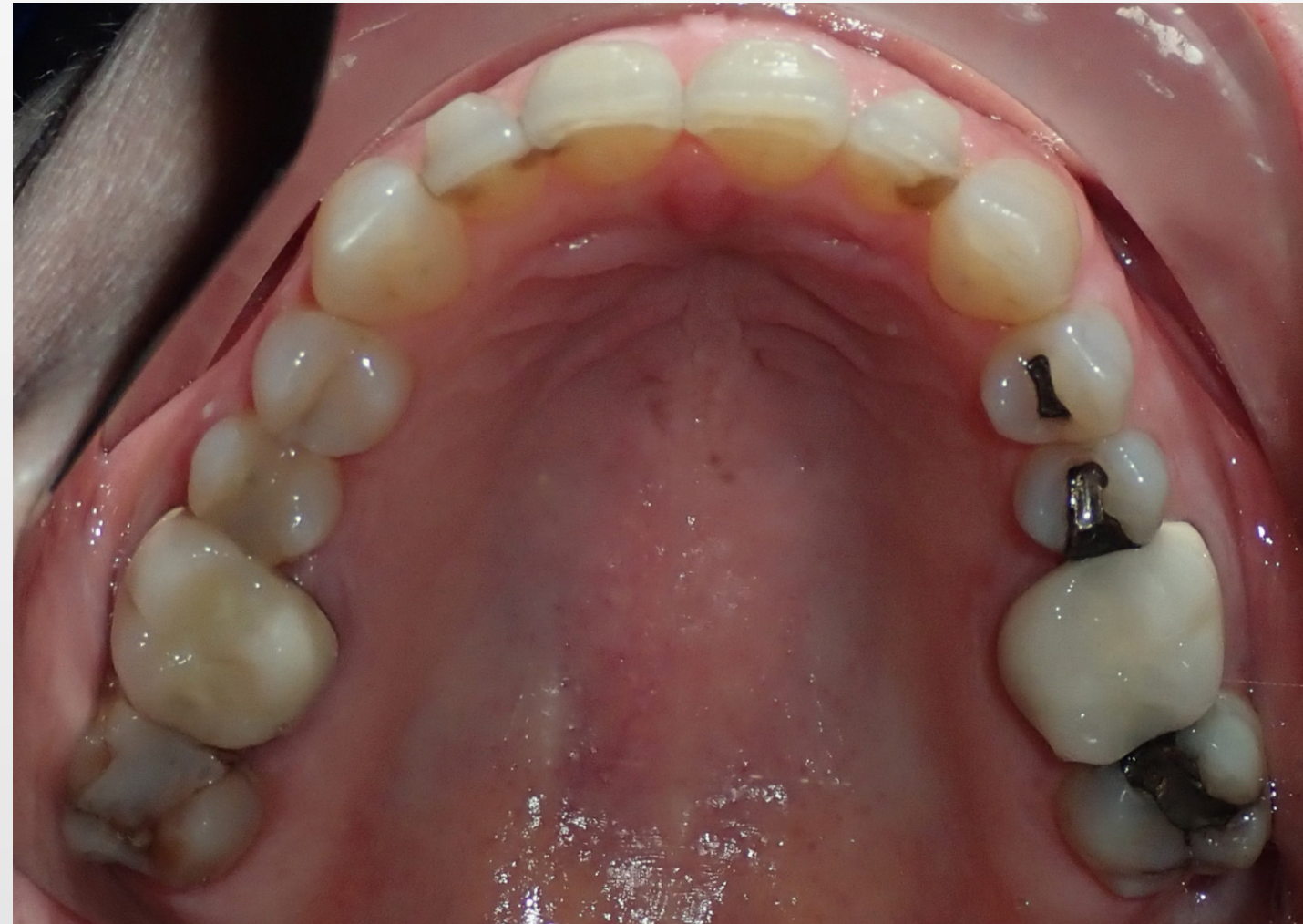
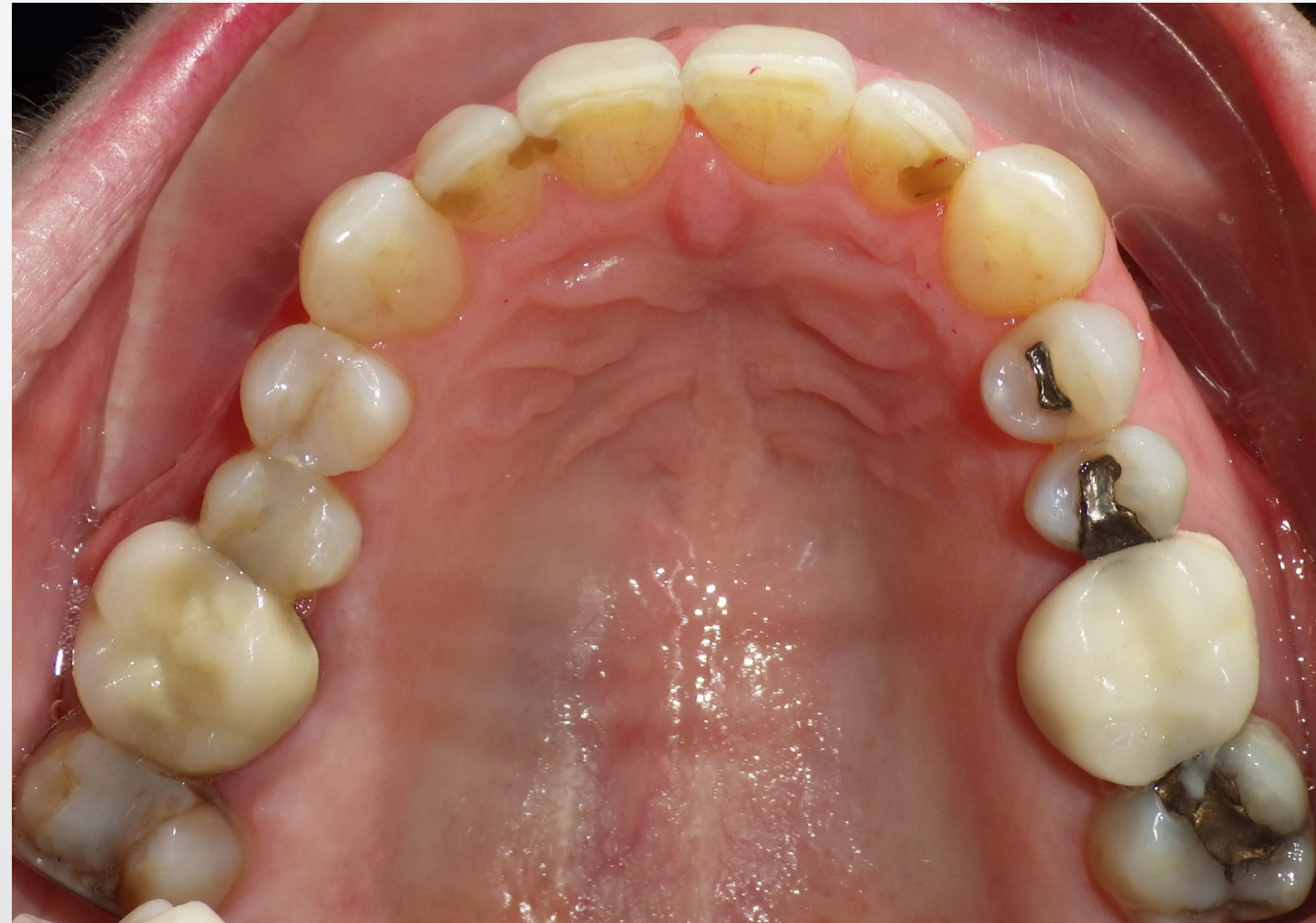Initial

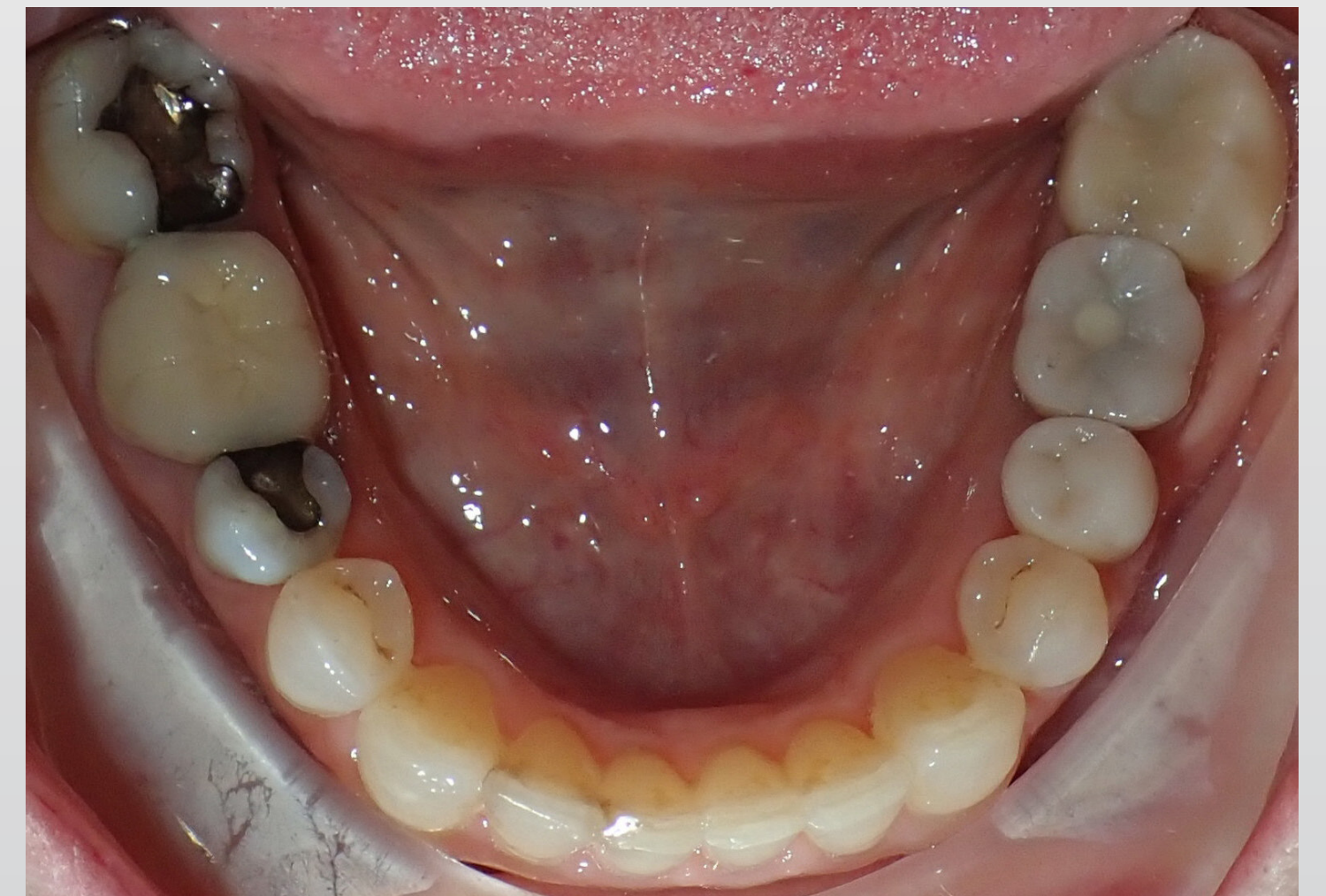
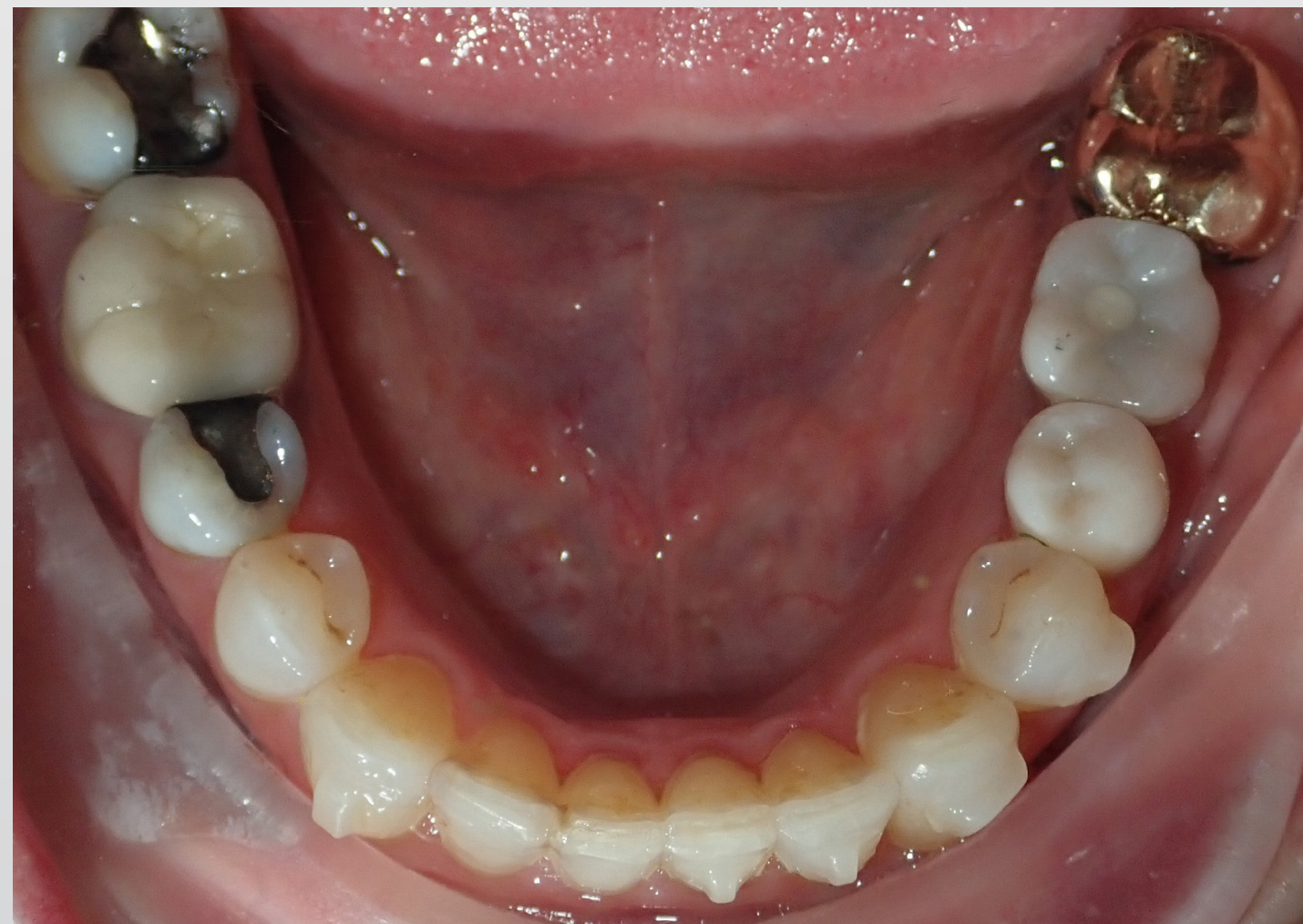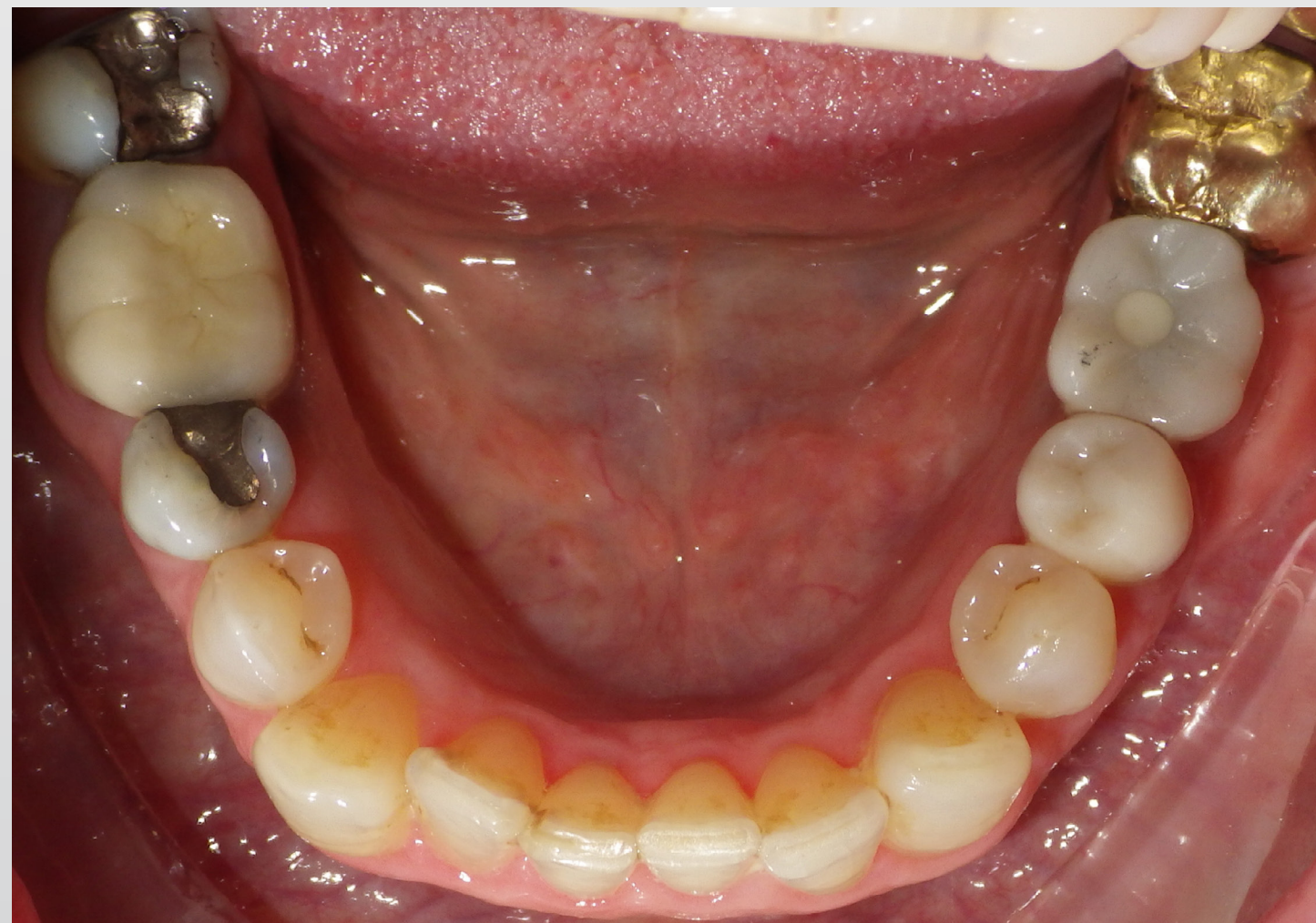Progress - 11.5 months

Final

**Occlusal –
maxillary**



**Occlusal –
mandibular**

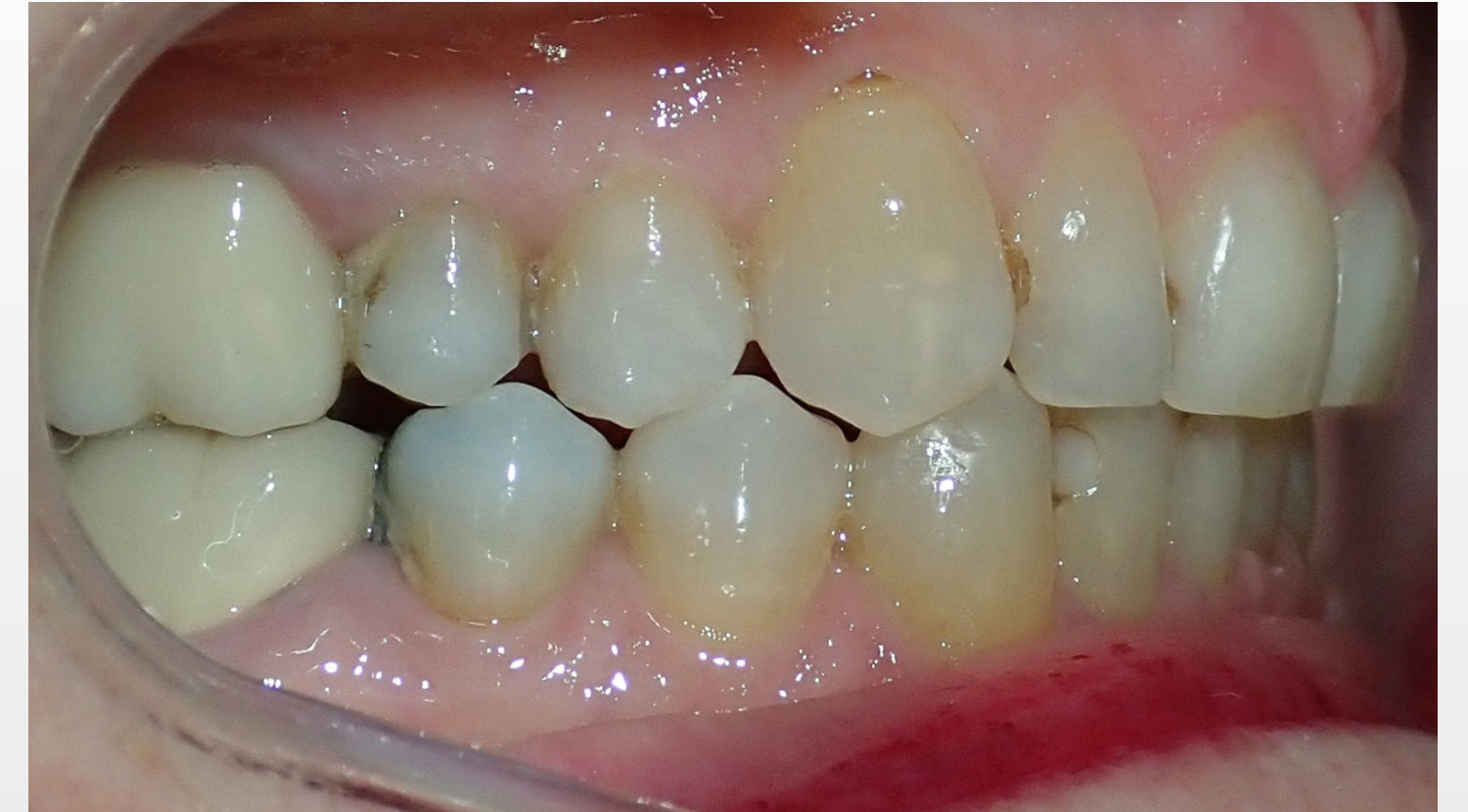
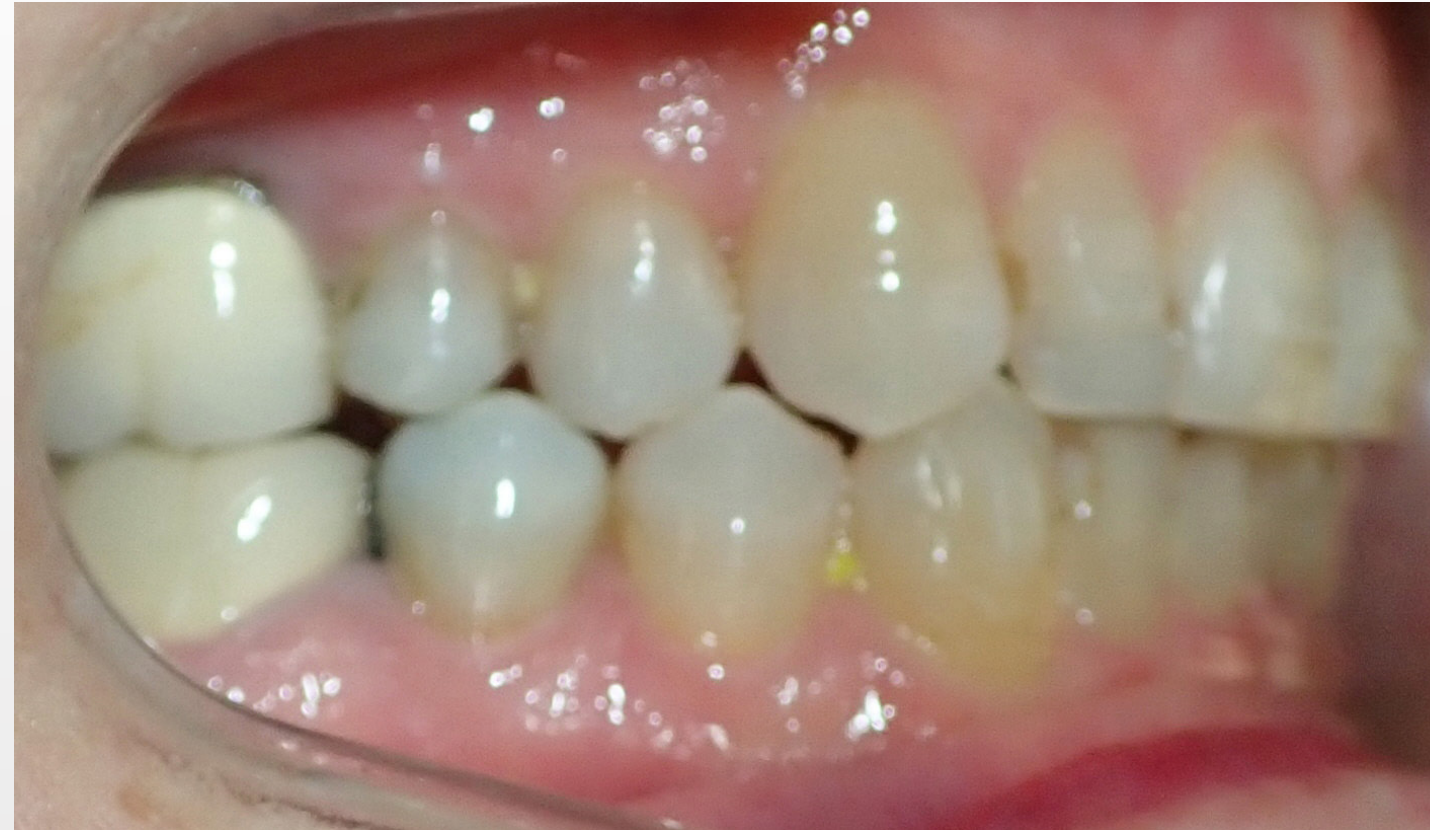
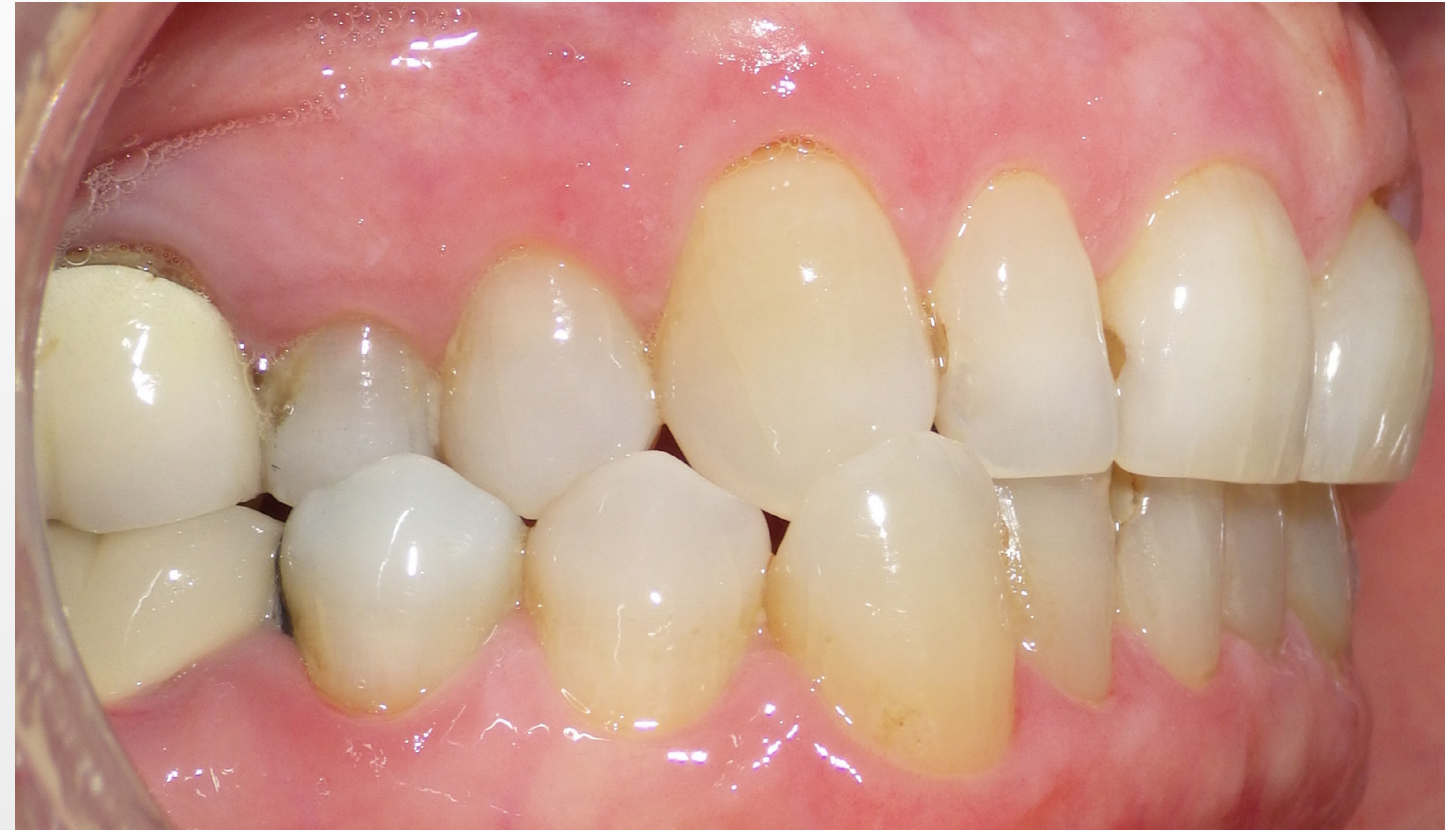Initial

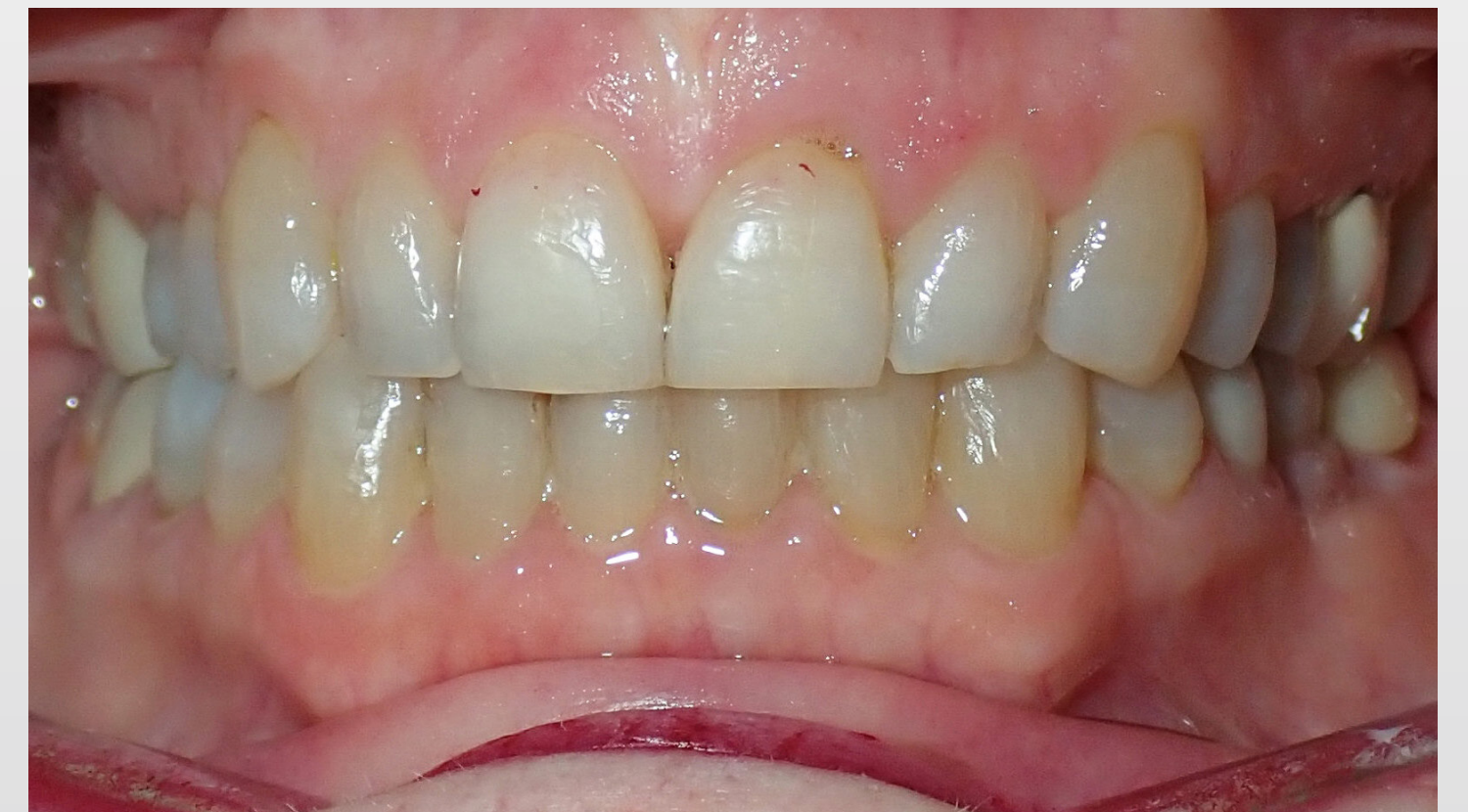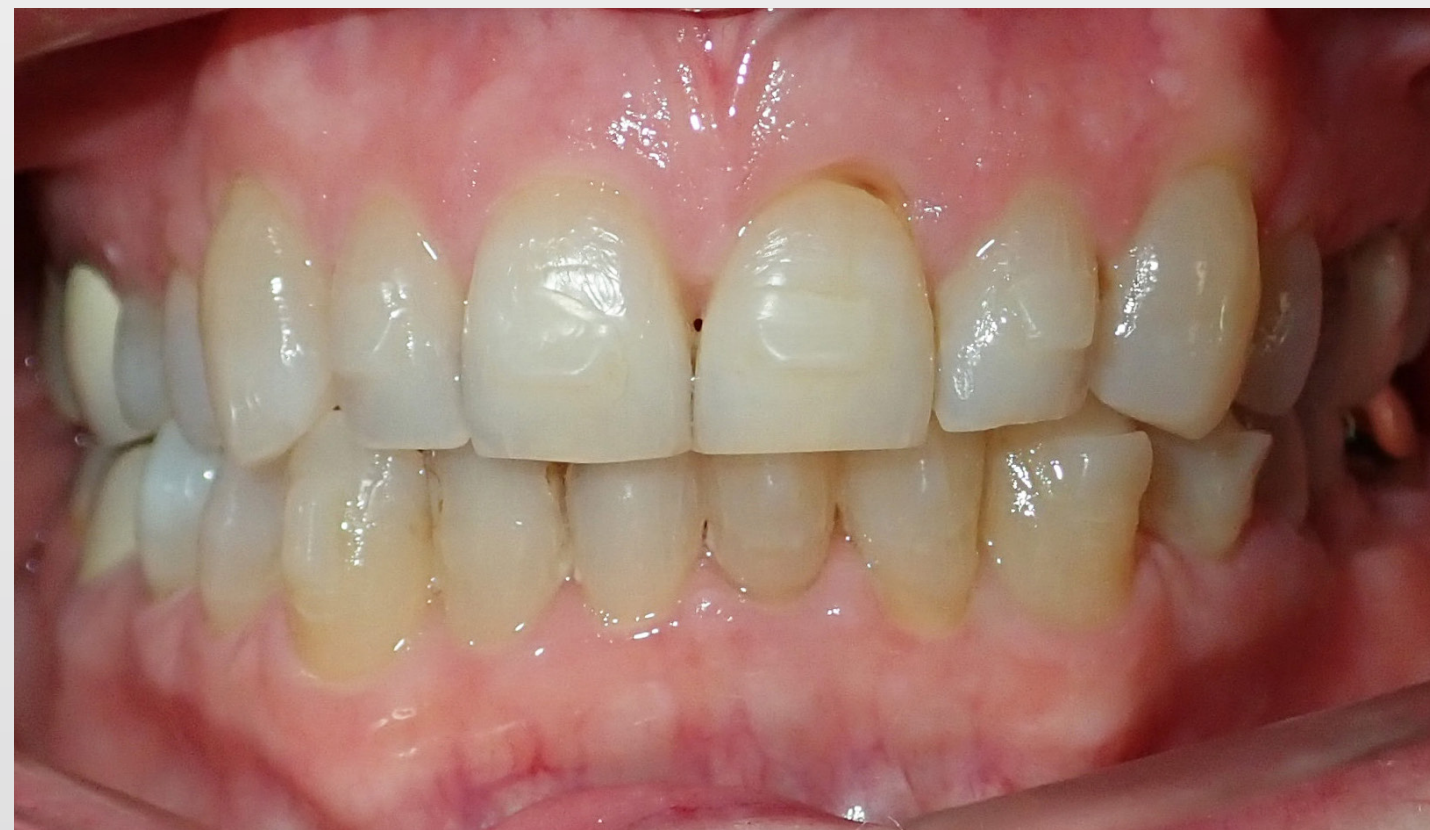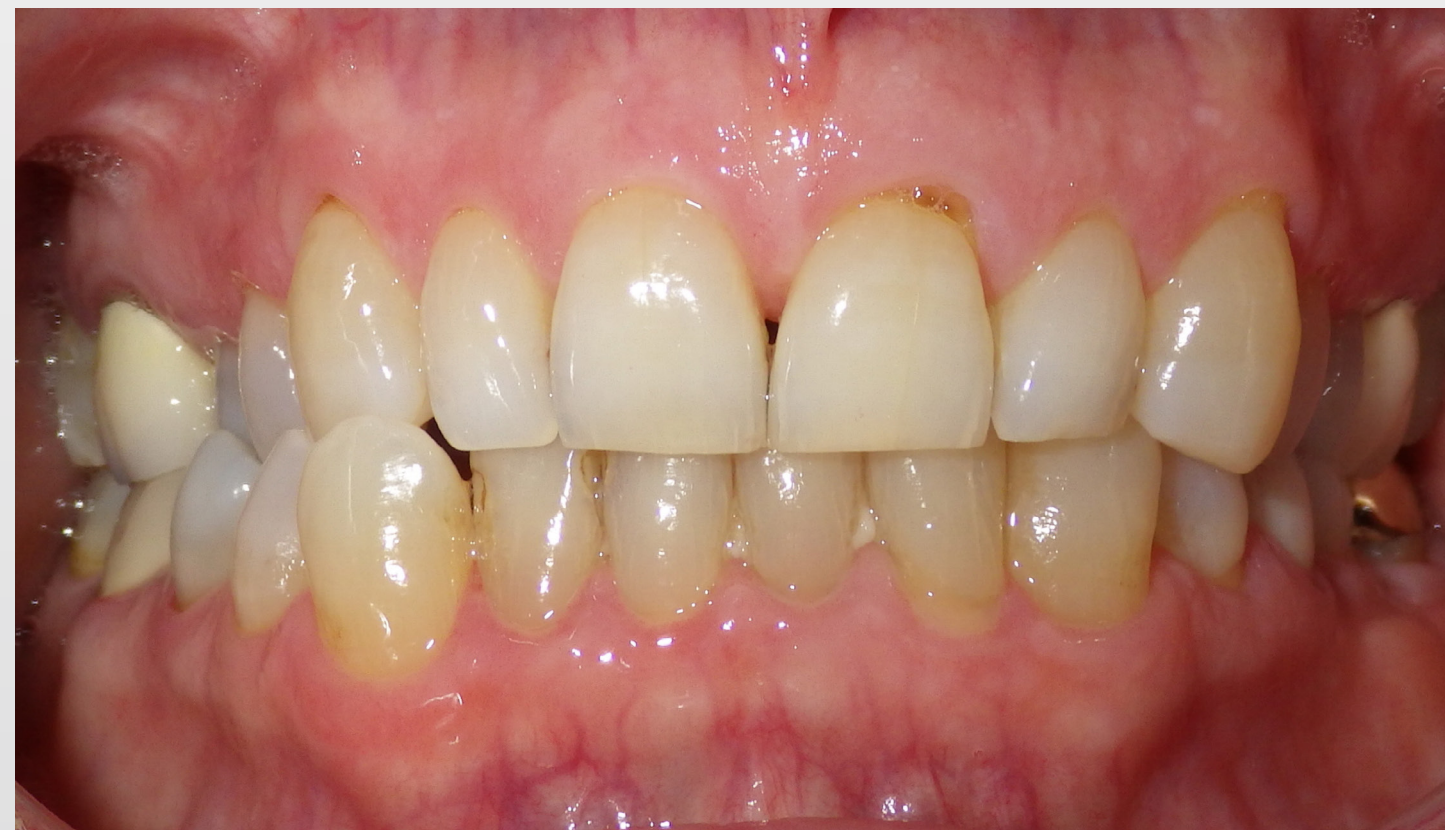Progress - 11.5 months

Final

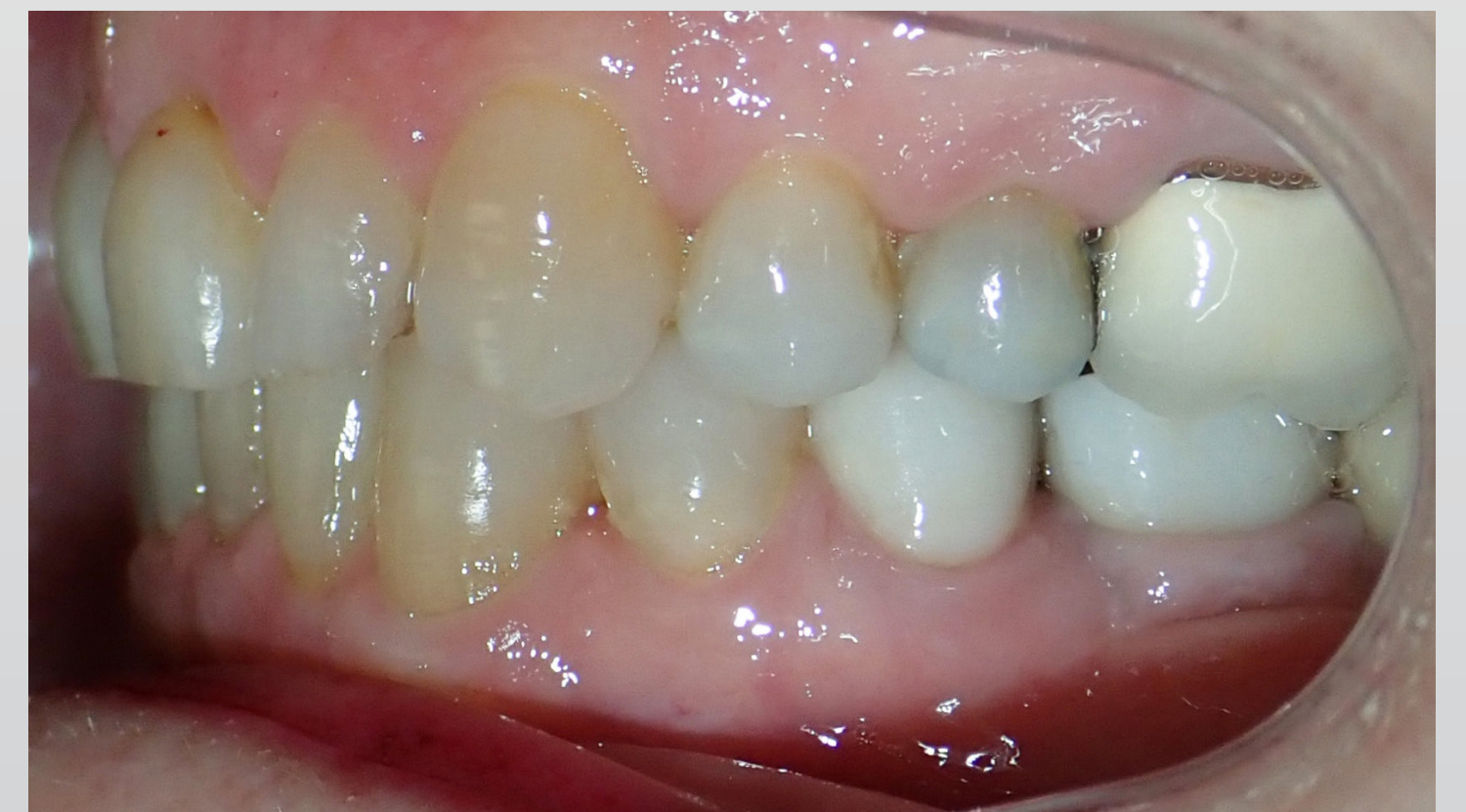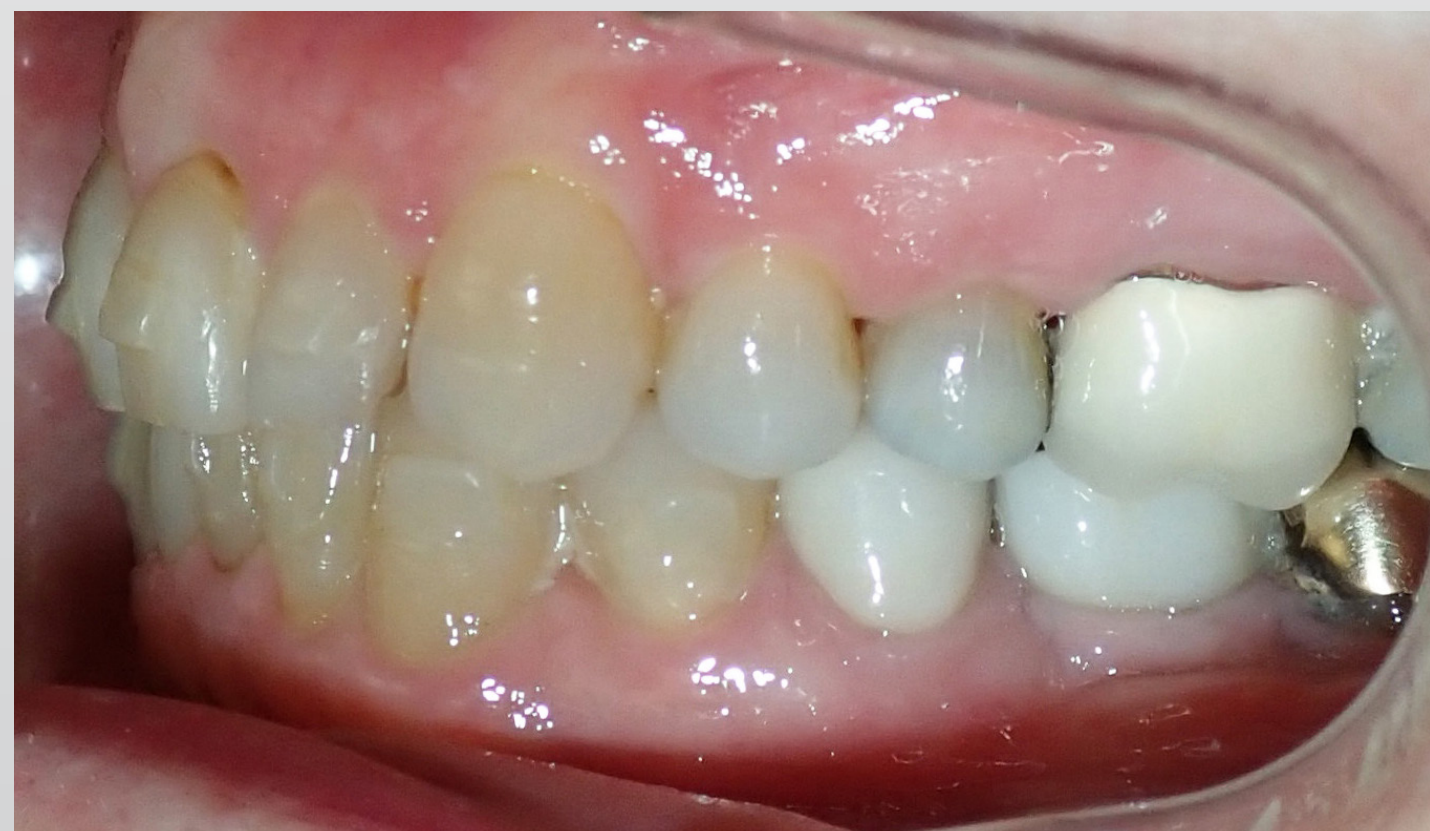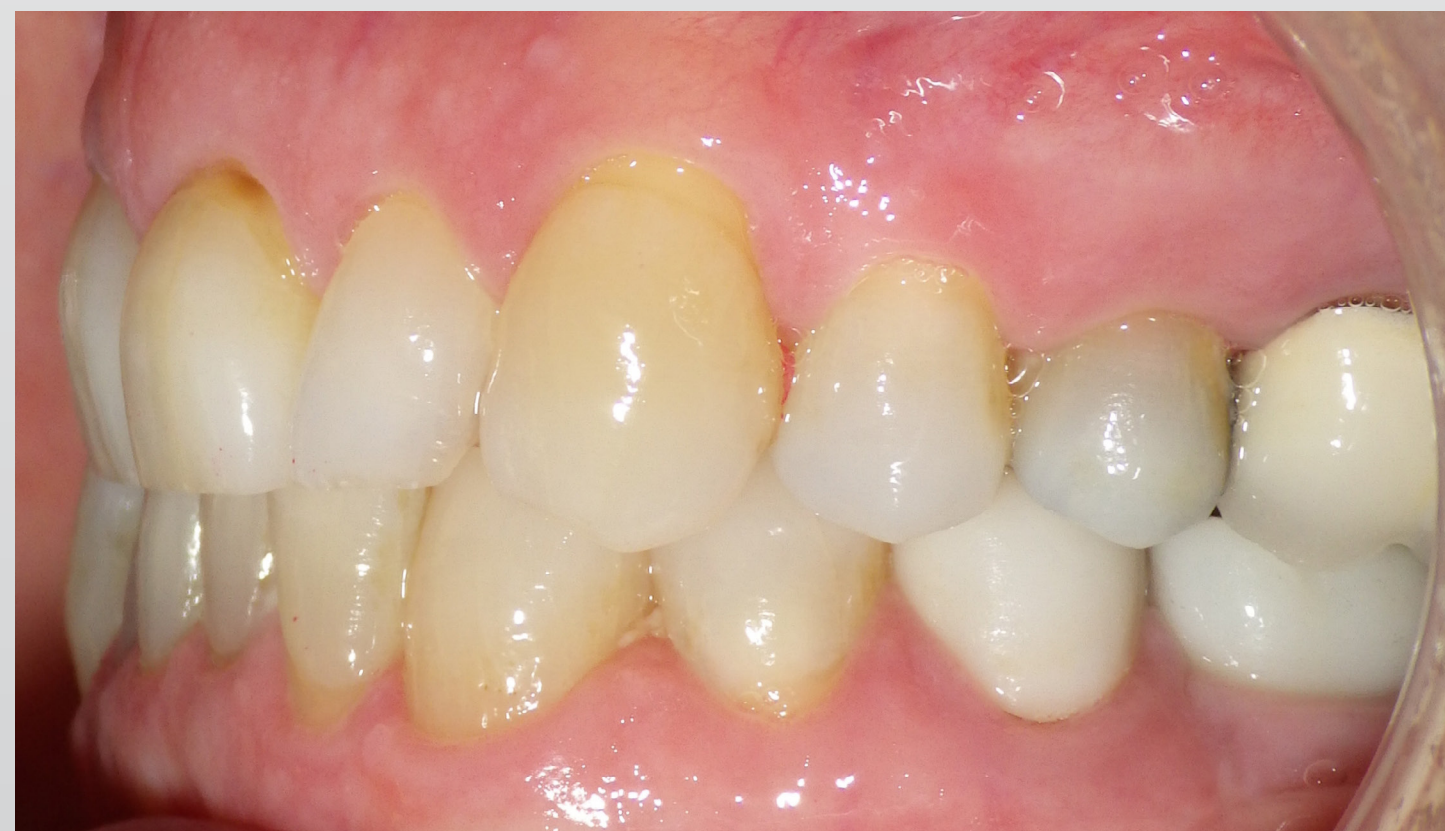**Retracted
buccal – right**



**Retracted
anterior
biting**

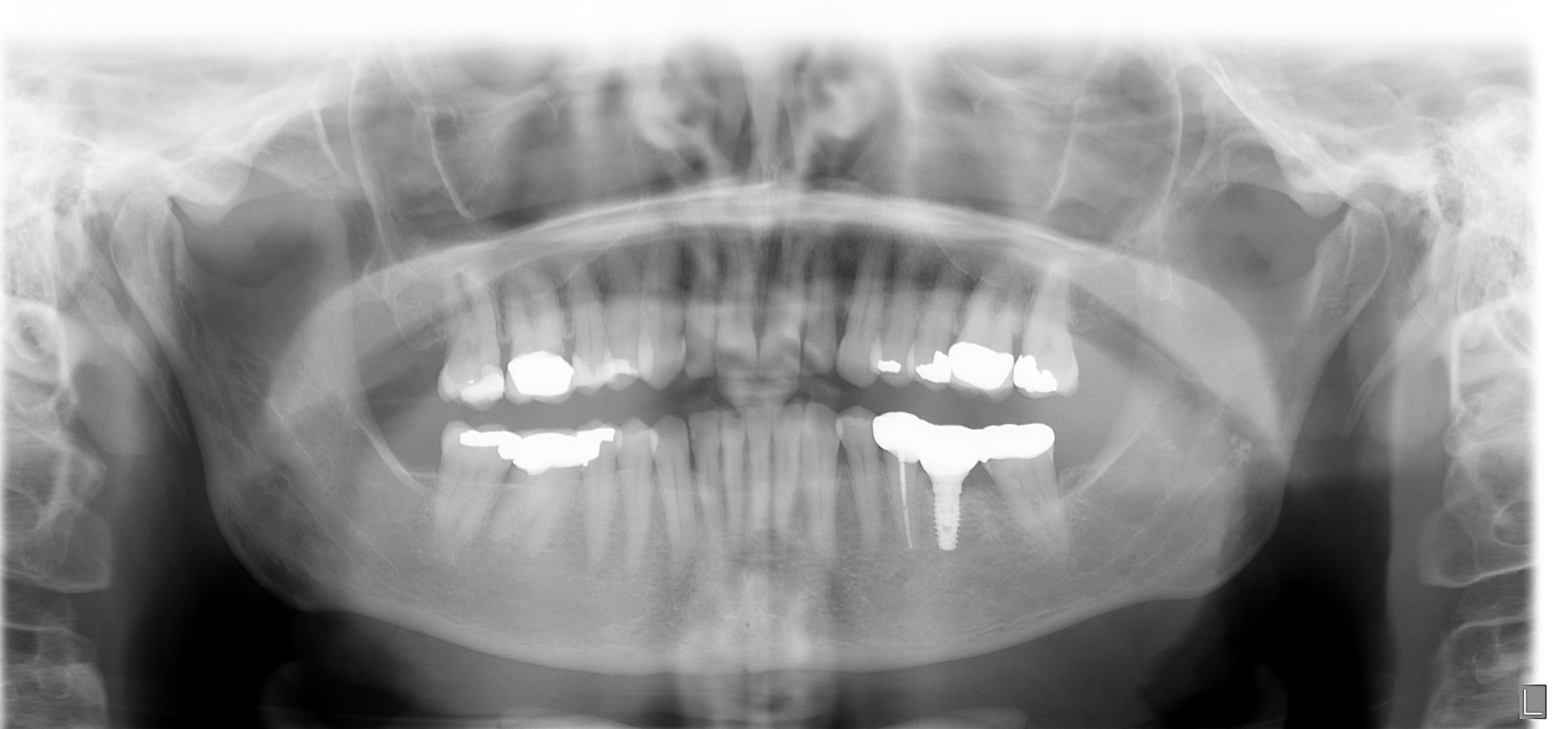

**Retracted
buccal – left**

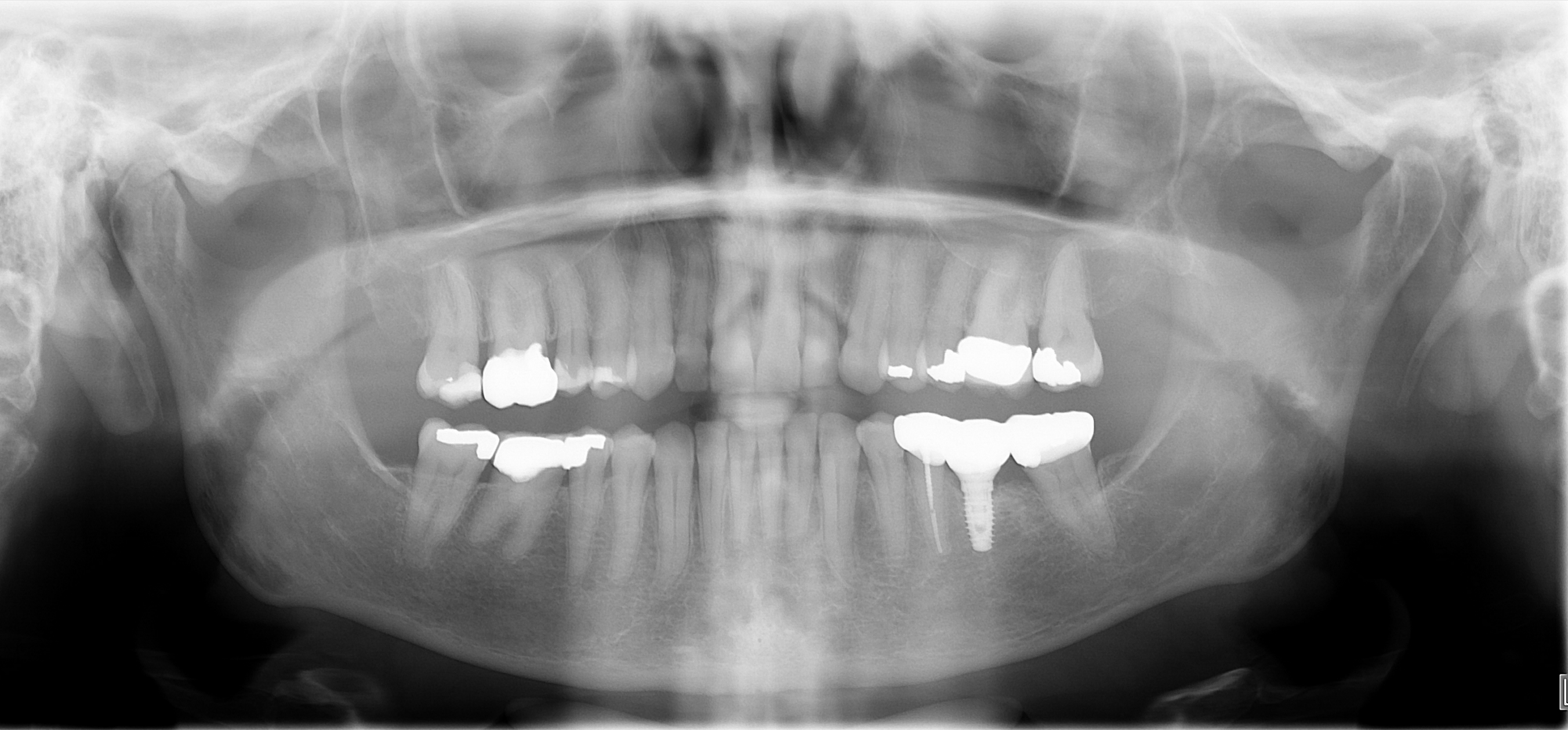

Panoramic radiograph

Initial



Final



Tx Design Video

- Treatment Plan
- Attachment Strategy
- Key Movements
- Summary of Final Results

Best Fit Overlay

