

Case study: 3M™ Clarity™ Aligners

Class 3 open bite with skeletal asymmetry (surgery was declined)

Age: 41

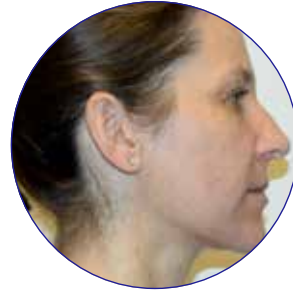Case summary

Number of aligners: 50 (dual arch)

Wear interval: Weekly

Treatment time: 16 months

Profile at rest (*initial*)



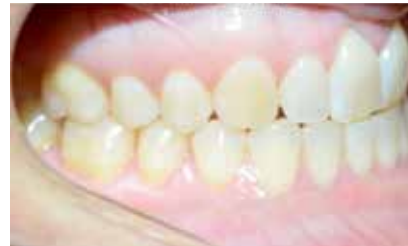Face at rest (*initial*)



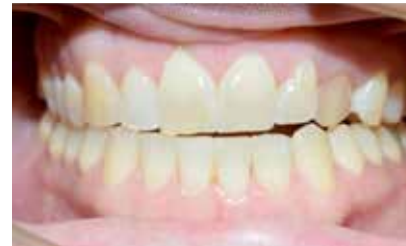Face smiling (*initial*)



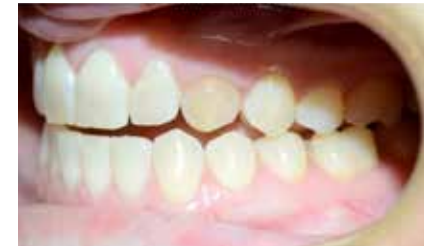Retracted Buccal (*initial*)



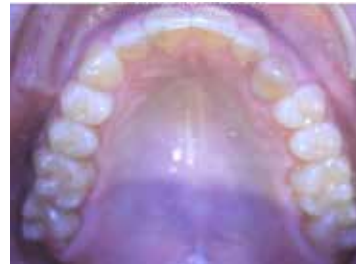Retracted anterior biting (*initial*)



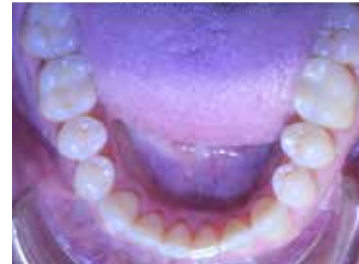Retracted Buccal (*initial*)



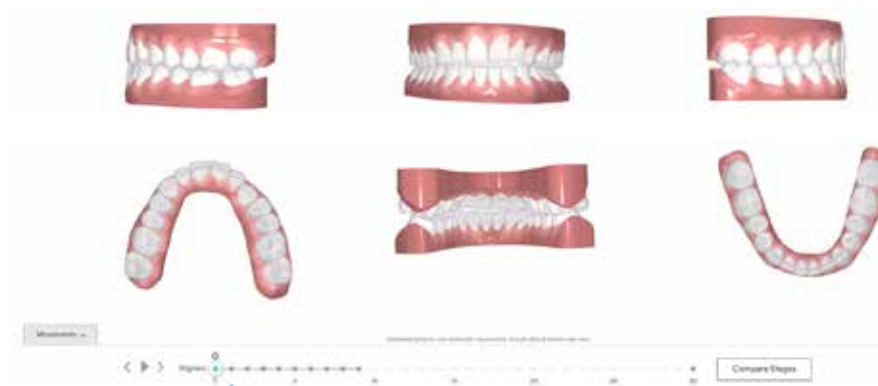
Occlusal – Maxillary (*initial*)



Occlusal – Mandibular (*initial*)



Oral Care Portal TxD (Initial)



Case courtesy of:
 Dr. Lisa Davison
 Powell, OH

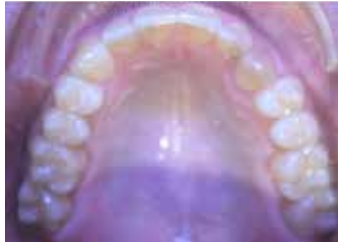

Clarity™

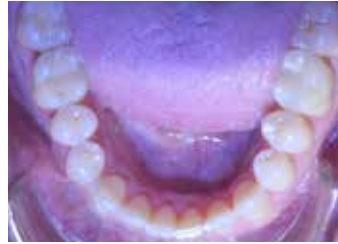Esthetic Orthodontic Solutions

Results

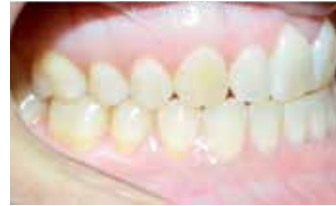Occlusal – Maxillary



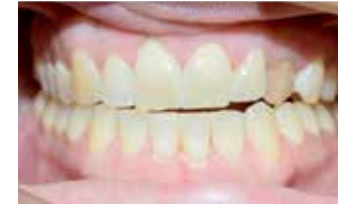Occlusal – Mandibular



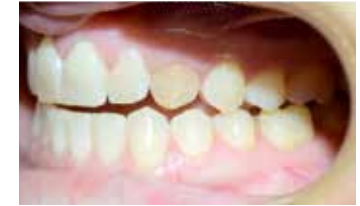Retracted buccal – Right



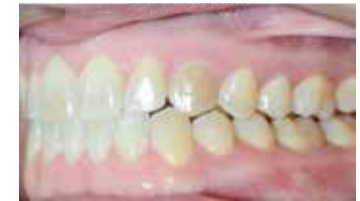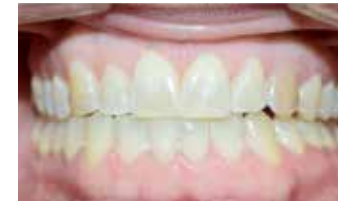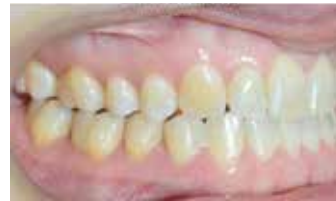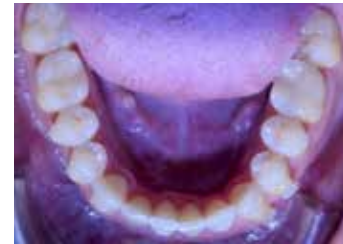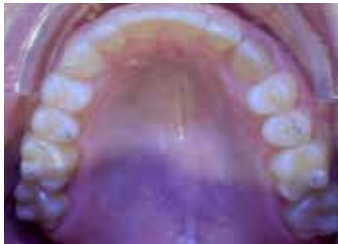Retracted anterior biting



Retracted buccal – Left

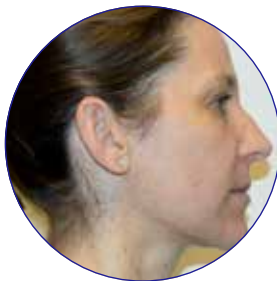

Initial



Final

Profile at rest



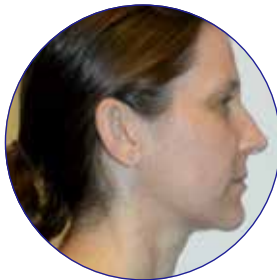Face at rest



Face smiling

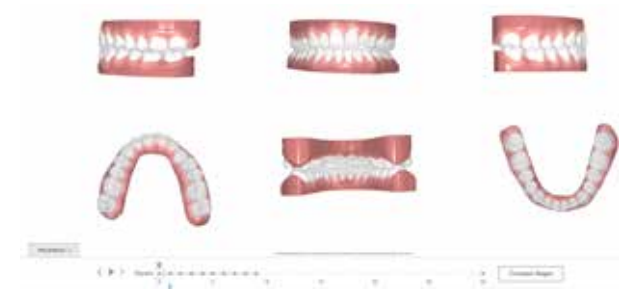


Initial



Final

Oral Care Portal TxD (Initial)



Oral Care Portal TxD (Final)

