

PREVENA RESTOR™

INCISION MANAGEMENT SYSTEM

Management of Bilateral Breast Reconstruction with PREVENA RESTOR BELLA•FORM™ Incision Management System

Abhishek Chatterjee, MD, MBA, Tufts Medical Center, Boston, MA

Patient

A 73-year-old female with symptomatic macromastia and left breast cancer presented to the clinic for oncoplastic surgery and a possible breast reduction with removal of axillary excess skin and fat (**Figure 1**). The patient was obese with high cholesterol and hypertension, and she had previously undergone surgery for breast cancer.

Procedure

The patient underwent oncoplastic surgery on her left side that included a large left sided partial mastectomy with a left sided breast reduction. She also underwent a symmetric right sided breast reduction. Both breast surgeries were closed using inverted-T incisions. Intraoperatively, the left nipple appeared blue secondary to indocyanine blue injection and venous congestion (**Figure 2**).

Application

Therapy with the PREVENA RESTOR BELLA•FORM™ Incision Management System was initiated at -125mmHg over both breasts (**Figure 3**). 3M™ Cavilon™ Advanced Skin Protectant was applied to the surrounding skin. The goals of therapy were management of the surgical incision and reduction of tensile forces across incision.

Discharge and Follow-up

The patient was discharged home the day of surgery. After 7 days, PREVENA RESTOR™ Therapy was discontinued, with the goals of therapy having been achieved. The incision had healed well and there were no signs of seroma or other postoperative complications. Upon follow-up 2 months post surgery, the incisions remained closed (**Figure 4**).

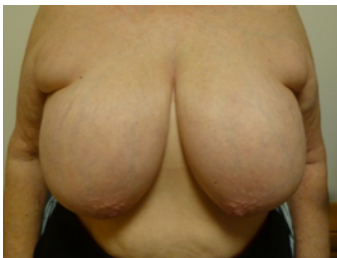

Figure 1. Patient appearance at presentation.

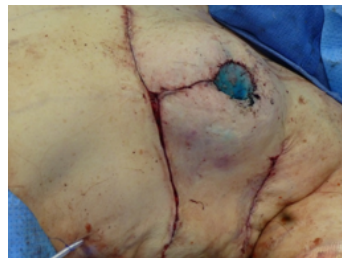

Figure 2. Blue coloring of the left nipple during breast reduction surgery, secondary to indocyanine blue injection and venous congestion.

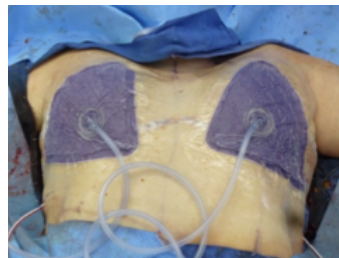


Figure 3. Application of therapy using PREVENA RESTOR BELLA•FORM™ Incision Management System over both breasts.

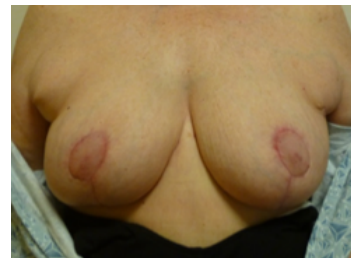

Figure 4. The incisions remained closed on both breasts at 2 months post surgery.

Patient data and photos courtesy of Abhishek Chatterjee, MD, MBA, Tufts Medical Center, Boston, MA.

NOTE: As with any case study, the results and outcomes should not be interpreted as a guarantee or warranty of similar results. Individual results may vary, depending on the patient's circumstances and condition.

NOTE: Specific indications, contraindications, warnings, precautions and safety information exist for these products and therapies. Please consult a clinician and product instructions for use prior to application. This material is intended for healthcare professionals.

© 2020 3M. All rights reserved. 3M and the other marks shown are marks and/or registered marks. Unauthorized use prohibited. PRA-PM-EU-00330 (07/20)