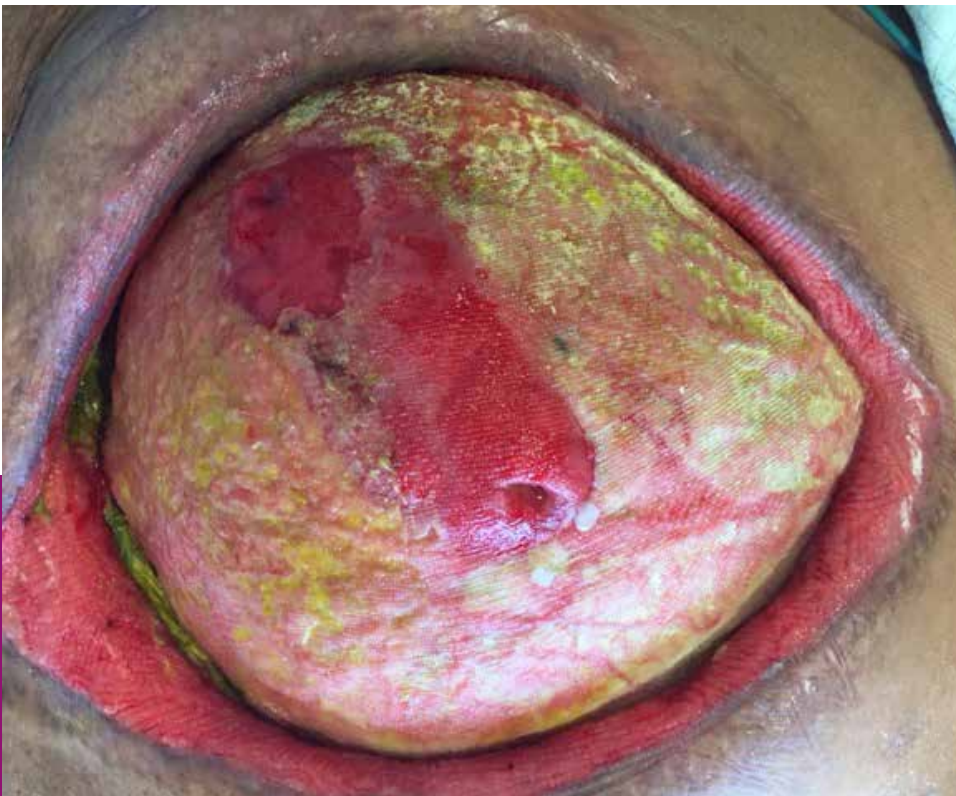

Enteric fistula effluent diversion devices

Isolate and divert effluent from enteroatmospheric fistulas, enterocutaneous fistulas, or an ostomy close to an incision.



The clinical challenges of fistulas

Isolating and diverting toxic effluent can help the wound heal.

Managing patients with complex abdominal wounds can be a struggle. Particularly challenging are enteric or intestinal fistulas that drain into open abdominal wounds. In a ten-year review of data from patients with enterocutaneous fistulas (ECFs) exclusively caused by trauma, Fischer, et.al found that these patients are at high risk of morbidity including malnutrition, poor wound healing, and sepsis¹.

Study design

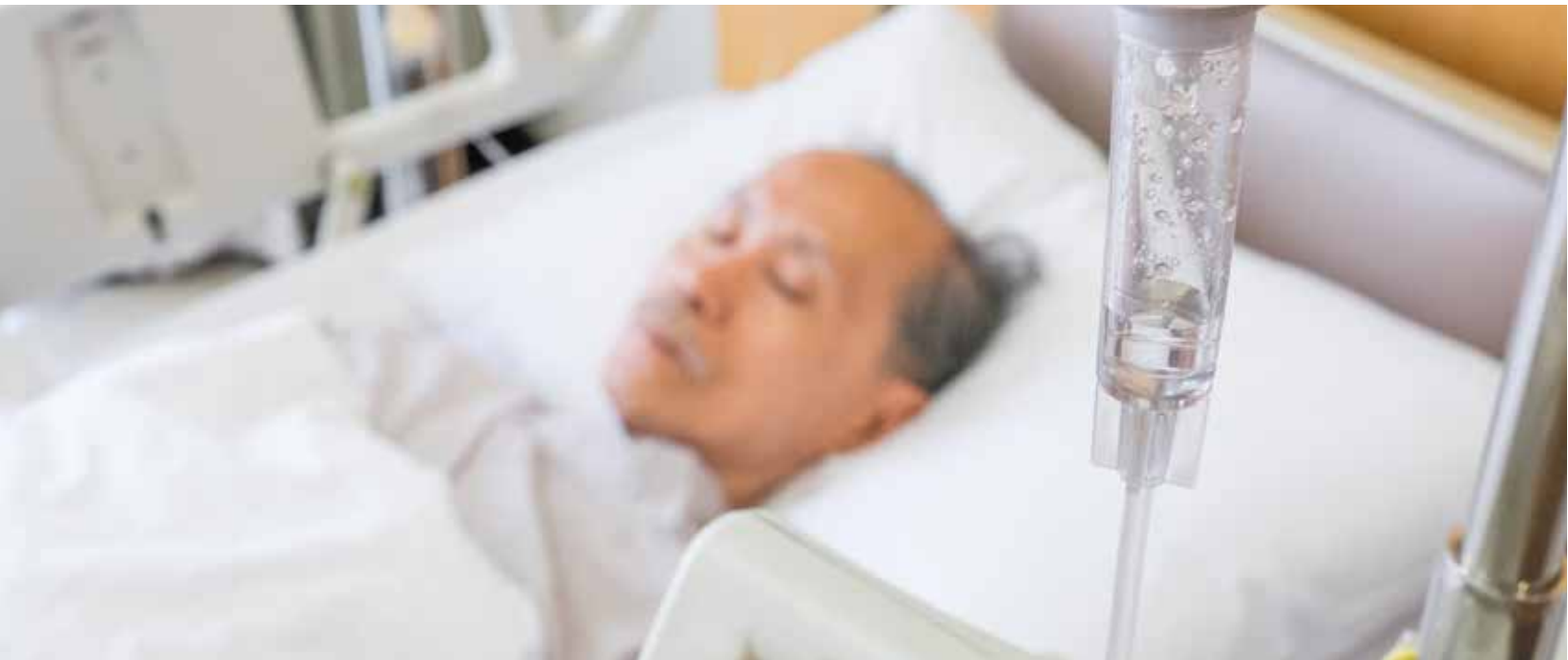- Trauma patients with ECF at a single regional trauma center.
- 10-year period was reviewed.
- Parameters studied included fistula output, site, nutritional status, operative history, and fistula resolution (spontaneous vs. operative).

Results

- Approximately 2 224 patients received a trauma laparotomy and survived longer than 4 days. Of these, 43 patients (1.9%) had an ECF.
- The rate of ECF in men was 2.22% and 0.74% in women.
- Patients with open abdomen had a higher ECF incidence (8% vs. 0.5%) and lower spontaneous closure rate (37% vs. 45%) compared to patients without open abdomen.
- Spontaneous fistula closure occurred in 31% of patients with high output fistulas, 13% with medium output, and 55% with low output.
- The mortality rate of ECF was 14% after an average stay of 59 days in the intensive care unit.

Conclusion

With damage-control laparotomies, the traumatic ECF rate is increasing and is a different entity than nontraumatic ECF. Although the two populations have similar mortality rates, the trauma cohort demonstrates higher spontaneous closure rates and a curiously higher rate of development in men. Fistula output was not predictive of spontaneous closure.



The cost of a fistula

A longitudinal study² of patients with abdominal trauma and ECF, showed a statistically significant hospital cost differential compared to controls with no fistula formation.

Study design

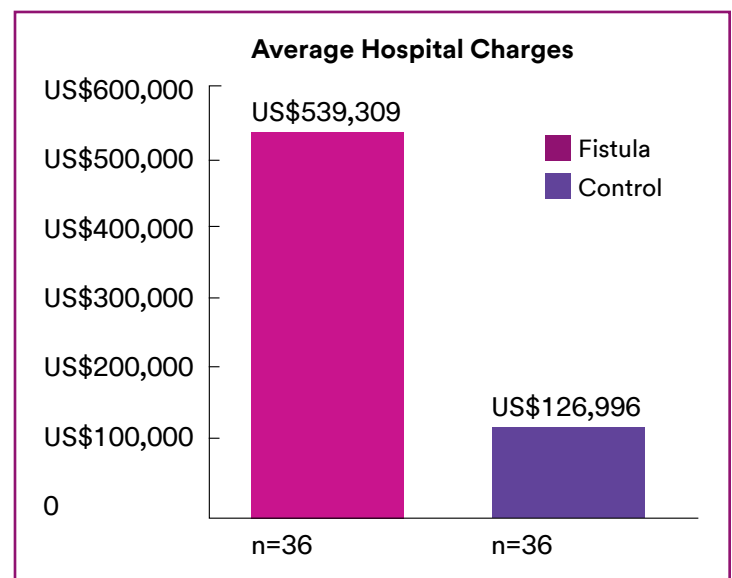
- Retrospective case-control study.
- All patients with enterocutaneous fistula (ECF) occurring after trauma laparotomy at an academic Level 1 trauma center were identified through a review of both the Trauma Registry and the Morbidity and Mortality reports for a 9-year period ending in December 2006.
- Each patient with an ECF was matched to one control (non-ECF) that did not develop this complication.
- Matching criteria were comprised of age, gender, mechanism of injury, Injury Severity Score, hypotension on admission, Glasgow Coma Scale, and the requirement for damage control laparotomy requiring an open abdomen.
- Outcomes analyzed: intensive care unit (ICU) and hospital length of stay, mortality, and total hospital charges.
- 56% of the ECF patients had multiple hollow viscus injuries.
- The development of an ECF was associated with significantly increased:
 - ICU length of stay (28.5 ± 30.5 vs. 7.6 ± 9.3 days, p=0.004)
 - hospital length of stay (82.1 ± 100.8 vs. 16.2 ± 17.3 days, p<0.001)
 - hospital charges (\$539,309 +/- \$623,222 vs. \$126,996 +/- \$171,450, p<0.001)
 - The total hospital costs were on average \$412,313 more expensive for patients with and ECF.

Results

- 2 373 acute laparotomies were performed.
- 36 (1.5%) patients developed an ECF, and were matched to 36 controls.
- Patients with an ECF were 31 ± 12 years of age, 97% male, had a mean Injury Severity Score of 21 ± 10, and 75% were penetrating wounds.
- 89% of the ECF patients had a hollow viscus injury. The most common was colon (69%), followed by small bowel (53%), duodenum (36%), and stomach (19%).

Conclusion

The authors found that the development of an ECF after laparotomy for trauma resulted in a significant impact on resource utilization including longer Intensive Care Unit (ICU) and hospital lengthof stay and higher hospital charges.



Longer ICU stay, longer hospital stay, higher daily cost of care all contribute to the expense.²

Fistula Solution® Devices

Help improve the management of patients with enteric fistulas using the **WOUND CROWN®**, **FISTULA FUNNEL®** and **ISOLATOR STRIP®**.

- Diverts effluent from wound site
- Simple and easy to understand product application
- One piece, compressible isolation device
- Can be trimmed to handle different sizes and numbers of fistulas

The **WOUND CROWN®**, **FISTULA FUNNEL®** and **ISOLATOR STRIP®** are intended for use for fistula management only. Following application, the surrounding wound should be treated according to hospital policy or clinical practice.

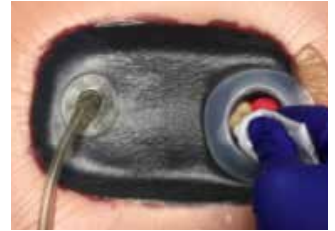
WOUND CROWN®



- Isolates and controls the effluent of enteric fistulas and ostomy stomas

When to use:

- General applications
- Small intestinal fistula
- Ileostomy



Trim WOUND CROWN® and place dressing between flanges of WOUND CROWN®. Place dressing in wound bed. Apply drape over all and cut hole in drape to expose fistula. Apply stoma paste if needed to get a seal. Apply ostomy appliance to collect effluent. Initiate NPWT.

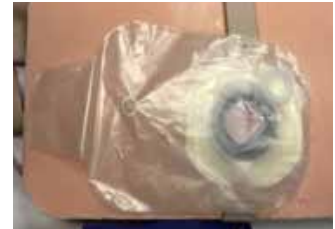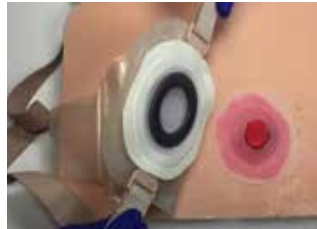FISTULA FUNNEL®



- Tapered design flexes to isolate sidewall fistulas
- Sizeable to 1, 2, or 3cm isolation area diameter

When to use:

- Small sized fistulas
- Sidewall fistulas
- Deep crevice wound bed areas



Place trimmed FISTULA FUNNEL® over stoma and denuded skin. Consider a heavy skin protectant. Using a belted pouching system, place over the FISTULA FUNNEL®. Secure belt.

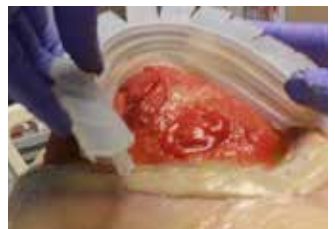
ISOLATOR STRIP®



- Flexible strip designed to be shaped as needed for specific isolation applications

When to use:

- Large fistulas
- Group of fistulas
- Large or uniquely shaped wound bed areas



Place dressing between flanges.

Published evidence

A published case series of patients treated with the WOUND CROWN® device found³:

- Control of effluent is critical to protect the wound bed from the corrosive effects of bowel contents and to allow the surrounding wound bed to develop granulation tissue.
- Inability to control effluent often requires both specialized wound care personnel and prolonged inpatient hospitalization.

Methods

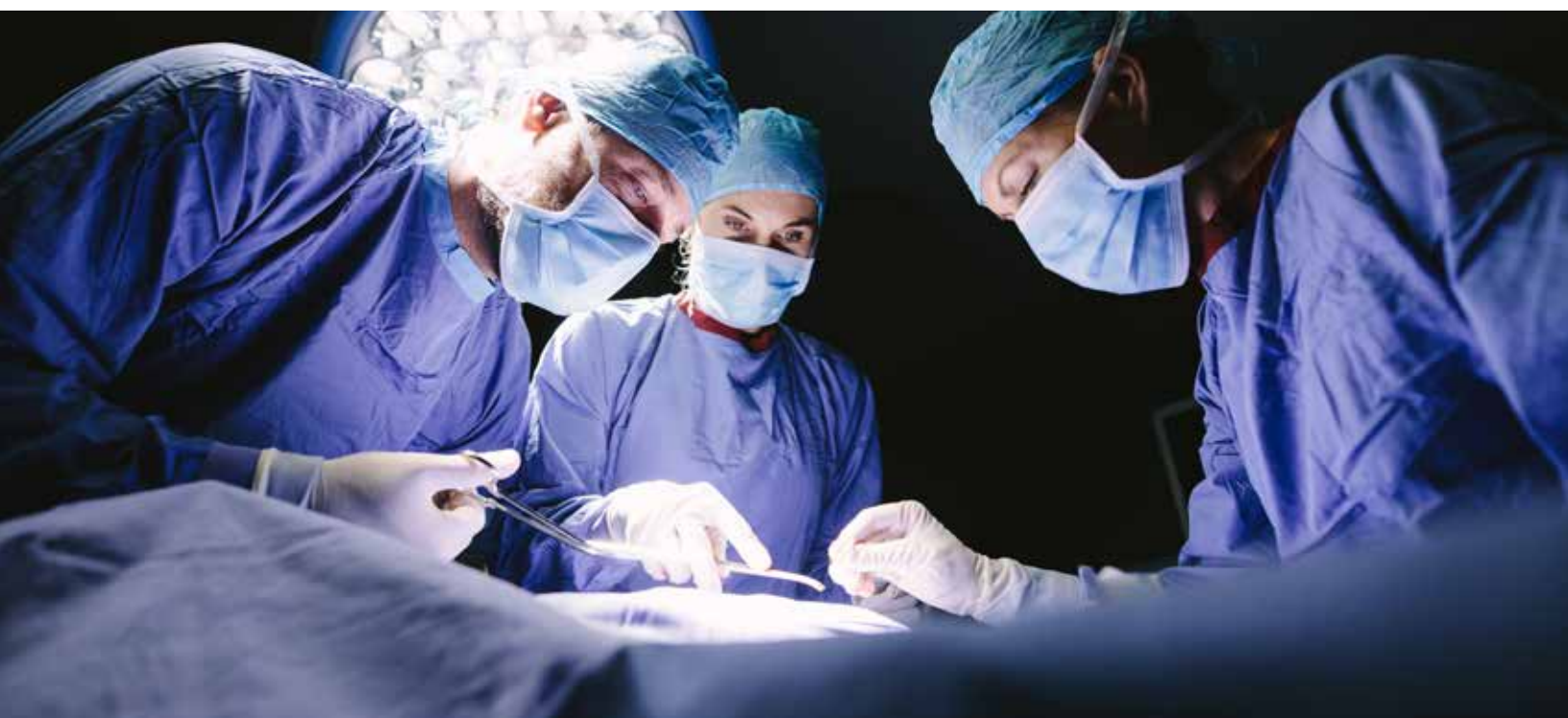- Four patients presented with enteroatmospheric fistulas (EAF).
- All patients had high fistula outputs, greater than 500ml/day.
- All fistulas were isolated with the Wound Crown® and the surrounding wounds with 3M™ V.A.C.® Therapy.
- After wound healing was complete, the fistula effluent was collected with an ostomy appliance.

Results

- All patients achieved excellent control of fistula effluent.
- Two patients were weaned off Total Parenteral Nutrition (TPN) before discharge, and both were tolerating a regular diet with excellent control of fistula effluent.
- Two patients were continued on TPN, in addition to an enteral diet, secondary to the proximal nature of the EAF.
- All patients were able to be mobilized and actively participate in physical therapy.
- Three patients underwent skin grafting of their open abdominal wound.
- After grafting, the Wound Crown® was reapplied in a similar fashion, and it provided excellent effluent control with an ostomy appliance.

Conclusion

The authors concluded that complete control of fistula effluent was noted which allowed the wounds to heal thus allowing early skin grafting of the abdominal wounds.



Case study

Fistula management

Patient:

The patient was a 54-year-old female with morbid obesity (body mass index >40kg/m²).

Diagnosis:

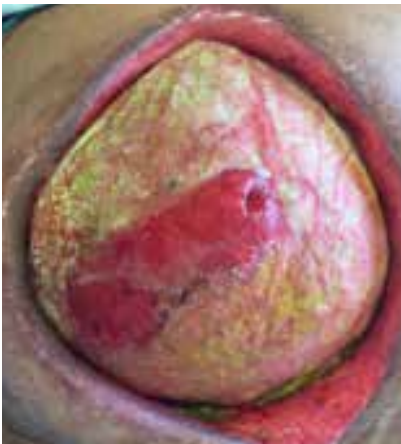The patient was admitted to the hospital with a small bowel obstruction and large ventral hernia. She underwent an exploratory laparotomy with lysis of adhesions and ventral hernia repair with mesh placement, and ultimately developed an enteroatmospheric fistula (EAF).

Treatment:

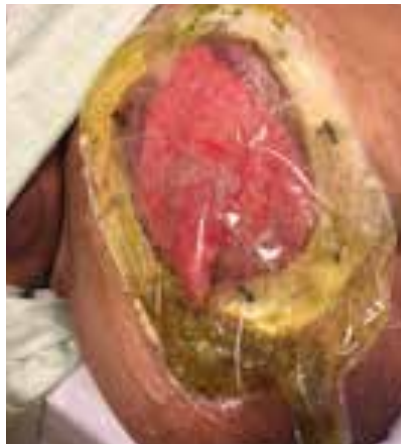A fistula management pouch was utilized for several months to encompass the wound and contain effluent. This method proved to be ineffective. The fistula was then isolated utilizing the WOUND CROWN® (a collapsible EAF isolation device) and an ostomy appliance to contain effluent. The wound was then managed with negative pressure wound therapy (NPWT). Contraction of wound edges and presence of granulation tissue were observed after NPWT use in the wound bed around the isolated EAF. Seven months after presentation, the patient underwent abdominal wall reconstruction and closure followed by 5 days of postoperative closed incision negative pressure therapy.

Discharge:

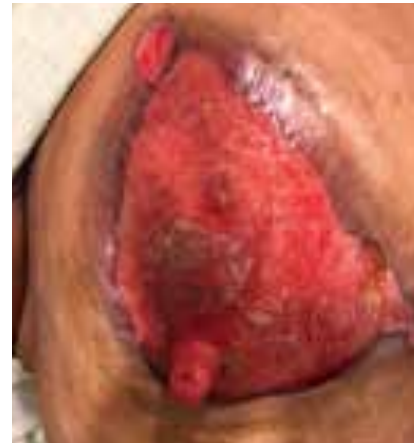The patient was successfully discharged to home under the care of visiting nurses following incision closure.



A. Abdominal wound (27 × 17 × 8cm) at presentation with 2 visible EAFs.



B. Wound with fistula management pouch to contain effluent. Pouch was changed daily at a skilled nursing facility secondary to leakage.

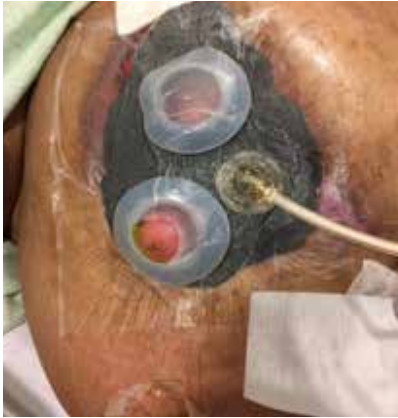

C. Wound (25 × 16 × 2cm) after pouch removal.

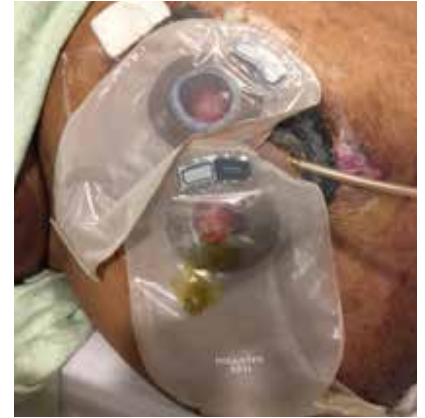Case study (cont.)



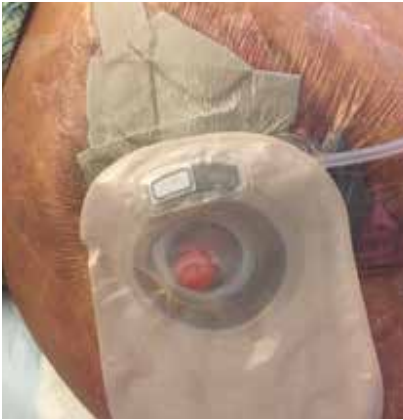D. Negative pressure polyurethane foam with the WOUND CROWNS® and barrier rings.



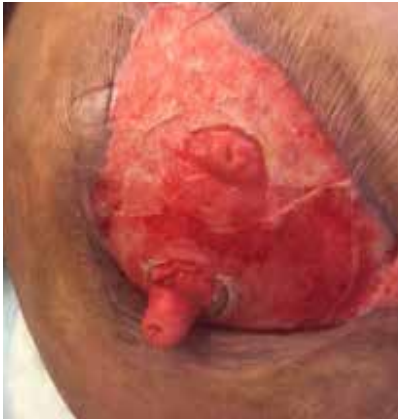E. Application of NPWT and the use of the WOUND CROWNS® to isolate the fistulas.



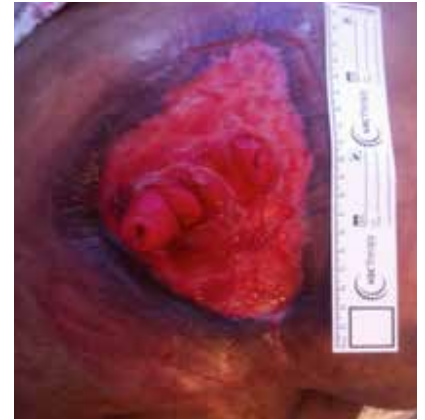F. Ostomy appliances placed over the WOUND CROWNS® to collect effluent while NPWT is in place.



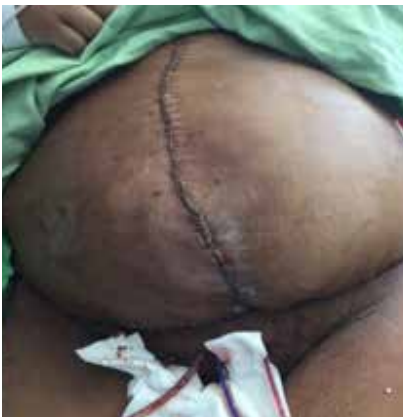G. Silver foam dressing applied to the superior aspect of the wound; black foam to the inferior aspect of the wound with the WOUND CROWN® and ostomy appliance.



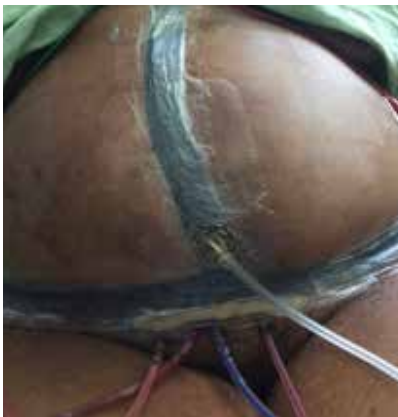H. Abdominal wound 4 months from presentation (21 × 13 × 0.5cm) at discharge to home care.



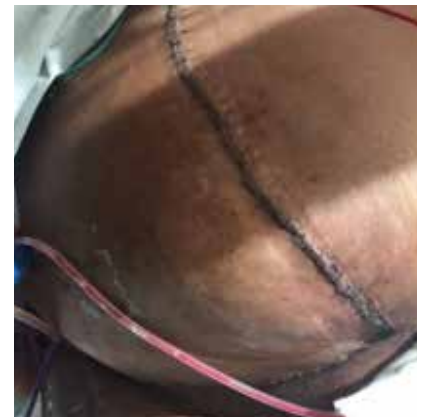I. Abdominal wound 6 months after presentation (14 × 11.5 × 0.4cm).



J. Abdominal wall reconstruction and closure 7 months after presentation.



K. ciNPT applied for 5 days postoperatively



L. Incision after removal of ciNPT.

Ordering information

	Quantity	Item Number
WOUND CROWN®	Each	00860013000301
FISTULA FUNNEL®	Each	00860013000325
ISOLATOR STRIP®	Each	00860013000318

WOUND CROWN®



FISTULA FUNNEL®



ISOLATOR STRIP®



To learn more or to order the Fistula Solution® Devices, contact your 3M representative.

References

1. Fischer PE, Fabian TC, Magnotti LJ, et.al. A ten-year review of enterocutaneous fistulas after laparotomy for trauma. J Trauma 2009; 67:924-928
2. Teixeira PG, Inaba K, et.al; Enterocutaneous fistula complicating trauma laparotomy: A major resource burden; The American Surgeon 2009; 75:30-32
3. Heineman JT, MD, MPH, Garcia LJ, MD, FACS, Obst MA, RN, BSN, CCRN, CWOCN, et.al. Collapsible Enteroatmospheric Fistula Isolation Device: A Novel, Simple Solution to a Complex Problem; Journal of the American College of Surgeons; 2015.

Note: Specific indications, contraindications, warnings, precautions and safety information exist for these products and therapies. Please consult a clinician and product instructions for use prior to application. Rx only.

The Wound Crown®, Fistula Funnel®, and Isolator Strip® are manufactured by Fistula Solution Corporation. 3M is the exclusive distributor.



3M Company
2510 Conway Ave
St. Paul, MN 55144 USA

Phone 1-800-275-4524 (NPWT products)
1-800-228-3957
Web 3M.com/medical

© 2021 3M. All rights reserved. 3M and the other marks shown are marks and/or registered marks. Unauthorized use prohibited. The Wound Crown®, Fistula Funnel®, and Isolator Strip® are manufactured by Fistula Solution Corporation. 70-2013-1121-7 PRA-PM-US-03291 (11/21)