

Post-Acute Case Studies

Learn how 3M Negative Pressure Wound Therapy (NPWT) and Advanced Wound Care (AWC) solutions can help provide comprehensive wound management from start to finish.



Introduction

This booklet includes case studies across several wound types. As with any case study, the results and outcomes should not be interpreted as a guarantee or warranty of similar results. Individual results may vary depending on the patient's condition and circumstances.

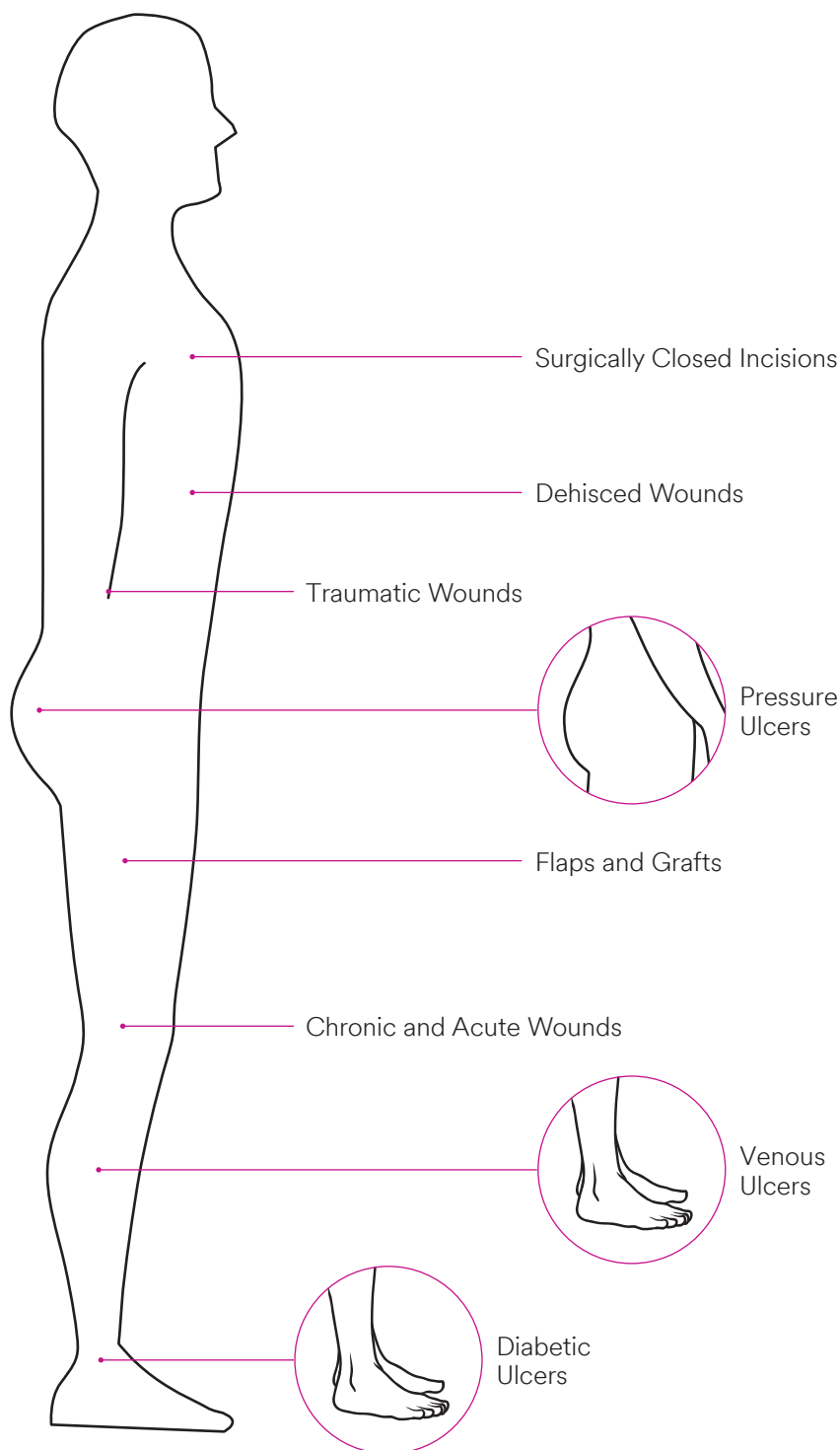
NOTE: Specific indications, contraindications, warnings, precautions, and safety information exist for these products and therapies, some of which may be Rx only. Please consult a clinician and product instructions for use prior to application.

Table of Contents

3M™ V.A.C.® Therapy System and 3M™ Snap™ Therapy System Indicated Wound Types	3
Benefits of <u>Early Initiation</u> of 3M™ V.A.C.® Therapy on Acute and Chronic Wounds.....	4
3M™ ActiV.A.C.™ Therapy System at a Glance	5
3M™ Snap™ Therapy System at a Glance.....	6
Select the Appropriate 3M Product.....	7
Surgical Dehisced	
Case Study 1: Sequential Wound Management Employing a Multimodal Approach to Wound Dehiscence Post Metatarsalphalangeal Joint Arthrodesis.....	8
Traumatic	
Case Study 2: Multimodal Management of Gas Gangrene and a Diabetic Foot in a Post-acute Setting	10
Chronic	
Case Study 3: Management of an Infected Incision and Drainage Wound with Undermining in a Post-acute Setting.....	12
DFU	
Case Study 4: Sequential Wound Management Employing a Multimodal Approach to Manage an Infected Diabetic Foot Wound	14
VLU	
Case Study 5: Venous Stasis Ulcer of the Lower Extremity	16
Case Study 6: Wound Management of Venous Leg Ulcers in the Right Lower Extremity Using Super-Absorbent Dressing and a Two-layer Compression Wrap.....	18
Case Study 7: Multimodal Wound Management of an Infected Venous Leg Ulcer	20
Pressure Injury	
Case Study 8: Pressure Injury Management in a Skilled Nursing Environment	22
3M™ ActiV.A.C.™ Therapy System Ordering Information.....	24
3M™ Snap™ Therapy System Ordering Information	25
3M™ Advanced Wound Care and Skin Integrity Solutions Ordering Information	25

3M™ V.A.C.® Therapy System and 3M™ Snap™ Therapy System Indicated Wound Types

These 3M Negative Pressure Wound Therapy (NPWT) products are indicated for the following wound types:

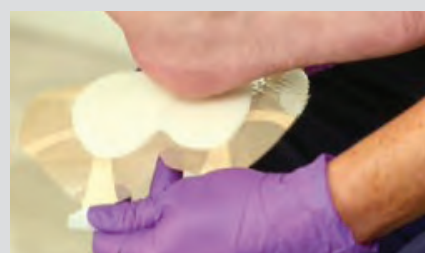

For appropriate wounds, initiate the use of 3M NPWT.

1. Start Early
with 3M NPWT.



2. Transition to
3M Advanced Wound
Care Solutions
according to facility
wound care protocol.



Benefits of Early Initiation of 3M™ V.A.C.® Therapy on Acute and Chronic Wounds

have been demonstrated in acute care, long-term acute care, and home health care.*¹⁻³

In a retrospective analysis of 4,739 acute and chronic wounds,** when V.A.C.® Therapy was initiated early in the wound care center setting, treatment time period compared to late initiation, the median days to reach significant closure (75% wound surface area reduction) were:⁴



1/2 time
for Acute Wounds



1/3 time
for Chronic Wounds



Additionally, the early group was **twice as likely** to reach 75% wound surface area (WSA) reduction as the late group for both acute and chronic wounds.

Early initiation of V.A.C.® Therapy has led to:



Reduced inpatient days in acute and intensive care unit by at least 50%.⁵



Reduced homecare length of stay by 34% for surgical wounds.²



Reduced inpatient days in long term acute care by 30%.³



Reduced homecare length of stay by 49% for pressure injuries.²

*Early NPWT was defined for acute wounds as treatment initiated within the first 7 days from the first wound treatment date and within 30 days for chronic wounds; late NPWT initiation occurred after this time. A secondary analysis was conducted on a sub-set of patients where Charlson Co-morbidity Index Scores ≤5, to assess Early vs. Late cost differences by wound type, excluding the sickest patients with significant non-wound long-term care costs; this cohort represented 80% of the wounds.

**The US Wound Registry was used in this retrospective analysis that examined 4,739 acute and chronic wounds (56.7% and 43.3%, respectively) that received NPWT, from 3,604 patients treated in 56 outpatient WCCs from 11-Nov-2000 through 16-Jul-2010. For Acute Wounds, median days from first visit to 75% Wound Surface Area (WSA) reduction was 40.4 days for early group vs. 81.6 days for late group, or 1/2 the time for the early group ($p < 0.0001$). For Chronic Wounds, median days from first visit to 75% WSA reduction was 96.4 days for early group vs. 274.6 days for late group, or 1/3 the time for the early group ($p < 0.0001$).

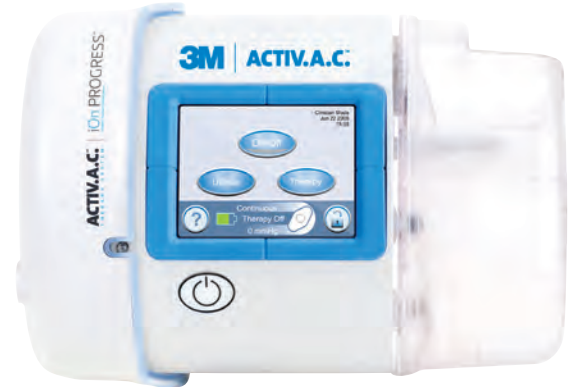3M™ ActiV.A.C.™ Therapy System at a Glance

A portable Negative Pressure Wound Therapy device designed for the ambulatory patient.

The ActiV.A.C.™ Therapy System was specifically developed for the mobile wound care patient, to help them resume their activities of daily living while still receiving the proven benefits of 3M™ V.A.C.® Therapy.

- Lightweight — weighs only 2.4 pounds
- Small size with a low profile that can be worn close to the body
- Easy-to-use
- Alarm notifications that are easy to recognize and correct
- Continuous or Intermittent therapy
- Pressure settings from -25mmHg to -200mmHg
- Easy, quick release 300mL canister
- 14-hour battery for activities of daily living
- Only V.A.C.® Therapy Devices provide patented 3M™ SensaT.R.A.C.™ Technology, a real time pressure monitoring feedback system

There are numerous studies that have evaluated the cost-effectiveness of V.A.C.® Therapy in a variety of settings and indicated wound types.



These studies have shown that V.A.C.® Therapy has been associated with:

- Fewer hospitalizations^{6,8}
- Fewer complications^{7,8}
- Fewer amputations^{9,10}
- Fewer dressing changes^{11,12}
- Faster time to wound healing¹³
- Shorter hospitalization^{9,10}
- Reduced treatment times^{14,15}

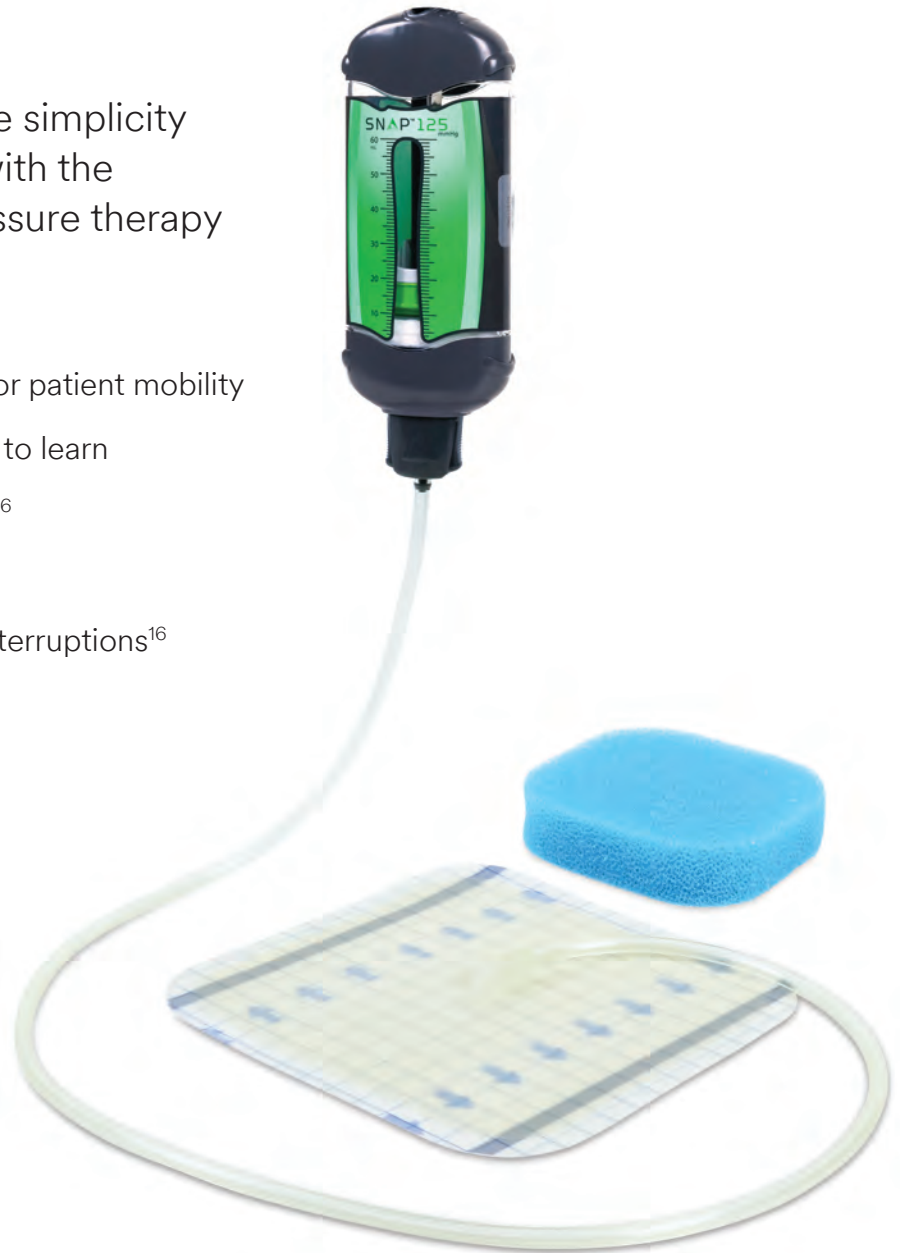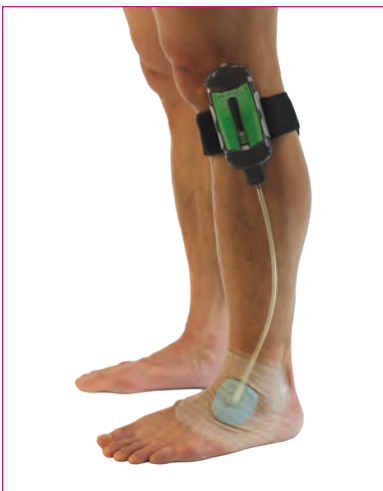By minimizing the factors that contribute to direct and indirect wound care costs, V.A.C.® Therapy has emerged as a cost-effective option for wound management.

3M™ Snap™ Therapy System at a Glance

A unique and convenient disposable negative pressure wound therapy (dNPWT) solution, ideal for patients who might benefit from silent, hidden and portable wound care.

The Snap™ System combines the simplicity of advanced wound dressings with the proven benefits of negative pressure therapy in a discreet design.¹⁶

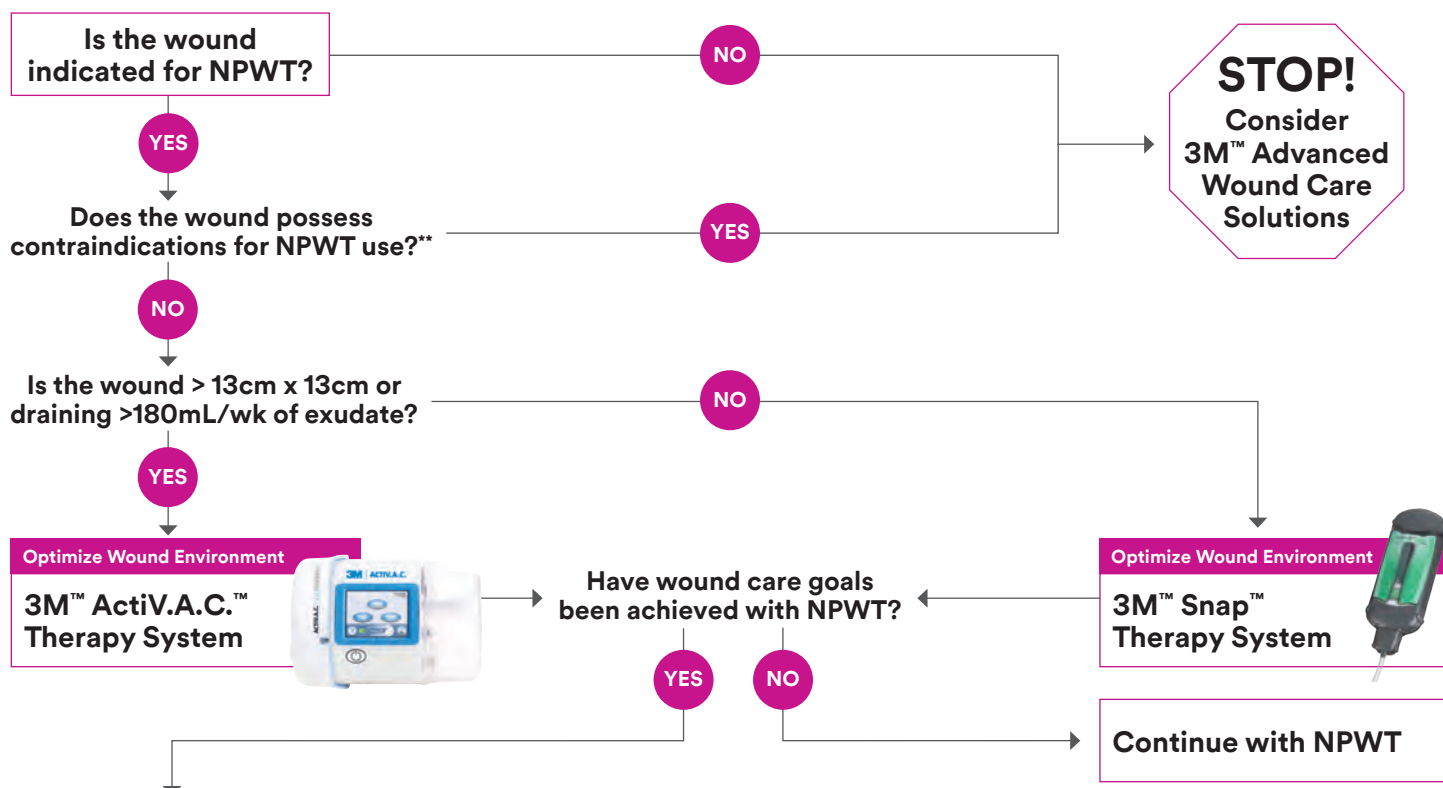
- Mechanically powered and portable for patient mobility
- No settings or adjustments for patient to learn
- Preserves patient quality of life (QOL)¹⁶
- Discreet and worn under clothing
- Silent design ensures minimal sleep interruptions¹⁶
- Continuous -125mmHg therapy
- Single-use, disposable NPWT
- Off-the-shelf availability



Select the Appropriate Product













Wound/Clinical Considerations (Non-Hospital)		
Criteria	3M™ ActiV.A.C.™ Therapy System	3M™ Snap™ Therapy System
Wound Size	> 13cm x 13cm	≤ 13cm x 13cm
Wound Drainage	> 180mL/week	≤ 180mL/week (3) x 60mL cartridges/week
NPWT Initiation	Previously treated with Modern Wound Care; > Day 30	First line treatment; Day 1* (No 30 day requirement for modern wound care, No minimum depth)

*May vary by payor.



When the time is right to transition from NPWT, consider 3M™ Advanced Wound Care and Skin Integrity Solutions

3M™ Advanced Wound Care Solutions may be appropriate when NPWT is not available or appropriate and should be selected based on clinical goal.

Protect Skin	Protect/Prepare Wound Bed		Optimize Wound Environment		Provide Therapeutic Compression
Routine Skin Protection	Manage Biofilm/Bioburden		Manage Exudate		
3M™ Cavilon™ No Sting Barrier Film	3M™ Kerracel™ Ag Gelling Fiber Dressing	3M™ Silvercel™ Non-Adherent Antimicrobial Alginate Dressing	3M™ Kerracel™ Gelling Fiber Dressing	3M™ Kerramax Care™ Super-Absorbent Dressing	3M™ Coban™ 2 Two-Layer Compression Systems
					
At-risk or Damaged Skin Protection	Provide Collagen	Minimize Adherence	3M™ Tegaderm™ Silicone Foam Dressings	3M™ Tegaderm™ High Performance Foam Dressings	3M™ Coban™ 2 Lite Two-Layer Compression Systems
3M™ Cavilon™ Advanced Skin Protectant	3M™ Promogran Prisma™ Matrix Wound Dressing	3M™ Adaptic™ Touch Non-Adhering Silicone Dressing			
					

****NOTE:** Specific indications, contraindications, warnings, precautions, and safety information exist for these products and therapies, some of which may be Rx only. Please consult a clinician and product instructions for use prior to application.

Case Study 1

Sequential Wound Management Employing a Multimodal Approach to Wound Dehiscence Post Metatarsalphalangeal Joint Arthrodesis

Patient

A 74-year-old male was referred to the wound care clinic and presented with a surgically dehiscent wound to the right lower extremity. The patient's past medical history included: degenerative joint disease, hallux rigidus, peptic ulcer disease, and three prior surgeries to the first metatarsalphalangeal (MTP) joint.

Diagnosis

The patient presented with an infected, dehiscent surgical incision with eschar status post MTP joint arthrodesis (**Figure 1**). The patient opted for an effort to salvage the right hallux.

Course of Treatment

The patient was referred to a vascular specialist and received an arteriogram of the lower extremities. Per the ankle-brachial index, the right toe pressures were suggestive of less than optimal potential for wound healing. He underwent a percutaneous transluminal (PT) angioplasty to treat an occlusion in the right posterior tibial artery. The presence of osteomyelitis prompted the removal of the surgically installed hardware and the patient declined amputation of the right hallux (**Figure 2**). The patient was referred to an Infectious Disease specialist and was administered antibiotics to manage the infection. He underwent a bone resection of the right hallux, and the patient was discharged home with an 3M™ ActiV.A.C.™ Therapy System (-125mmHg) with 3M™ V.A.C.® Granufoam™ Dressing (**Figure 3**). Dressing changes occurred every 2–3 days. On postoperative day (POD) 21, the wound was evaluated, an allograft was applied (**Figure 4**), and the ActiV.A.C. Therapy System with V.A.C.® Granufoam™ Dressing was used to bolster the protected graft. As the allograft demonstrated appreciable take, 3M™ V.A.C.® Therapy was discontinued.

Discharge and Follow-up

Treatment transitioned to the use of 3M™ Promogran Prisma™ Matrix to facilitate tissue granulation and wound closure. Promogran Prisma Matrix was applied to the wound on POD 35 (**Figure 5**). On POD 49, the wound was reevaluated and treatment with Promogran Prisma Matrix continued (**Figure 6**). Seventy days (POD 70) following the bone resection, the wound was almost closed (**Figure 7**).

Treatment Modalities

- Administration of antibiotics managed by Infectious Disease
- Hardware removal
- Arterial duplex ensued by vascular referral with arteriogram with PT angioplasty
- Intravenous antibiotics
- Resection of infected bone followed by conventional negative pressure wound therapy using the ActiV.A.C. Therapy System with V.A.C.® Granufoam™ Dressing
- Application of allograft with ActiV.A.C. Therapy System with V.A.C.® Granufoam™ Dressing to bolster the allograft
- Application of Promogran Prisma Matrix

Case Study 1: Figures 1–7

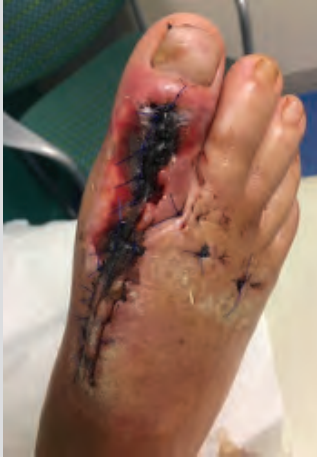

Figure 1. Right foot at presentation status post MTP joint arthrodesis demonstrating surgical incision dehiscence with eschar.

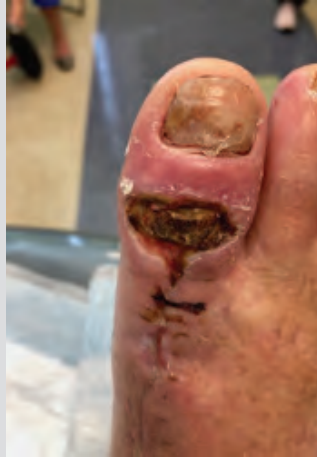

Figure 2. Right hallux following hardware removal and prior to infected bone resection.

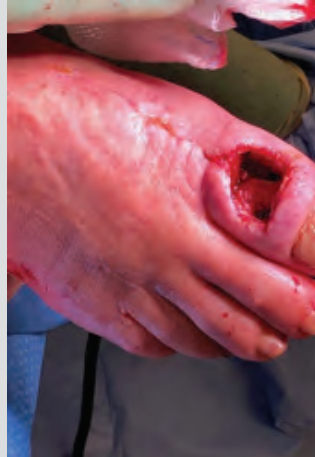

Figure 3. Wound following infected bone resection and the application of 3M™ ActiV.A.C.™ Therapy System with 3M™ Granufoam™ Dressing.

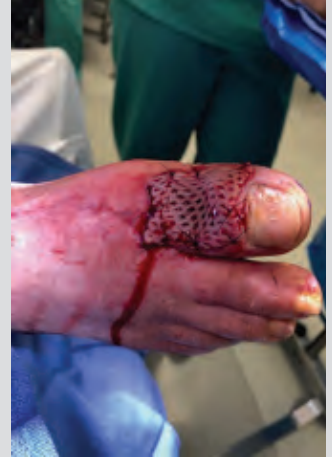

Figure 4. Wound covered with allograft on POD 21 prior to being bolstered with ActiV.A.C.™ Therapy System.

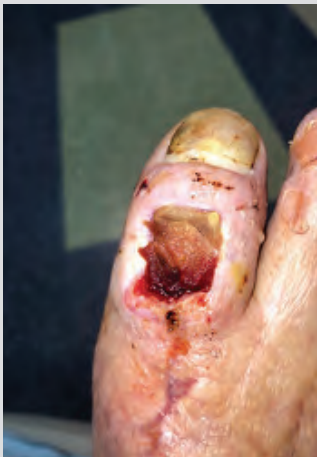

Figure 5. Wound filled with 3M™ Promogran Prisma™ Matrix on POD 35.

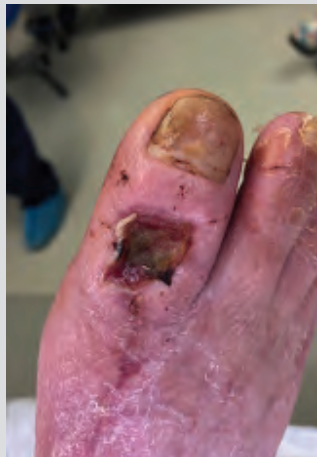

Figure 6. Wound on POD 49 following treatment with Promogran Prisma Matrix.

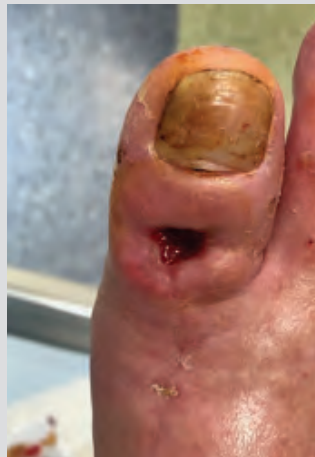

Figure 7. At follow-up appointment (POD 70), the wound on the right hallux is almost closed.

Case Study 2

Multimodal Management of Gas Gangrene and a Diabetic Foot in a Post-acute Setting

Patient

A 44-year-old female presented to the Emergency Department with gangrene of the fourth toe, blanching of the sulcus of the forefoot and erythema of the plantar medial arch that extended upward (**Figure 1**). Six days prior, the patient reportedly dropped canned food on the left foot. The patient had type 2 diabetes, which was poorly controlled. However, she had no other known comorbidities, prior foot infection or ulceration.

Diagnosis

The patient presented septic with gas seen on an X-ray of the left foot. The patient was diagnosed with gas gangrene and a diabetic left foot.

Course of Treatment

The patient was taken to the operating room (OR) for emergent incision and drainage of the affected foot. The surgeon performed an open amputation of the second, third, fourth and fifth toes (**Figure 2**). Necrotic and grossly infected tissue was excised. The surgical defect of the open foot was packed and dressed using saline moistened gauze. The patient was admitted to the acute floor and administered intravenous antibiotics. On postoperative Day 3, the patient returned to the OR for debridement, washout and surgical revision of the open foot. Partial closure was achieved on the plantar arch. 3M™ V.A.C.® Therapy was initiated to the remaining open wound. Dressings changes occurred every 3 days.

Discharge and Follow-up

One week later, the patient was discharged home with V.A.C.® Therapy and further instructed to be non-weight bearing on the left foot. A home health nurse changed 3M™ V.A.C.® Dressing every 2–3 days. The patient was seen in the clinic for follow-up twelve days status post debridement, washout, partial delayed primary closure and V.A.C.® Therapy (**Figure 3A**). Dressing changes occurred every 2–3 days. Maceration was noted along the sutured plantar incision and V.A.C.® Therapy over the open wound was suspended for 1 week (**Figure 3B**).

To address the maceration, a povidone-iodine solution (Betadine®; Avrio Health LP, Stamford, Connecticut) was enlisted to promote drying and to serve as a bactericidal agent. Additionally, calcium alginate was employed as the primary dressing during the week-long suspension of V.A.C.® Therapy. After one week, V.A.C.® Therapy resumed over the open wound, and wound progression was evaluated each week (**Figure 4**). After seven weeks, V.A.C.® Therapy was discontinued. The remaining wound was without depth, demonstrated reduced wound area and was occupied by 100% granulation tissue (**Figure 5**).

The 3M™ Snap™ Therapy System was then enlisted to provide negative pressure wound therapy as the patient awaited approval of a biologic medical product (**Figure 6**). Upon approval of the biologic, the Snap Therapy System was discontinued. To facilitate wound closure, a bilayered human skin equivalent composed of living cells (Apligraf®; Organogenesis Inc., Canton, MA) was applied and covered with a nonadherent dressing. The human skin equivalent was applied weekly for seven weeks (**Figure 7**). At eight weeks, wound closure was achieved. The patient returned to the clinic nineteen weeks after the resolution of the wound for a follow-up appointment (**Figure 8**). The previously affected site was still intact and remained completely healed.

Treatment Modalities

- Emergent surgical incision and drainage
- Open amputation and excision of necrotic and grossly infected tissue
- Surgical defect packed with saline moistened gauze
- Intravenous antibiotics
- Surgical revision with debridement and washout
- V.A.C.® Therapy to promote granulation tissue formation and create an environment to promote wound healing dimensions
- Povidone-iodine solution (Betadine®; Avrio Health LP, Stamford, Connecticut)
- Calcium alginate dressing
- Snap Therapy System as a transitional therapy between V.A.C.® Therapy discontinuation and application of skin substitute
- Living cellular skin substitute (Apligraf®; Organogenesis Inc., Canton, MA)

Case Study 2: Figures 1–8

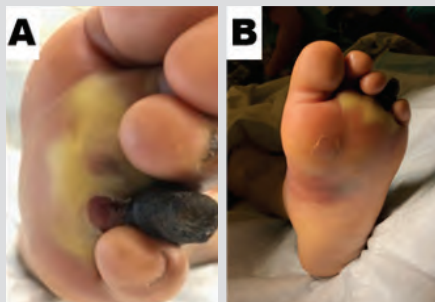

Figure 1. Left diabetic foot with gas gangrene at presentation. A. Gangrene of the fourth toe with blanching of the sulcus of the forefoot. B. Gangrene of the fourth toe, blanching of the sulcus of the forefoot and erythema extending up the plantar medial arch.

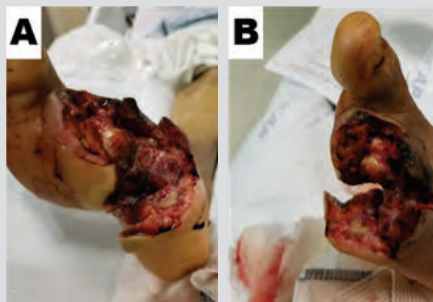


Figure 2. Left diabetic foot on postoperative Day 3 and prior to the second surgical procedure. A. Ventral aspect of open wound demonstrating the amputation of the 2nd through 5th toes. B. Dorsal aspect of open wound.

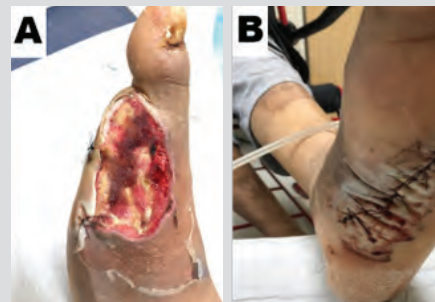

Figure 3. Left diabetic foot 12 days after second surgical procedure. A. Open foot wound after one week of 3M™ V.A.C.® Therapy. B. Macerated tissue distributed along the length of the primary closed plantar arch.

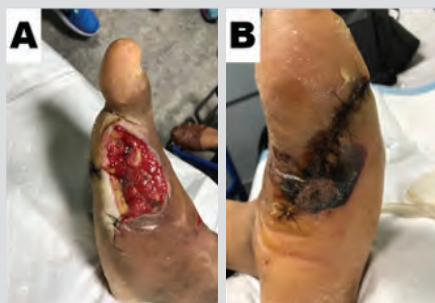

Figure 4. Left diabetic foot after four weeks of V.A.C.® Therapy. A. Open foot wound exhibiting bright beefy red tissue following four weeks of V.A.C.® Therapy. B. Ventral aspect of primary closed plantar arch.

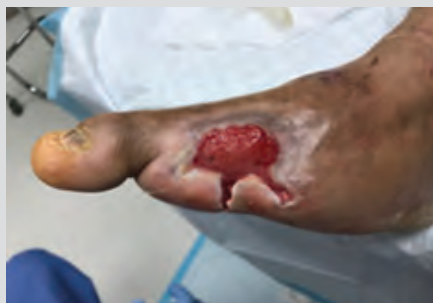

Figure 5. After seven weeks of V.A.C.® Therapy, the open wound of the left diabetic foot was without depth as well as demonstrated reduced wound area and 100% tissue granulation. Having achieved therapeutic goals, V.A.C.® Therapy was discontinued.

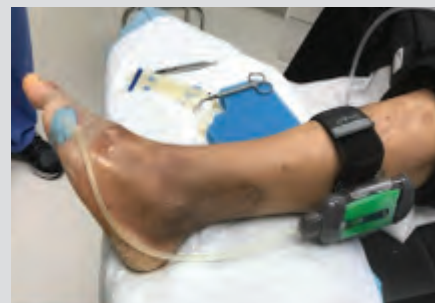

Figure 6. The 3M™ Snap™ Therapy System was applied to the wound as the patient awaited approval for a biologic medical product.

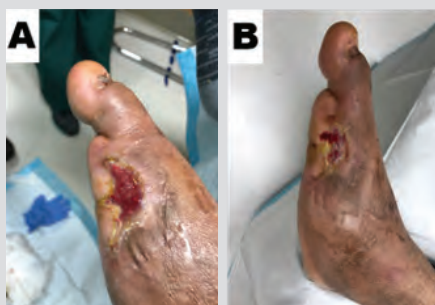

Figure 7. Wound after weekly applications of a living cellular skin substitute. A. Wound at four weeks. B. Wound at seven weeks.

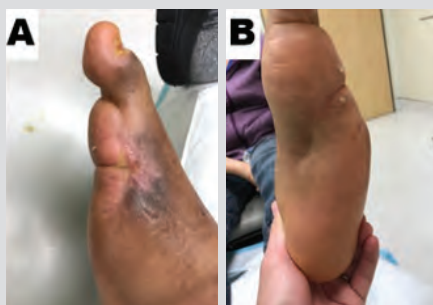

Figure 8. Left foot 19 weeks after wound resolution. A. Dorsal aspect of foot with resolved wound. B. Ventral aspect of foot with resolved plantar incision.

Case Study 3

Management of an Infected Incision and Drainage Wound with Undermining in a Post-acute Setting

Patient

A 28-year-old female presented to the outpatient wound clinic following hospitalization for an infected wound on the lower extremity (**Figure 1**). Three days prior, the patient underwent incision and drainage (I&D) for septic bursitis of the left knee. Aside from asthma, she had no other known medical history.

Diagnosis

The patient had been previously diagnosed with abscess of the left knee prepatellar bursa. The patient presented to the clinic with an incision and drainage wound measuring $4.0 \times 1.4 \times 0.9\text{cm}^3$ with 2.5cm with undermining at the 9 o'clock position. The patient initially received an intravenous antibiotic and was transitioned to an oral antibiotic based on wound culture result.

Course of Treatment

Following an evaluation of the wound, negative pressure wound therapy using the 3M™ ActiV.A.C.™ Therapy System was recommended to manage the wound created from the I&D defect. 3M™ V.A.C.® Granufoam™ Dressing was applied to the defect, and 3M™ V.A.C.® Therapy was initiated at -125mmHg of continuous subatmospheric pressure. Dressing changes occurred every 2–3 days. After 3 weeks of V.A.C.® Therapy, the undermining had resolved, and the wound measured $2.2 \times 0.7 \times 0.2\text{cm}^3$ (**Figure 2**). The wound exhibited a reduction in volume and was occupied by granulation tissue. V.A.C.® Therapy was reapplied for 2 more weeks.

Discharge and Follow-up

Five weeks after her initial presentation at the wound care clinic, the patient's wound measured $1.1 \times 0.3 \times 0.1\text{cm}^3$ (**Figure 3**). V.A.C.® Therapy was discontinued.

Treatment Modalities

- Incision and drainage of bursa abscess
- Intravenous Antibiotics
- Oral antibiotic based on culture sensitivity assay
- Negative pressure wound therapy using the ActiV.A.C. Therapy System with V.A.C.® Granufoam™ Dressing

Case Study 3: Figures 1–3

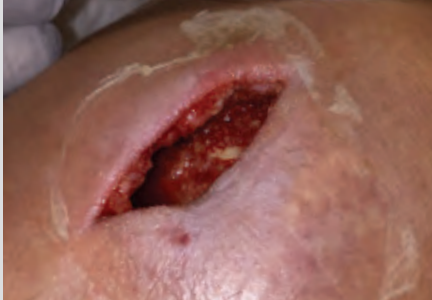

Figure 1. Infected left knee wound ($4.0 \times 1.4 \times 0.9\text{cm}^3$) with undermining (2.5cm) status post I&D three days prior.

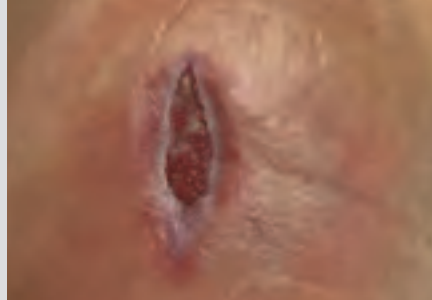

Figure 2. Left knee wound ($2.2 \times 0.7 \times 0.2\text{cm}^3$) after three weeks of 3M™ V.A.C.® Therapy.

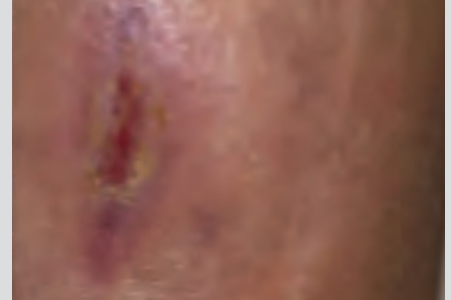

Figure 3. Left knee five weeks after initial presentation and measuring $1.1 \times 0.3 \times 0.1\text{cm}^3$.

Case Study 4

Sequential Wound Management Employing a Multimodal Approach to Manage an Infected Diabetic Foot Wound

Patient

A 53-year-old female was admitted to the hospital with sepsis derived from an infected diabetic foot. The patient's past medical history included: type 2 diabetes, coronary artery disease, chronic kidney disease, hypertension, peripheral neuropathy, depression, anxiety disorder, panic disorder and fibromyalgia.

Diagnosis

The patient presented with sepsis via an infected diabetic left foot. The patient was administered intravenous antibiotics to manage the infection.

Course of Treatment

On the day of admission, a vascular fellow and vascular surgery attending physician took the patient to the operating room (OR) for emergent incision and drainage of the affected foot (**Figure 1**). The presence of osteomyelitis prompted a hallux and first ray amputation (**Figure 2**). On postoperative day (POD) 1, 3M™ Veraflo™ Therapy was enlisted to cleanse the surgical defect; 14mL of normal saline was instilled with a 10-minute dwell time, followed by 3.5 hours of subatmospheric pressure (-125mmHg). Dressing changes occurred every 2–3 days, the patient received 5 days of 3M™ Veraflo™ Therapy. The patient was discharged home with a 3M™ ActiV.A.C.™ Therapy System with 3M™ V.A.C.® Granufoam™ Dressing. On POD 7, the open wound was evaluated (**Figure 3**), and 3M™ ActiV.A.C.™ Therapy System with 3M™ V.A.C.® Granufoam™ Dressing was continued. On POD 35, it was felt that additional therapy was needed using ActiV.A.C. Therapy System with V.A.C.® Granufoam™ Dressing (**Figure 4**). The patient was expected to be non-weight bearing on the left foot. Dressing changes occurred every 2–3 days. After 2 weeks (POD 49), V.A.C.® Therapy was discontinued as the wound cavity was filled and wound edges were brought together (**Figure 5**). To facilitate wound closure, 3M™ Promogran Prisma™ Matrix was applied to the wound (**Figure 6**).

Discharge and Follow-up

Ten weeks (POD 70) from the initial surgery, the wound achieved closure (**Figure 7**). The patient was seen in the clinic for her follow-up appointment, and the previously affected site was intact and remained closed. (**Figure 8**). The patient was ambulatory, utilizing diabetic shoes and insoles.

Treatment Modalities

- Emergent surgical incision and drainage
- First ray resection along with amputation of the hallux
- Intravenous antibiotics
- Veraflo Therapy to cleanse the wound
- Conventional negative pressure wound therapy using the ActiV.A.C. Therapy System with V.A.C.® Granufoam™ Dressing
- Promogran Prisma Matrix

Case Study 4: Figures 1–8

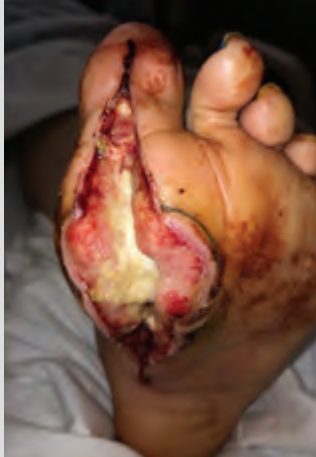

Figure 1. Infected left diabetic foot following emergent incision and drainage.

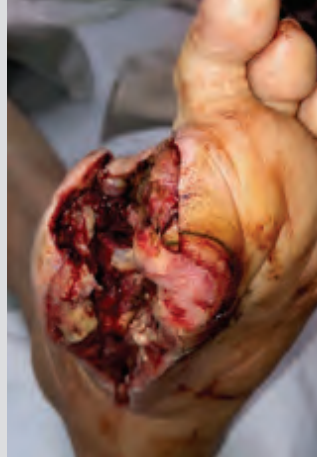

Figure 2. Left diabetic foot following ray amputation of the hallux.

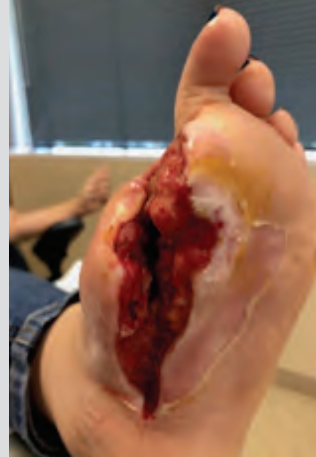

Figure 3. Open foot wound after five days (POD 7) of 3M™ Veraflo™ Therapy. Patient transitioned to conventional negative pressure wound therapy using the 3M™ ActiV.A.C.™ Therapy System.

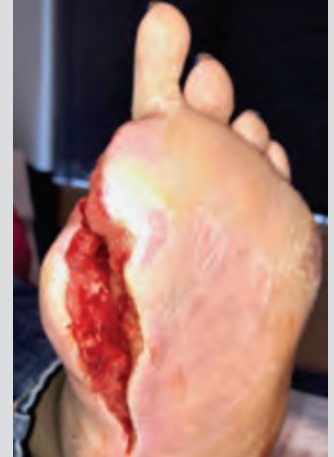

Figure 4. Left diabetic foot on POD 35. Application of the ActiV.A.C. Therapy System was continued.

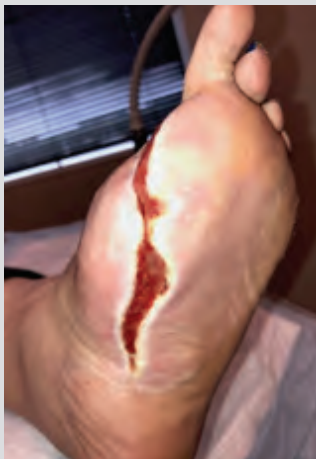

Figure 5. Left diabetic foot on POD 49. Having achieved therapeutic goals, V.A.C.® Therapy was discontinued.

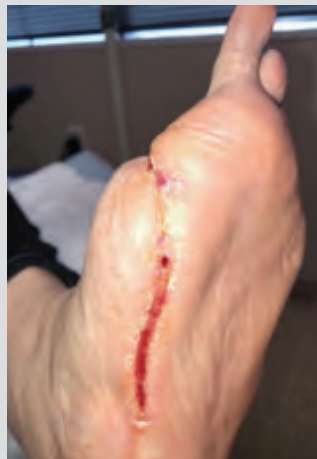

Figure 6. Left diabetic foot on POD 63, after receiving 3M™ Promogran Prisma™ Matrix for two weeks.

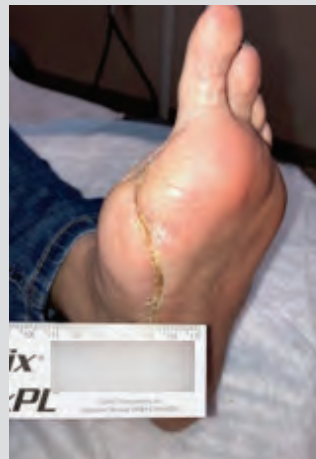

Figure 7. Wound closed on POD 70, ten weeks from initial surgical procedure.

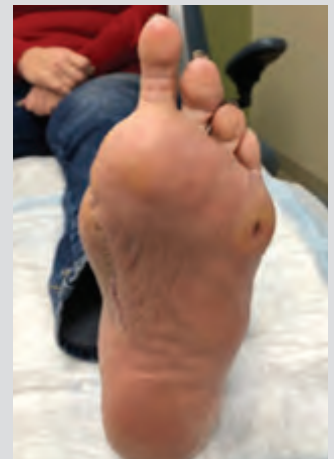

Figure 8. Left foot at follow-up appointment demonstrating wound remained closed.

Case Study 5

Venous Stasis Ulcer of the Lower Extremity

Patient

A 72-year-old male presented to the outpatient wound clinic with a venous leg ulcer (VLU) (**Figure 1**). The wound was extremely painful and unable to be adequately debrided in clinic. His previous medical history included peripheral vascular disease.

Diagnosis

The patient had a venous stasis ulcer of the left lower extremity. The patient received perioperative antibiotics and was continued on oral antibiotics for 10 days.

Course of Treatment

Following an initial evaluation of the VLU, the patient was taken to the operating room (OR) for the excision of non-viable tissue (**Figure 2**). 3M™ Veraflo™ Therapy was initiated (**Figure 3**); 30mL of normal saline was instilled with a 20-minute dwell time, followed by continuous subatmospheric pressure (-125mmHg) for 2 hours. Dressing changes should occur every 2–3 days. The patient returned to the OR (Day 4) for STSG harvesting (**Figure 4**). The STSG was applied over the VLU and an allograft placental matrix (AmnioBand® Particulate; MTF Biologics, Edison, NJ) was distributed over the graft to optimize healing (**Figure 5**). Prior to applying 3M™ V.A.C.® Therapy dressing, 3M™ Adaptic™ Non-Adhering Dressing was placed over the graft to protect it. V.A.C.® Therapy was then applied and initiated to bolster the protected graft (**Figure 6**). 3M™ Promogran Prisma™ Matrix was applied to the STSG donor sites on the left thigh to facilitate healing (**Figure 7**). Ten days later (Day 14), the graft demonstrated full take (**Figure 8**). The donor site also demonstrated adequate healing (**Figure 9**).

Discharge and Follow-up

Six weeks after his initial presentation at the wound care clinic, the patient's VLU had healed completely (**Figure 10**) and the donor sites on the left thigh had also fully reepithelialized (**Figure 11**).

Treatment Modalities

- Perioperative antibiotics
- Excision of non-viable tissue within the OR
- Initiation of Veraflo™ Therapy
- Acquisition of STSG from thigh and application of STSG to VLU.
- Application of allograft placental matrix (AmnioBand® Particulate) over the STSG to optimize healing
- Initiation of V.A.C.® Therapy using 3M™ Granufoam™ Dressing to bolster the STSG
- Adaptic Non-Adhering Dressing to protect the STSG
- Application of Promogran Prisma Matrix to donor site wounds to promote reepithelialization

Case Study 5: Figures 1–11

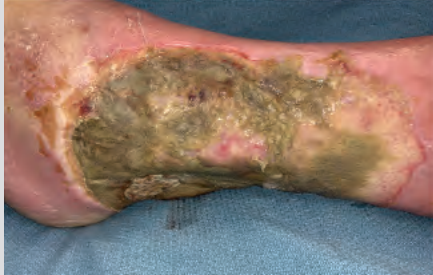

Figure 1. Venous stasis ulcer with non-viable tissue at presentation (Day 1).

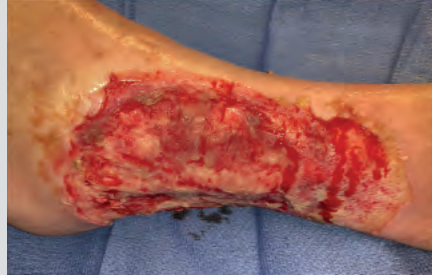

Figure 2. VLU post excision of non-viable tissue (Day 1).

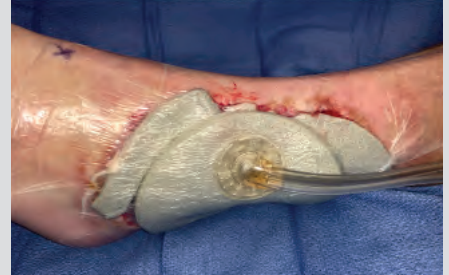

Figure 3. 3M™ Veraflo™ Therapy applied to the VLU (Day 1).

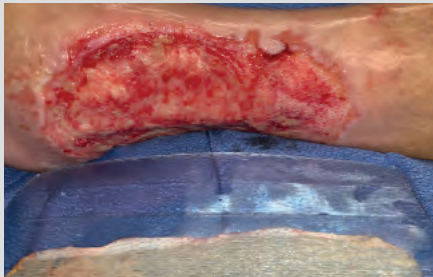


Figure 4. VLU after three days of Veraflo Therapy and prior to STSG placement (Day 4).

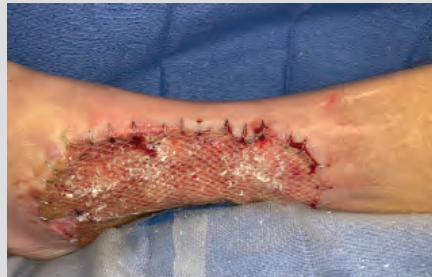

Figure 5. STSG and allograft placental matrix applied to the VLU (Day 4).

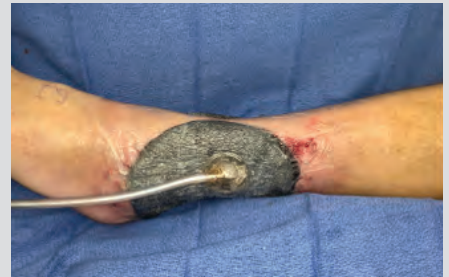

Figure 6. Application of 3M™ V.A.C.® Therapy using 3M™ V.A.C.® Granufoam™ Dressing to bolster. The STSG protected with 3M™ Adaptic™ Non-Adhering Dressing (Day 4).

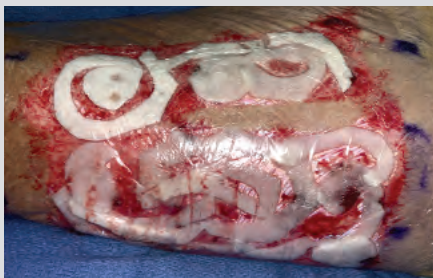

Figure 7. Placement of 3M™ Promogran Prisma™ Matrix over the donor site wounds (Day 4).

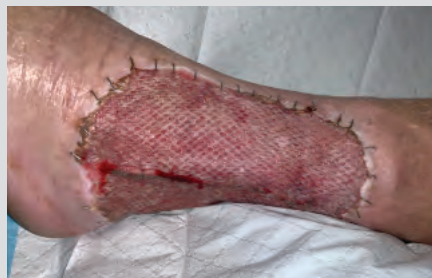

Figure 8. VLU on Day 14.

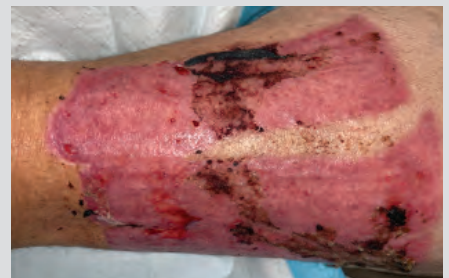

Figure 9. STSG donor site (left thigh) wounds on Day 14.

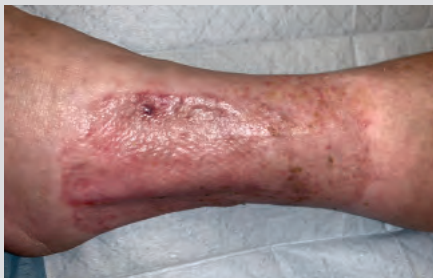

Figure 10. Completely healed VLU at follow-up appointment (six weeks).

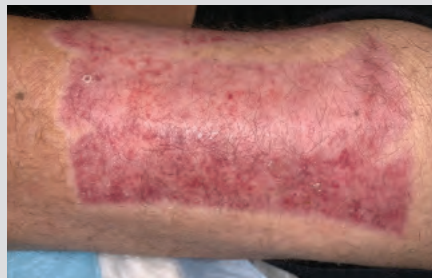

Figure 11. Reepithelialized STSG donor site (left thigh) wounds at follow-up appointment (six weeks).

Patient data and photos courtesy of Michael N. Desvigne, MD, FACS, CWS, FACCWS; Valley Wound Care Specialists, Glendale, Arizona.

Case Study 6

Wound Management of Venous Leg Ulcers in the Right Lower Extremity Using Super-Absorbent Dressing and a Two-layer Compression Wrap

Patient

A 68-year-old male presented for care with lymphedema and multiple, copiously draining ulcerations on the right lower extremity (**Figure 1**). Symptoms were present for years and failed to respond to compression, foam dressings, or abdominal pads. Previous medical history included hypertension requiring use of anti-hypertensive medication.

Diagnosis

The patient presented with lymphedema and multiple ulcerations on the right lower extremity with copious amounts of drainage. A positive Stemmer sign was noted and palpable pedal pulses with mild symptoms of venous insufficiency were noted. He was diagnosed with lymphedema and venous leg ulcers.

Course of Treatment

The patient underwent sharp debridement followed by 3M™ Kerramax Care™ Super-Absorbent Dressing and 3M™ Coban™ 2 Two-Layer Compression System. The dressing was changed 3 days later and revealed that the copious drainage had dramatically decreased (**Figure 2**). Therapy was continued with weekly dressing changes. After three weeks, treatment was changed to 3M™ Kerracel™ Ag Gelling Fiber Dressing and Coban 2 Compression System.

Discharge and Follow-up

After 1 month, the ulcer had healed and the edema almost completely resolved (**Figure 3**). A support garment was prescribed, and pneumatic compression was ordered for daily use. A lymphedema therapist was recommended. The patient has continued to do well with only mild exacerbation of symptoms.

Treatment Modalities

- Sharp debridement
- Kerramax Care Super-Absorbent Dressing
- Kerracel Ag Gelling Fiber Dressing
- Coban 2 Compression System
- Support garment
- Daily use of pneumatic compression after ulcer healed

Case Study 6: Figures 1–3

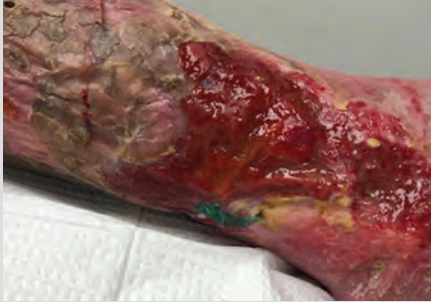

Figure 1. Right leg venous leg ulcer at presentation.

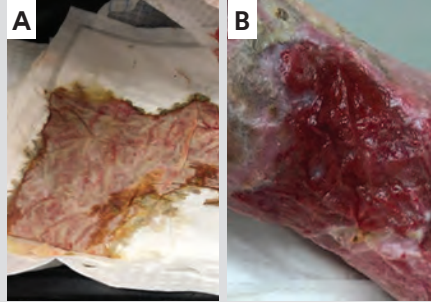


Figure 2. One week after application of 3M™ Kerramax Care™ Super-Absorbent Dressing along with 3M™ Coban™ 2 Two-Layer Compression System. A. Drainage was incorporated in the dressing; B. The wound surface was dry to the touch.

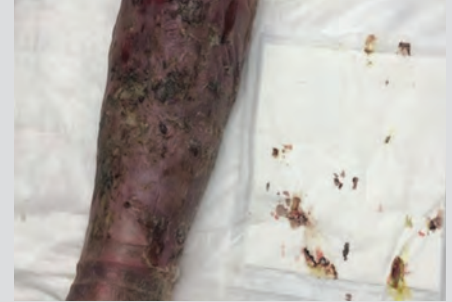


Figure 3. Lower extremity 1 month after Kerramax Care Super-Absorbent Dressing along with Coban 2 Compression System use.

Case Study 7

Multimodal Wound Management of an Infected Venous Leg Ulcer

Patient

A 60-year-old female presented for care with a venous leg ulcer of the right leg (**Figure 1**). Previous medical history included hypertension and dyslipidemia.

Diagnosis

The patient presented with venous leg ulcer of the right leg. Purulent drainage was observed in the wound dressings. The patient was diagnosed with a venous leg ulcer and infection.

Course of Treatment

The patient underwent sharp debridement with wound culture followed by application of 3M™ Silvercel™ Non-Adherent Antimicrobial Alginate Dressing with 3M™ Easylift™ Precision Film Technology. Oral antibiotics were initiated as bacterial culture results indicated heavy growth of *Staphylococcus aureus*. After 10 days, the wound was improved (**Figure 2**). Oral antibiotics were continued for an additional 10 days along with Silvercel Non-Adherent Dressing and 3M™ Coban™ 2 Two-Layer Compression System (**Figure 3**).

Discharge and Follow-up

Treatment was changed to 3M™ Promogran Prisma™ Matrix and Coban 2 Compression System (**Figure 4**). After two weeks, treatment was changed to 3M™ Promogran™ Matrix Wound Dressing and Coban 2 Compression System, which was continued until the wound was fully healed (**Figure 5**). After the wound was fully healed, 20mmHg support hose were prescribed.

Treatment Modalities

- Sharp debridement
- Oral antibiotics
- Silvercel Non-Adherent Dressing with Easylift Technology
- Coban 2 Compression System
- Promogran Prisma Matrix
- Promogran Matrix

Case Study 7: Figures 1–5

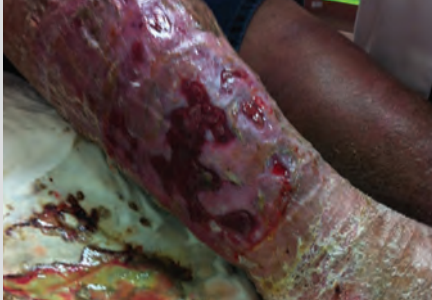

Figure 1. Venous leg ulcer at presentation.

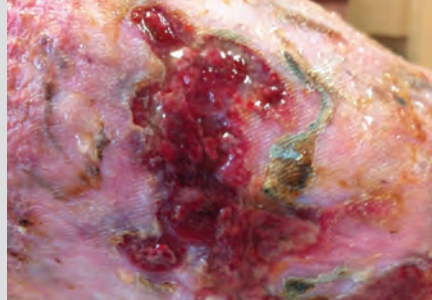


Figure 2. Venous leg ulcer after 10 days of 3M™ Silvercel™ Non-Adherent Dressing and 3M™ Coban™ 2 Two-Layer Compression System.

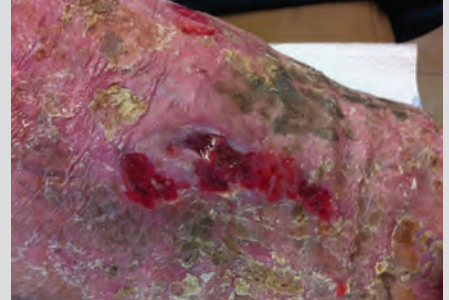

Figure 3. Venous leg ulcer after an additional 10 days of Silvercel Non-Adherent Dressing and Coban 2 Compression System.

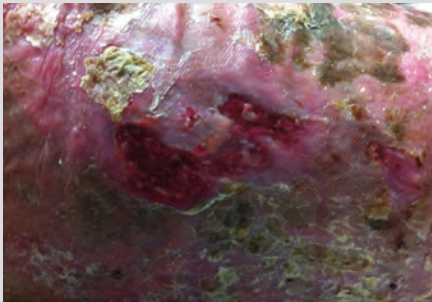

Figure 4. Venous leg ulcer after 14 days of 3M™ Promogran Prisma™ Matrix and Coban 2 Compression System use.

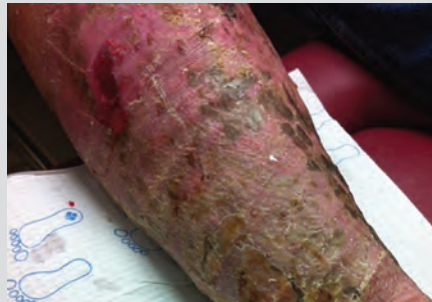

Figure 5. Venous leg ulcer treatment switched to 3M™ Promogran™ Matrix and Coban 2 Compression System.

Case Study 8

Pressure Injury Management in a Skilled Nursing Environment

Patient

An 83-year-old male presented with an injury resulting from a fall in his home. He fell and was unable to adjust his position for several hours until he was found and sent to the Emergency Department. The patient's medical history was significant for hypertension, hyperlipidemia, atrial fibrillation, dementia, and benign prostatic hypertrophy. After a generalized work-up, the patient was found to have mild dehydration but no other acute medical issues except gait disturbance. After 12 hours and gentle intravenous rehydration, he was transferred to a skilled nursing facility for short-term rehabilitation. There, an apparent hematoma was noted on the right lower leg. This injury progressed to black eschar (**Figure 1**) over a four-day period. A wound consultation was requested by the attending physician.

Diagnosis

Initial evaluation revealed no acute distress or inguinal lymphadenopathy. There were no palpable peripheral pulses, but biphasic Doppler waveforms and an ankle-brachial index of 0.81 on the effected leg. Edema was moderate. There was a large, unstageable pressure ulcer at the anterior mid-tibia with edge separation and liquefying non-viable tissue in need of debridement. There was no odor to the wound, nor indications of cellulitis. Superficial satellite coagulums were also noted superiorly.

Course of Treatment

Sharp debridement occurred at the bedside. Post-debridement measurements $9.0 \times 8.5 \times 1.5\text{cm}^3$. The wound was copiously irrigated and 3M™ Kerracel™ Gelling Fiber Dressing was placed into the wound covered by 3M™ Kerrafoam™ Simple Border Dressing. A tubular elastic bandage was placed on the leg to provide mild compression.

Upon re-evaluation one week later (**Figure 2**), the patient was found to have increased edema, erythema, and warmth to the leg. The wound, although measuring $9.0 \times 6.7 \times 1.5\text{cm}^3$, had purulent drainage in large amounts. There was minimal undermining noted at 11 o'clock.

The patient's relative with medical power of attorney declined oral antibiotics. Wound management transitioned to continuous pulsed irrigation daily for seven days,

followed by daily application of 3M™ Kerracel™ Ag Gelling Fiber Dressing to manage infection and control exudate. The secondary dressing consisted of Kerrafoam Simple Border Dressing and tubular elastic compression.

Over the next 14 days, the wound and surrounding erythema improved. Wound management transitioned to 3M™ V.A.C.® Therapy on Day 21 (**Figure 3**). Wound measurements were $8.5 \times 4.6 \times 1.0\text{cm}^3$ with a small area of undermining of 0.8cm superiorly. Negative pressure settings were initiated at -125mmHg continuously, then changed to an intermittent setting (cycles of five minutes of negative pressure followed by two minutes off) on Day 4 of therapy.

Over the course of two weeks, the wound improved dramatically, achieving the goals of exudate control, promotion of granulation tissue, reduction of wound size, and wound edge contraction. Intensive periwound hygiene was performed at each dressing change. V.A.C.® Therapy was discontinued on Day 35 (**Figure 4**) with wound measurements of $7.5 \times 3.0 \times 0.1\text{cm}^3$ and a demonstrable healthy granulating wound bed.

The goal of therapy continued to be local antimicrobial management without the use of antibiotics. 3M™ Promogran Prisma™ Matrix was applied to the wound, and 3M™ Touchless Care™ Zinc Oxide Protectant Spray was used to protect the periwound area. Kerrafoam Simple Border Dressing was reapplied as secondary dressing. Mild lower extremity edema was again controlled with an elastic tubular bandage.

On Day 91, the wound measurements were $3.8 \times 0.8\text{cm}^2$ (**Figure 5**). On Day 119, the wound was epithelialized (**Figure 6**), and the patient was no longer receiving wound management services.

Treatment Modalities

- Sharp debridement
- Kerracel Gelling Fiber Dressing
- Kerracel Ag Gelling Fiber Dressing
- Kerrafoam Simple Border Dressing
- V.A.C.® Therapy
- Promogran Prisma Matrix
- Touchless Care Zinc Oxide Protectant Spray

Case Study 8: Figures 1–6

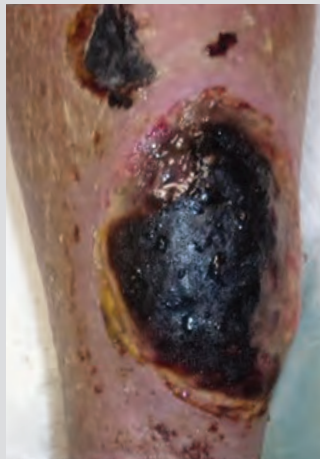

Figure 1. Wound appearance at baseline evaluation.

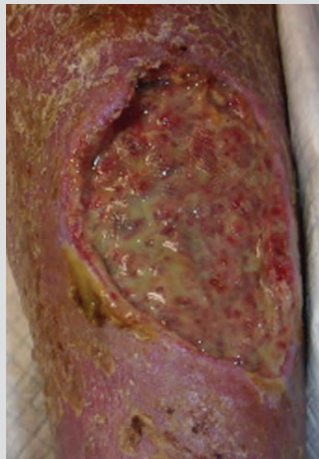


Figure 2. Wound appearance after debridement, irrigation, and seven days of management with gelling fiber dressings.

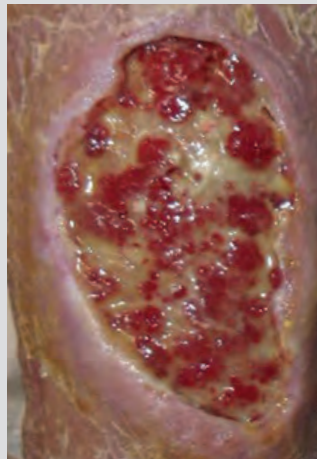


Figure 3. Wound appearance on Day 21.

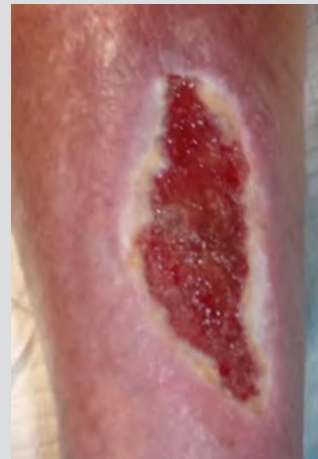

Figure 4. Wound appearance on Day 35.

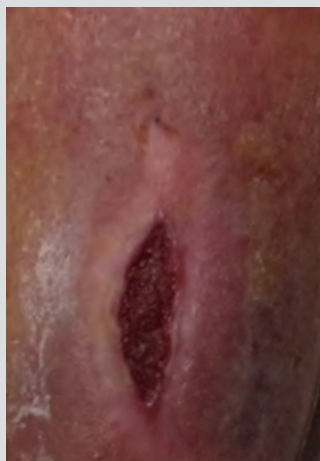

Figure 5. Wound appearance on Day 91.

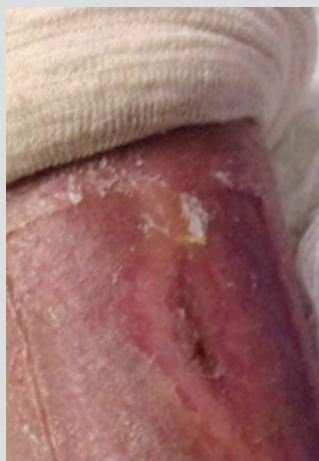

Figure 6. Wound appearance on Day 119.











V.A.C.®
Therapy

Product	Description	Ordering Options*
	3M™ Granufoam™ Small Dressing Kit <ul style="list-style-type: none">1 Granufoam™ Dressing (10 × 7.5 × 3.2cm)1 sheet of V.A.C.® Drape	<ul style="list-style-type: none">1 SensaT.R.A.C.™ Pad with connector1 disposable ruler Case of 5 (M8275051/5) Case of 10 (M8275051/10)
	3M™ Granufoam™ Medium Dressing Kit <ul style="list-style-type: none">1 Granufoam™ Dressing (18 × 12.5 × 3.2cm)2 sheets of V.A.C.® Drape	<ul style="list-style-type: none">1 SensaT.R.A.C.™ Pad with connector1 disposable ruler Case of 5 (M8275052/5) Case of 10 (M8275052/10)
	3M™ Granufoam™ Large Dressing Kit <ul style="list-style-type: none">1 Granufoam™ Dressing (26 × 15 × 3.2cm)2 sheets of V.A.C.® Drape	<ul style="list-style-type: none">1 SensaT.R.A.C.™ Pad with connector1 disposable ruler Case of 5 (M8275053/5) Case of 10 (M8275053/10)
	3M™ Granufoam™ Silver Small Dressing Kit <ul style="list-style-type: none">1 Granufoam™ Silver Dressing (10 × 7.5 × 3.2cm)1 V.A.C.® Drape	<ul style="list-style-type: none">1 SensaT.R.A.C.™ Pad with connector1 disposable ruler Case of 5 (M8275098/5) Case of 10 (M8275098/10)
	3M™ Granufoam™ Silver Medium Dressing Kit <ul style="list-style-type: none">1 Granufoam™ Silver Dressing (18 × 12.5 × 3.2cm)2 sheets of V.A.C.® Drape	<ul style="list-style-type: none">1 SensaT.R.A.C.™ Pad with connector1 disposable ruler Case of 5 (M8275096/5) Case of 10 (M8275096/10)
	3M™ Granufoam™ Silver Large Dressing Kit <ul style="list-style-type: none">1 Granufoam™ Silver Dressing (26 × 15 × 3.2cm)2 sheets of V.A.C.® Drape	<ul style="list-style-type: none">1 SensaT.R.A.C.™ Pad with connector1 disposable ruler Case of 5 (M8275099/5) Case of 10 (M8275099/10)
	3M™ Whitefoam™ Small Dressing Kit <ul style="list-style-type: none">1 polyvinyl alcohol dressing (10 × 7.5 × 1cm)1 V.A.C.® Drape	<ul style="list-style-type: none">1 SensaT.R.A.C.™ Pad with connector1 disposable ruler Case of 5 (M8275068/5) Case of 10 (M8275068/10)
	3M™ Whitefoam™ Large Dressing Kit <ul style="list-style-type: none">1 polyvinyl alcohol dressing (10 × 15 × 1cm)1 V.A.C.® Drape	<ul style="list-style-type: none">1 SensaT.R.A.C.™ Pad with connector1 disposable ruler Case of 5 (M8275067/5) Case of 10 (M8275067/10)
	3M™ Whitefoam™ Small Dressing (foam only) <ul style="list-style-type: none">1 polyvinyl alcohol dressing (10 × 7.5 × 1cm)	Case of 10 (M6275033/10)
	3M™ Whitefoam™ Large Dressing (foam only) <ul style="list-style-type: none">1 polyvinyl alcohol dressing (10 × 15 × 1cm)	Case of 10 (M6275034/10)
	3M™ Granufoam™ Bridge Dressing Kit <ul style="list-style-type: none">1 Granufoam™ Dressing (3 pre-cut Circular pieces and 2 pre-cut rectangular pieces, 6 × 17 × 1.9cm)1 Granufoam™ Bridge Dressing (67cm) with integrated SensaT.R.A.C.™ Pad	<ul style="list-style-type: none">1 sheet of perforated V.A.C.® Drape with pre-cut hole and 5 removal V.A.C.® Drape Strips1 disposable ruler Case of 5 (M8275042/5) Case of 10 (M8275042/10)
	3M™ Granufoam™ Bridge XG Dressing <ul style="list-style-type: none">2 spiral Granufoam™ Dressings (14.7 × 17.4 × 1.75cm, fully unwound: 81.3cm)1 Granufoam™ Bridge Dressing (67cm) with integrated SensaT.R.A.C.™ Pad	<ul style="list-style-type: none">1 sheet of V.A.C.® Drape1 sheet of perforated V.A.C.® Drape with pre-cut hole1 disposable ruler Case of 5 (M8275044/5)
	3M™ Simplace™ Medium Dressing Kit with 3M™ Tegaderm™ Drape <ul style="list-style-type: none">2 spiral Granufoam™ Dressings (14.7 × 17.4 × 1.75cm, fully unwound: 81.3cm)	<ul style="list-style-type: none">3 sheets of 3M™ Tegaderm™ Drape1 SensaT.R.A.C.™ Pad with connector1 disposable ruler Case of 5 (M8275040/5) Case of 10 (M8275040/10)
	3M™ Simplace™ EX Medium Dressing Kit <ul style="list-style-type: none">2 spiral Granufoam™ Dressings (14.7 × 17.4 × 1.75cm fully unwound: 81.3cm)	<ul style="list-style-type: none">1 sheet of V.A.C.® Drape and 2 drape strips1 SensaT.R.A.C.™ Pad with connector1 disposable ruler Case of 5 (M8275045/5)
	3M™ V.A.C.® Drape <ul style="list-style-type: none">1 sheet of adhesive drape (30.5 × 26cm)	Case of 10 (M6275009/10)
	3M™ V.A.C.® Y-Connector <ul style="list-style-type: none">Allows two V.A.C.® Dressings to be connected to one 1 V.A.C.® Therapy Unit**	Case of 5 (M6275066/5) Case of 10 (M6275066/10)



*Default quantities will be shipped unless otherwise specified. Payor restrictions may apply.

**Contact your representative, or review the 3M™ V.A.C.® Therapy Clinical Guidelines or Product IFU for additional information on treating multiple wounds with one 3M™ V.A.C.® Therapy Unit.




3M™ Snap™ Therapy System

Product	Description	Case Qty	SKU
 3M™ Snap™ Therapy Cartridge	Pressure: -125mmHg Capacity: 60mL	Each 10	SNPA125US SNPA125US/10
	Pressure: -100mmHg Capacity: 60mL	Each 10	SNPA100US SNPA100US/10
	Pressure: -75mmHg Capacity: 60mL	Each 10	SNPA075US SNPA075US/10
 3M™ Snap™ Therapy Strap	Size: 18", Small	Each	STPAS
	Size: 21", Medium	Each	STPAM
	Size: 24", Large	Each	STPAL
 3M™ Snap™ Plus 125mmHg Therapy Cartridge	Pressure: -125mmHg Capacity: 150mL	Each 10	SNPA125PLUS SNPA125PLUS/10
 3M™ Snap™ Plus Therapy Strap, Small	Size: 18"	Each	STPASP
	Size: 21"	Each	STPAMP
	Size: 24"	Each	STPALP
 3M™ Snap™ Bridge Dressing Kit	Hydrocolloid: 14cm x 11cm Foam: 8cm x 8cm Interface: Reticulated Open Cell Foam (blue)	Each 10	BKTF14X11 BKTF14X11/10
 3M™ Snap™ Bridge Dressing Kit with SecurRing™ Hydrocolloid Skin Barrier	Hydrocolloid: 14cm x 11cm Foam: 8cm x 8cm Interface: Reticulated Open Cell Foam (blue) Includes 3M™ Snap™ SecurRing™ Hydrocolloid Skin Barrier	Each 10	BKTF14X11S BKTF14X11S/10
 3M™ Snap™ Advanced Dressing Kit	Hydrocolloid: 10cm x 10cm Foam: 8cm x 8cm Interface: Reticulated Open Cell Foam (blue)	Each 10	SKTF10X10 SKTF10X10/10
	Hydrocolloid: 15cm x 15cm Foam: 13cm x 13cm Interface: Reticulated Open Cell Foam (blue)	Each 10	SKTF15X15 SKTF15X15/10
	Hydrocolloid: 20cm x 20cm Foam: 18cm x 18cm Interface: Reticulated Open Cell Foam (blue)	Each 10	SKTF20X20 SKTF20X20/10
 3M™ Snap™ SecurRing™ Hydrocolloid Skin Barrier	Size: 2" diameter	10	SRNG10



3M™ Advanced Wound Care and Skin Integrity Solutions


Product	Cat. No.	Size	Items/Box	Boxes/Case	HCPCS Code
 3M™ Caviton™ No Sting Barrier Film	3343	1mL wand	25	4	Skin Care: A6250 Ostomy: A5120
	3344	1mL wipe	30	4	
	3345	3mL wand	25	25	
	3346	28mL spray bottle	12	1	Ostomy: A6250 Skin Care: A4369
 3M™ Caviton™ Advanced Skin Protectant	5050	2.7mL applicator	20	—	A6250
	5051	0.7mL applicator	20	—	—

3M™ Advanced Wound Care and Skin Integrity Solutions (cont.)


Product		Cat. No.	Size	Items/Box	Boxes/Case	HCPCS Code	
	3M™ Adaptic™ Non-Adhering Dressing	2012	3 in. x 3 in.	50	12	A6222	
		2015	3 in. x 8 in.	24	6	A6223	
		2013	3 in. x 8 in.	36	6		
		2014	3 in. x 16 in.	36	6		
		2018	3 in. x 60 in. roll	10	—	A6266	
		2019	5 in. x 9 in. sheet	12	6	A6223	
	3M™ Adaptic™ Touch Non-Adhering Silicone Dressing	500501	2 in. x 3 in.	10	5	A6206	
		500502	3 in. x 4-1/4 in.	10	5	A6207	
		500503	5 in. x 6 in.	10	5	A6207	
		500504	8 in. x 12-3/4 in.	5	—	A6208	
	3M™ Adaptic™ Digit Non-Adhering Dressing	Digit	MAD003U	Small 3/4 in.	10	17	—
		MAD013U	Medium 1 in.	10	17		
		MAD023U	Large 1-1/8 in.	10	17		
		MAD042U	XL 1-1/4 in.	10	17		
	Digit Toe	MAD062U	Large 1-1/8 in.	10	17		
	3M™ Kerracel™ Gelling Fiber Dressing	CWL1032	2 in. x 2 in.	10	10	A6196	
		CWL1033	4 in. x 5 in.	10	10	A6197	
		CWL1034	6 in. x 6 in.	5	10		
		CWL1035	1 in. x 18 in. ribbon	5	10	A6199	
	3M™ Kerracel™ Ag Gelling Fiber Dressing	CWL1157	2 in. x 2 in.	10	10	A6196	
		CWL1158	4 in. x 5 in.	10	10	A6197	
		CWL1159	6 in. x 6 in.	5	10		
		CWL1160	8 in. x 12 in.	5	10	A6198	
		CWL1163	16 in. x 16 in.	5	10	—	
		CWL1168	0.75 in. x 12 in. ribbon	5	10	A6199	
		CWL1162	0.75 in. x 18 in. ribbon	5	10		
			3M™ Silvercel™ Non-Adherent Antimicrobial Alginate Dressing	900112	1 in. x 12 in.	5	5
900202	2 in. x 2 in.			10	5	A6196	
900404	4-1/4 in. x 4-1/4 in.			10	5	A6197	
900408	4 in. x 8 in.			5	5		
	3M™ Promogran™ Matrix Wound Dressing	PG004	4.34 sq. in. hexagon	10	4	A6021	
		PG019	19.07 sq. in. hexagon	10	4	A6022	
	3M™ Promogran Prisma™ Matrix Wound Dressing	MA028	4.34 sq. in. hexagon	10	4	A6021	
		MA123	19.07 sq. in. hexagon	10	4	A6022	
		MA032	3/8 in. x 3/8 in. x 12-5/8 in. rope	6	4	A6024	
	3M™ Kerramax Care™ Super-Absorbent Dressing	PRD500-025	2 in. x 2 in.	10	110	A6196	
		PRD500-050	4 in. x 4 in.	10	110		
		PRD500-100	5 in. x 6 in.	10	65		
		PRD500-120	4 in. x 9 in.	10	70	A6197	
		PRD500-240	8 in. x 9 in.	10	38		
		PRD500-380	8 in. x 12 in.	5	48		
		PRD500-380-B10	8 in. x 12 in.	10	24	A6198	
		PRD500-600	8 in. x 20 in.	5	25		
		PRD500-600-B10	8 in. x 20 in.	10	15		
		PRD500-300	8 in. x 9 in. multisite	5	38	A6197	


3M™ Advanced Wound Care and Skin Integrity Solutions (cont.)

Product	Cat. No.	Size	Items/Box	Boxes/Case	HCPCS Code
	PRD500-1174	4 in. x 4 in.	10	19	A6196
	PRD500-1175	6 in. x 6 in.	10	13	
	PRD500-1176	8 in. x 8 in.	10	20	A6197
	PRD500-1177	6 in. x 10 in.	10	10	
	90600	2 in. x 2 in.	10	4	A6209
	90601	4 in. x 4 in.	10	4	
	90602	4 in. x 8 in.	5	6	A6210
	90603	8 in. x 8 in.	5	6	A6211
	90604	3-1/2 in. x 3-1/2 in., fenestrated	10	4	A6209
	90605	4 in. x 24 in., roll	1	6	A6211

Product	Cat. No.	Foam Pad Size	Overall Dressing Size	Items/Box	Boxes/Case	HCPCS Code
	90610 (Square)	2 in. x 2 in.	3-1/2 in. x 3-1/2 in.	10	4	A6212
	90611 (Oval)	2-1/2 in. x 3 in.	4 in. x 4-1/2 in.	10	4	
	90612 (Square)	4 in. x 4 in.	5-5/8 in. x 5-5/8 in.	10	4	A6213
	90613 (Oval)	4 in. x 4-1/2 in.	5-5/8 in. x 6-1/8 in.	5	6	
	90614 (Mini Oval)	1-1/4 in. x 1-1/2 in.	2-3/4 in. x 3 in.	10	4	A6212
	90616 (Oval)	5-1/2 in. x 6-3/4 in.	7-1/2 in. x 8-3/4 in.	5	3	A6213
	90619 (Heel/Elbow)	3 in. x 3 in.	5-1/2 in. x 5-1/2 in.	5	4	A6212
	90615* (Mini Wrap)	1 in. x 1 in.	2-3/4 in. x 2-3/4 in.	10	4	

*The mini wrap dressing is constructed of a conformable, absorbent, polyurethane foam pad with a highly breathable, non-waterproof, film backing reinforced with soft cloth tape.

Product		Product	Overall Dressing Size	Items/Box	Boxes/Case	HCPCS Code
		Foam Pad Size				
	90631	Non-bordered Dressing	4 in. x 4-1/4 in.	10	4	A6210
	90632	Non-bordered Dressing	6 in. x 6 in.	10	4	
	90643	Bordered Dressing 0.8 in. x 0.8 in.	2 in. x 2 in.	10	6	A6212
	90640	Bordered Dressing 1.5 in. x 1.5 in	3 in. x 3 in.	10	6	
	90641	Bordered Dressing 2.38 in. x 2.38 in.	4 in. x 4 in.	10	6	
	90642	Bordered Dressing 4.13 in. x 4.13 in.	6 in. x 6 in.	10	4	
	90646	Heel and Contour 3.88 in. x 3.88 in.	6-1/2 in. x 6-1/2 in.	5	4	A6212
	90647	Small Sacral 4.13 in. x 5 in.	6 in. x 6-3/4 in.	10	4	A6213
	90648	Large Sacral 5.25 in. x 6.38 in.	7-1/4 in. x 8-3/4 in.	5	4	

Product	Cat. No.	Application/Use	Comfort Layer Size		Boxes/Case	HCPCS Code
			Compression Layer Size			
 3M™ Coban™ 2 and 3M™ Coban™ 2 Lite Two-Layer Compression Systems	2094N	Below the knee	4 in. x 2.9 yd. (10cm x 2.7m)		8	A6441
			4 in. x 5.1 yd. (10cm x 4.7m) stretched			A6452
	2794N	Below the knee (ABPI > 0.5)	4 in. x 2.9 yd. (10cm x 2.7m)		8	A6441
			4 in. x 5.1 yd. (10cm x 4.7m) stretched			A6452
	2094XL	Below the knee (lg. circumference)	4 in. x 3.8 yd. (10cm x 3.5m)		8	A6441
			4 in. x 6.3 yd. (10cm x 5.8m) stretched			A6452
	20096	Above the knee	6 in. x 3.8 yd. (15cm x 3.5m)		8	—
			6 in. x 4.9 yd. (15cm x 4.5m) stretched			
	2092	Toe boot	2 in. x 1.3 yd. (5cm x 1.2m)		8	—
			2 in. x 3 yd. (5cm x 2.7m) stretched			

References:

1. Baharestani MM, Driver VR. Optimizing clinical and cost effectiveness with early intervention of V.A.C.® Therapy. *Ostomy Wound Manage.* 2008;54(11 Suppl):1–15.
2. Baharestani MM, Houliston-Otto DB, Barnes S. Early versus late initiation of negative pressure wound therapy: examining the impact home care length of stay. *Ostomy Wound Manage.* 2008; 54(11 Suppl):48–53.
3. Driver VR, de Leon JM. Health economic implications for wound care and limb preservation. *J Managed Care Med.* 2008; 1(11):13–19.
4. Miller-Mikolajczyk C, MStat RJ. Real world use: comparing early versus late initiation of negative pressure wound therapy on wound surface area reduction in patients at wound care clinics. Poster presented at The Wound Ostomy and Continence Nurses Society Annual Conference, June 22–26, 2013. Seattle, Washington.
5. Kaplan M, Daly D, Stemkowski S. Early intervention of negative pressure wound therapy using vacuum-assisted closure in trauma patients: impact on hospital length of stay and cost. *Adv Skin Wound Care.* 2009;3(22):128–132.
6. Page JC, Newswander B, Schwenke DC, Hansen M, Ferguson J. Retrospective analysis of negative pressure wound therapy in open foot wounds with significant soft tissue defects. *Advances in Skin and Wound Care.* 2004;17:354–364.
7. Falagas ME, Tansarli GS, Kapaskelis A, Vardakas KZ. Impact of vacuum-assisted closure (VAC) therapy on clinical outcomes of patients with sternal wound infections: a meta-analysis of non-randomized studies. *PLoS One.* 2013 May 31;8(5):e64741.
8. Scherer LA, Shiver S, Chang M, Meredith JW, Owings JT. The vacuum assisted closure device: a method of securing skin grafts and improving graft survival. *Arch Surg.* 2002;137:930–934.
9. Blume PA, Walters J, Payne W, Ayala J, Lantis J. Comparison of negative pressure wound therapy using vacuum-assisted closure with advanced moist wound therapy in the treatment of diabetic foot ulcers: a multicenter randomized controlled trial. *Diabetes Care.* 2008;31:631–636.
10. Armstrong DG, Lavery LA, Diabetic Foot Study Consortium. Negative pressure wound therapy after partial diabetic foot amputation: a multicentre, randomised controlled trial. *Lancet.* 2005;366:1704–1710.
11. Monsen C, Acosta S, Mani K, Wann-Hansson C. A randomised study of NPWT closure versus alginate dressings in peri-vascular groin infections: quality of life, pain and cost. *J Wound Care.* 2015;24:252–260.
12. Ozturk E, Ozguc H, Yilmazlar T. The use of vacuum assisted closure therapy in the management of Fournier's gangrene. *Am J Surg.* 2009;197:660–665.
13. Yao M, Fabbi M, Hayashi H et al. A retrospective cohort study evaluating efficacy in high-risk patients with chronic lower extremity ulcers treated with negative pressure wound therapy. *International Wound Journal.* 2014;11:483–488.
14. Sinha K, Chauhan VD, Maheshwari R, Chauhan N, Rajan M, Agrawal A. Vacuum assisted closure therapy versus standard wound therapy for open musculoskeletal injuries. *Adv Orthop.* 2013;2013:245940.
15. Dalla Paola L, Carone A, Ricci S, Russo A, Ceccacci T, Ninkovic S. Use of vacuum assisted closure therapy in the treatment of diabetic foot wounds. *Journal of Diabetic Foot Complications.* 2010;2:33–44.
16. Armstrong DG, Marston WA, Reyzelman AM, Kirsner RS. Comparative effectiveness of mechanically and electrically powered negative pressure wound therapy devices: a multicenter randomized controlled trial. *Wound Repair and Regen.* 2012;20(3):332–341.

**For clinical, ordering or technical support, please contact your
3M Account Representative, call the 3M Health Care Customer
Helpline at 1-800-228-3957 or visit 3M.com/KCI**



3M Company
2510 Conway Avenue
St. Paul, MN 55144 USA

Phone 1-800-228-3957
Web 3M.com/Medical

IMPORTANT NOTE: The information contained in this document is provided for informational purposes only and represents no statement, promise or guarantee by 3M concerning the levels of reimbursement, payment, calculations, eligibility, charges or that these policies and codes will be appropriate for specific services or products provided or that reimbursement will be made. Information is current as of the date of publication and is subject to change at any time. 3M recommends that you consult your local CMS contracted carrier, Medicaid carrier or other applicable payor organization with regard to specific reimbursement policies, coverage, documentation, payment and criteria. Individual circumstances and situations may vary.

NOTE: All amounts listed do not reflect adjustments for quality reporting, e-prescribing, sequestration or any other reduction. All numbers represent national averages only.

NOTE: As with any case study, the results and outcomes should not be interpreted as a guarantee or warranty of similar results. Individual results may vary depending on the patient's circumstances and condition.

NOTE: Specific indications, contraindications, warnings, precautions, and safety information exist for these products and therapies, some of which may be Rx only. Please consult a clinician and product instructions for use prior to application.

© 2021 3M. All rights reserved. 3M and the other marks shown are marks and/or registered marks. Unauthorized use prohibited. PRA-PM-US-02611 (07/21) US_70-2011-8015-8