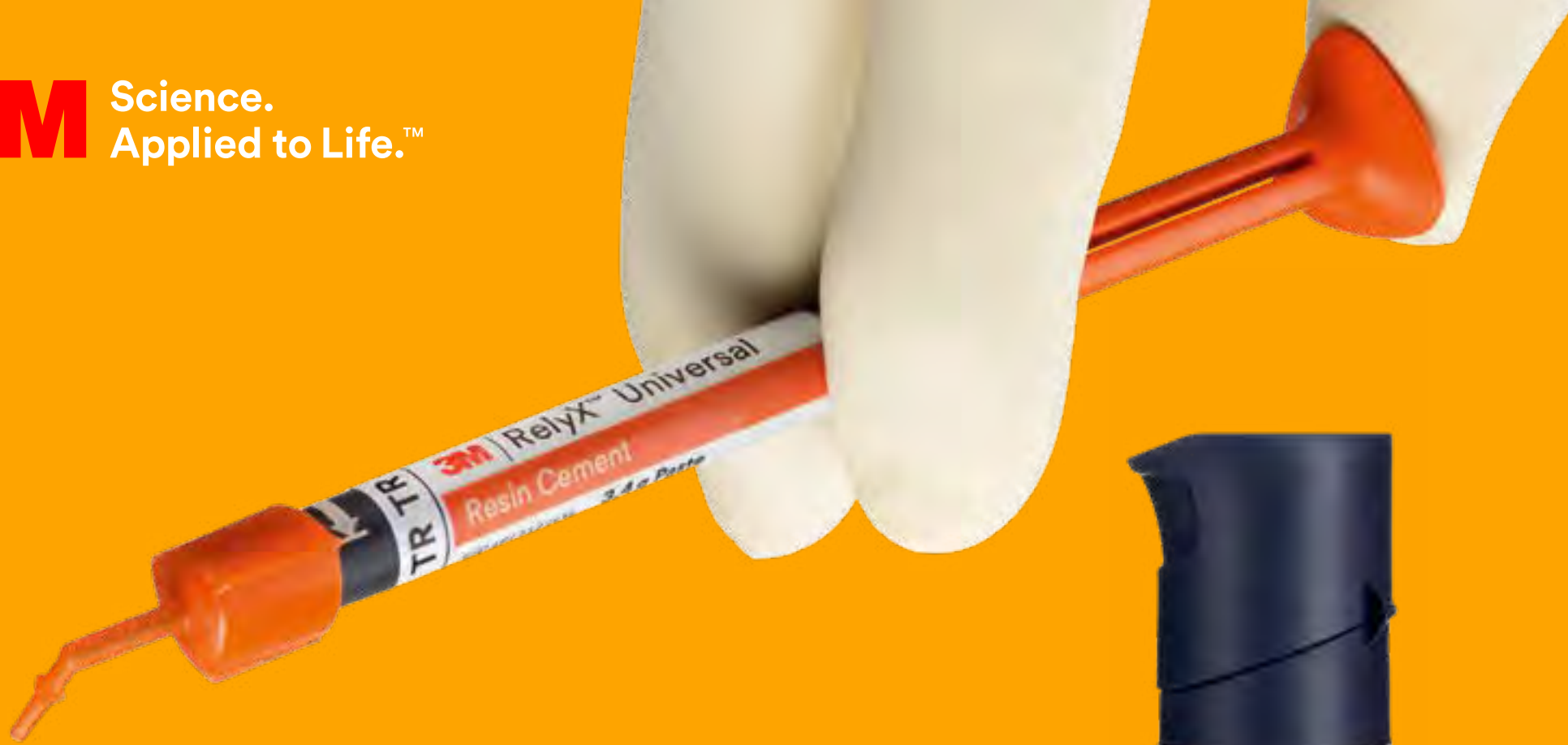

3M Science.
Applied to Life.™



Clinical Case Collection

**The two that
can do it all.**





✓ Universal resin cement with **self-adhesive properties**

✓ **Adhesive resin cement system** with 3M™ Scotchbond™ Universal Plus Adhesive as self-cure tooth primer supporting self-etch, selective-/total-etch techniques

✓ **Universal primer** for all restorative materials including glass ceramics, zirconia and metal

✓ **First radiopaque all-in-one universal adhesive** for all types of direct and indirect restorations

A truly universal two component system.

3M™ RelyX™ Universal Resin Cement works both as a standalone, self-adhesive cement – and as an adhesive cement together with **3M™ Scotchbond™ Universal Plus** Adhesive. The adhesive serves as an universal primer for all materials and covers all direct and indirect bonding indications.

Eliminate the hassle and confusion of multiple resin cements, primers and adhesives and simplify your direct and indirect restorative workflows. Less products to keep on stock and replenish. Saves space, time and money.

Explore universality in action.

A true two-component system that solves virtually all adhesive and self-adhesive dual-cure resin cement cases as well as bonding for direct composite build-ups and fillings.

Tooth pre-treatment options

1
Self-
adhesive

2
(Selective-
etch)
adhesive

3
Total-
etch
adhesive

Veneer,
adhesive bridge

Inlay/onlay

Crown & bridge

Post, bonding for
build-up, crown



Bonding for
composite filling

Total-etch adhesive bonding of a glass ceramic veneer and self-adhesive cementation of a zirconia crown

Clinical Case by Dr. Paulo Monteiro, Portugal



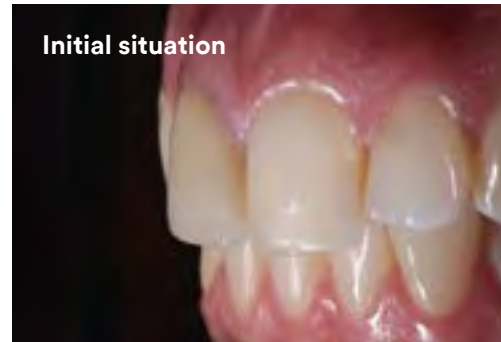24-year-old patient wanted to enhance aesthetics, especially in the upper central incisors. She had an old zirconia crown on tooth 21 with some discoloration and an inadequate cervical margin. Tooth 11 had old composite restorations.

In the treatment plan, it was decided to replace the crown on tooth 21 with a new zirconia crown and make a glass ceramic veneer for tooth 11. A direct composite restoration was planned on tooth 12 as well to create a more harmonious smile curve.

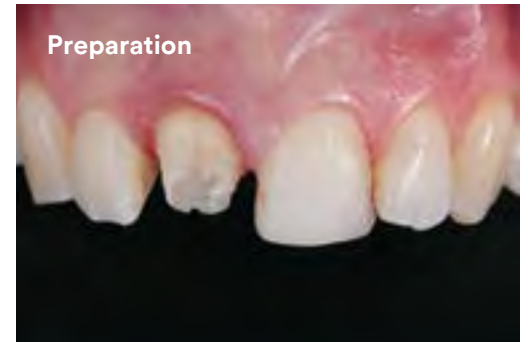3M™ RelyX™ Universal Resin Cement was used for both the self-adhesive cementation of the zirconia crown as well as the esthetic bonding of the glass ceramic veneer. This allowed for a streamlined, more efficient seating process versus using multiple resin cements.

The author holds an International Certification in Advanced Aesthetic and Restorative Dentistry and teaches at Instituto Universitário Egas Moniz, Caparica, Portugal.

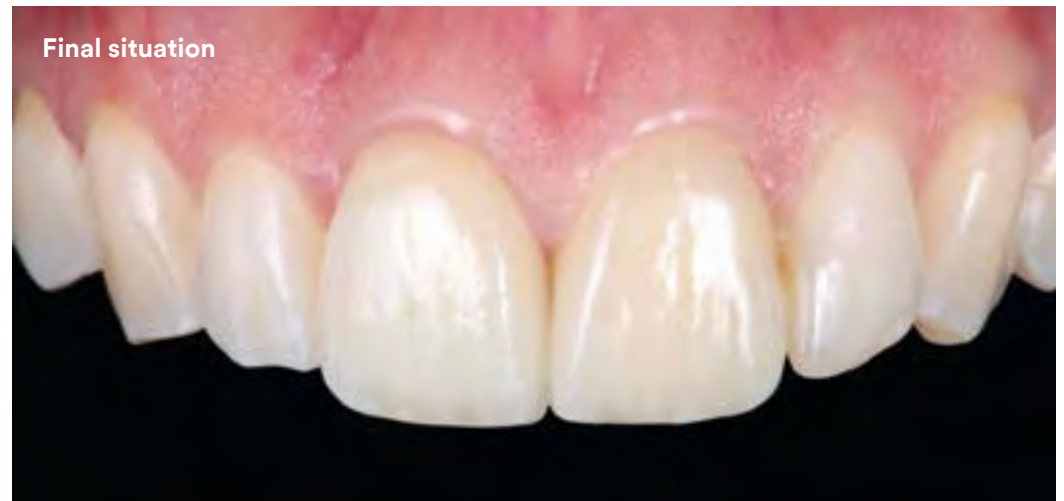Initial situation



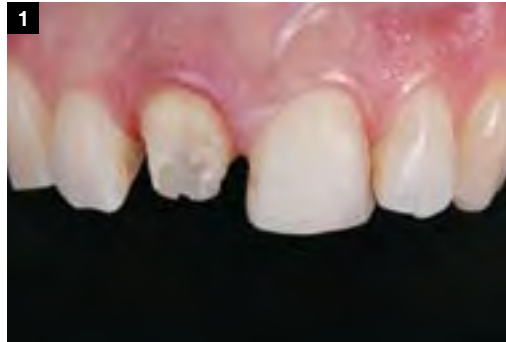Preparation



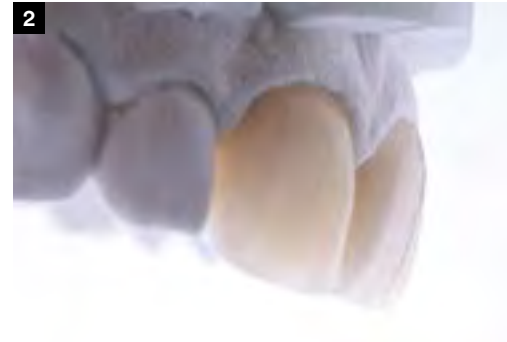Final situation



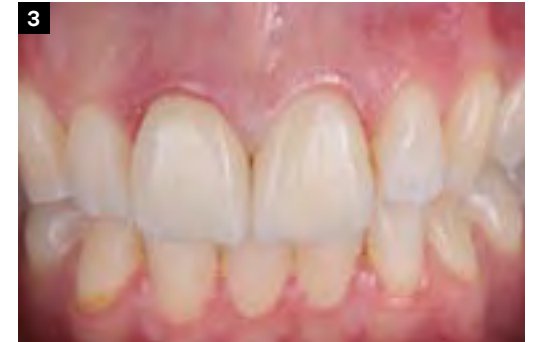Total-etch adhesive bonding of a glass ceramic veneer and self-adhesive cementation of a zirconia crown



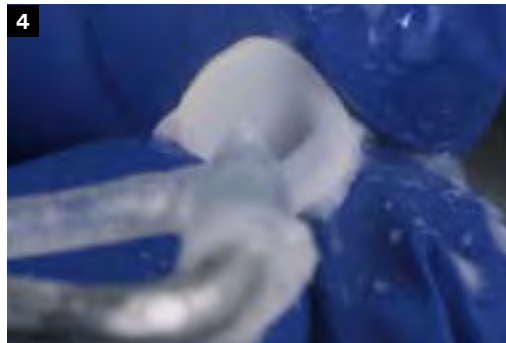
1 Prepared anterior teeth for both a crown and a veneer restoration.




2 Lab made veneered zirconia crown and glass ceramic veneer.



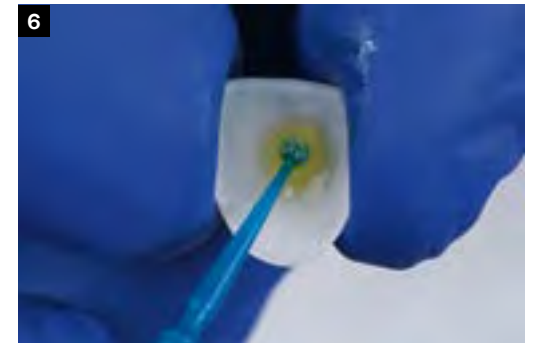
3 Try-In with 3M™ RelyX™ Try-in Paste, shade TR.



4 Sandblasting of the zirconia crown.
No primer required.



5 HF etching of the glass ceramic veneer.



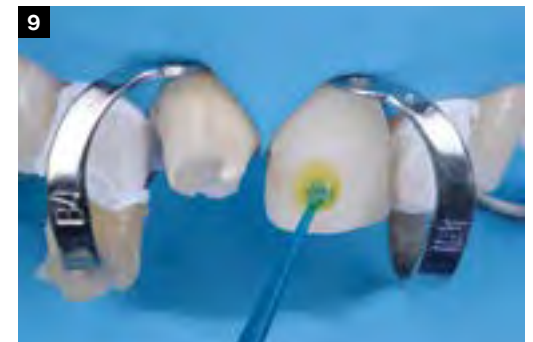6 Application of 3M™ Scotchbond™ Universal Plus
Adhesive followed by air drying.



7 Rubber dam in place, preparations ready for
pre-treatment.



8 Total-etch of veneer preparation.



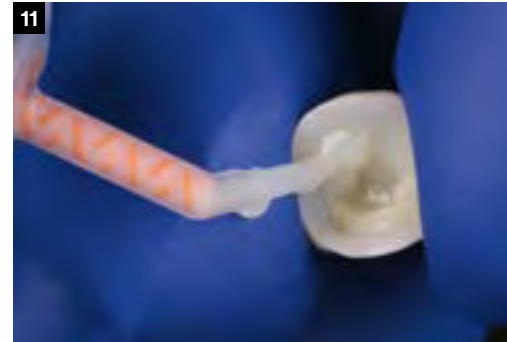9 Application of 3M™ Scotchbond™ Universal Plus
Adhesive followed by air drying.

Clinical Case
by Dr. Paulo Monteiro,
Portugal

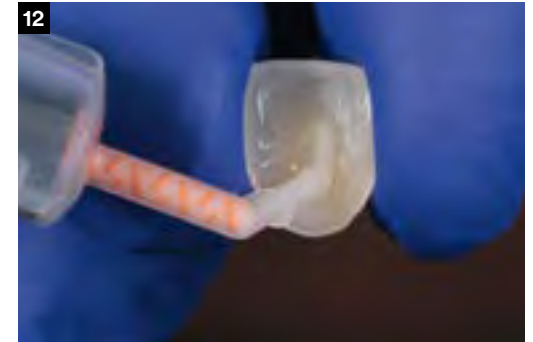Total-etch adhesive bonding of a glass ceramic veneer and self-adhesive cementation of a zirconia crown



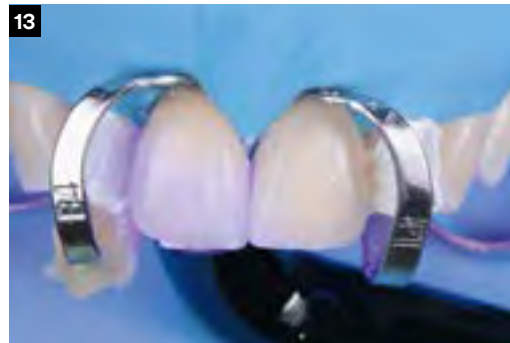Veneer and crown restorations ready for cementation.



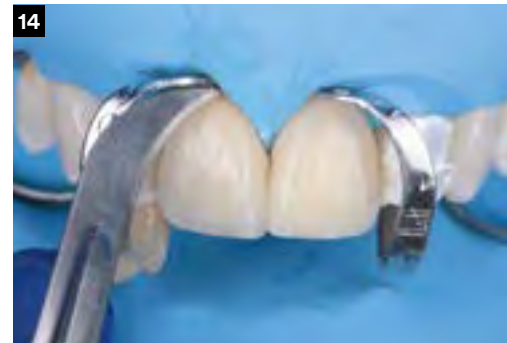Application of 3M™ RelyX™ Universal Resin Cement to the zirconia crown.



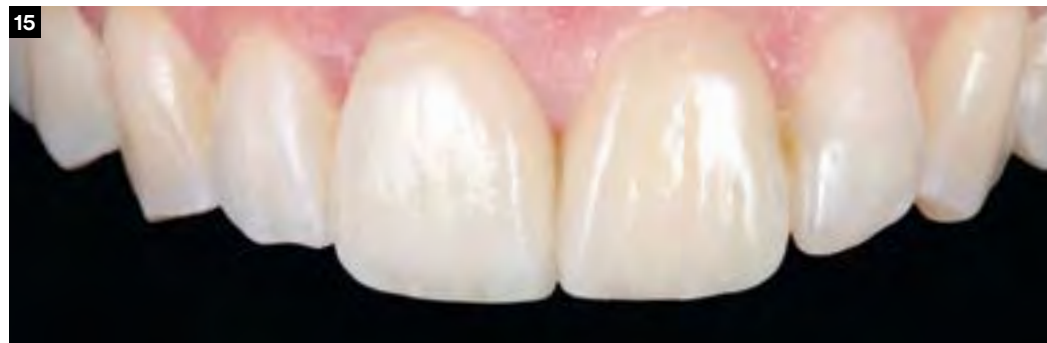Application of 3M™ RelyX™ Universal Resin Cement to the veneer.



Light-cure after clean-up.



Final clean-up at margins.



Final situation after 2 months.

Clinical Case
by Dr. Paulo Monteiro,
Portugal

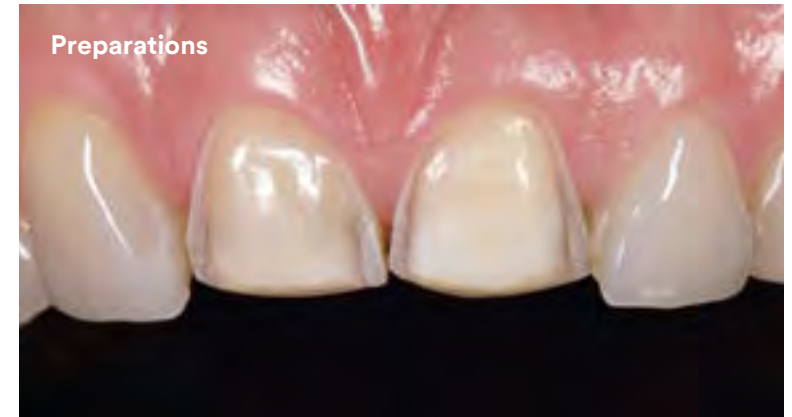Total-etch adhesive bonding of two glass ceramic veneers

Clinical Case by Dr. Rafał Mędzin, Poland

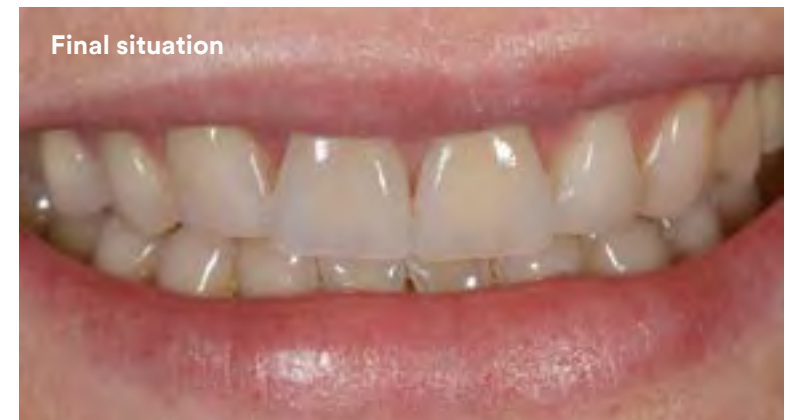A patient with the history of agenesis of lateral incisors received orthodontic treatment and six feldspathic veneers for the upper anteriors. Eight years later, the veneers on teeth 11 and 21 broke in a sport accident and were temporarily repaired with 3M™ Filtek™ Ultimate Universal Restorative. Six months later the old veneers were removed and new feldspathic veneers were placed with 3M™ RelyX™ Universal Resin Cement and 3M™ Scotchbond™ Universal Plus Adhesive using the total-etch technique.



Preparations

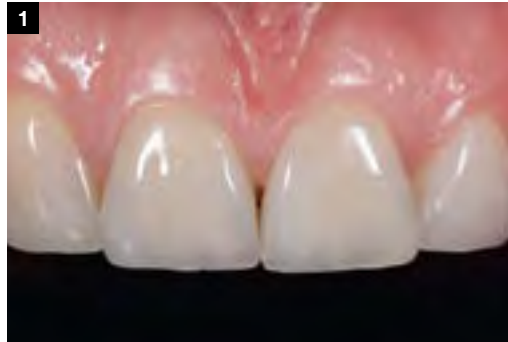

Final situation

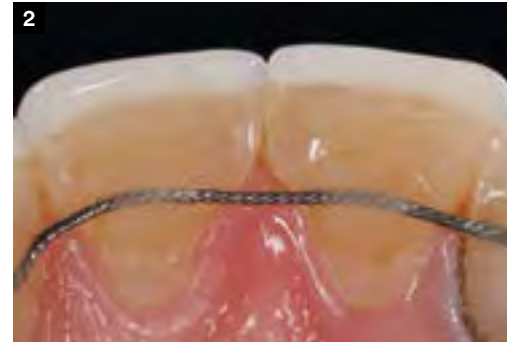


Total-etch adhesive bonding of two glass ceramic veneers

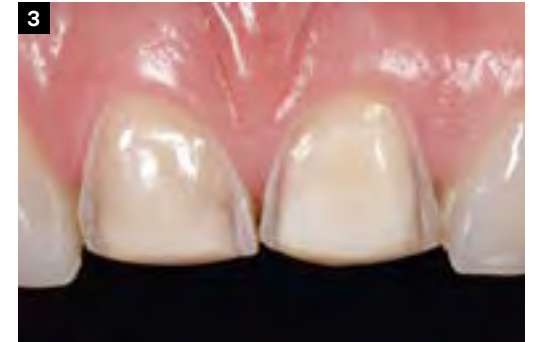Clinical Case
by Dr. Rafał Mędzin,
Poland



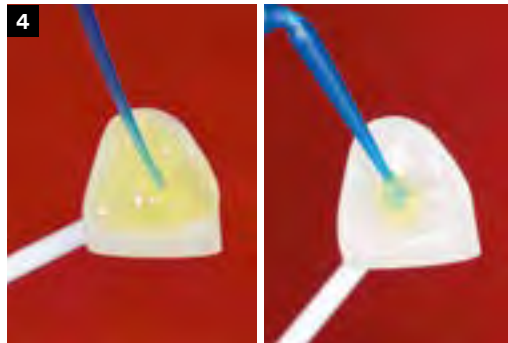
1 Initial situation. Veneers on teeth 11 and 21 repaired with 3M™ Filtek™ Ultimate Universal Restorative.



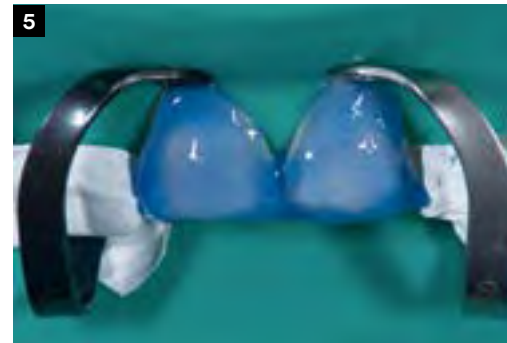2 Palatal view showing incisal edge crack of veneer on tooth 11.



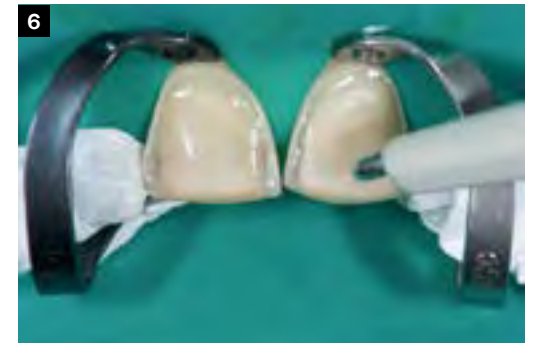3 Final preparations.



4 HF etching of bonding surface and priming with 3M™ Scotchbond™ Universal Plus Adhesive as silane.



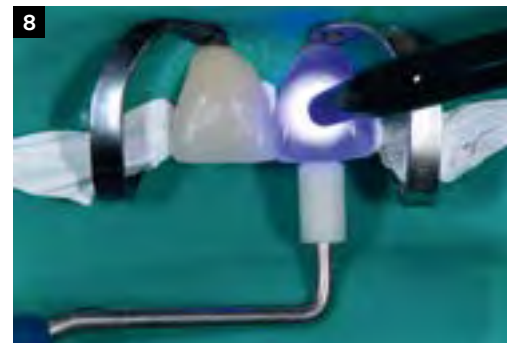5 Total-etch.



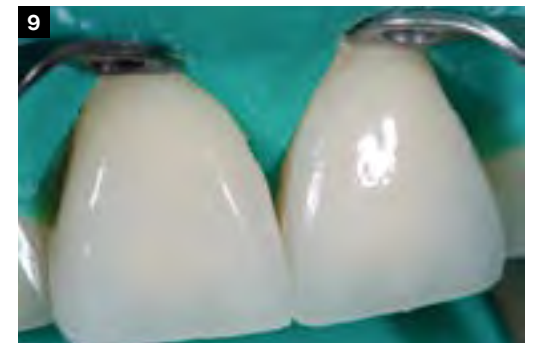6 Air-drying of 3M™ Scotchbond™ Universal Plus Adhesive after application.



7 Application of 3M™ RelyX™ Universal Resin Cement (shade Translucent).



8 Initial attachment with pinpoint light guide.



9 Both veneers in place after clean-up. Note the perfect marginal integration of the ceramic and enamel.

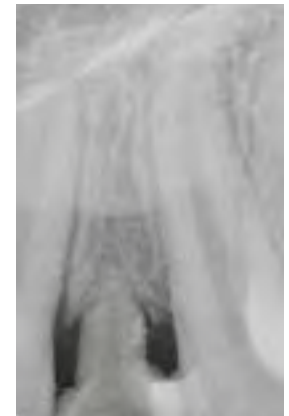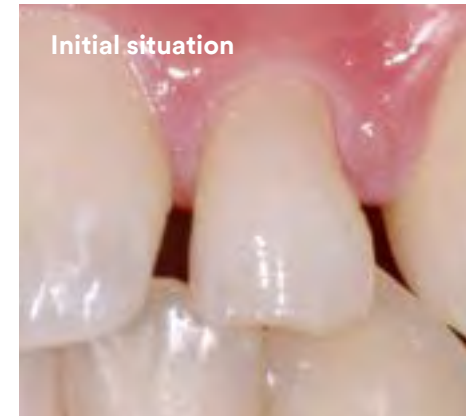Total-etch adhesive cementation of a zirconia Maryland bridge

Clinical Case by Dr. Alwin van Daelen, Netherlands

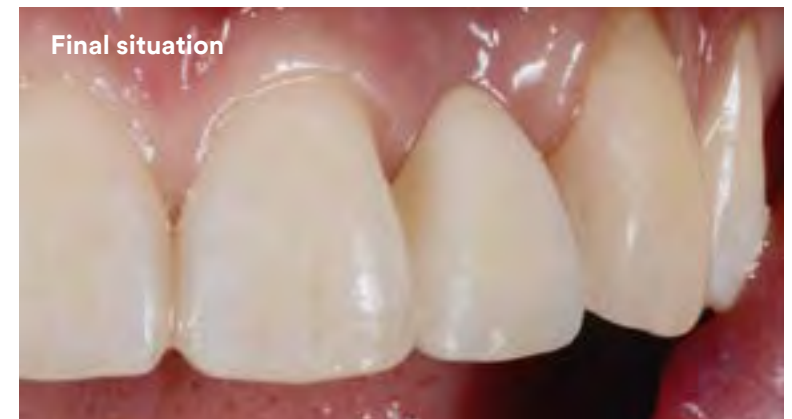A 27-year-old patient with a congenitally missing tooth 22 received orthodontic treatment for three years, however no sufficient space for placing an implant was achieved, due to root proximity (wagonwheel effect). Treatment plan decision was to place a resin bonded uni-wing Maryland bridge. After extraction of the persistent deciduous lateral incisor, pontic site development was performed with the help of a removable retainer. A very shallow preparation of the palatal surface of the left central incisor with a small positioning groove was performed. A labially veneered zirconia bridge was fabricated and bonded with 3M™ RelyX™ Universal Resin Cement and 3M™ Scotchbond™ Universal Plus Adhesive following a total-etch adhesive protocol.



Initial situation

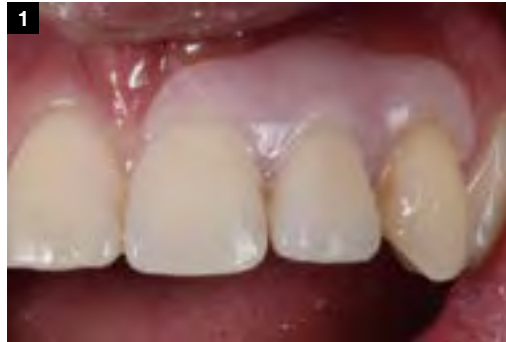

Final situation

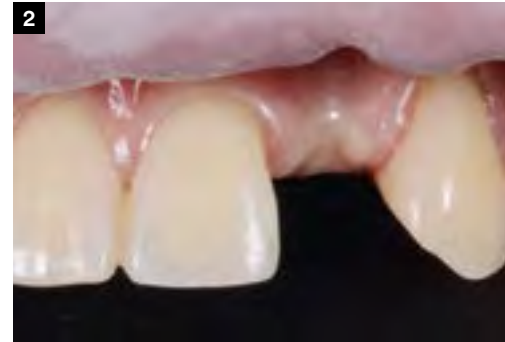

Total-etch adhesive cementation of a zirconia Maryland bridge

Clinical Case
by Dr. Alwin van Daelen,
Netherlands



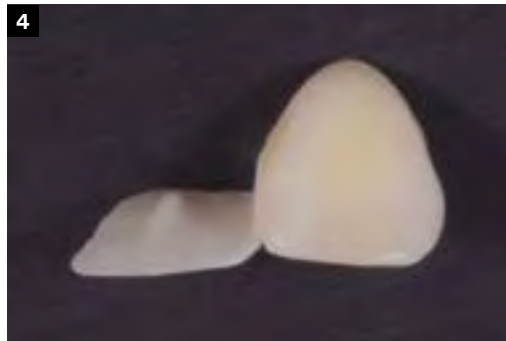1 Situation after extraction with flexible retainer for pontic site development.



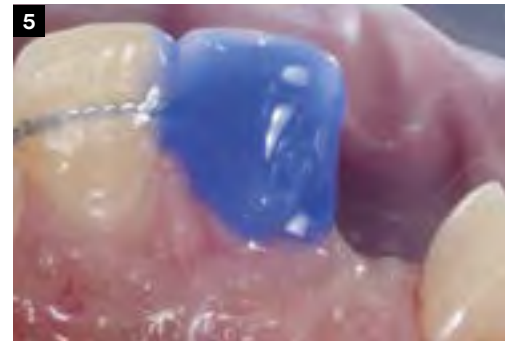2 Pontic site developed.



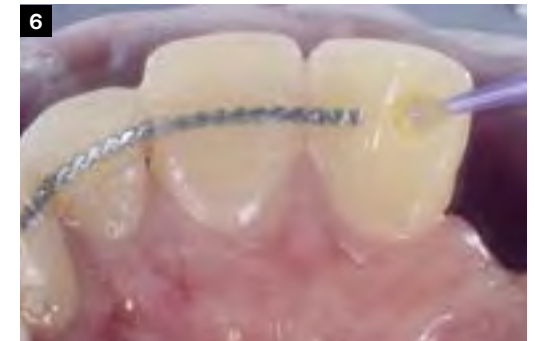3 Palatal view of preparation on model.



4 Maryland bridge with retention element. Pre-treatment of bonding surface was done by sandblasting followed by priming.



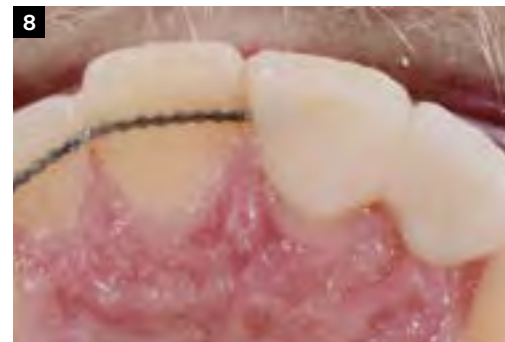5 Etching of preparation.



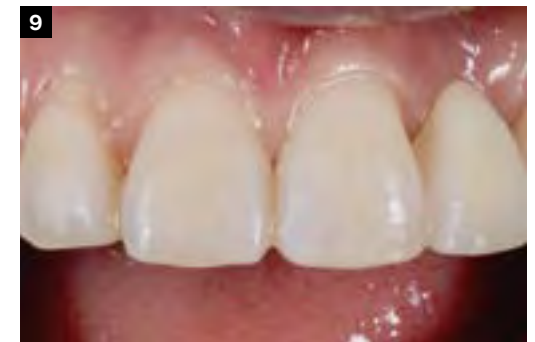6 Application of 3M™ Scotchbond™ Universal Plus Adhesive.



7 Application of 3M™ RelyX™ Universal Resin Cement.



8 Restoration in place after final clean-up.

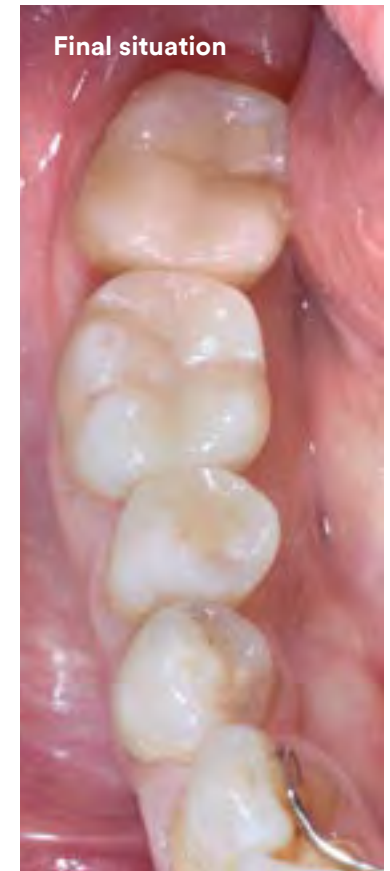
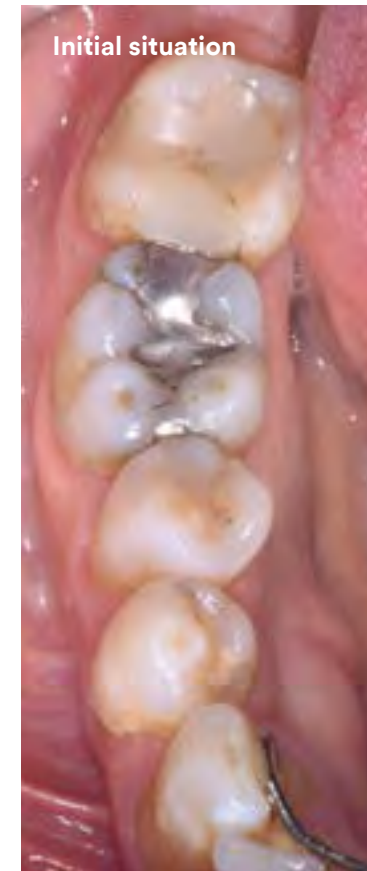
9 Final situation.

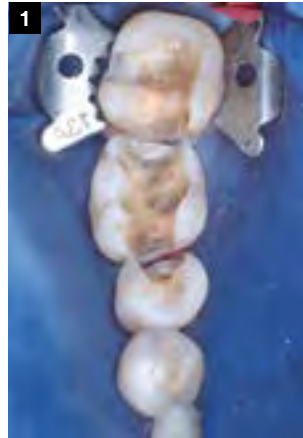Selective-etch adhesive cementation of chairside CAD/CAM glass ceramic inlays

Clinical Case by Dr. Stergios Zafiriadis, Switzerland

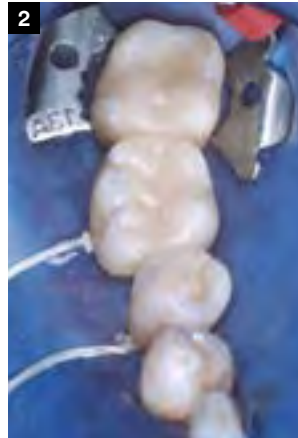46-year-old patient presented with secondary caries on teeth 35, 36, 37. Teeth were restored with chairside CAD/CAM inlays (Straumann® nIce® A2 LT) cemented with 3M™ RelyX™ Universal Resin Cement and 3M™ Scotchbond™ Universal Plus Adhesive using the selective-etch technique.



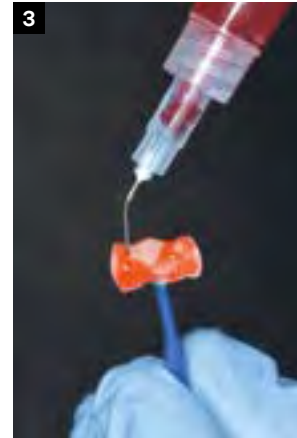Selective-etch adhesive cementation of chairside CAD/CAM glass ceramic inlays



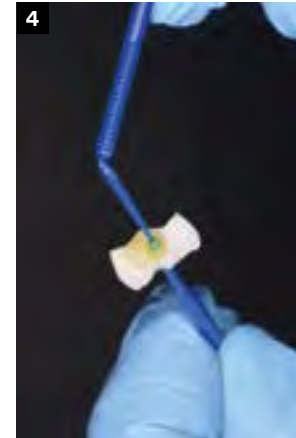1
Preparations.



2
Try-in of inlays.



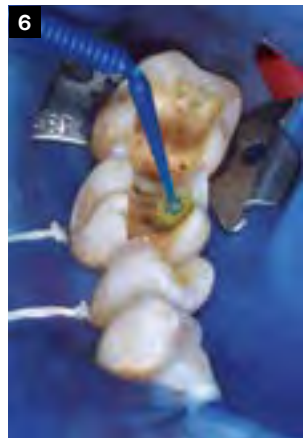3
HF etching.



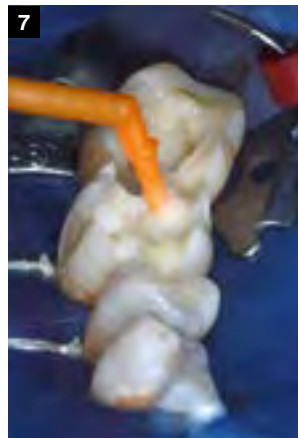4
Application of 3M™ Scotchbond™
Universal Plus Adhesive as silane
primer.



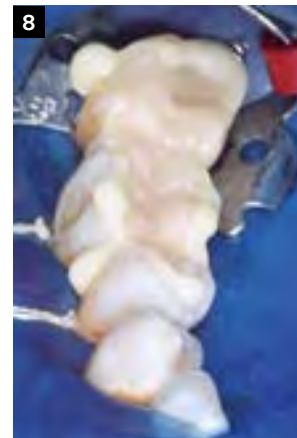5
Selective enamel etching.



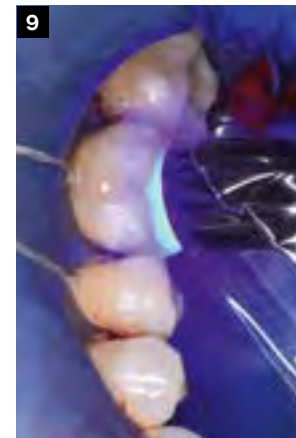6
Application of 3M™ Scotchbond™
Universal Plus Adhesive.



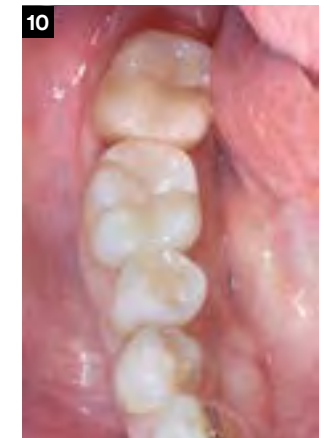7
Application of 3M™ RelyX™
Universal Resin Cement into the
cavities.



8
Right after placement –
cement excess stays put
for easy excess clean-up.



9
Final light-cure with 3M™ Elipar™
DeepCure LED Curing Light
after excess clean-up.



10
Final situation.

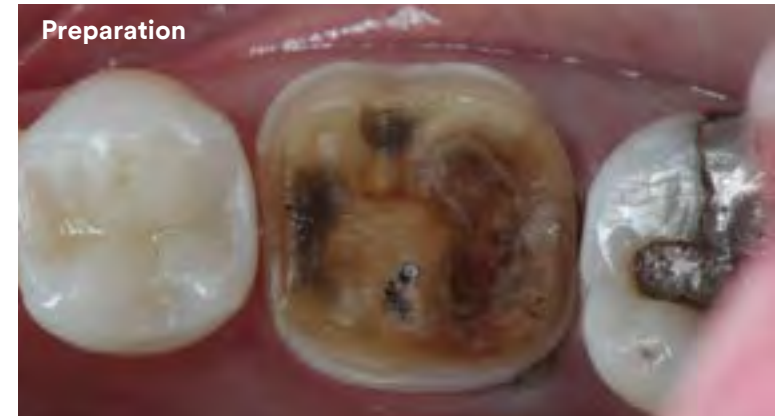Selective-etch adhesive bonding of a glass ceramic onlay

Clinical Case by Dr. Akit Patel, United Kingdom

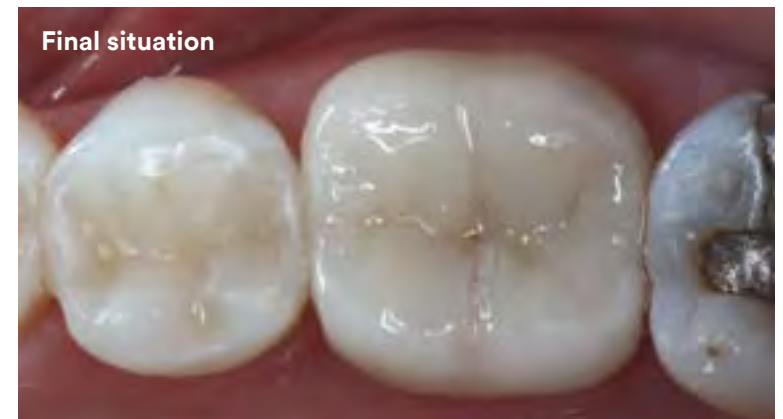A 57-year-old patient presented with a failed onlay on tooth 36. An IPS e.max® Press onlay was defined as the treatment plan. The onlay was primed with 3M™ Scotchbond™ Universal Plus Adhesive as the silane and cemented with 3M™ RelyX™ Universal Resin Cement and Scotchbond Universal Plus Adhesive in the selective-etch adhesive technique.



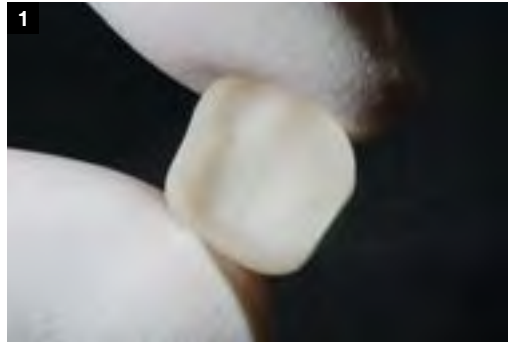Preparation



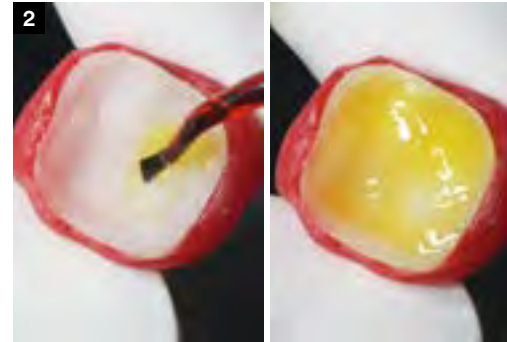Final situation



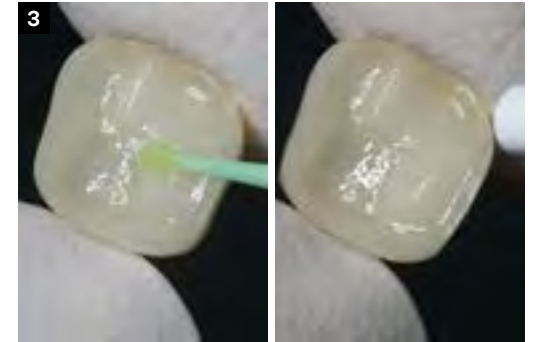Selective-etch adhesive bonding of a glass ceramic onlay



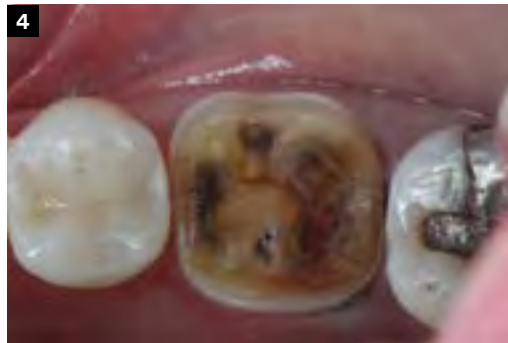1 IPS e.max® Press onlay.



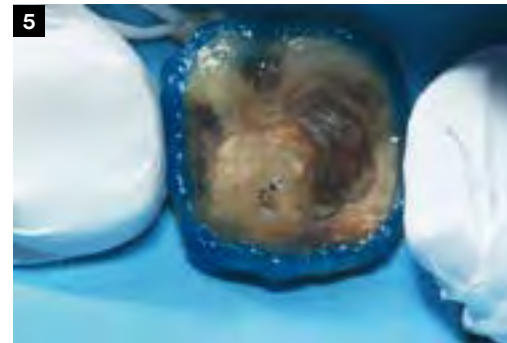
2 HF etching of bonding surface. External surface is protected with wax.



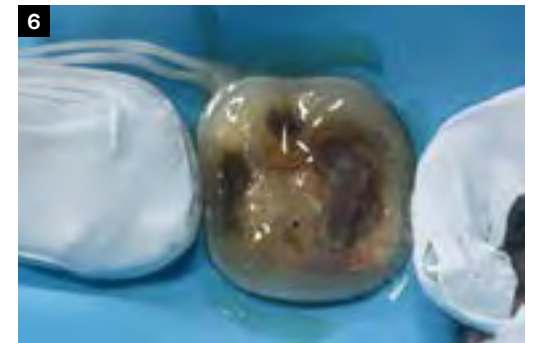3 Application of 3M™ Scotchbond™ Universal Plus Adhesive as a silane followed by air drying.



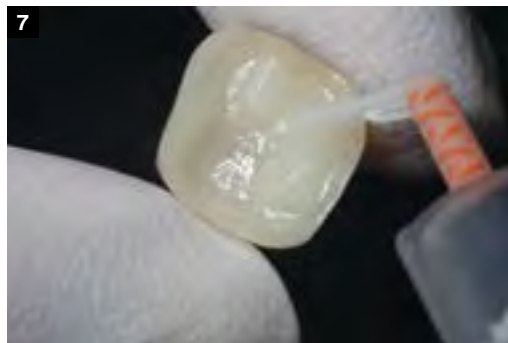4 Prepped tooth.



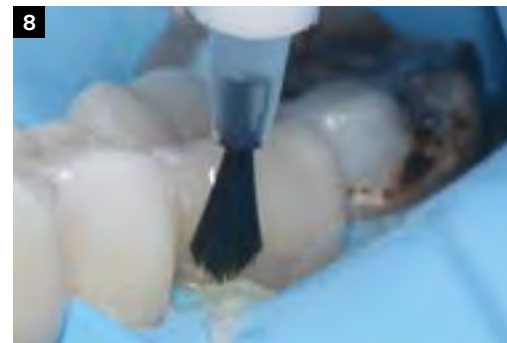5 Selective enamel etch with 3M™ Scotchbond™ Universal Plus Etchant after cleaning of prep with 50 µm alumina.



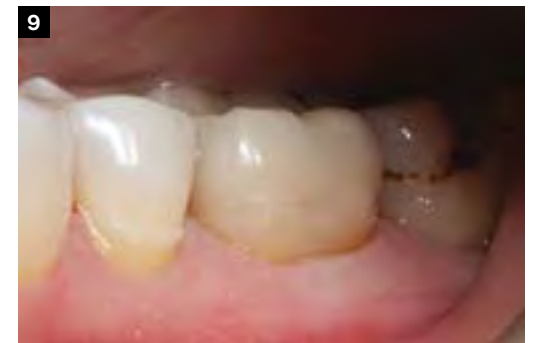6 Tooth prep with applied 3M™ Scotchbond™ Universal Plus Adhesive after air-drying. No light-cure.



7 Application of 3M™ RelyX™ Universal Resin Cement.



8 Excess clean-up.



9 Final situation.

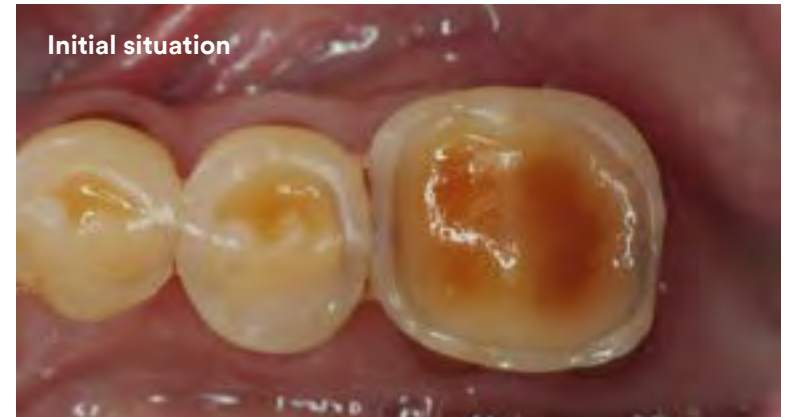Selective-etch adhesive bonding of a metal onlay

Clinical Case by Dr. Akit Patel, United Kingdom

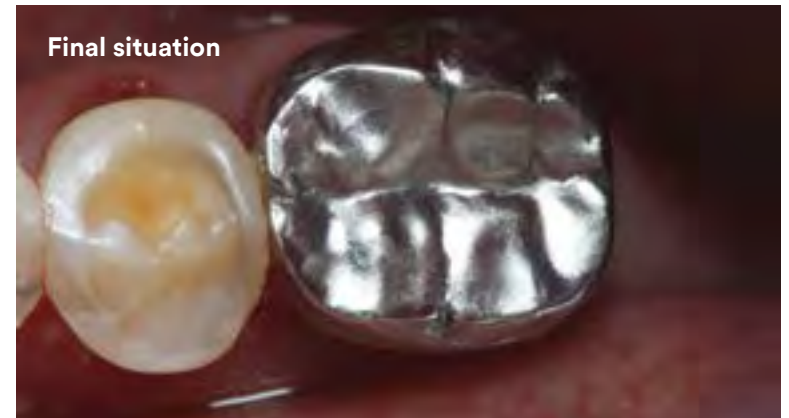A patient of 68 years presented with severe wear on tooth 36. The tooth was conservatively prepared for a non-precious metal adhesive onlay to protect the exposed dentine and restore occlusal function. The onlay was pre-treated by sandblasting and in this case the optional priming of metal with 3M™ Scotchbond™ Universal Plus Adhesive was done. For the cementation 3M™ RelyX™ Universal Resin Cement and Scotchbond Universal Plus Adhesive were used in the selective-etch adhesive technique.



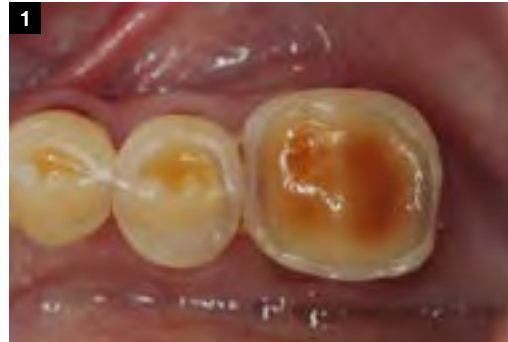Initial situation



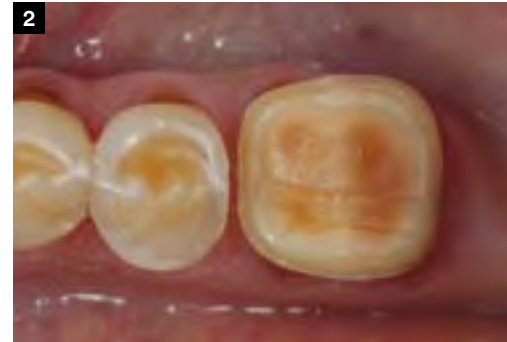Final situation



Selective-etch adhesive bonding of a metal onlay



Initial situation.



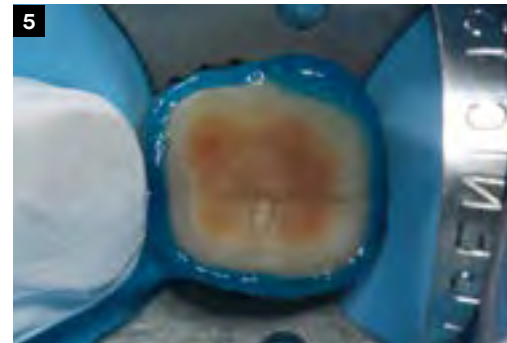
Preparation.



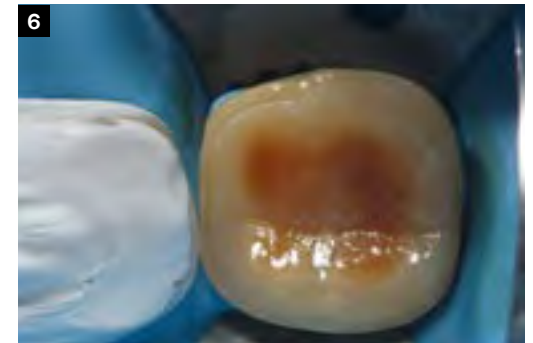
Sandblasting of metal onlay bonding surface.



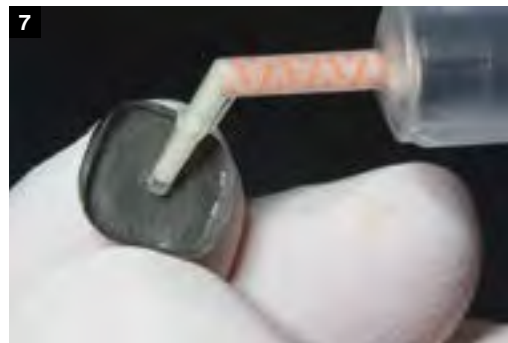Application of 3M™ Scotchbond™ Universal Plus Adhesive followed by air-thinning.



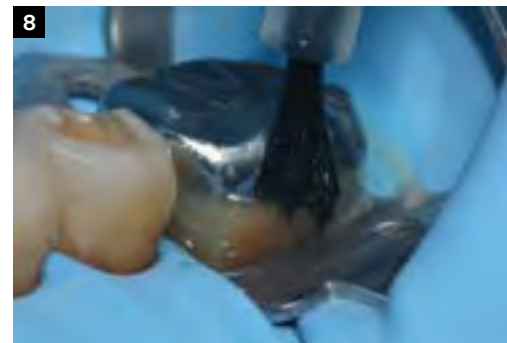
Selective enamel etch with 3M™ Scotchbond™ Etchant after cleaning of prep with 50 µm alumina.



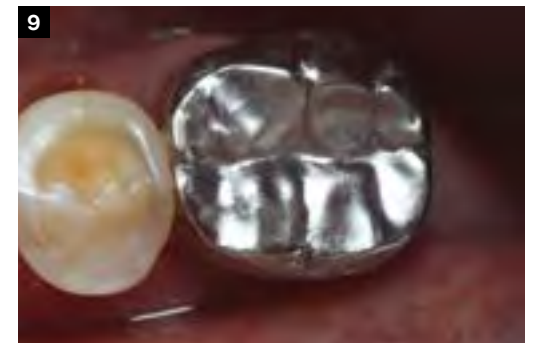After application and air thinning of 3M™ Scotchbond™ Universal Plus Adhesive. No light-cure.



Application of 3M™ RelyX™ Universal Resin Cement.



Excess clean-up.



Final situation.

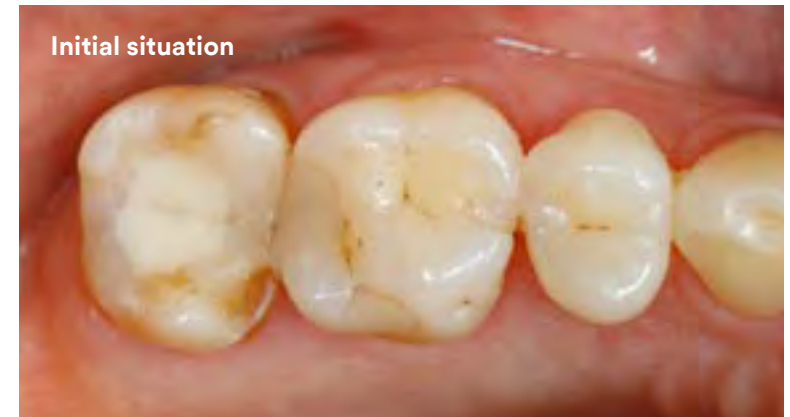Selective-etch adhesive bonding of an IPS e.max® CAD partial crown

Clinical Case by Dr. Gunnar Reich, Germany

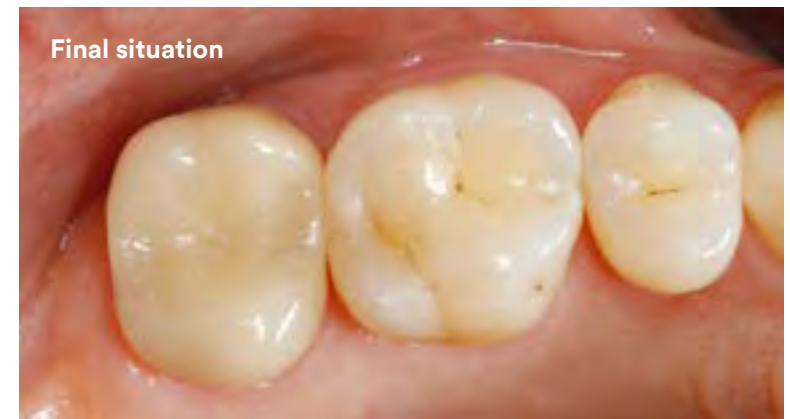A 52-year-old female patient presented with a large composite filling and a fractured cusp on the endodontically treated tooth 26. The tooth was restored with a lithium disilicate glass ceramic partial crown cemented with 3M™ RelyX™ Universal Resin Cement and 3M™ Scotchbond™ Universal Plus Adhesive in the selective-etch adhesive technique.



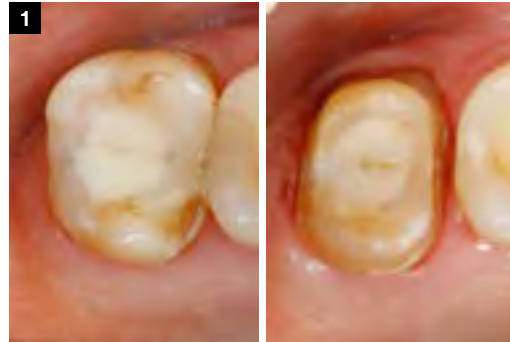Initial situation



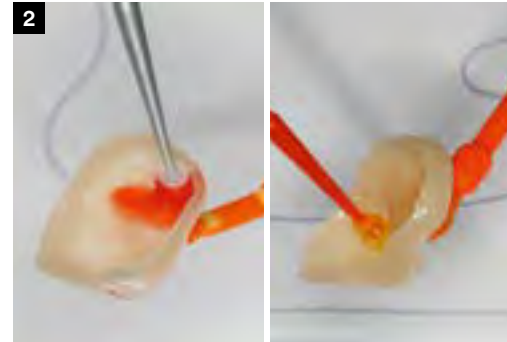
Final situation



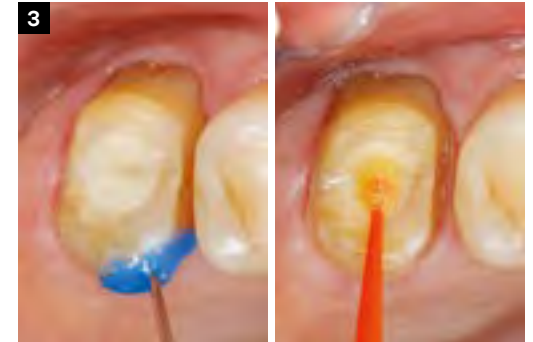Selective-etch adhesive bonding of an IPS e.max® CAD partial crown



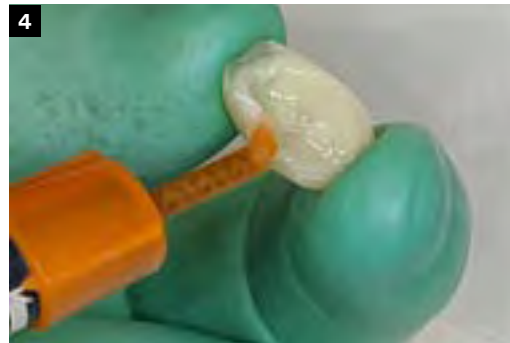Initial situation and preparation.



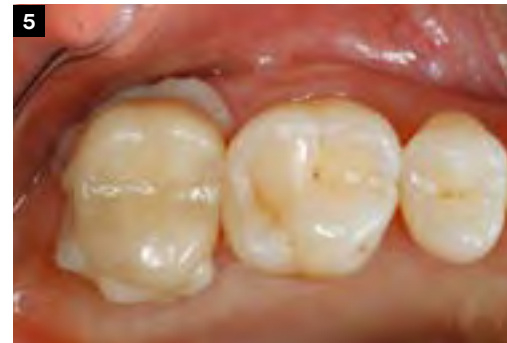HF etching of bonding surface and priming with 3M™ Scotchbond™ Universal Plus Adhesive as silane.



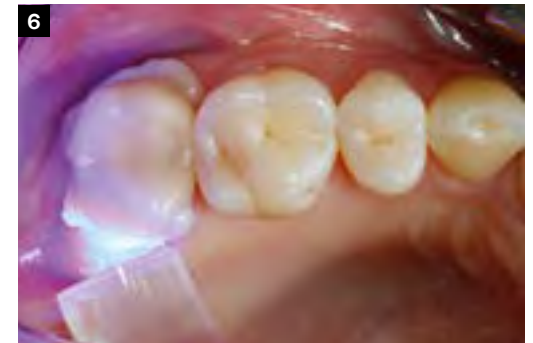Selective enamel etch with 3M™ Scotchbond™ Universal Etchant and application of 3M™ Scotchbond™ Universal Plus Adhesive.



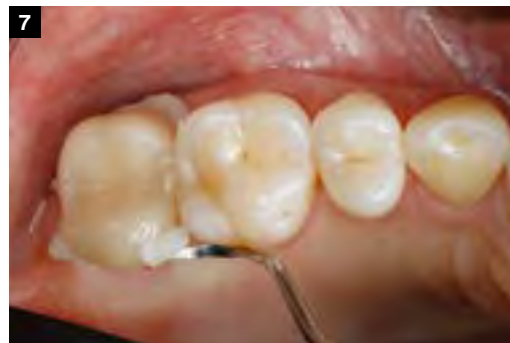Application of 3M™ RelyX™ Universal Resin Cement.



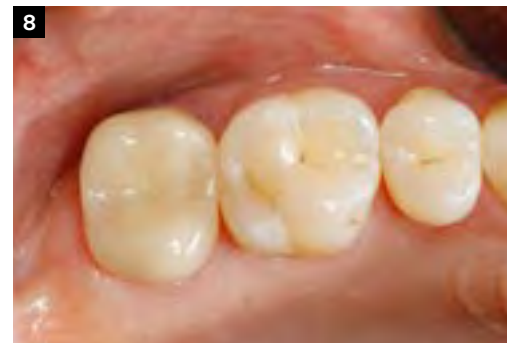Seated partial crown with cement excess.



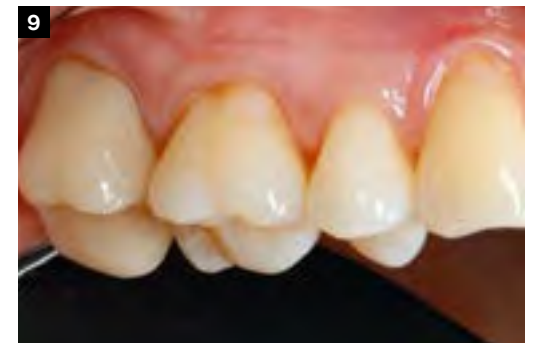Tack-cure of cement excess.



Excess clean-up with scaler.



Final situation.



Final situation buccal view.

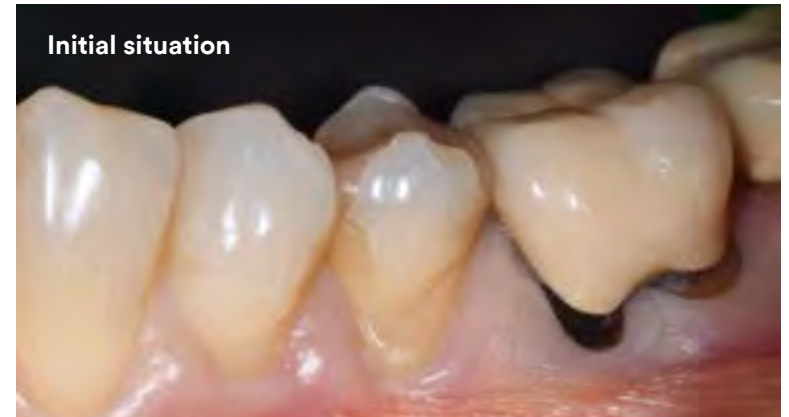Total-etch adhesive bonding of a chairside CAD/CAM glass ceramic overlay

Clinical Case by Dr. Stergios Zafiriadis, Switzerland

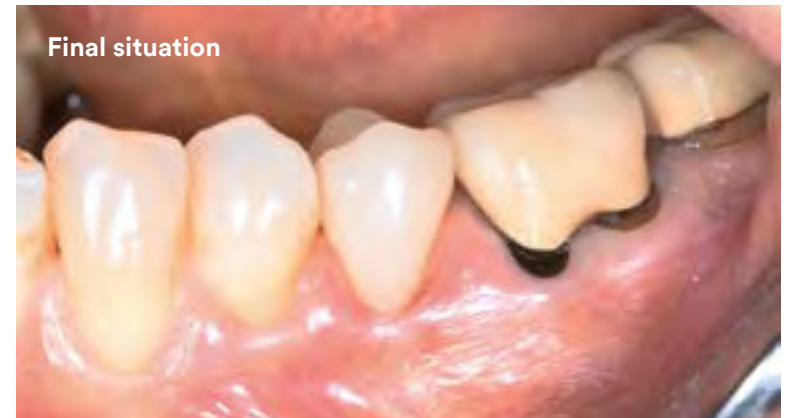The 61-year-old female patient had a fractured cusp and secondary caries on tooth 35. The tooth was restored with a Straumann® nIce® A2 HT overlay manufactured in a chairside CAD/CAM process. 3M™ Scotchbond™ Universal Plus Adhesive was used as restoration primer and tooth adhesive with a total-etch technique. 3M™ RelyX™ Universal Resin Cement was used as the cement.



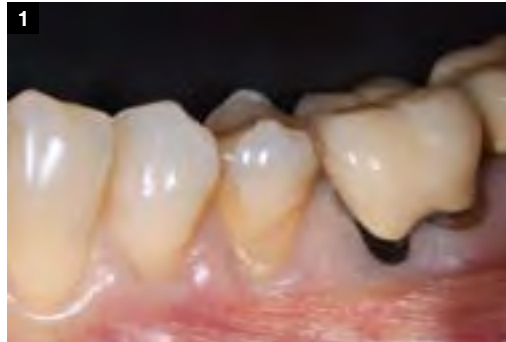Initial situation



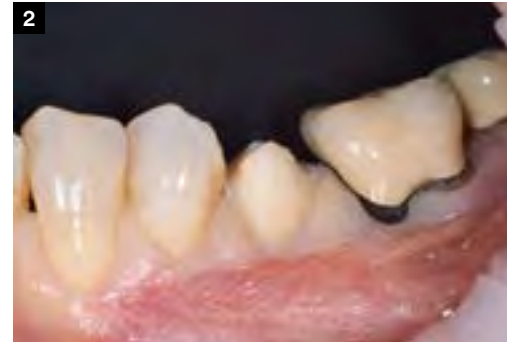Final situation



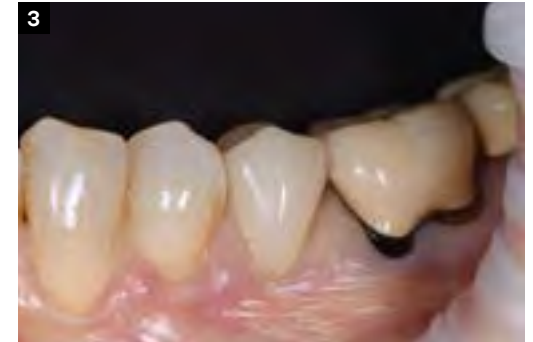Total-etch adhesive bonding of a chairside CAD/CAM glass ceramic overlay



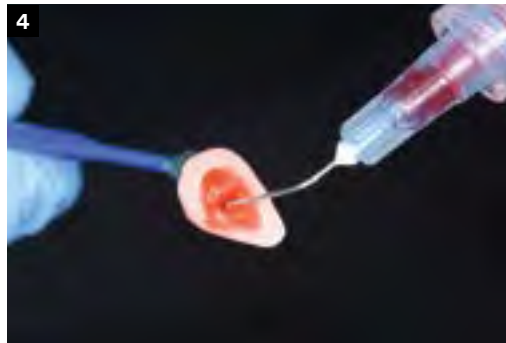Initial situation.



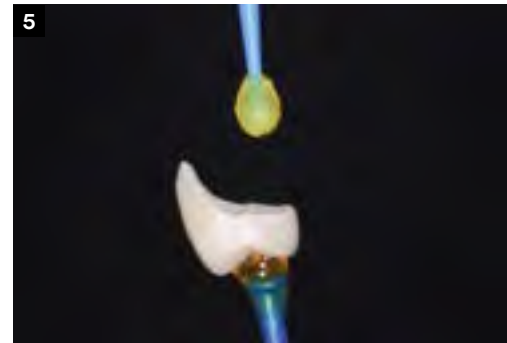Preparation.



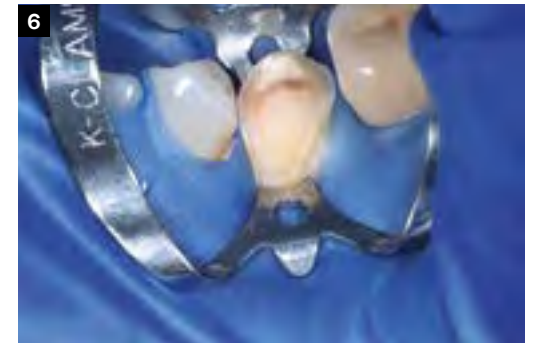Try-in of glass ceramic overlay.



HF etching.



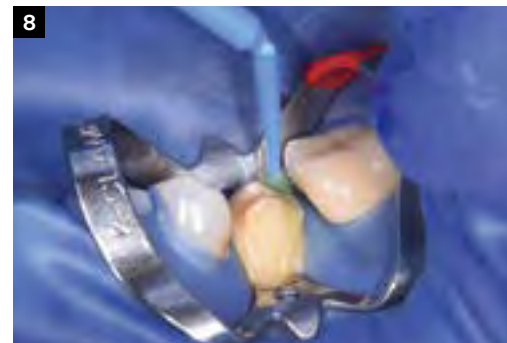Application of 3M™ Scotchbond™ Universal Plus Adhesive as silane primer.



Preparation ready for bonding.



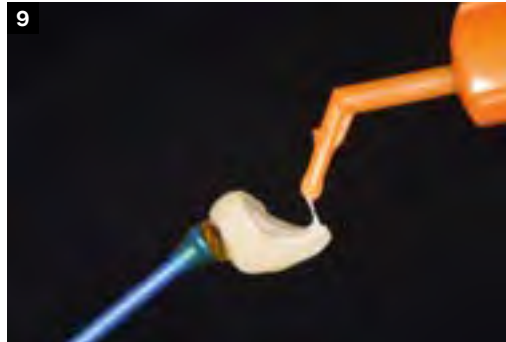Total-etch.



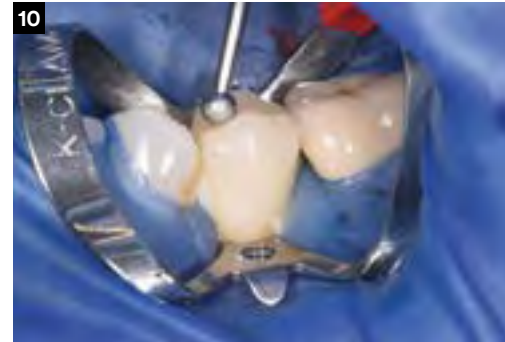Application of 3M™ Scotchbond™ Universal Plus Adhesive.

Clinical Case
by Dr. Stergios Zafiriadis,
Switzerland

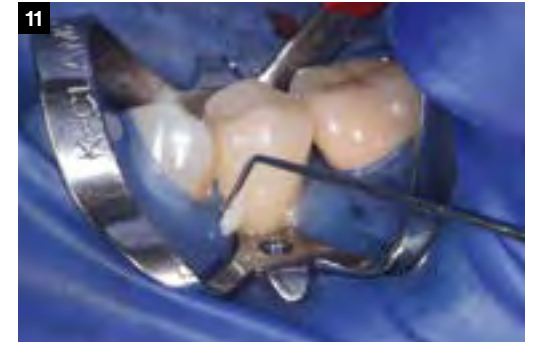**Total-etch
adhesive
bonding of a
chairside
CAD/CAM
glass ceramic
overlay**



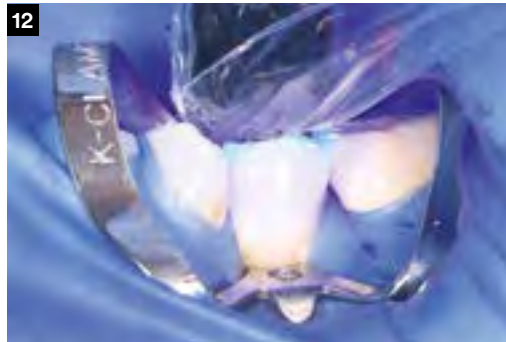Application of 3M™ RelyX™ Universal Resin Cement.



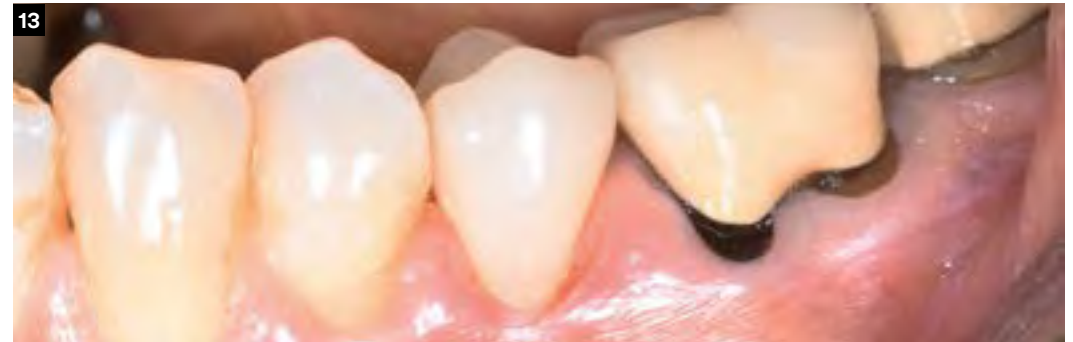Seating of the restoration.



Excess clean-up.



Light-curing.

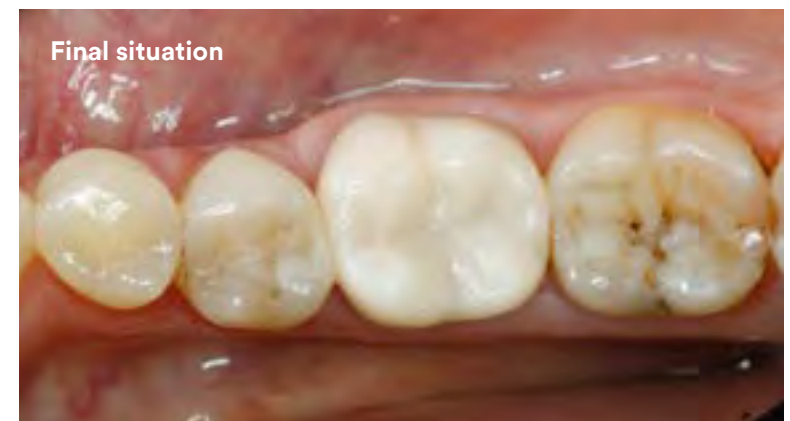
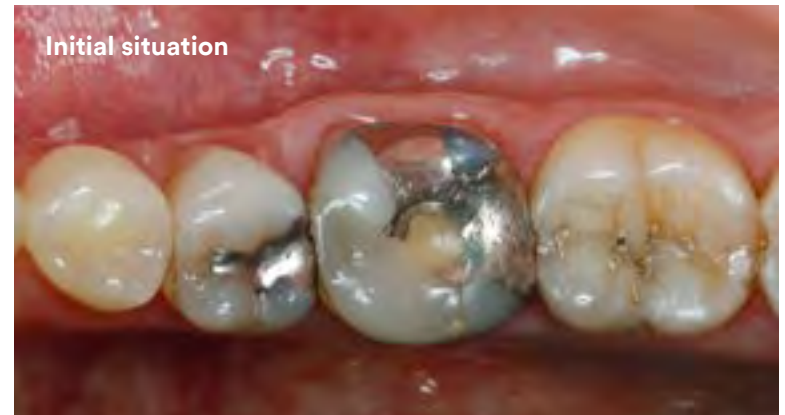
Final situation right after placement.

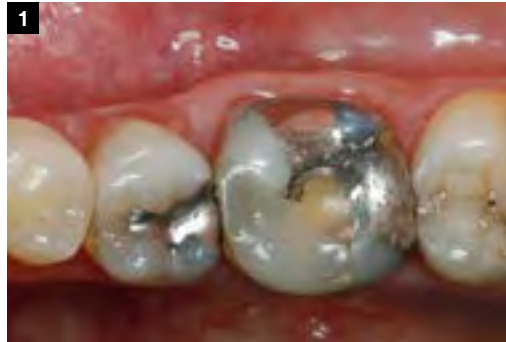Self-adhesive cementation of a zirconia crown

Clinical Case by Dr. Gunnar Reich, Germany

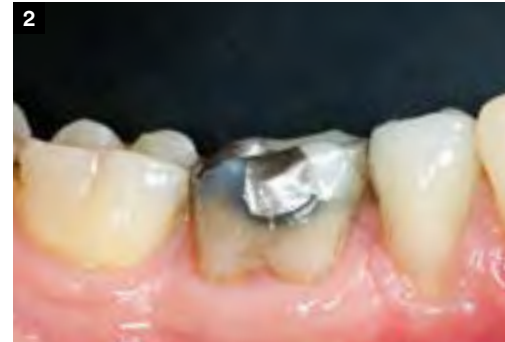A 55-year-old female patient presented with an insufficient amalgam filling and fractured enamel on tooth 36. A 3M™ Chairside Zirconia crown was fabricated and seated using 3M™ RelyX™ Universal Resin Cement with a self-adhesive protocol.



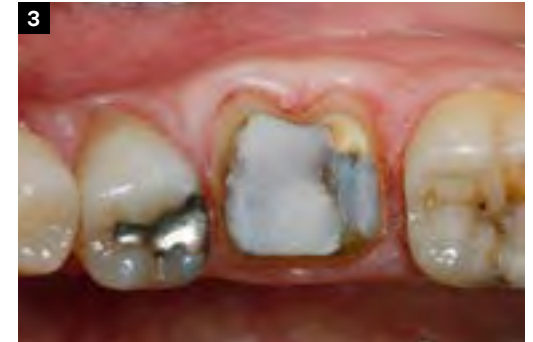Self-adhesive cementation of a zirconia crown



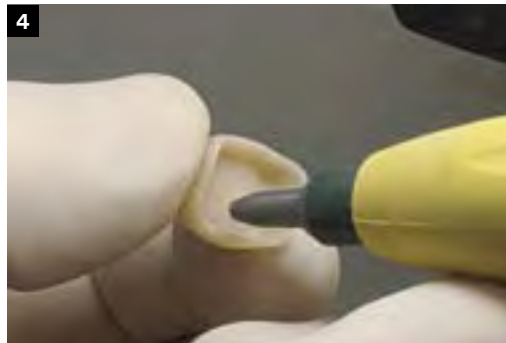Initial situation.



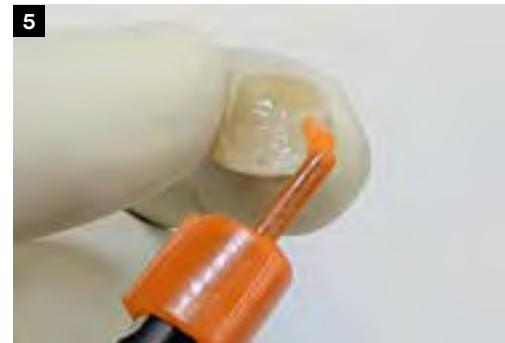Initial situation (buccal view).



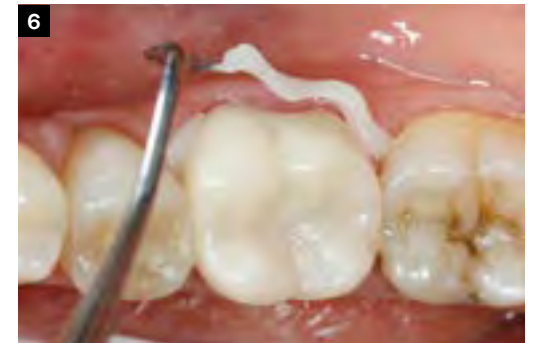Preparation.



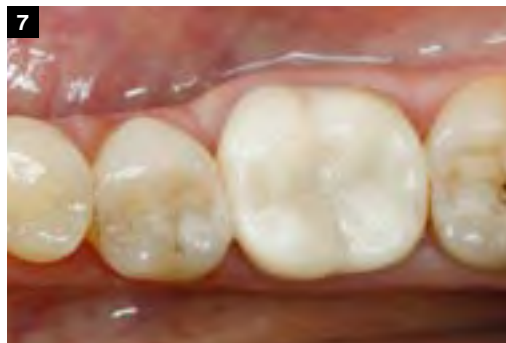Sandblasting.



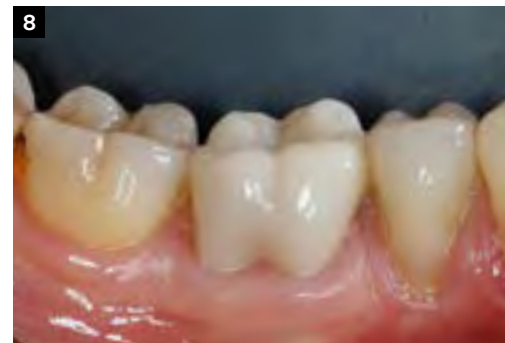Application of 3M™ RelyX™ Universal Resin Cement.



Excess clean-up.



Final situation.



Final situation (buccal view).

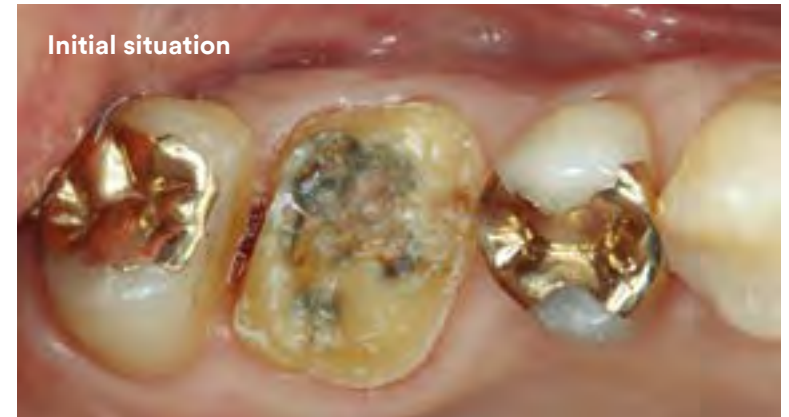Self-adhesive re-cementation of a gold crown

Clinical Case by Dr. Gunnar Reich, Germany

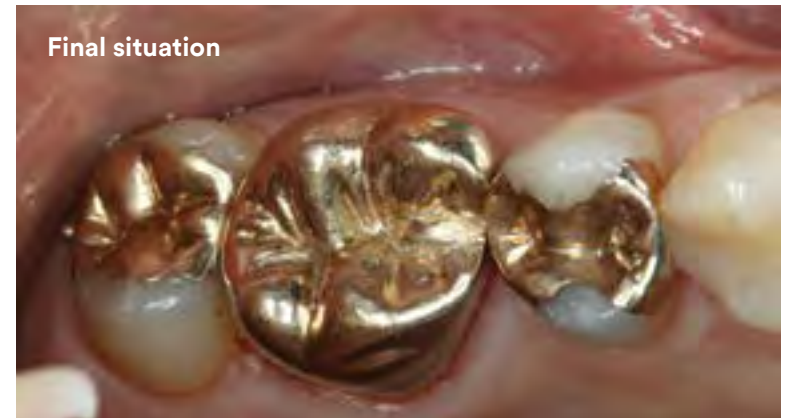A 62-year-old male patient presented with a dislodged gold crown from tooth 16. The tooth was sound with minimal secondary decay. After caries removal the preparation was cleaned and the crown was sandblasted and re-cemented with 3M™ RelyX™ Universal Resin Cement.



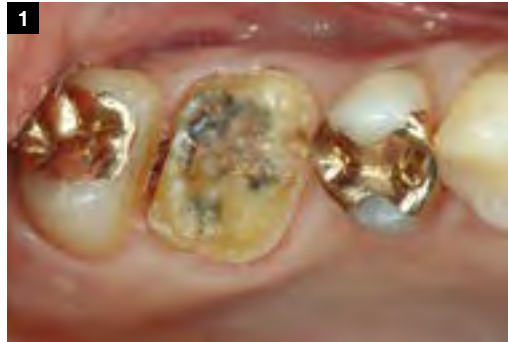Initial situation



Final situation



Self-adhesive re-cementation of a gold crown



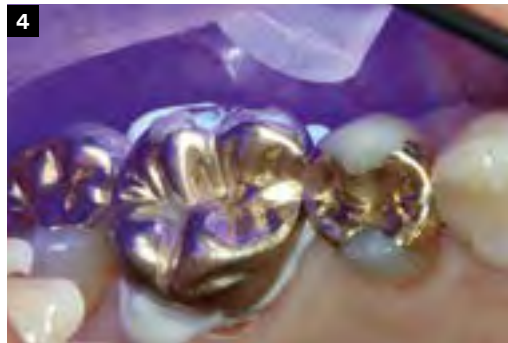Initial situation.



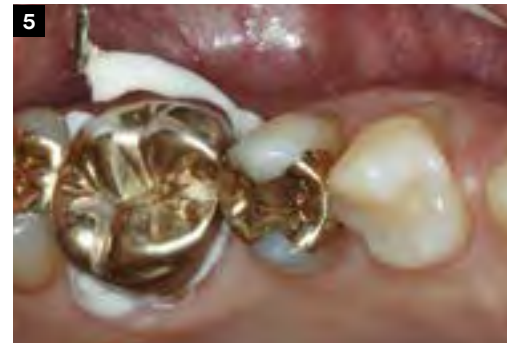Preparation.



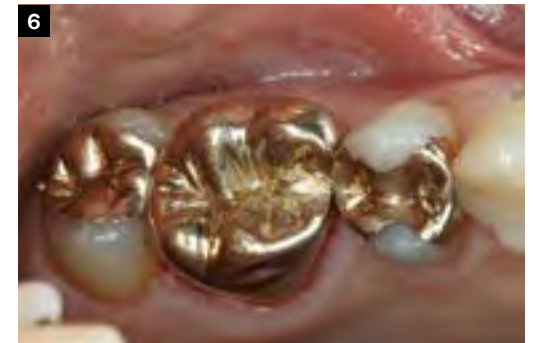Application of 3M™ RelyX™ Universal Resin Cement.



Tack-cure of excess cement.



Excess clean-up.



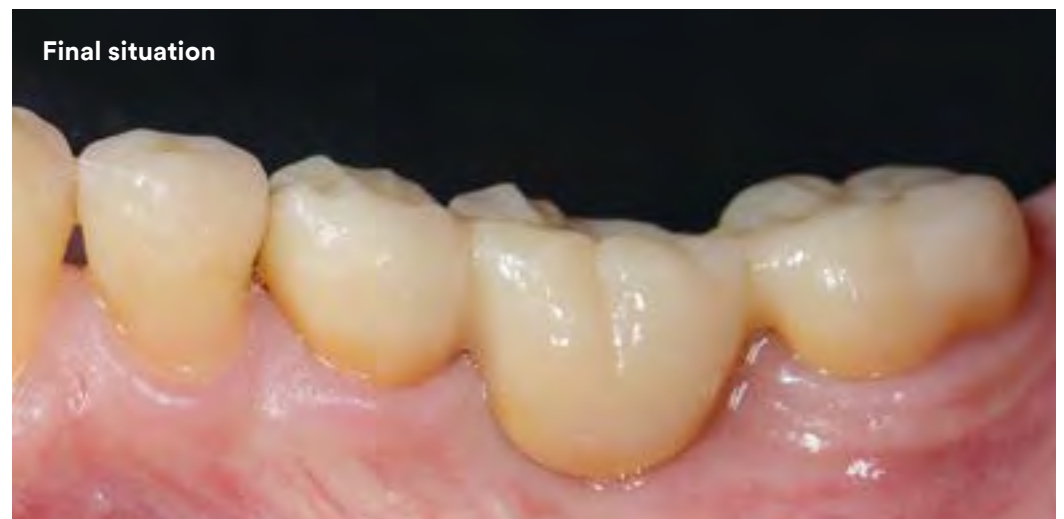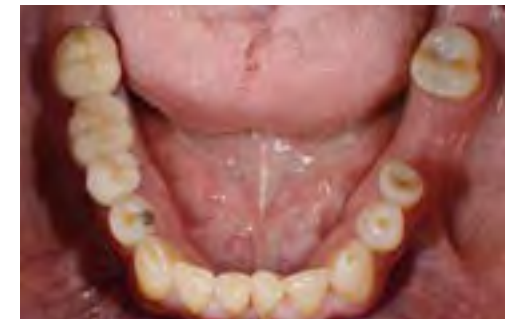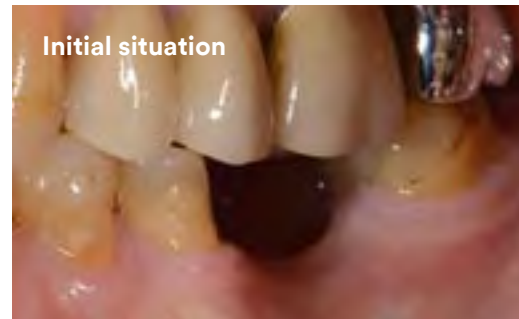Final situation.

Self-adhesive cementation of a 3-unit zirconia bridge

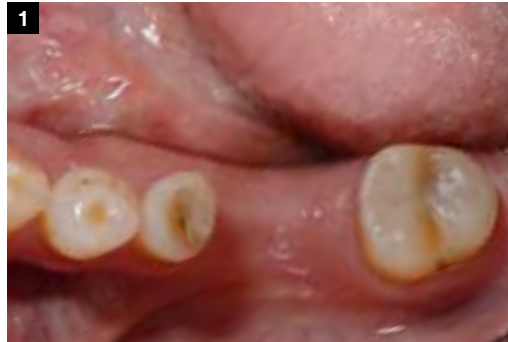Clinical Case by Prof. Dr. Jan-Frederik Gueth, Germany

A 67-year-old male patient presented with a missing tooth 36 and caries and fillings on the neighboring teeth 35 and 37. Discussion of all treatment options with the patient led to a full zirconia 3-unit FDP as the treatment plan.

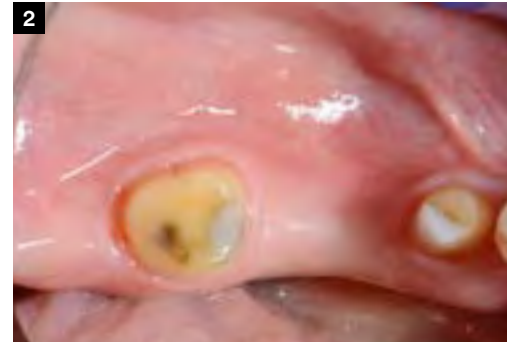After careful caries excavation and renewal of fillings, the preparation was carried out and a precision impression was taken with 3M™ Impregum™ Super Quick Polyether Impression Material. A 3M™ Lava™ Esthetic Fluorescent Full-Contour Zirconia bridge was fabricated and seated with 3M™ RelyX™ Universal Resin Cement with a self-adhesive protocol.



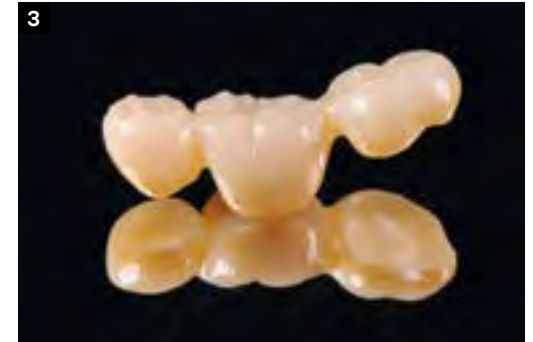Self-adhesive cementation of a 3-unit zirconia bridge



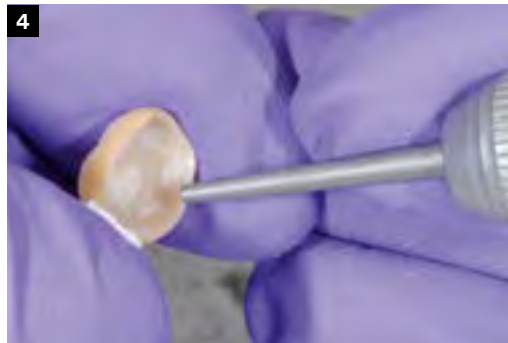
Initial situation.



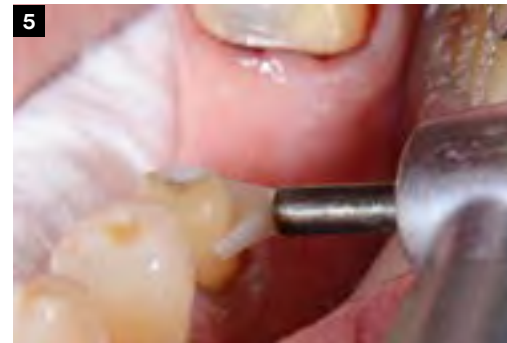Preparations.



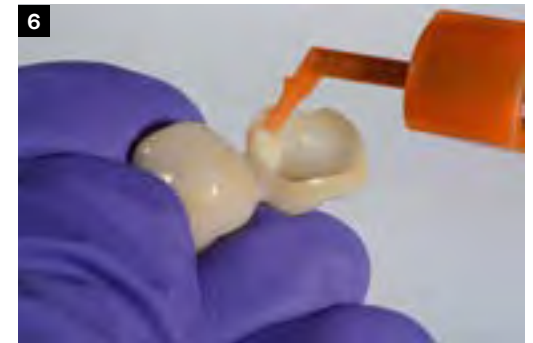3M™ Lava™ Esthetic Fluorescent Full-Contour Zirconia bridge.



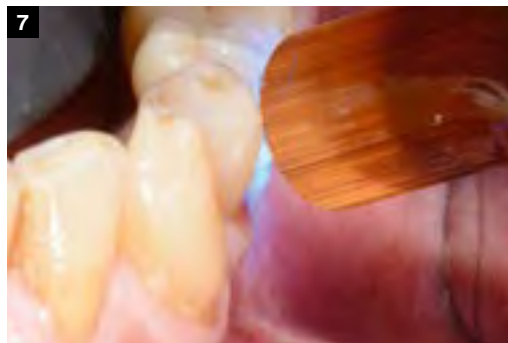Sandblasting of bonding surface.



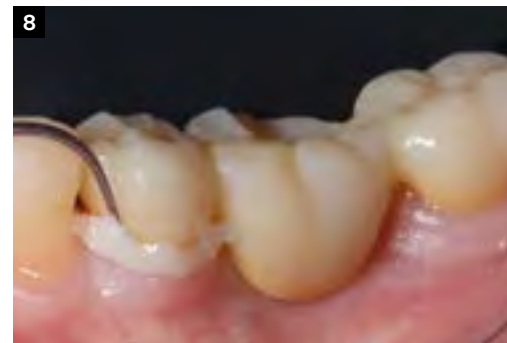Cleaning of prep with fluoride-free polishing paste.



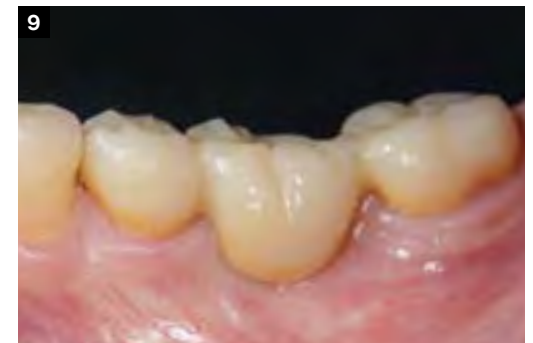Application of 3M™ RelyX™ Universal Resin Cement.



Tack-cure of excess.



Excess clean-up.



Final situation.

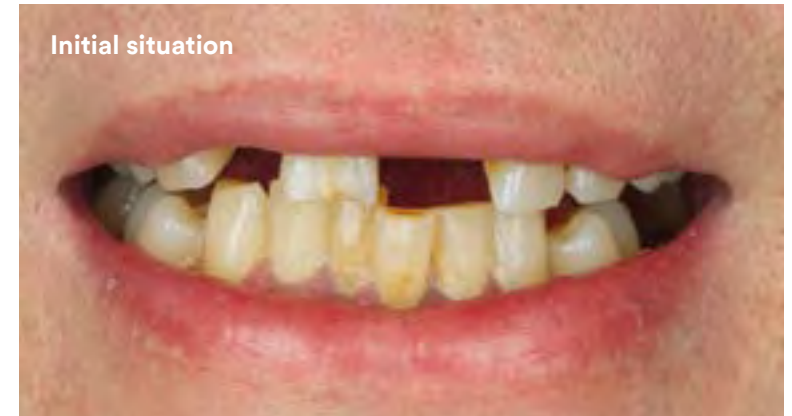Self-adhesive cementation of a 6-unit anterior zirconia bridge

Clinical Case by Dr. Andreas W. Benecke, Germany

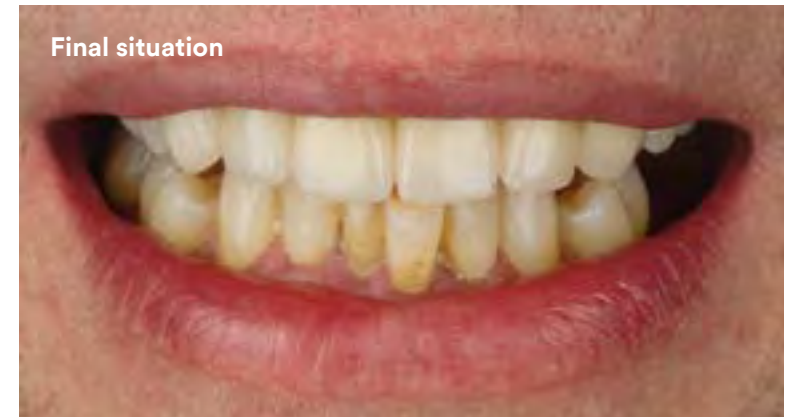This 45-year-old patient presented with several missing teeth, tooth decay and the primary wish of rehabilitation of the anterior zone. After consultation on functional, aesthetic and economical aspects a 6-unit monolithic zirconia bridge on four abutment teeth was chosen for the anterior reconstruction. In this case the optional priming of the zirconia with 3M™ Scotchbond™ Universal Plus Adhesive was done after sand-blasting. On the tooth side a self-adhesive protocol was employed with 3M™ RelyX™ Universal Resin Cement.



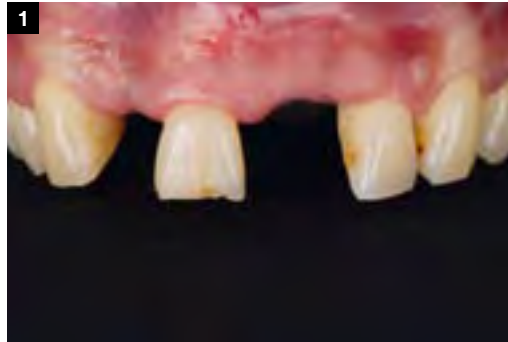Initial situation



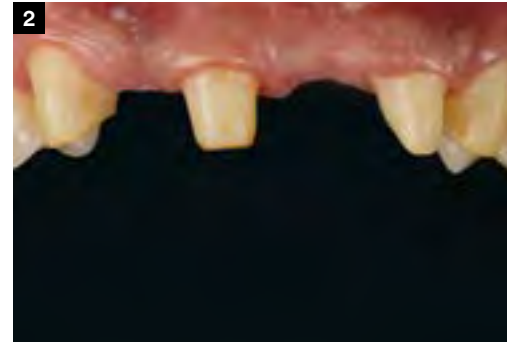Final situation



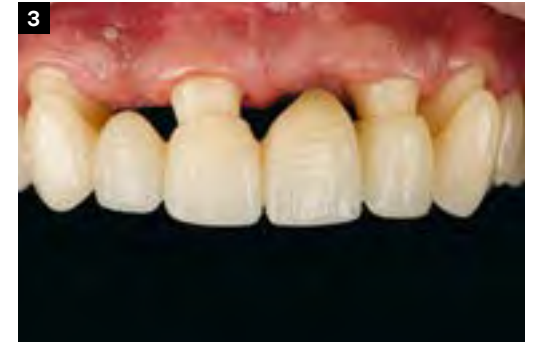Self-adhesive cementation of a 6-unit anterior zirconia bridge



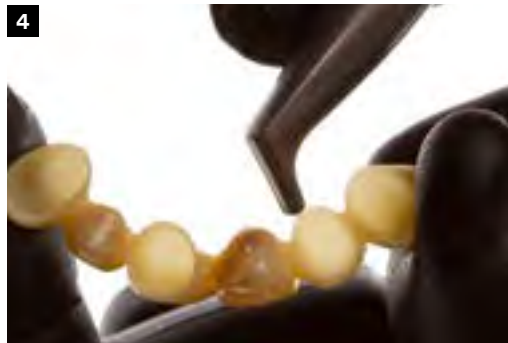1 Initial situation.



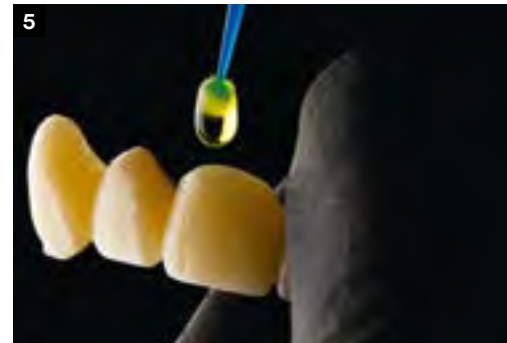2 Final preparations ready for seating.



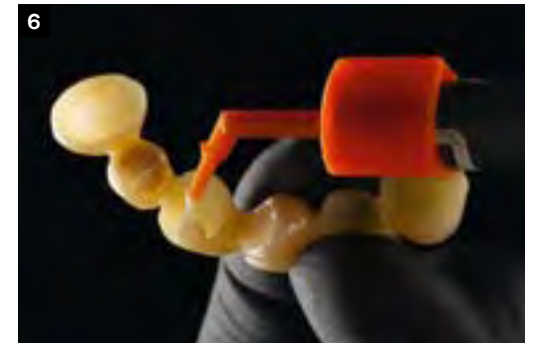
3 Try-in.



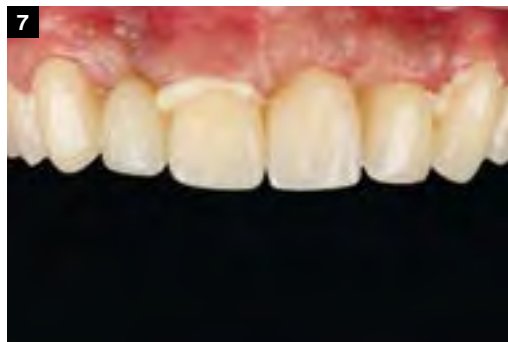4 Sandblasting pre-treatment.



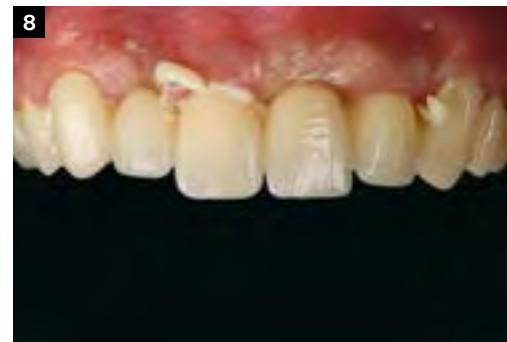5 Priming with 3M™ Scotchbond™ Universal Plus Adhesive.



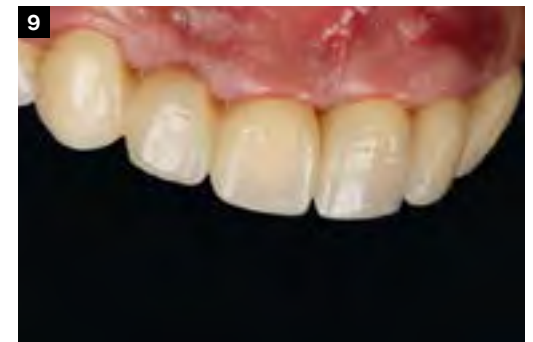6 Application of 3M™ RelyX™ Universal Resin Cement.



7 Seated zirconia bridge with cement excess.



8 Cement excess clean-up.



9 Final situation.

Clinical Case
by Dr. Andreas W. Benecke,
Germany

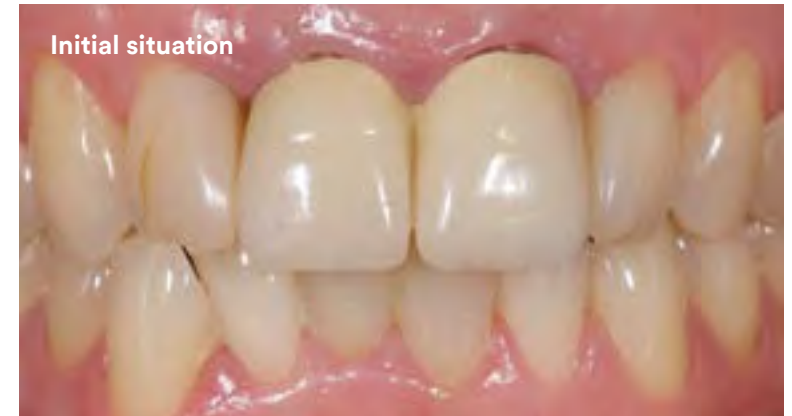Total-etch adhesive bonding of two lithium disilicate glass ceramic crowns

Clinical Case by Dr. Rafał Mędzin, Poland

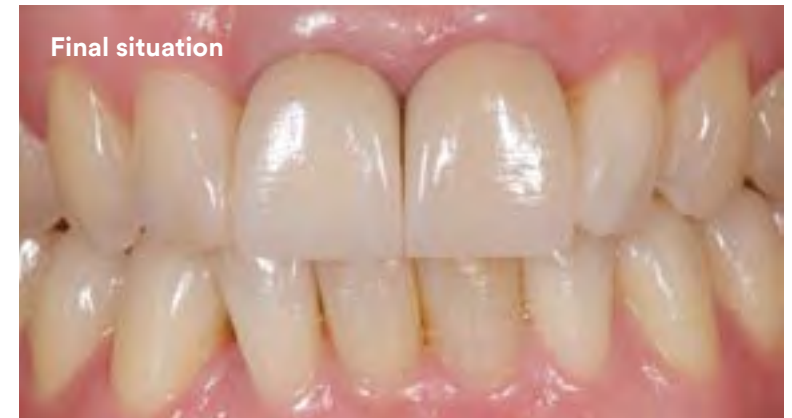A female patient was referred because of problematic central incisors restored with old PFM crowns, having insufficient endodontic treatment. Both crowns were removed and after endodontic retreatment and core build-up provisional crowns made of 3M™ Protemp™ 4 Temporization Material were placed. The patient paused the treatment and returned after eight years with the same Protemp 4 crowns. The case was finished with lithium disilicate glass ceramic crowns, cemented with 3M™ RelyX™ Universal Resin Cement and 3M™ Scotchbond™ Universal Plus Adhesive in the total-etch technique.



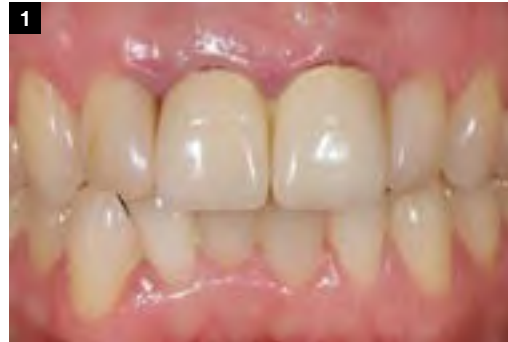Initial situation



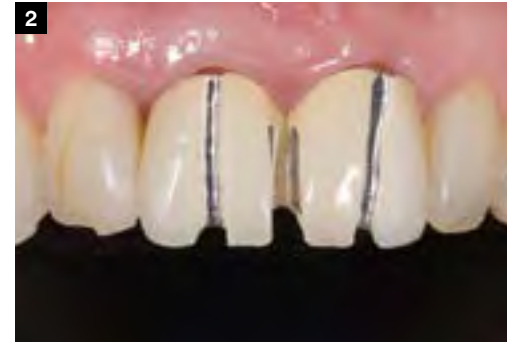Final situation



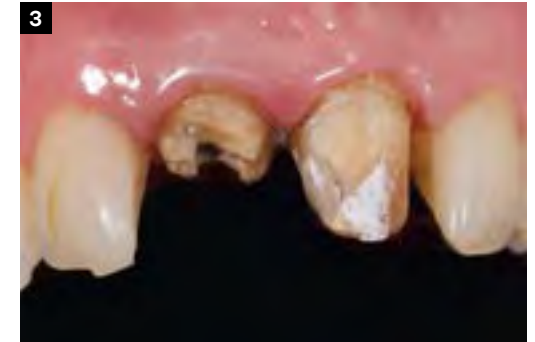Total-etch adhesive bonding of two lithium disilicate glass ceramic crowns



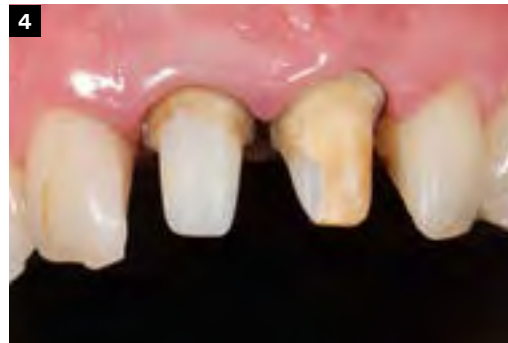Initial situation.



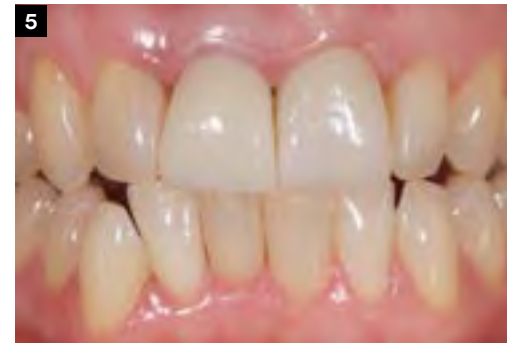Removal of PFM restorations.



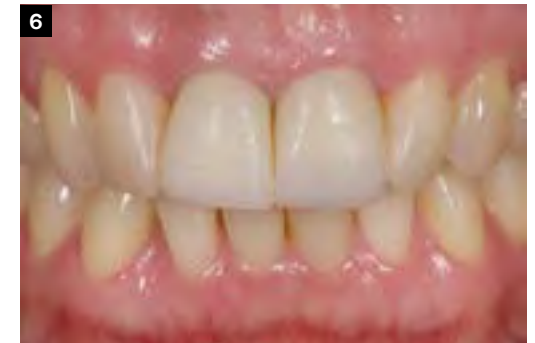Stumps after removal of build-up.



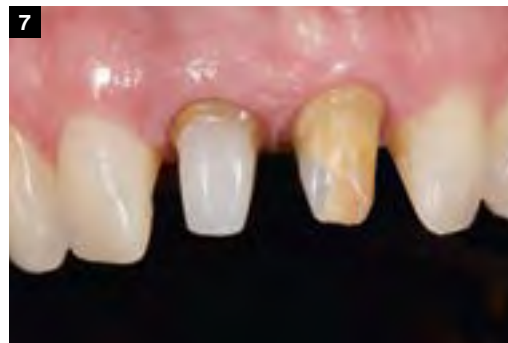Final preparations with new core build-up.



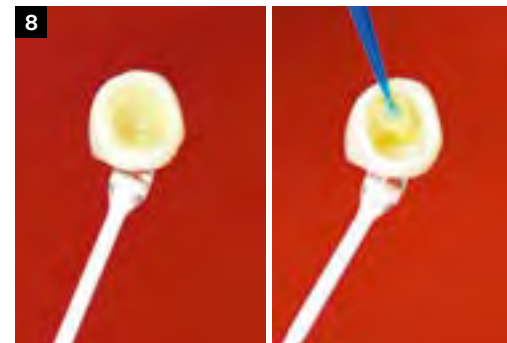
Temporary crowns made of 3M™ Protemp™ 4 Temporization Material.



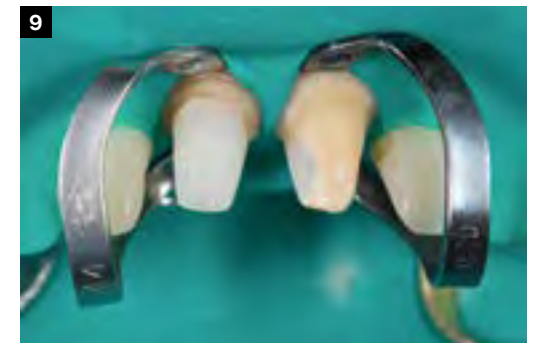Provisional crowns made of 3M™ Protemp™ 4 Temporization Material after eight years in situ.



Provisionals removed.



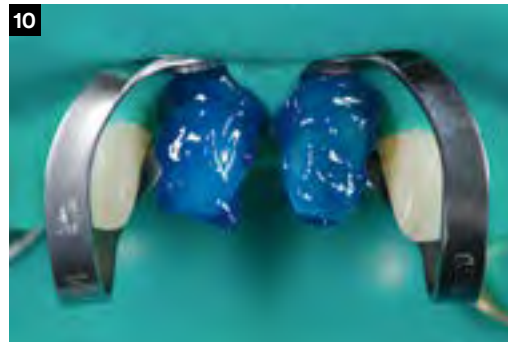HF etching of bonding surface, priming with 3M™ Scotchbond™ Universal Plus Adhesive.



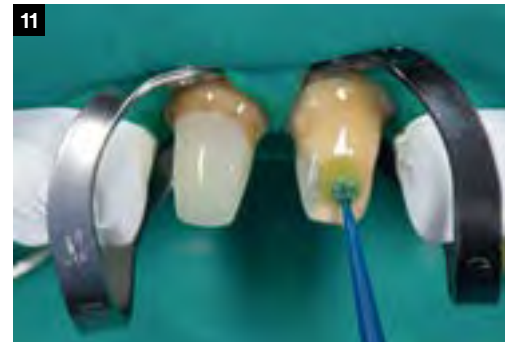Preps ready for pre-treatment.

Clinical Case
by Dr. Rafał Mędzin,
Poland

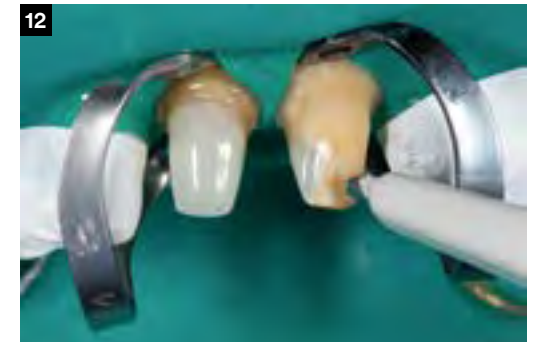Total-etch adhesive bonding of two lithium disilicate glass ceramic crowns



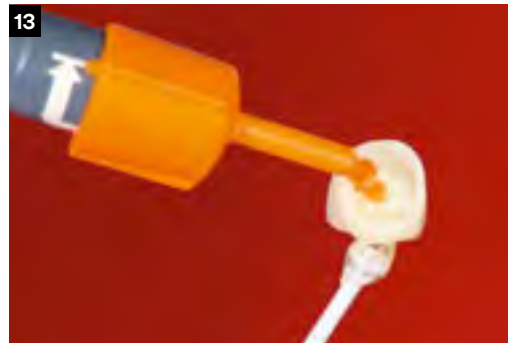10 Total-etch technique.



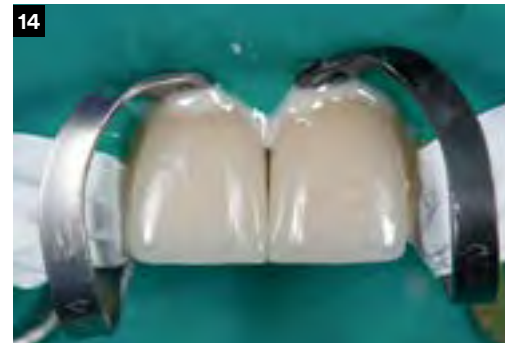11 Application of 3M™ Scotchbond™ Universal Plus Adhesive.



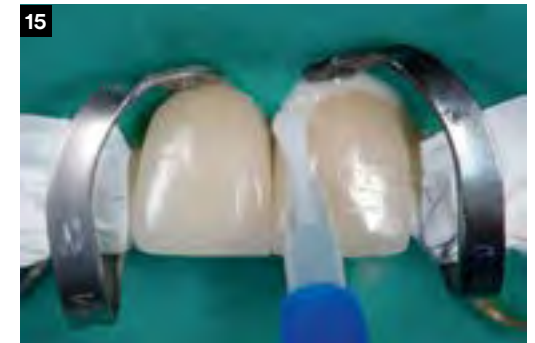12 Air-drying of 3M™ Scotchbond™ Universal Plus Adhesive.



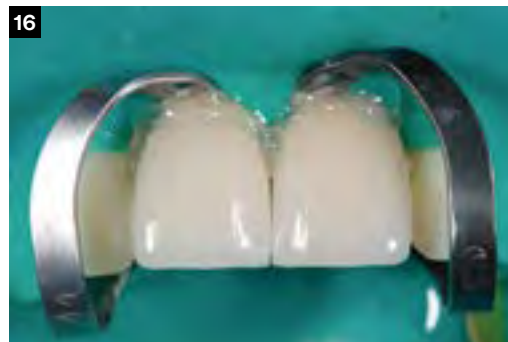13 Application of 3M™ RelyX™ Universal Resin Cement.



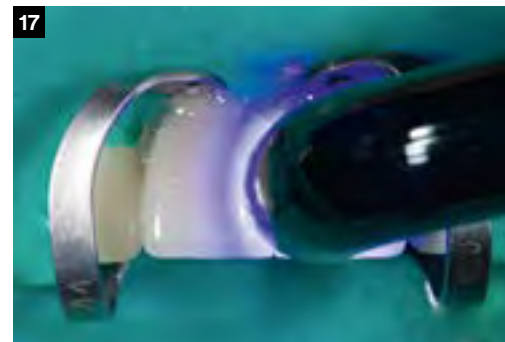
14 Seated crowns.



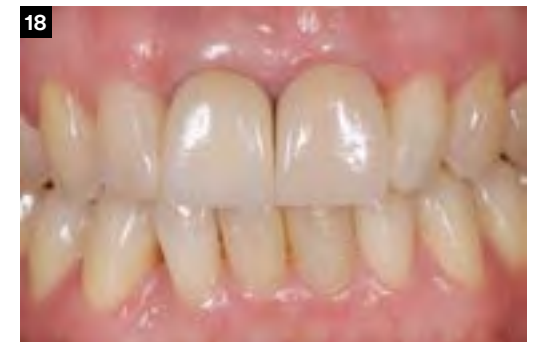15 Excess clean-up with brush.



16 Covering of margins with glycerin gel.



17 Final light-cure.



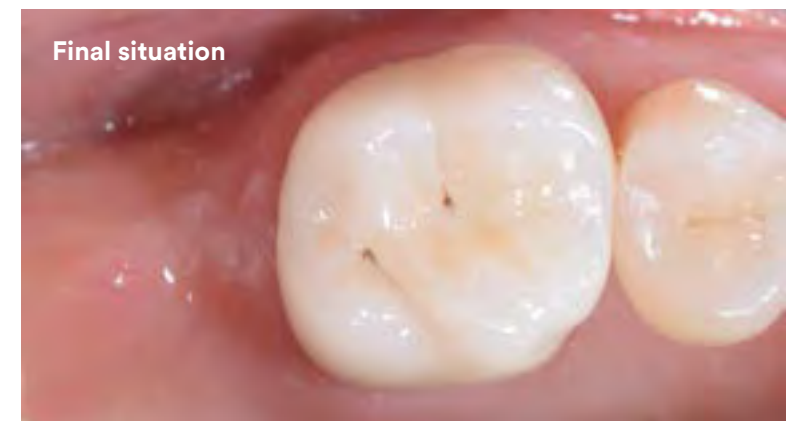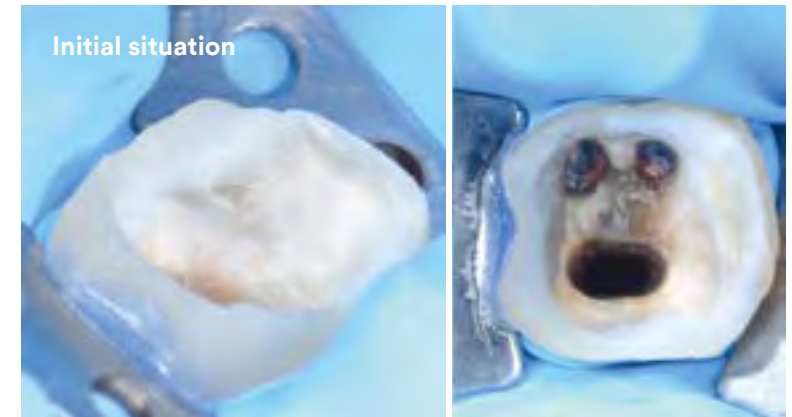
18 Final situation.

Clinical Case
by Dr. Rafał Mędzin,
Poland

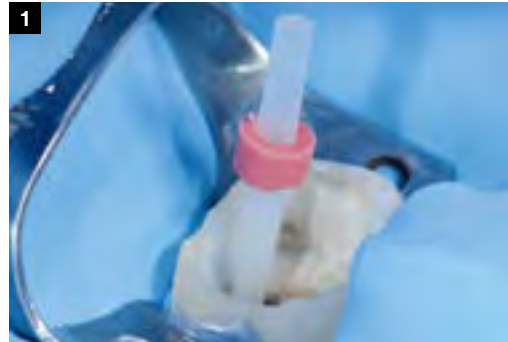Self-adhesive post cementation, adhesive core build-up and self-adhesive crown cementation

Clinical Case by Dr. Giuseppe Chiodera, Italy

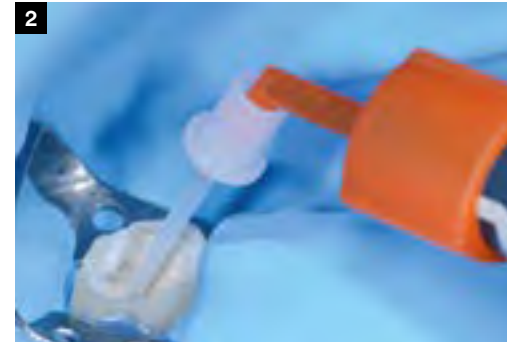An endodontically treated molar of a 45-year-old male patient was restored with a fibre post core build-up and a monolithic zirconia crown. 3M™ RelyX™ Universal Resin Cement was used for the self-adhesive placement of both the post and the final crown. 3M™ Scotchbond™ Universal Plus Adhesive and 3M™ Filtek™ One Bulk Fill Restorative were used for the core build-up.



Self-adhesive post cementation, adhesive core build-up and self-adhesive crown cementation



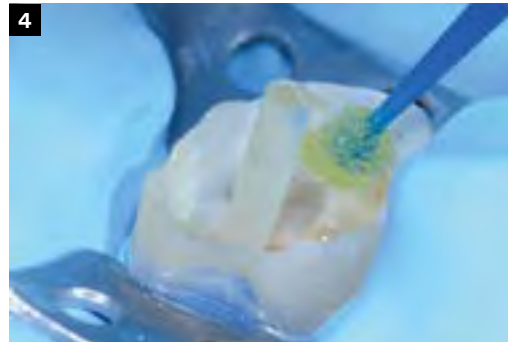1 Trial fitting of post for length assessment.



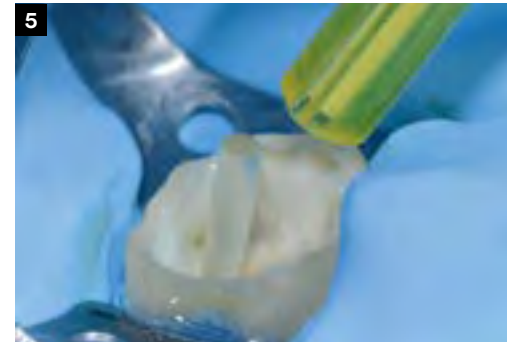2 Application of 3M™ RelyX™ Universal Resin Cement to the root canal with elongation tip.



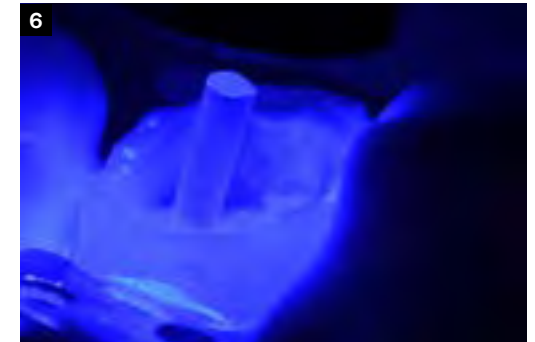3 Light-cure after seating of the post and cement excess clean-up.



4 Application of 3M™ Scotchbond™ Universal Plus Adhesive for core build-up.



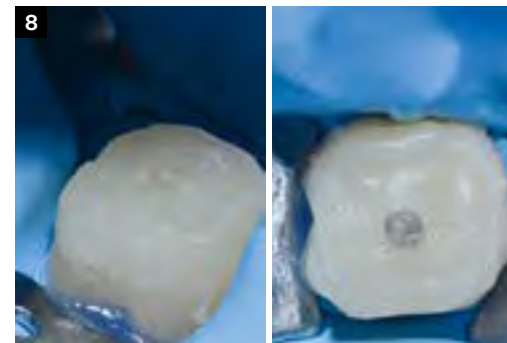
5 Air drying of 3M™ Scotchbond™ Universal Plus Adhesive.



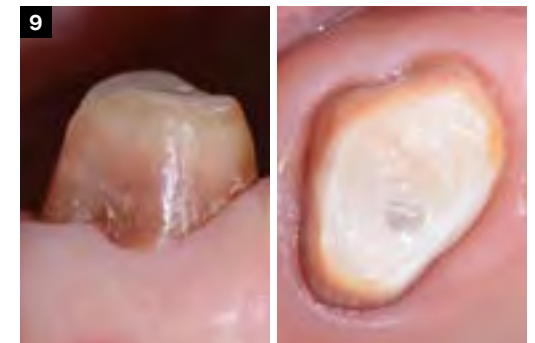6 Light cure of 3M™ Scotchbond™ Universal Plus Adhesive.



7 Application of 3M™ Filtek™ One Bulk Fill Restorative.



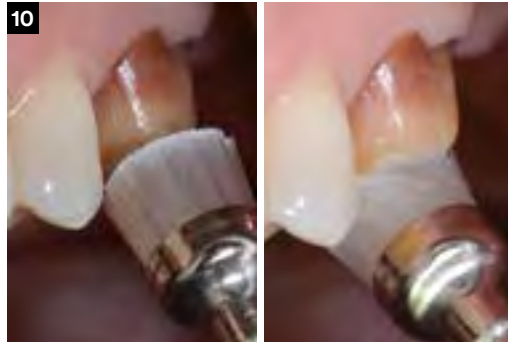8 Core build-up after light-cure.



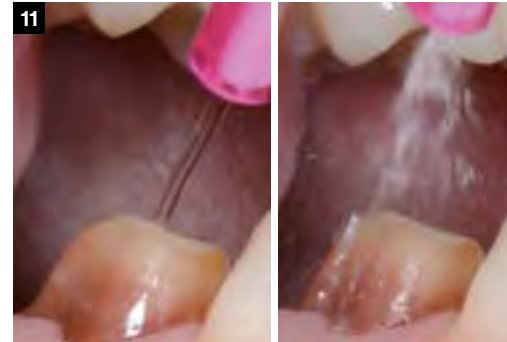9 Final preparation.

Clinical Case
by Dr. Giuseppe Chiodera,
Italy

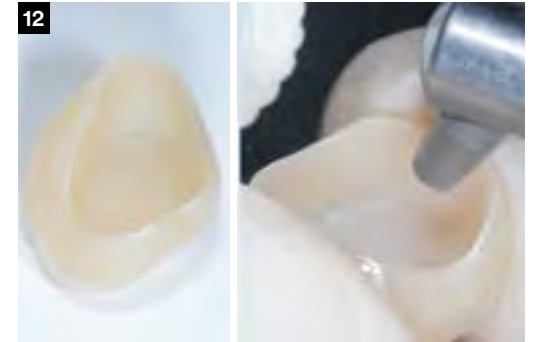Self-adhesive post cementation, adhesive core build-up and self-adhesive crown cementation



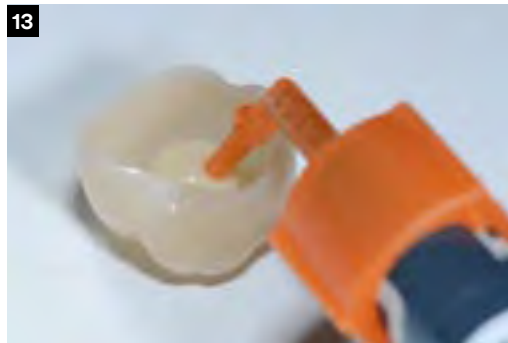10 Cleaning of preparation at final seating appointment.



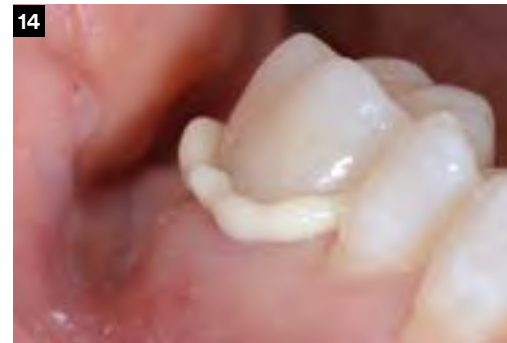11 Rinsing and air-drying of preparation.



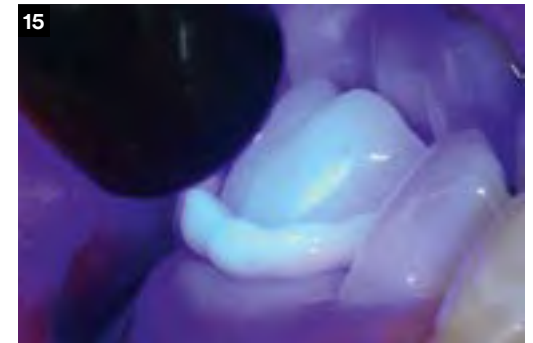12 Sandblasting of zirconia crown bond surface.



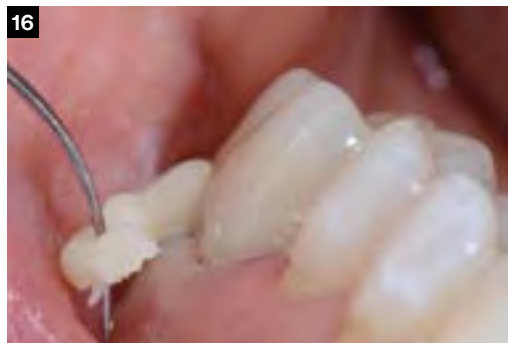13 Application of 3M™ RelyX™ Universal Resin Cement.



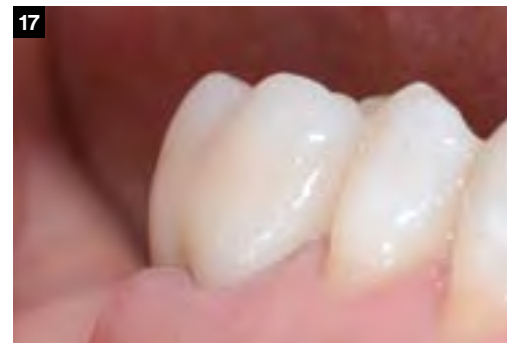14 Seated crown with excess outflow.



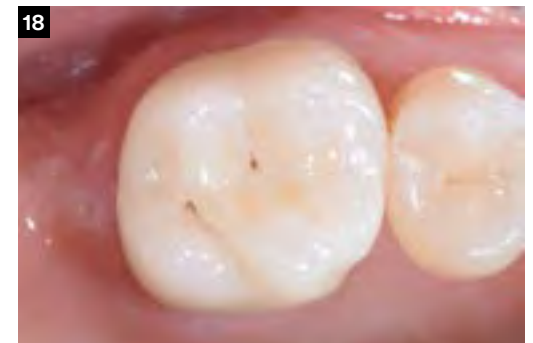15 Tack-cure of cement excess.



16 Excess clean-up with probe.



17 Final situation (buccal view).



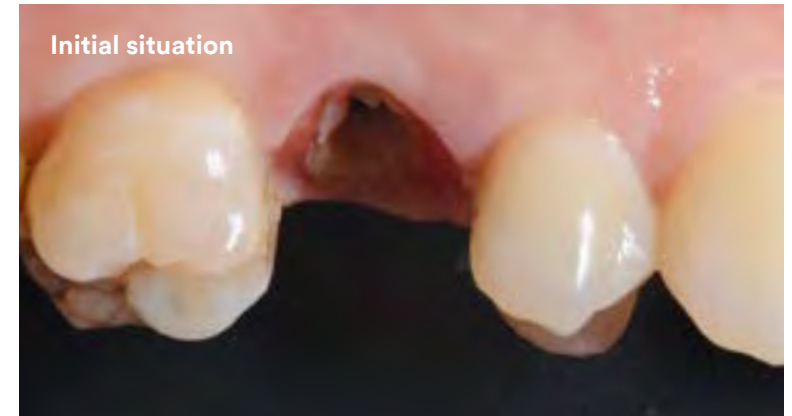18 Final situation (occlusal view).

Post reinforced core build-up of a magnetic extruded root topped with a self-adhesive cemented zirconia crown

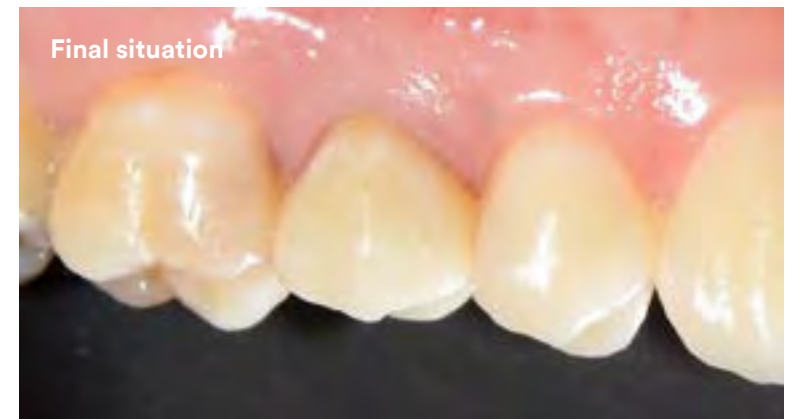Clinical Case by Prof. Dr. Jan-Frederik Gueth, Germany

The 47-year-old female patient presented with a heavily destroyed tooth 15 and the strong wish to keep the tooth by any means. Key step of the planned approach was the magnetic extrusion of the root after root canal treatment. After core build-up with a post, a full-contour zirconia crown was placed. 3M™ RelyX™ Universal Resin Cement was used for self-adhesive cementation of both the 3M™ RelyX™ Fiber Post 3D and the 3M™ Lava™ Esthetic Full-Contour Zirconia Crown. 3M™ Scotchbond™ Universal Plus Adhesive and 3M™ Filtek™ One Bulk Fill Restorative were employed for the core build-up.

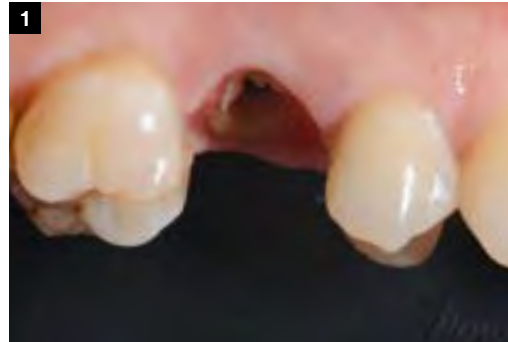Initial situation



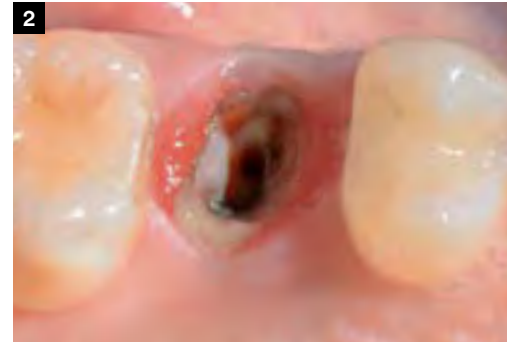Final situation



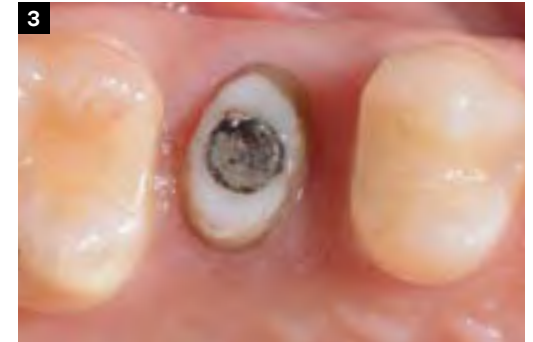Post reinforced core build-up of a magnetic extruded root topped with a self-adhesive cemented zirconia crown



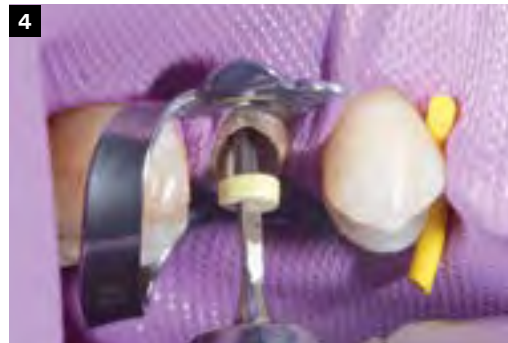Initial situation.



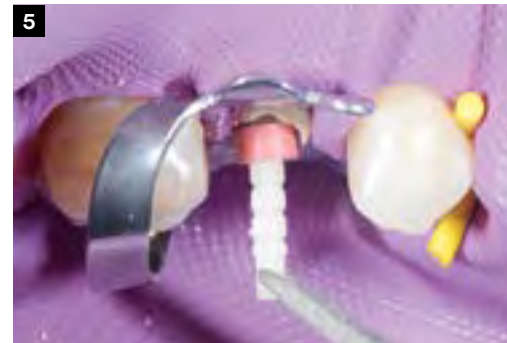Initial situation, occlusal view.



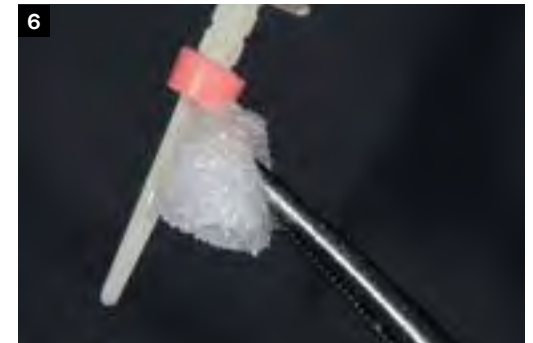Situation after endodontic treatment and three weeks of extrusion by magnets fixed on the root and on a splint.



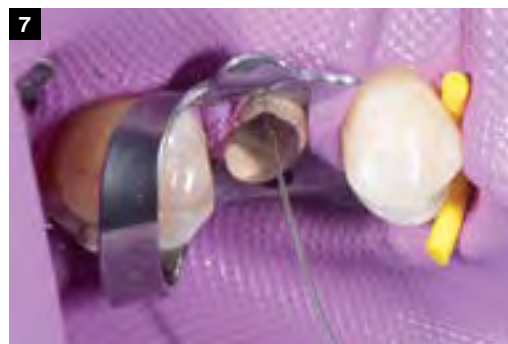Preparation of the root canal.



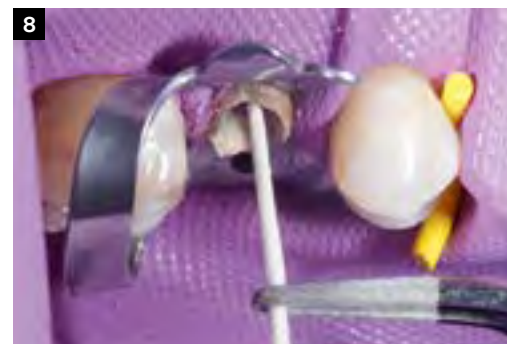Try-in of the 3M™ RelyX™ Fiber Post 3D for length determination.



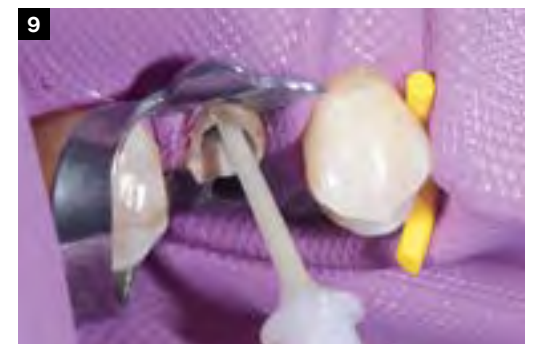Cleaning of the 3M™ RelyX™ Fiber Post 3D with alcohol after length adjustment.



Rinsing.

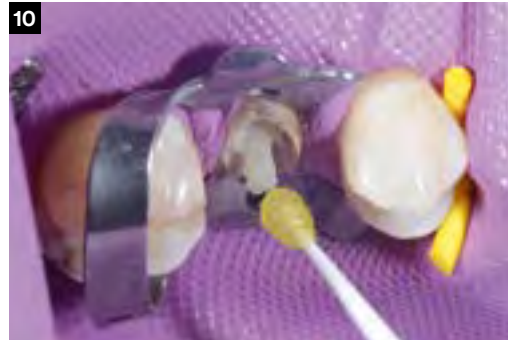

Drying with paper tips.



Application of 3M™ RelyX™ Universal Resin Cement with elongation tip.

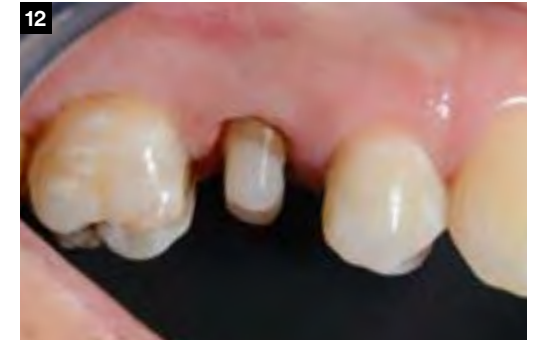Post reinforced core build-up of a magnetic extruded root topped with a self-adhesive cemented zirconia crown



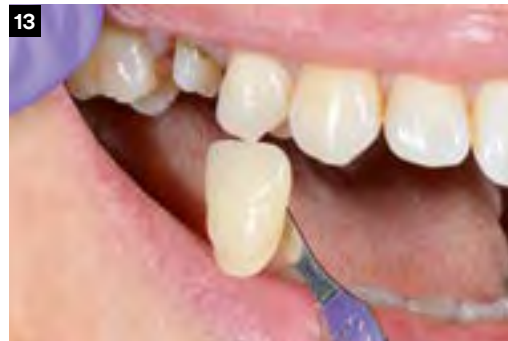10 After post placement: Application of 3M™ Scotchbond™ Universal Plus Adhesive for core build-up followed by light-curing.



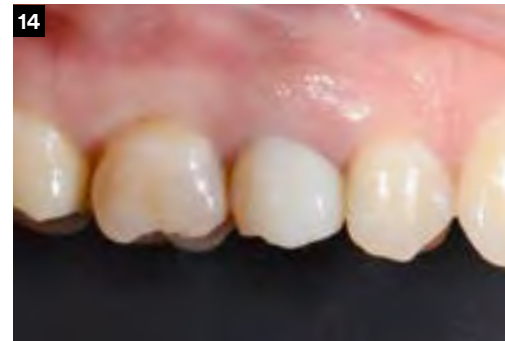11 Light-cure of 3M™ Filtek™ One Bulk Fill Restorative core build-up.



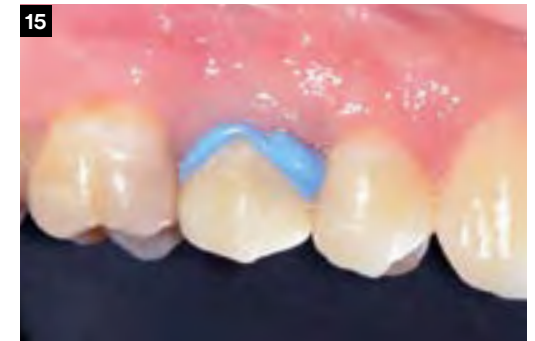12 Preparation.



13 Shade determination.



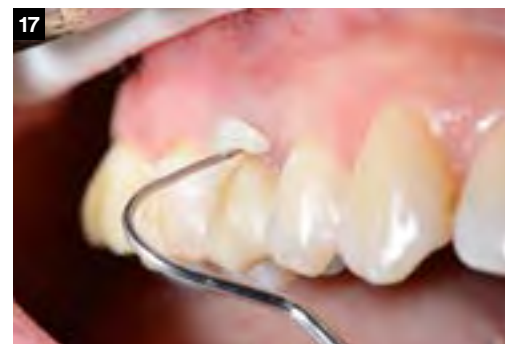14 Provisional restoration in place.



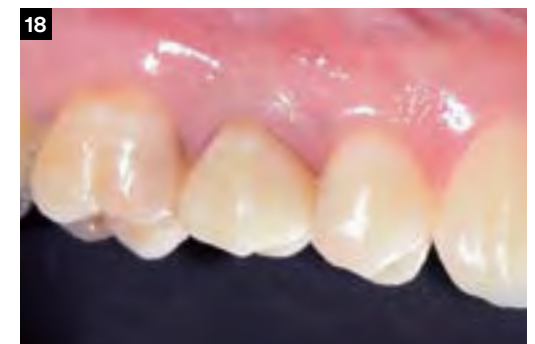15 Try-in of 3M™ Lava™ Esthetic Fluorescent Full-Contour Zirconia Crown.



16 Sandblasting of the 3M™ Lava™ Esthetic Fluorescent Full-Contour Zirconia Crown.



17 Excess clean-up of 3M™ RelyX™ Universal Resin Cement after tack-curing.



18 Final situation.

Clinical Case
by Prof. Dr. Jan-Frederik Gueth,
Germany

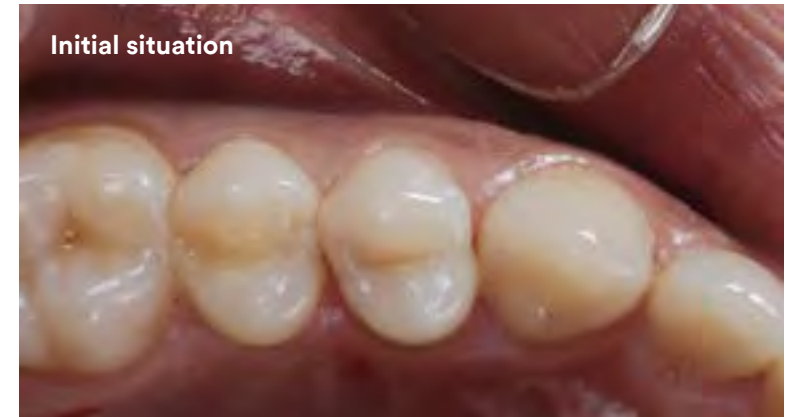Class II filling on upper first pre-molar

Clinical Case by Prof. Dr. Alberto Ferreiroa, Spain

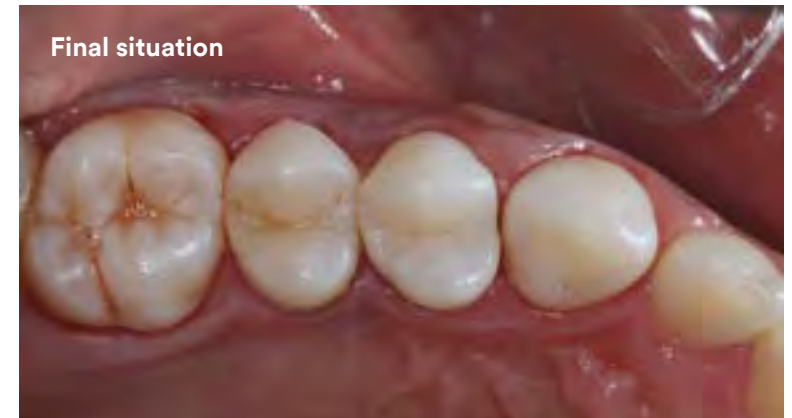Patient came with light pain on the left upper side, the clinical evaluation showed the presence of a caries on distal side of the left first upper premolar which was confirmed by the periapical X-ray. The treatment plan consisted on a class II, OD (occluso-distal) restoration using 3M™ Scotchbond™ Universal Plus Adhesive and 3M™ Filtek™ Universal Restorative, shade A2. After total isolation with a rubber dam, the caries was removed, all the procedures related to the adhesive were made and the composite material was placed and polished using 3M™ Sof-Lex™ Polishing System.



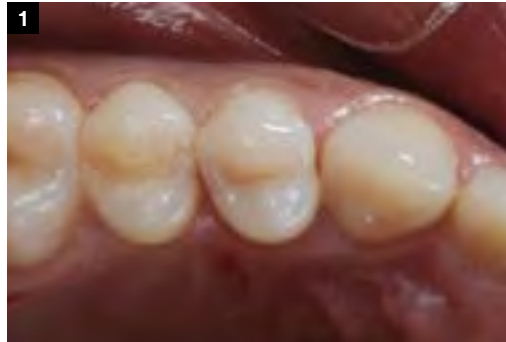Initial situation



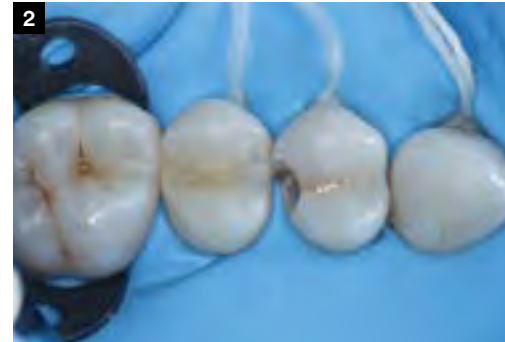Final situation



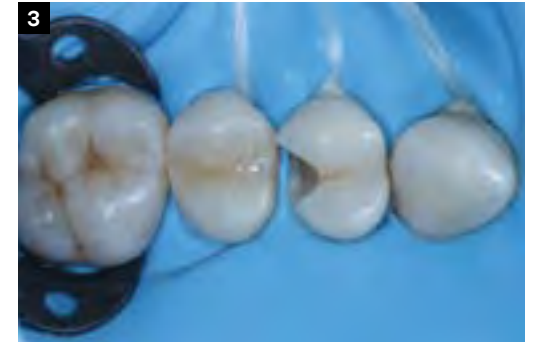Class II filling on upper first pre-molar



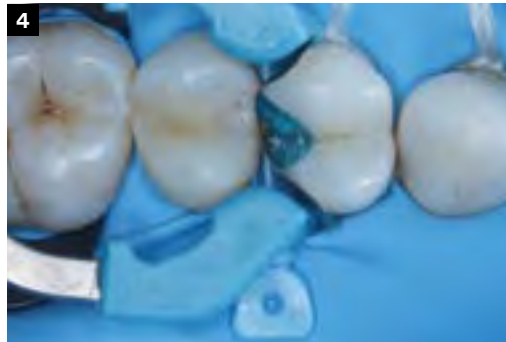Initial situation.



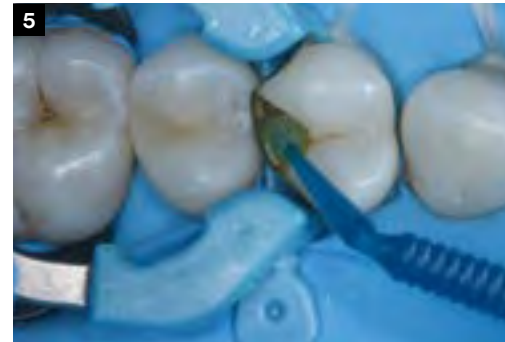Access to caries lesion.



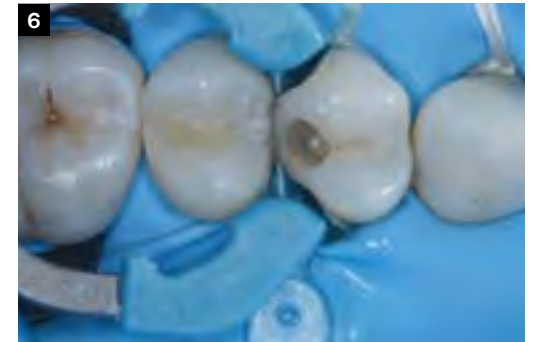After excavation.



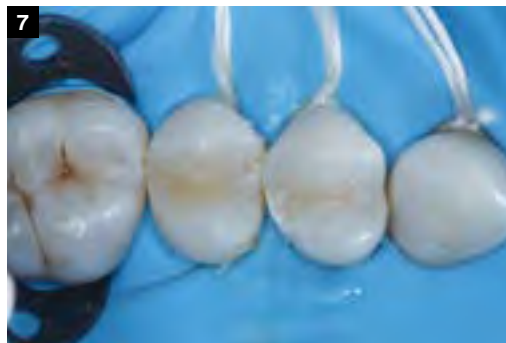Selective enamel etching.



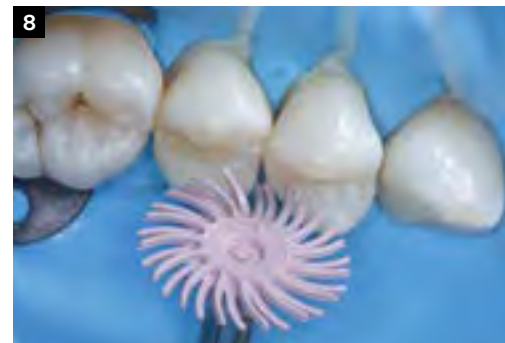Application of 3M™ Scotchbond™ Universal Plus Adhesive followed by light-curing for 10 sec.



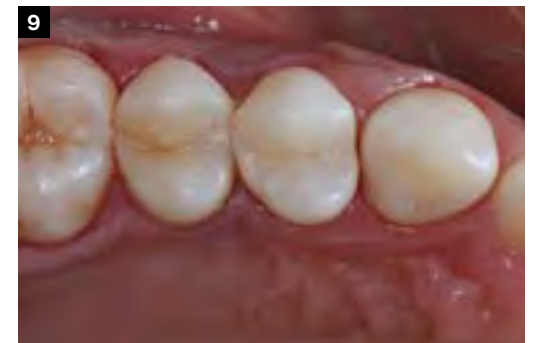Build-up of distal ridge with 3M™ Filtek™ Universal Restorative.



Filling completed.



Polishing with 3M™ Sof-Lex™ Spiral Wheels.



Final situation.

For more information,
3M.co.uk/Dental

For complete product information and correct product usage
please follow all manufacturer instructions for use.

3M United Kingdom PLC
3M Oral Care
Charnwood Campus
10 Bakewell Road
Loughborough
Leicestershire, LE11 5RB
+0800 626 578

3M Ireland Ltd
The Iveagh Building
Carrickmines Park
Carrickmines Dublin 18
Ireland
+353 1 280 3555

3M, Elipar, Filtek, Impregum, Lava, Protemp, RelyX,
Scotchbond and Sof-Lex are trademarks of 3M Company
or 3M Deutschland GmbH. Straumann, n!ce and e.max
are trademarks of the Straumann company. © 3M 2020.
All rights reserved. 17422317_UK20200916

