

Case Study: 3M™ Clarity™ Aligners

Phase 1: End on Class II mixed dentition with narrow arches and anterior crossbite.

Age: 10

Total number of aligners: 65 (dual arch)

Wear interval: Weekly - 5 days

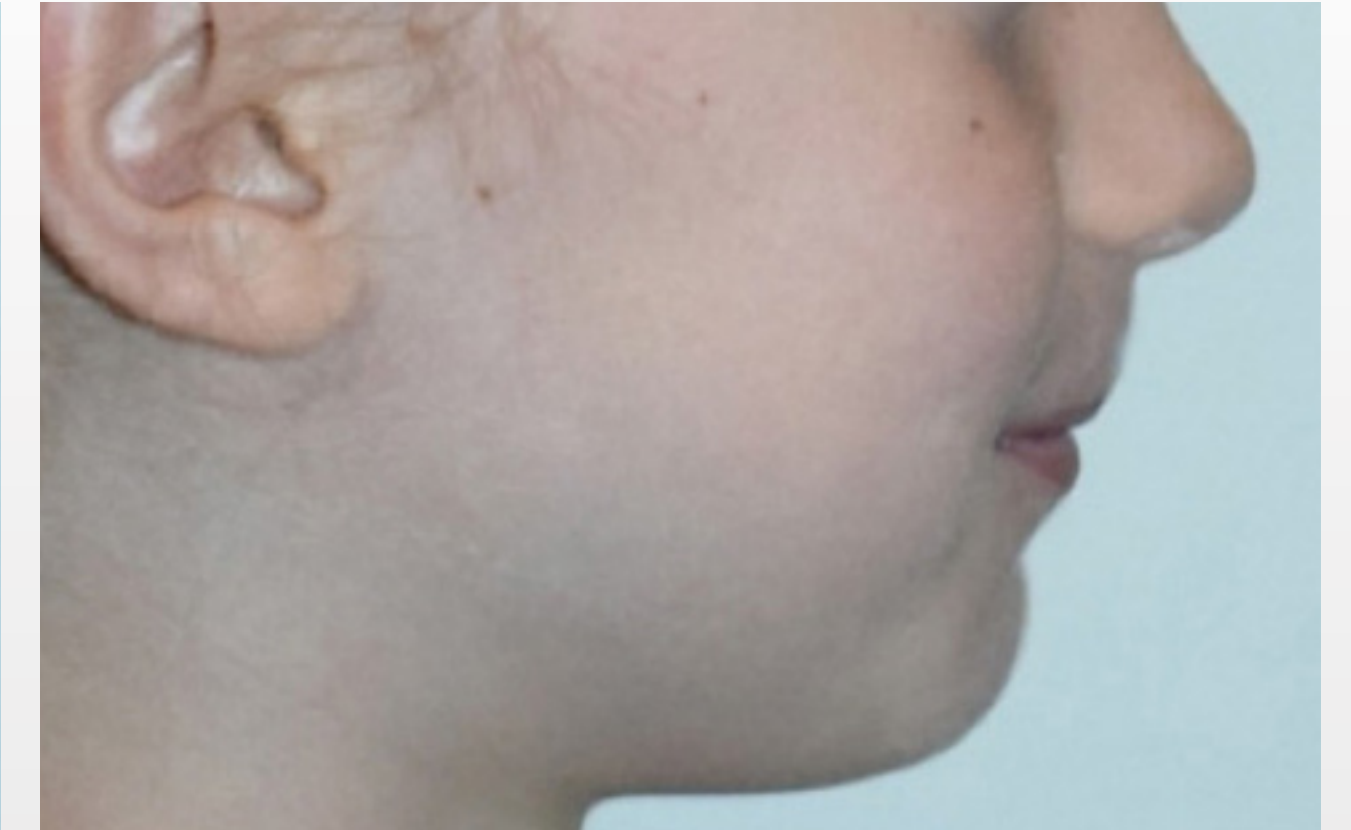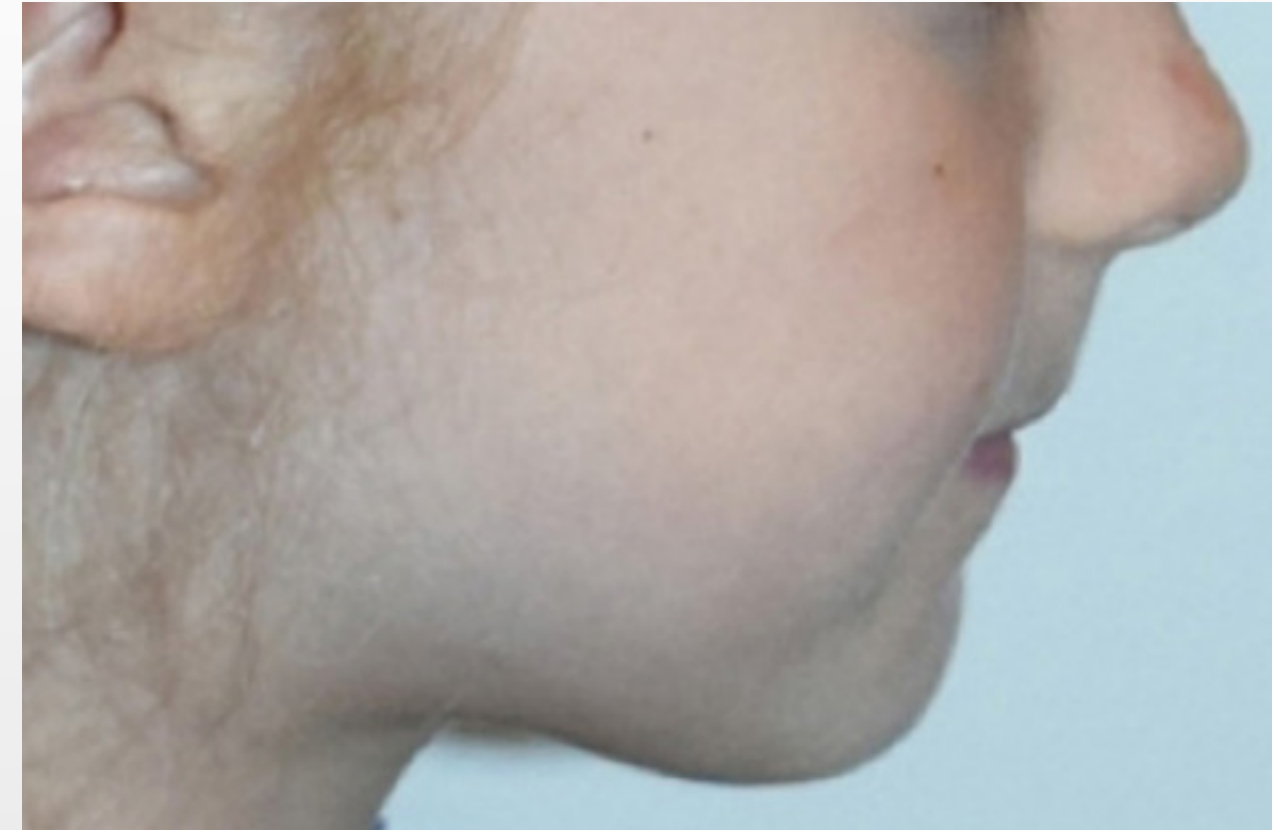Treatment time: Phase 1 = 12 months

Case courtesy of:
Dr. Lisa Davison
Powell, OH – USA

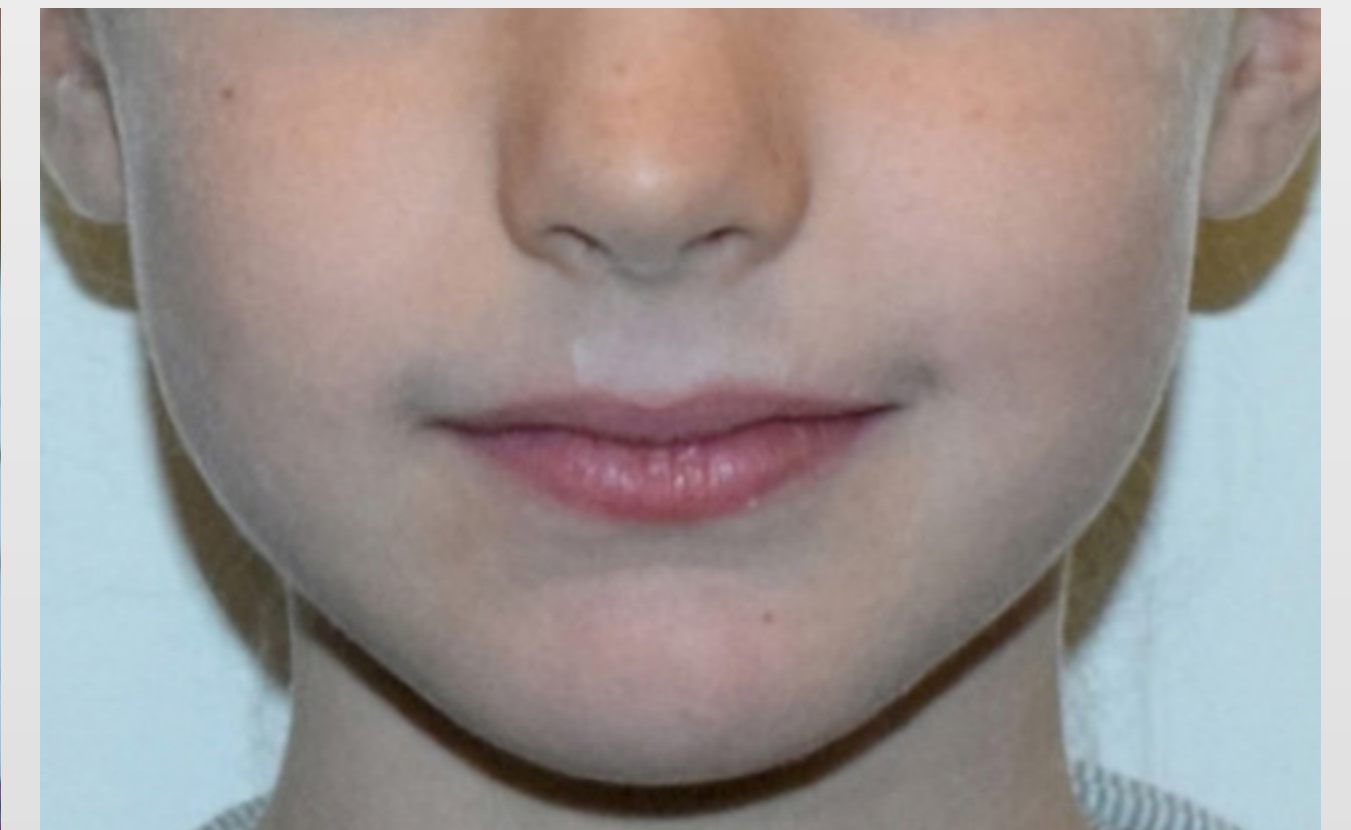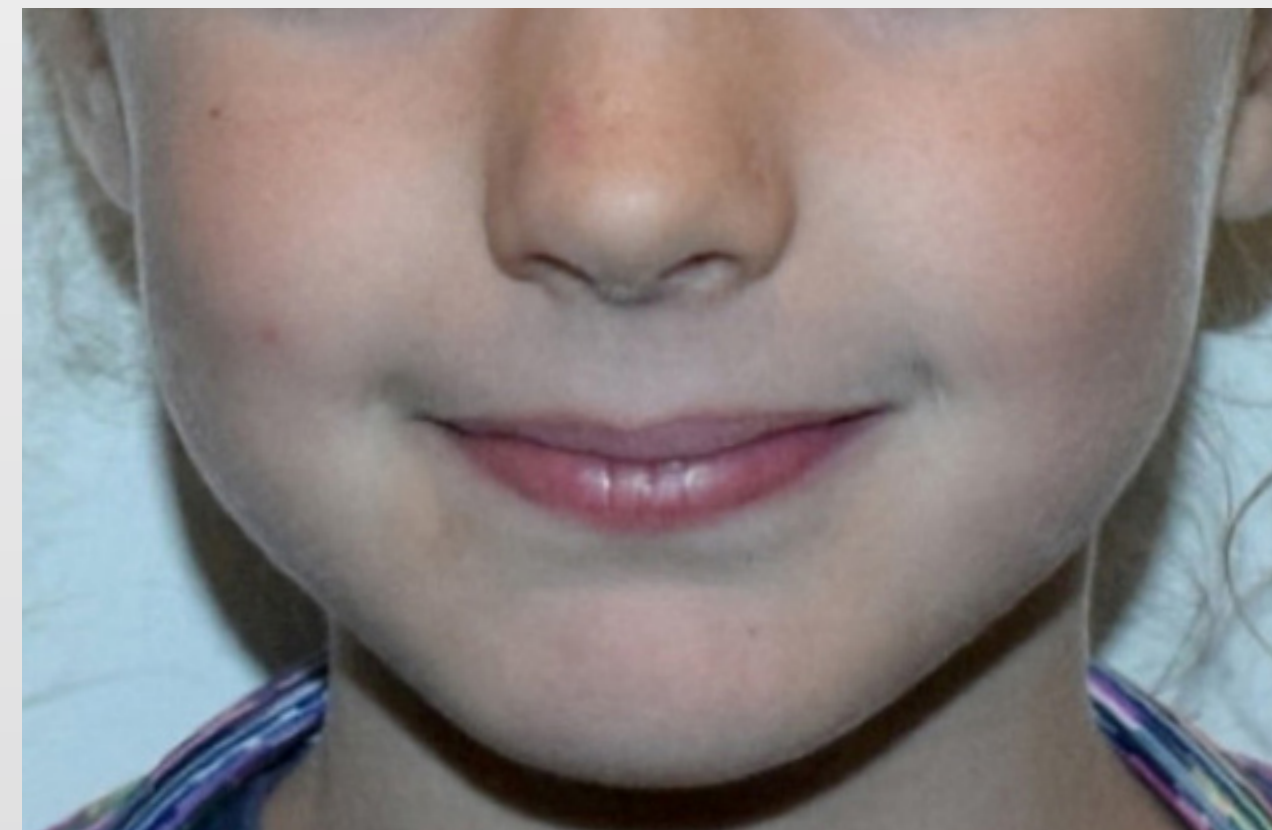Initial

Final

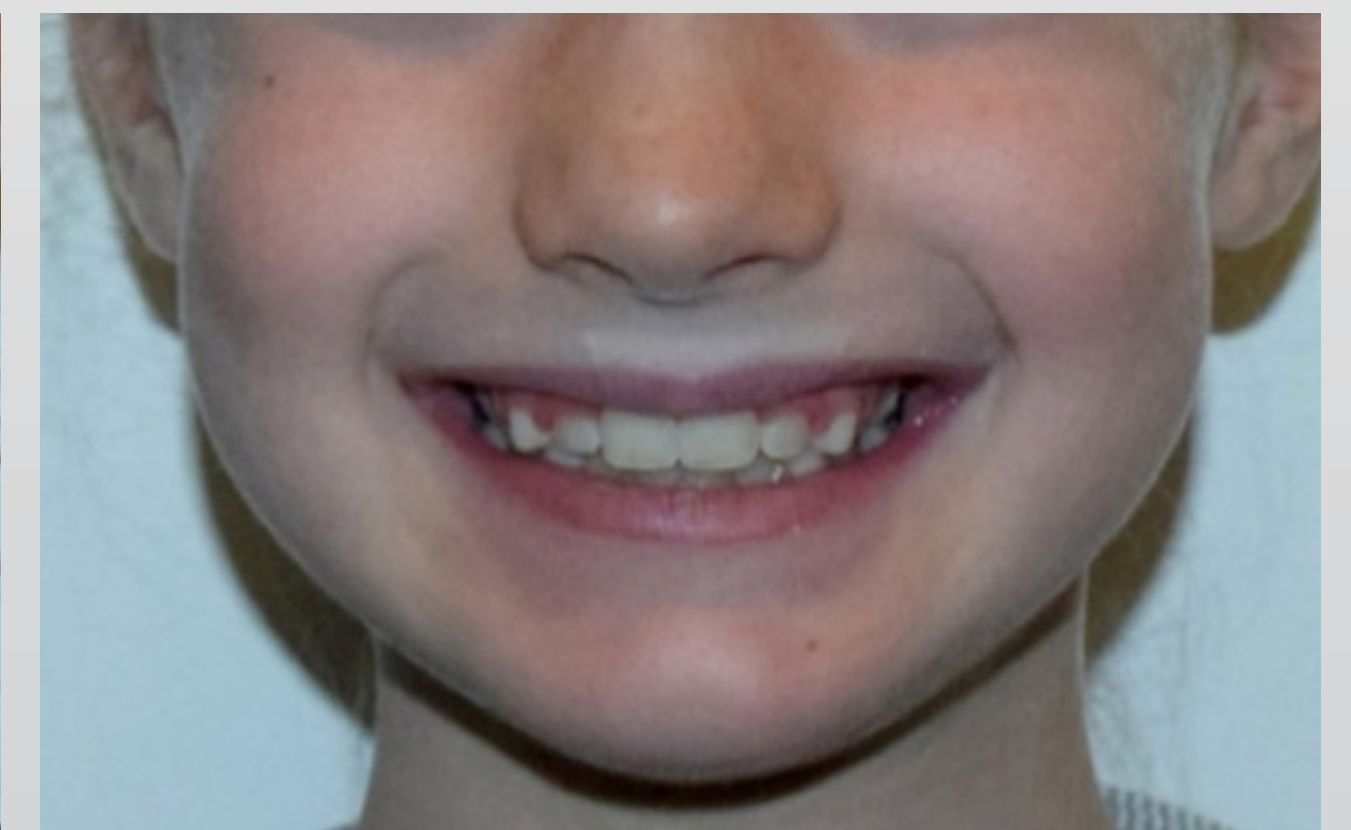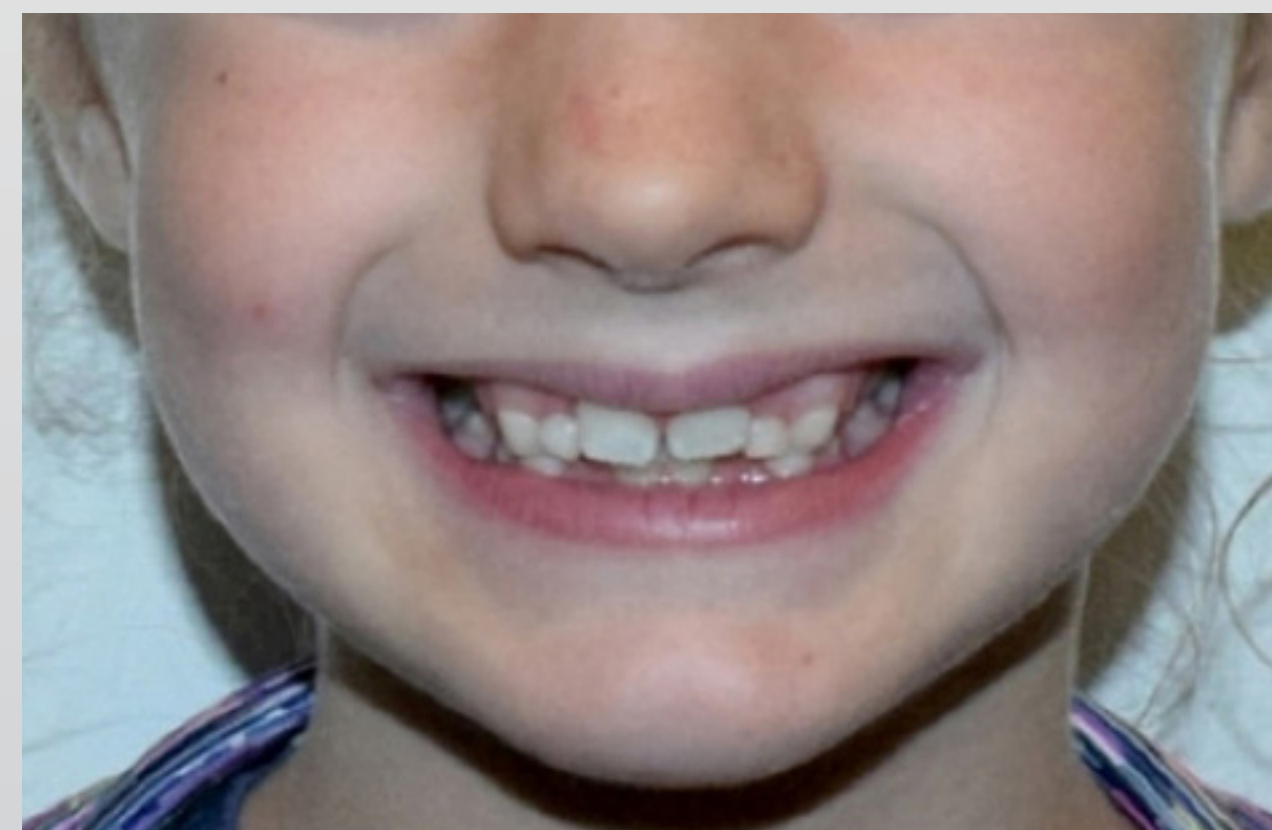Profile at rest



Face at rest



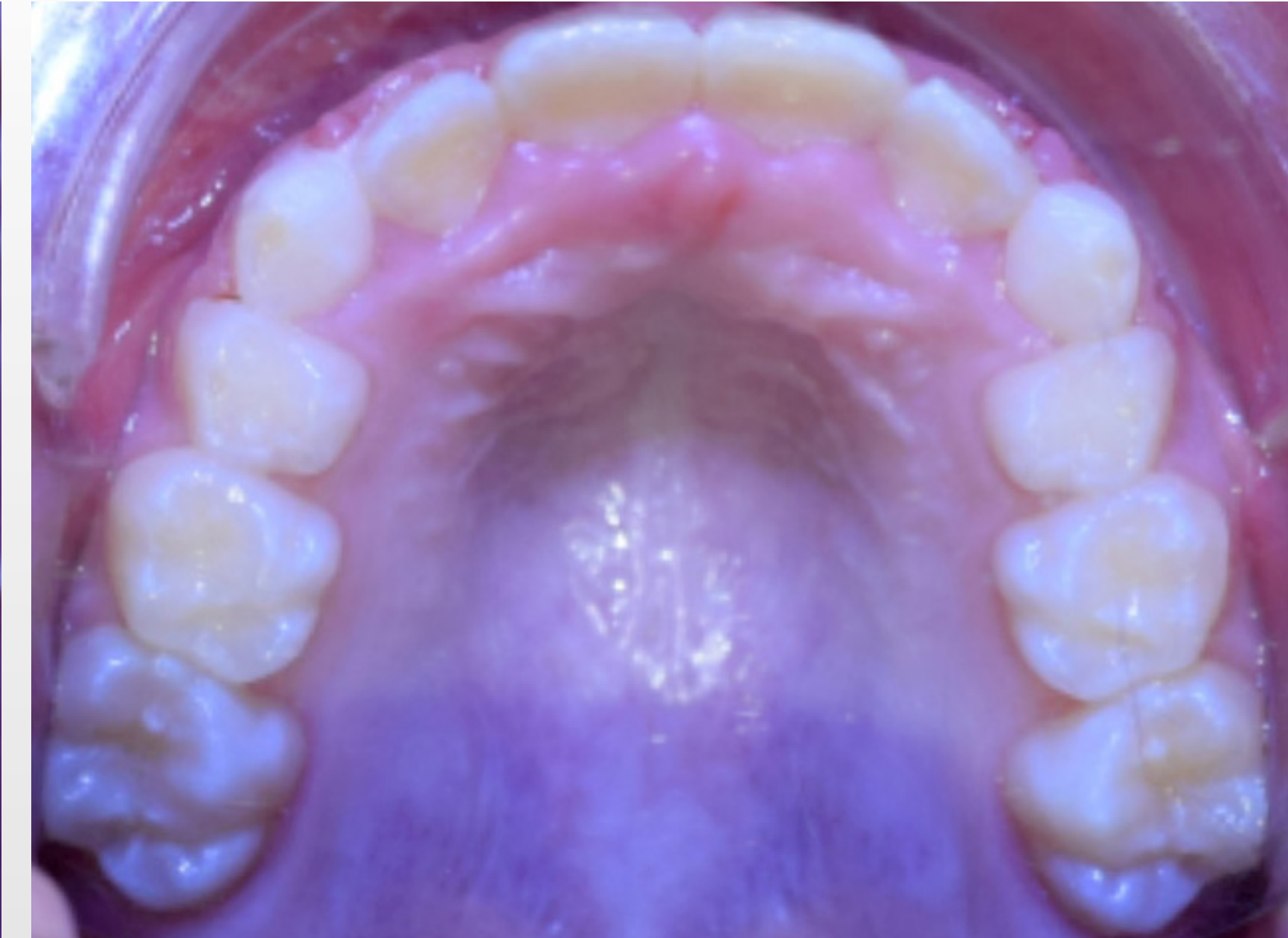
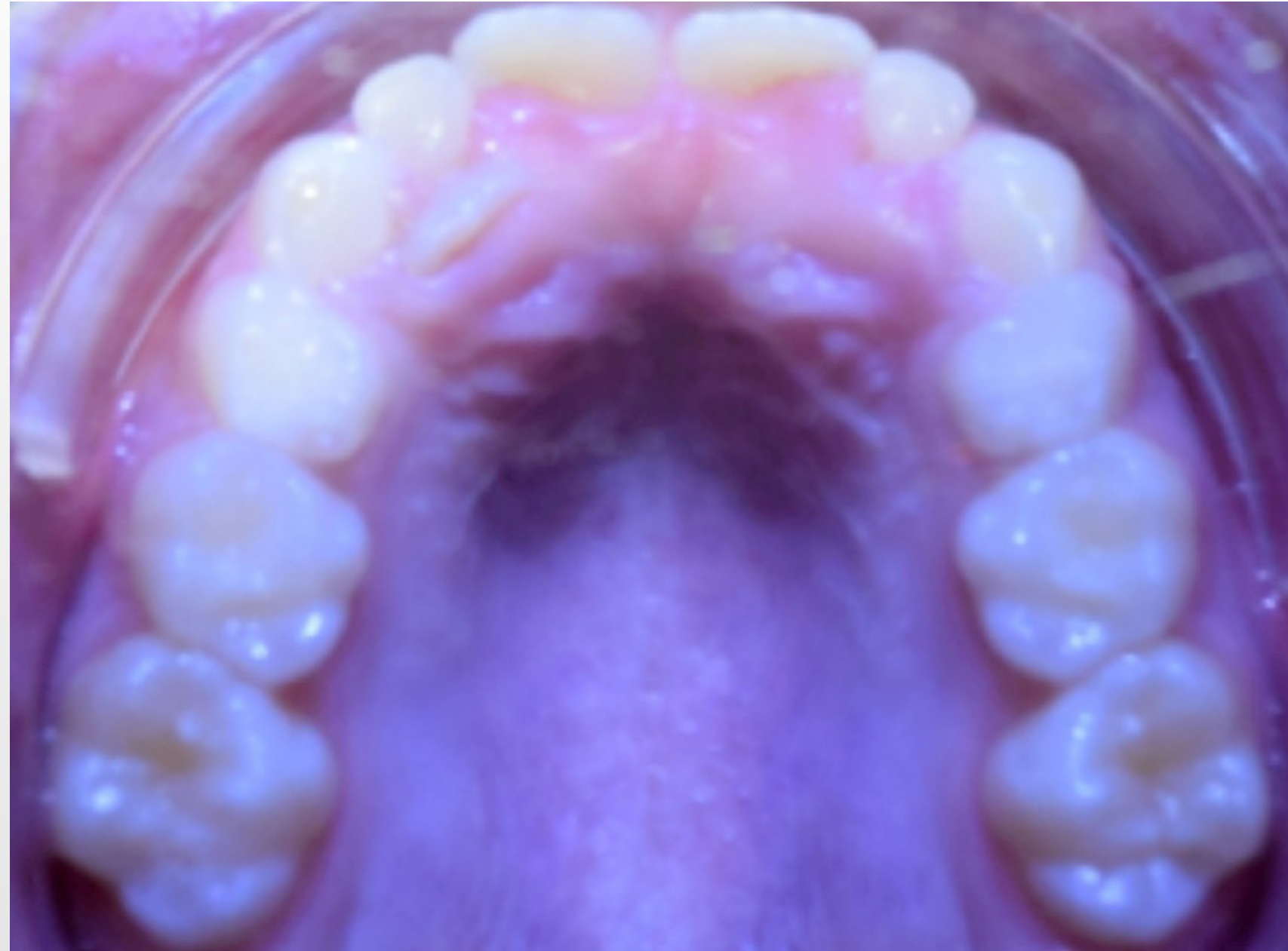
Face smiling



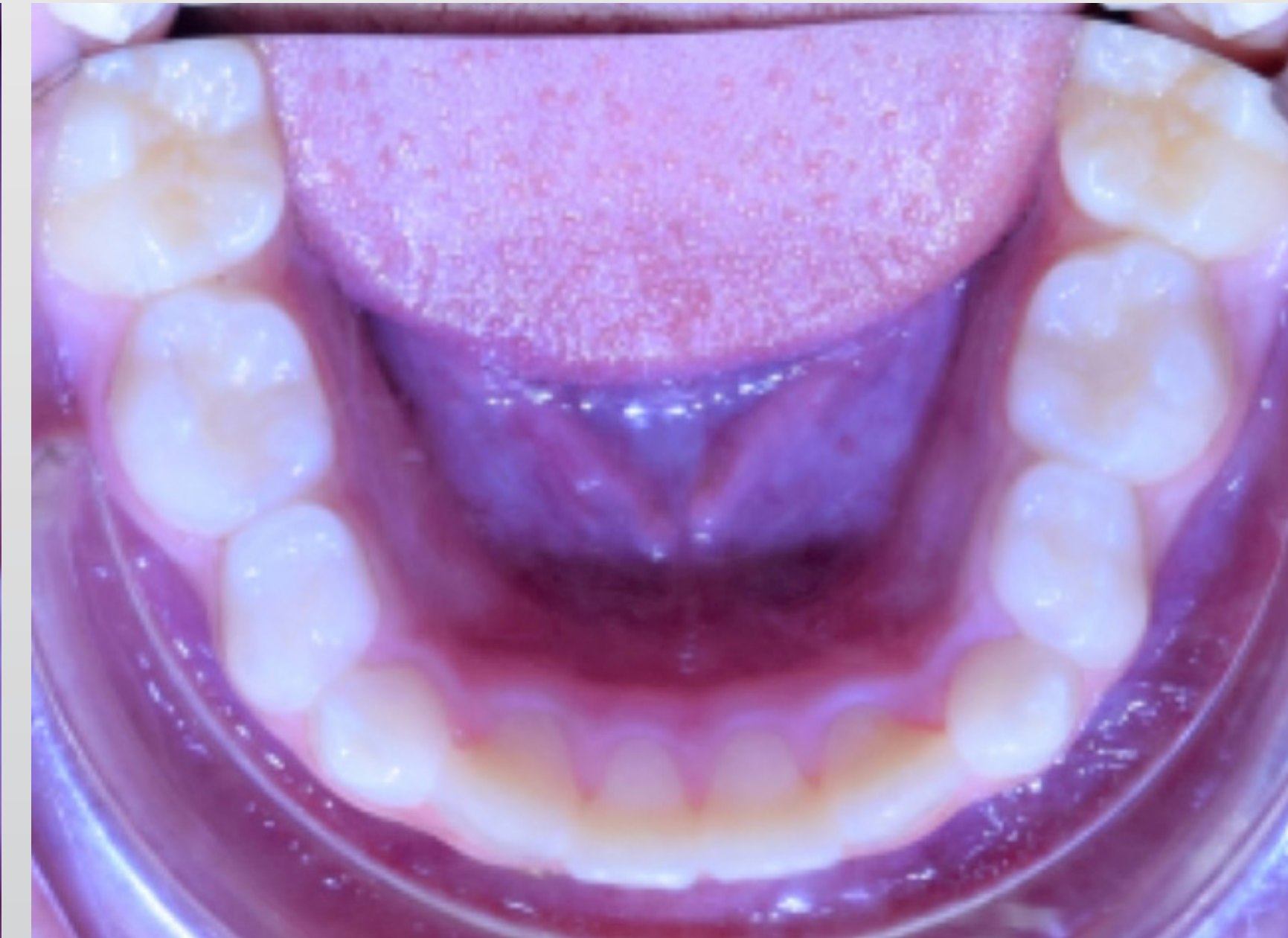
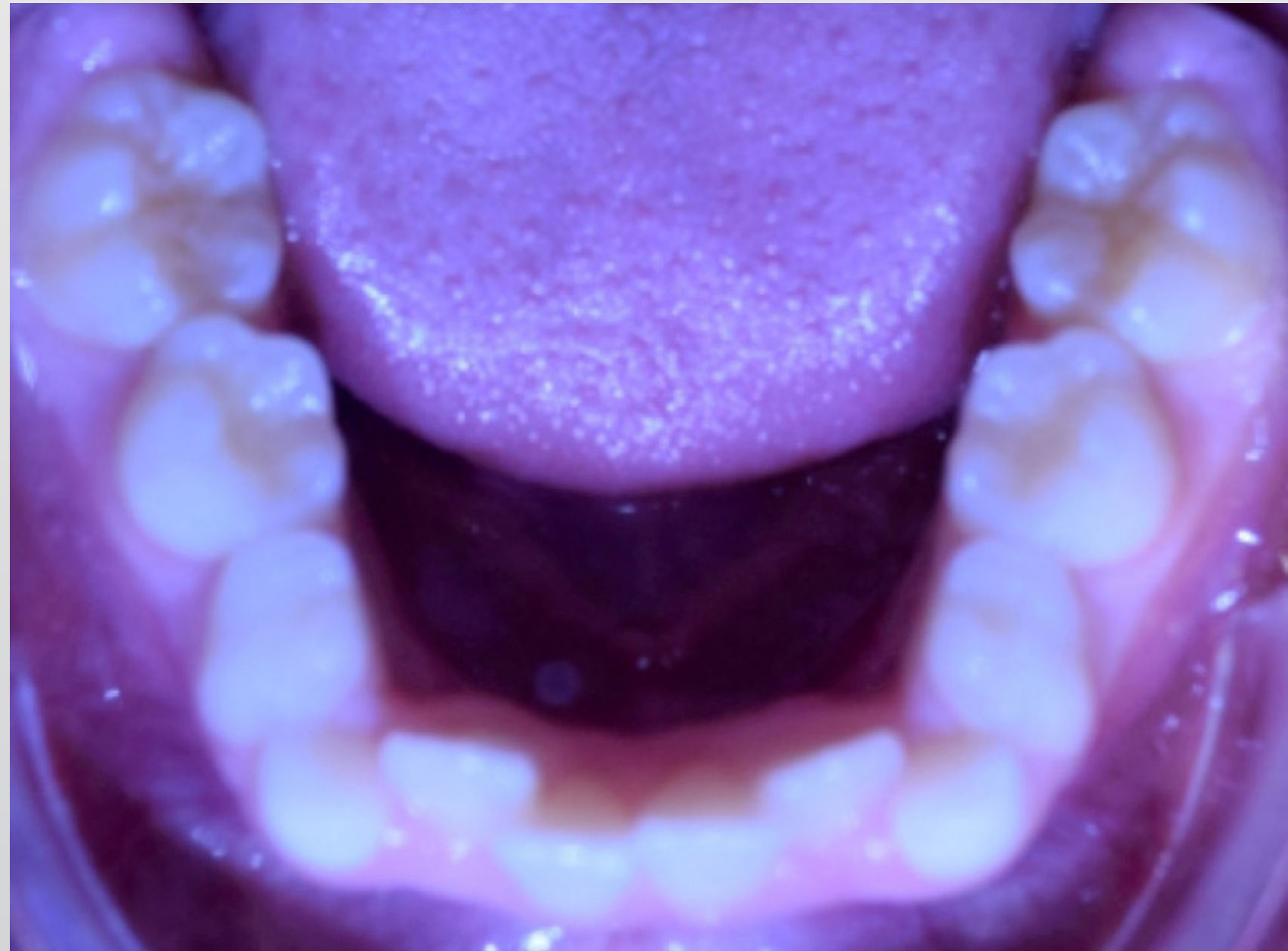Initial

Final

**Occlusal –
maxillary**



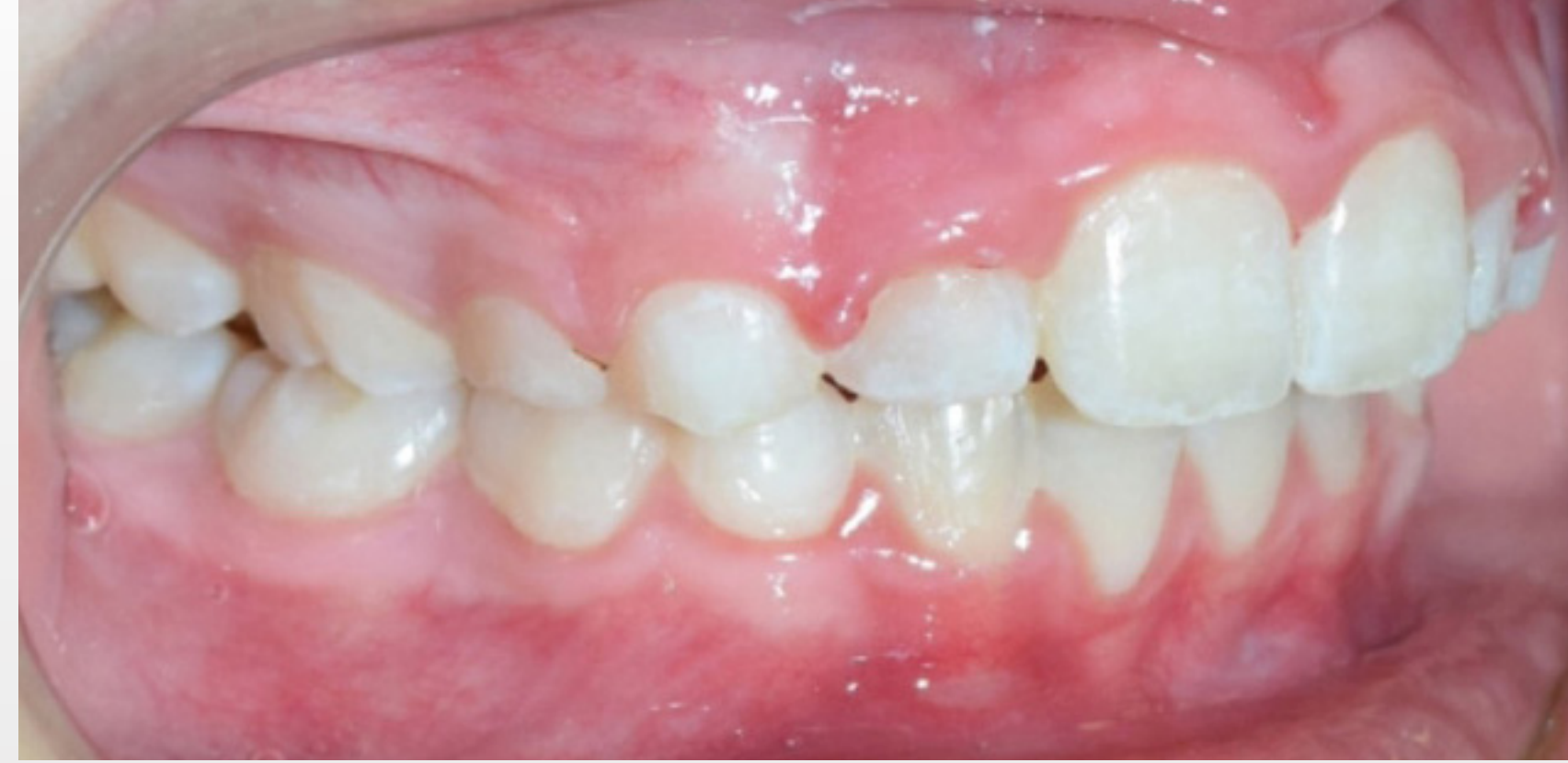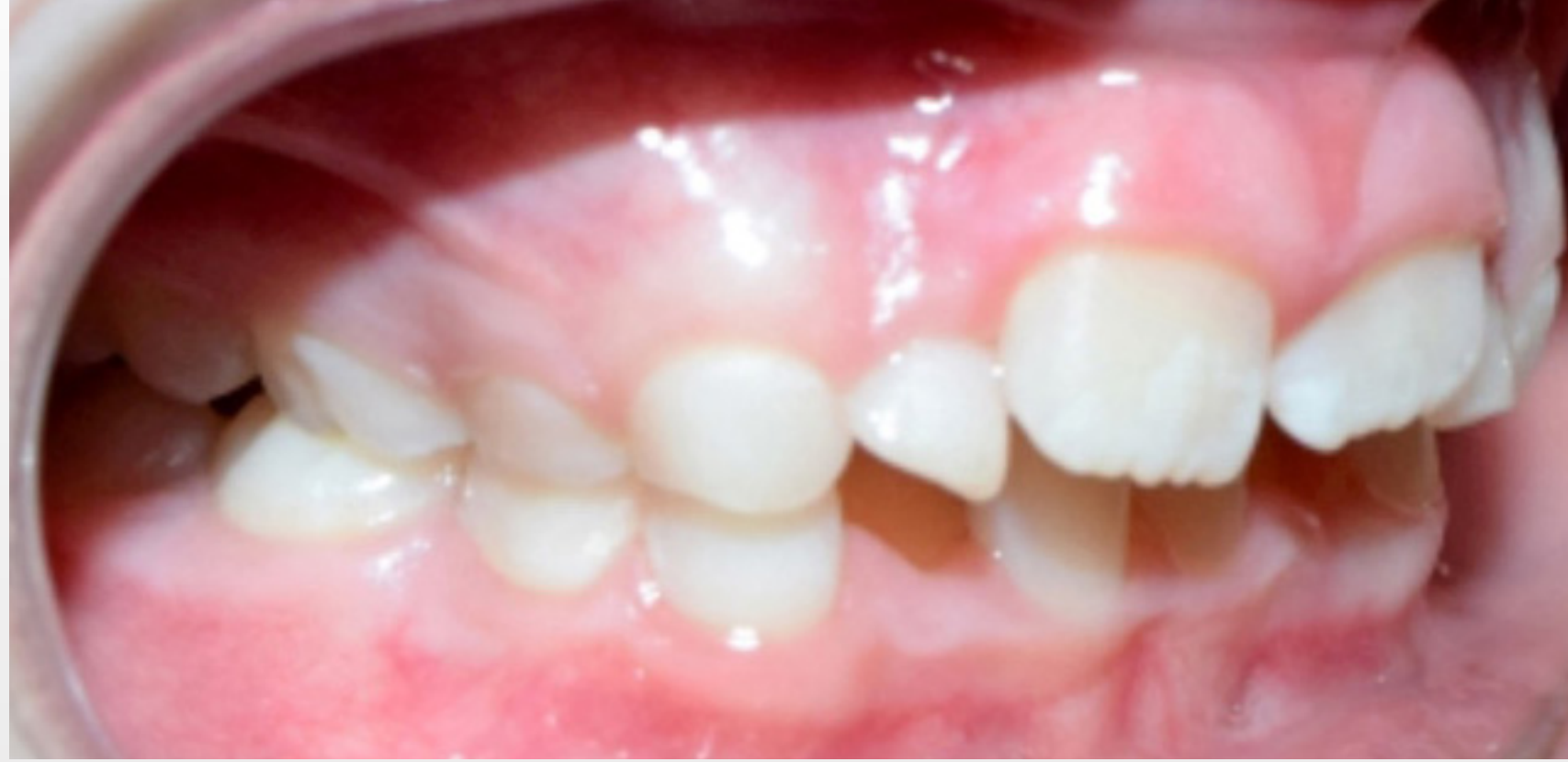**Occlusal –
mandibular**



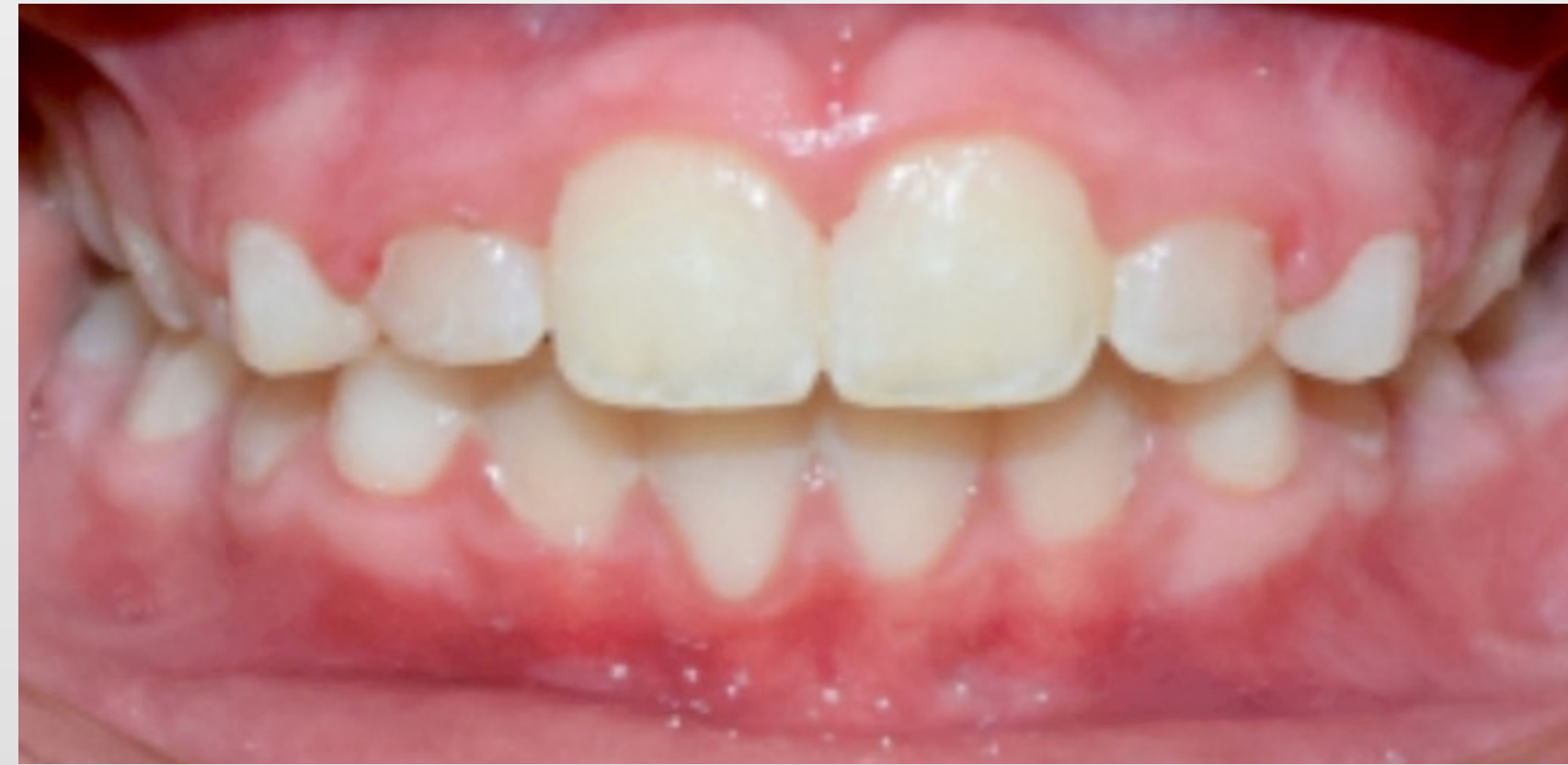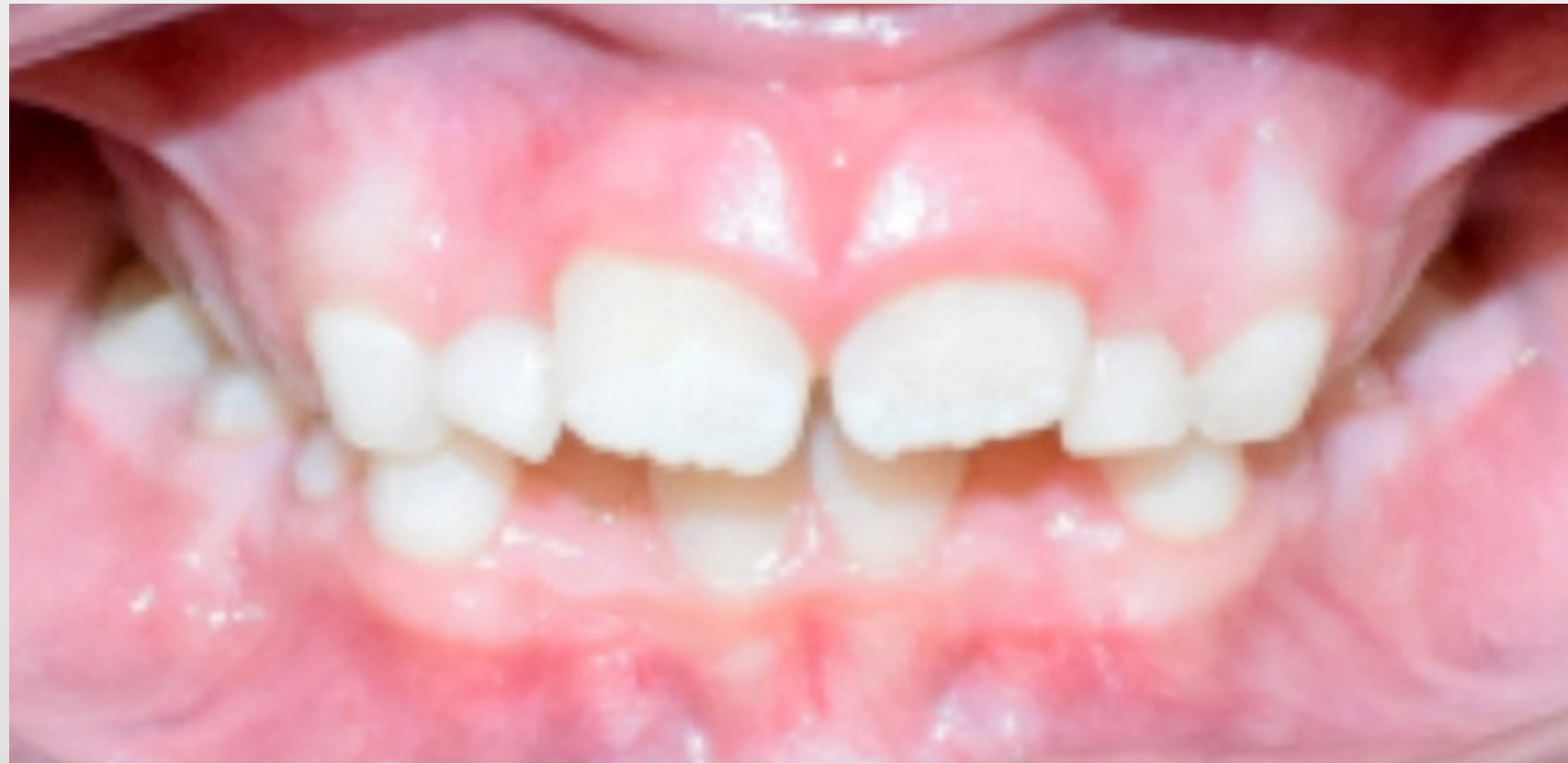Initial

Final

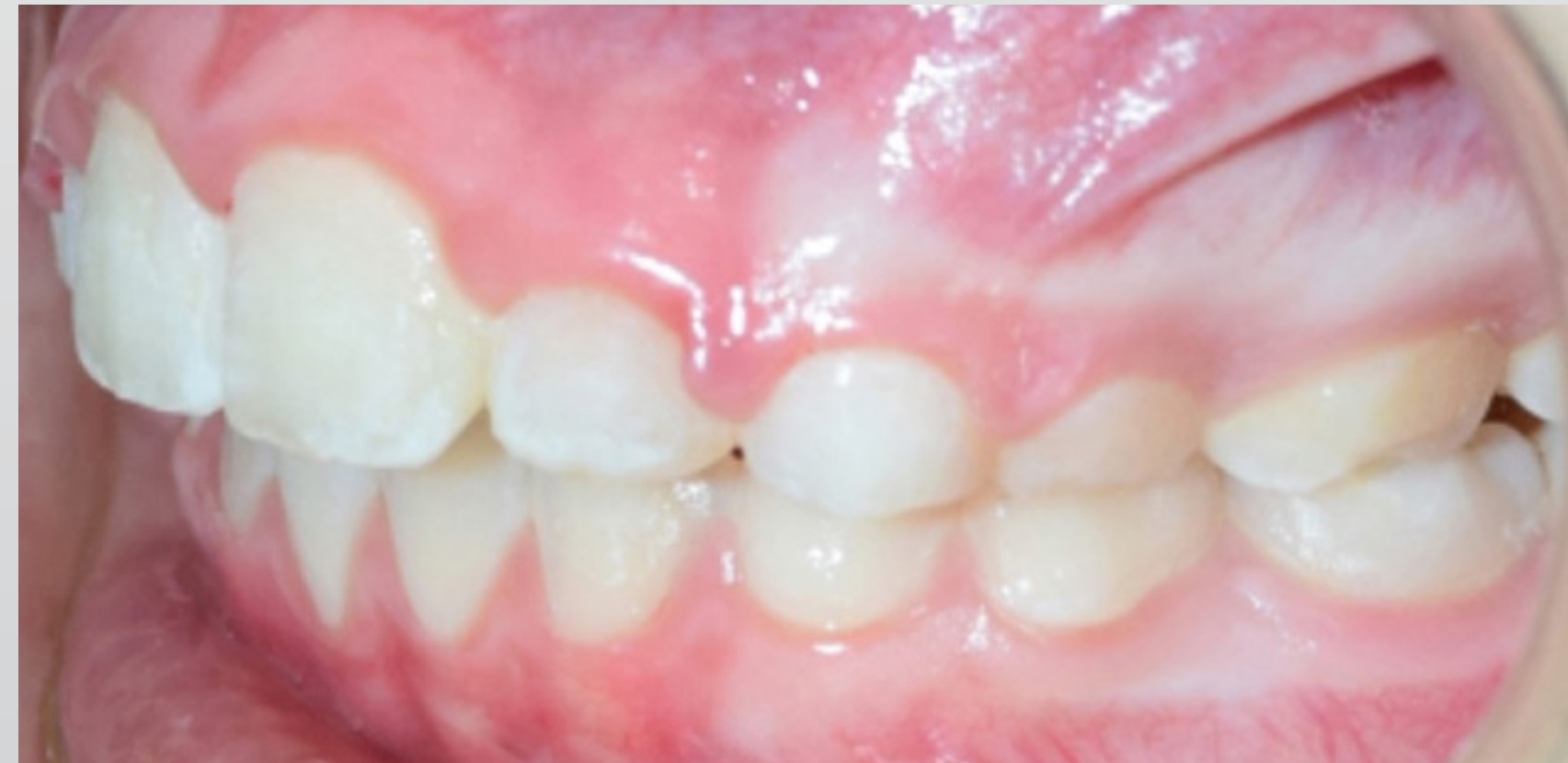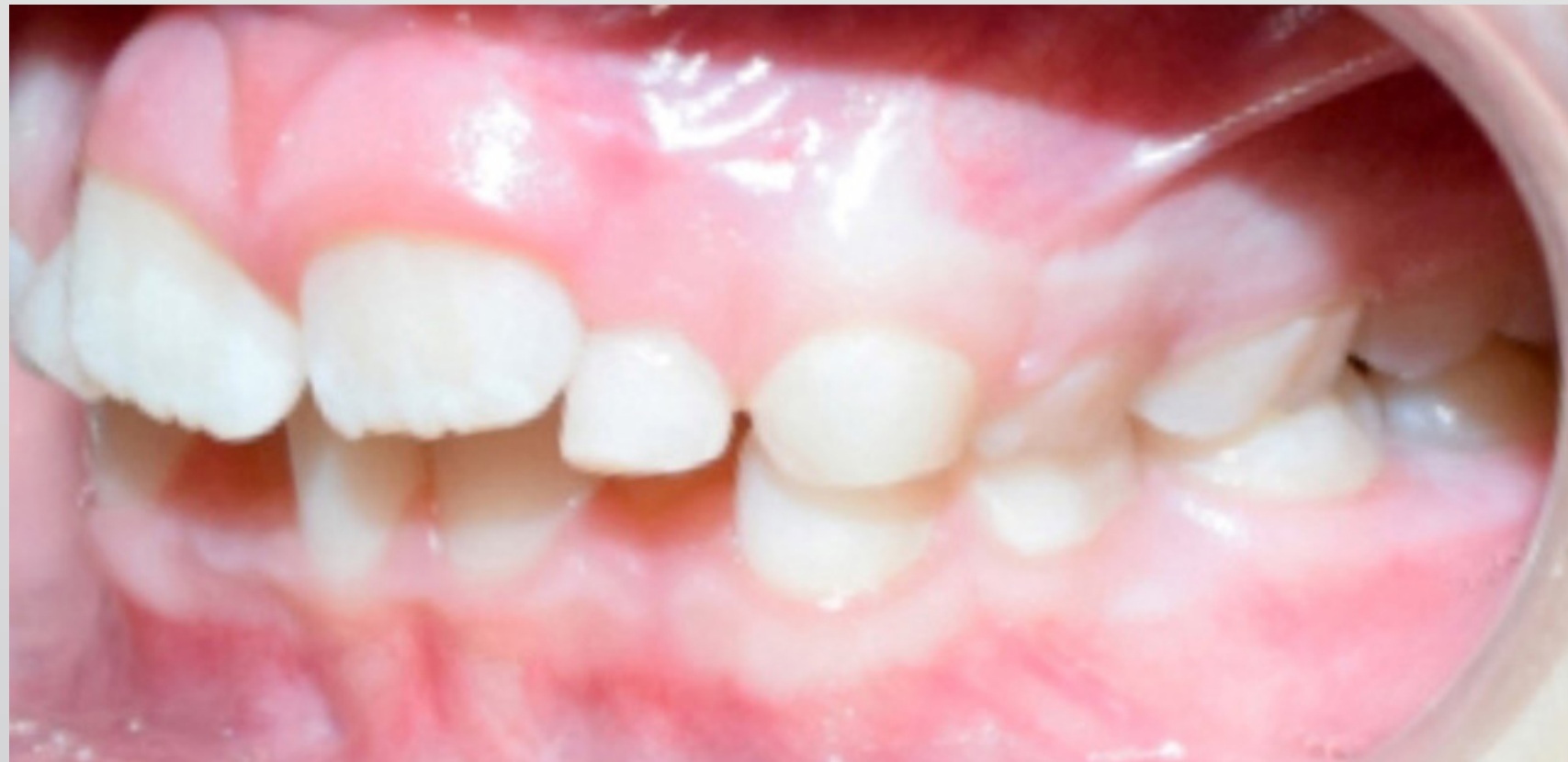**Retracted
buccal – right**



**Retracted
anterior biting**

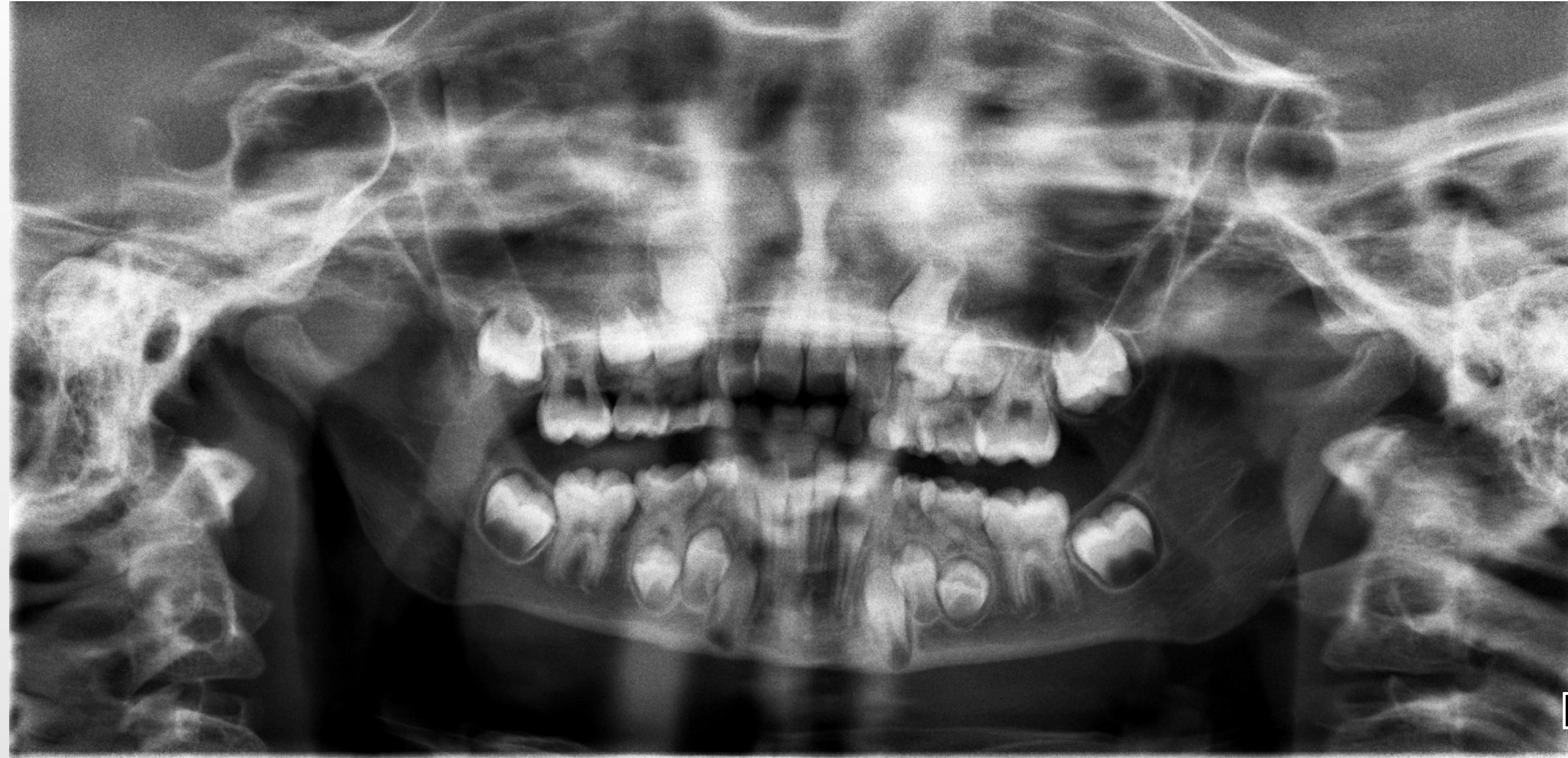

**Retracted
buccal – left**



Panoramic radiograph

Initial



Final



