

**Case Study:** 3M™ Clarity™ Aligners

**Correction of severe crowding and constricted arch with existing implant.**

**Age:** 49

**Original malocclusion:** Class I

**Total number of aligners:** 34 (dual arch)

**Wear interval:** Weekly

**Treatment time:** 8.5 months

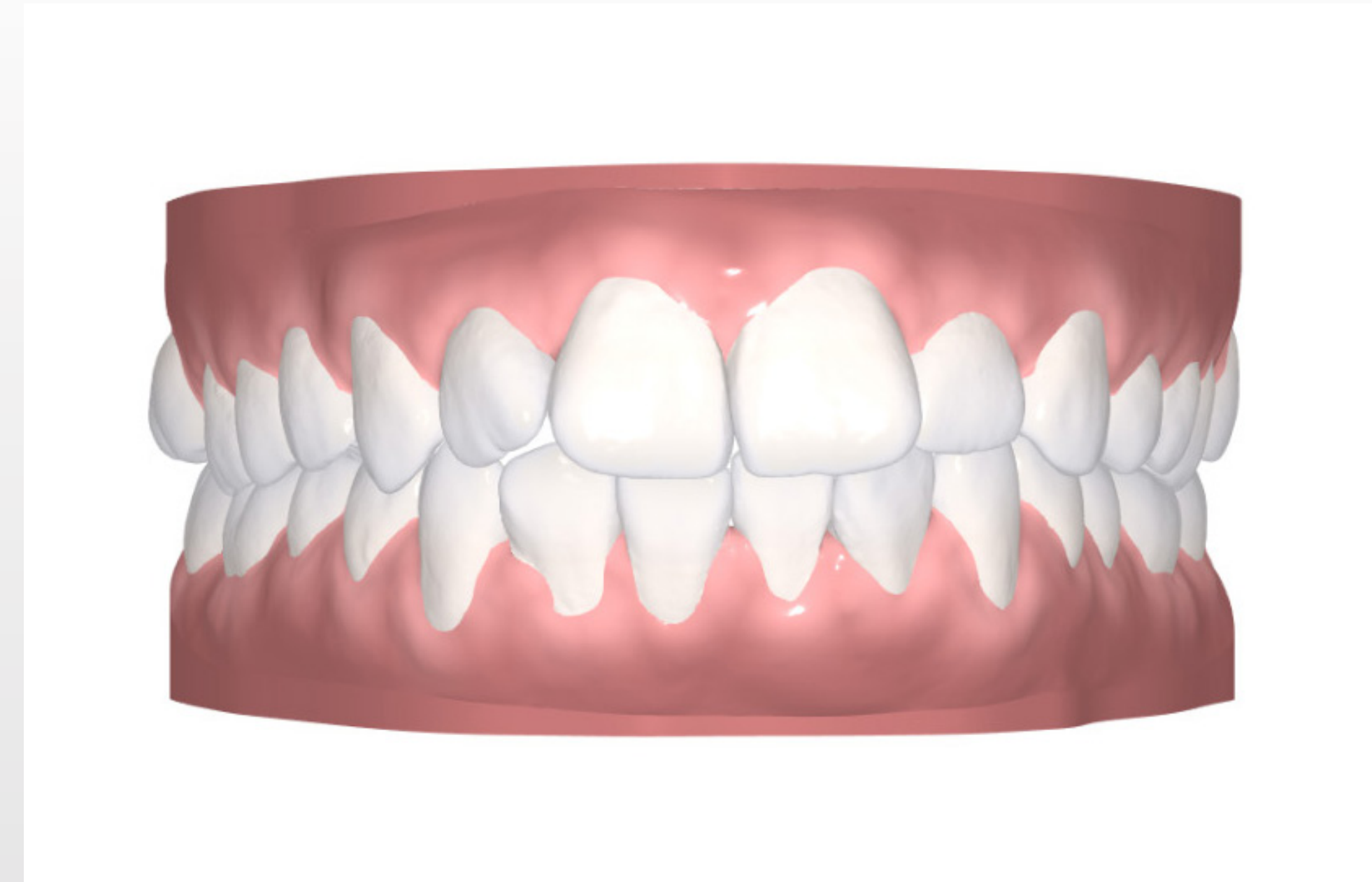
**IPR:** Total IPR Lower Arch = 1.2 mm

| By Stage   |  | Entire Case |    |    |    |    |    |    |    | Total IPR Upper Arch = 0mm |    |    |    |    |    |    |    | Total IPR Lower Arch = 1.2mm |  |  |  |  |  |  |  |
|------------|--|-------------|----|----|----|----|----|----|----|----------------------------|----|----|----|----|----|----|----|------------------------------|--|--|--|--|--|--|--|
|            |  | R8          | R7 | R6 | R5 | R4 | R3 | R2 | R1 | L1                         | L2 | L3 | L4 | L5 | L6 | L7 | L8 |                              |  |  |  |  |  |  |  |
| Upper Arch |  |             |    |    |    |    |    |    |    |                            |    |    |    |    |    |    |    |                              |  |  |  |  |  |  |  |
| Lower Arch |  |             |    |    |    |    |    |    |    | .2                         | .4 | .4 | .2 |    |    |    |    |                              |  |  |  |  |  |  |  |

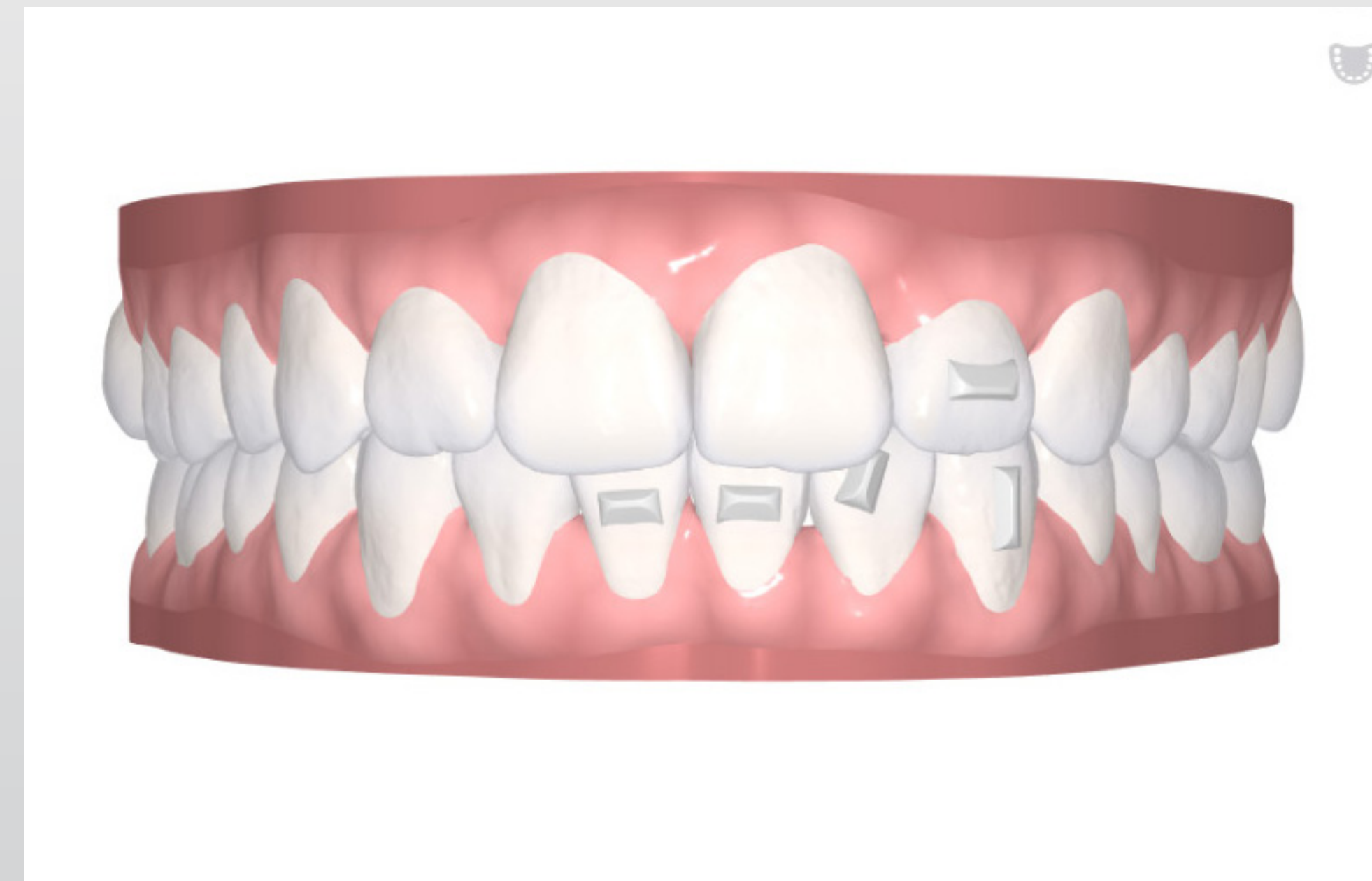**Case courtesy of:**  
 Dr. Adam Schulhof  
 Oradell, NJ – USA

**Tx design**

**Initial**



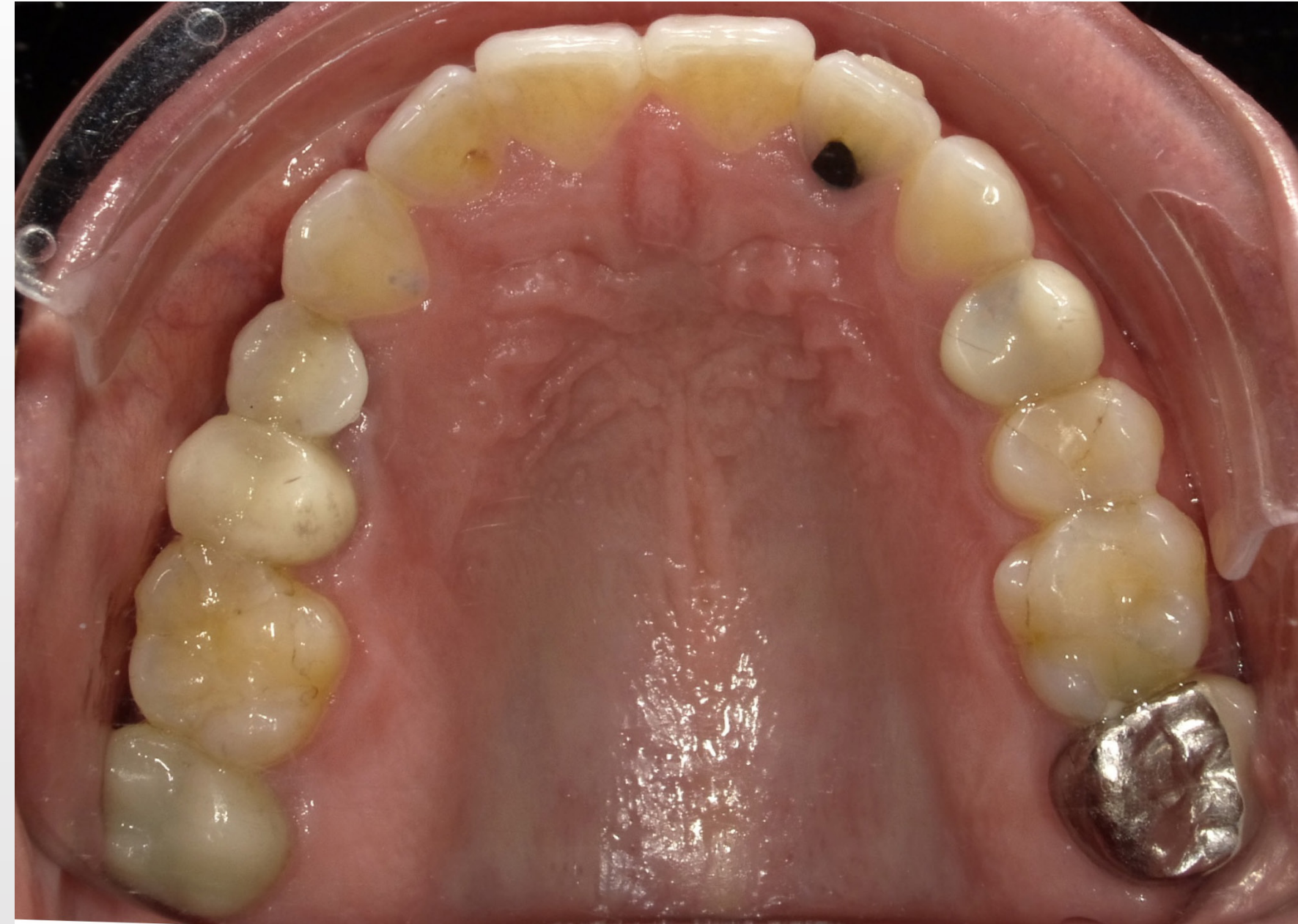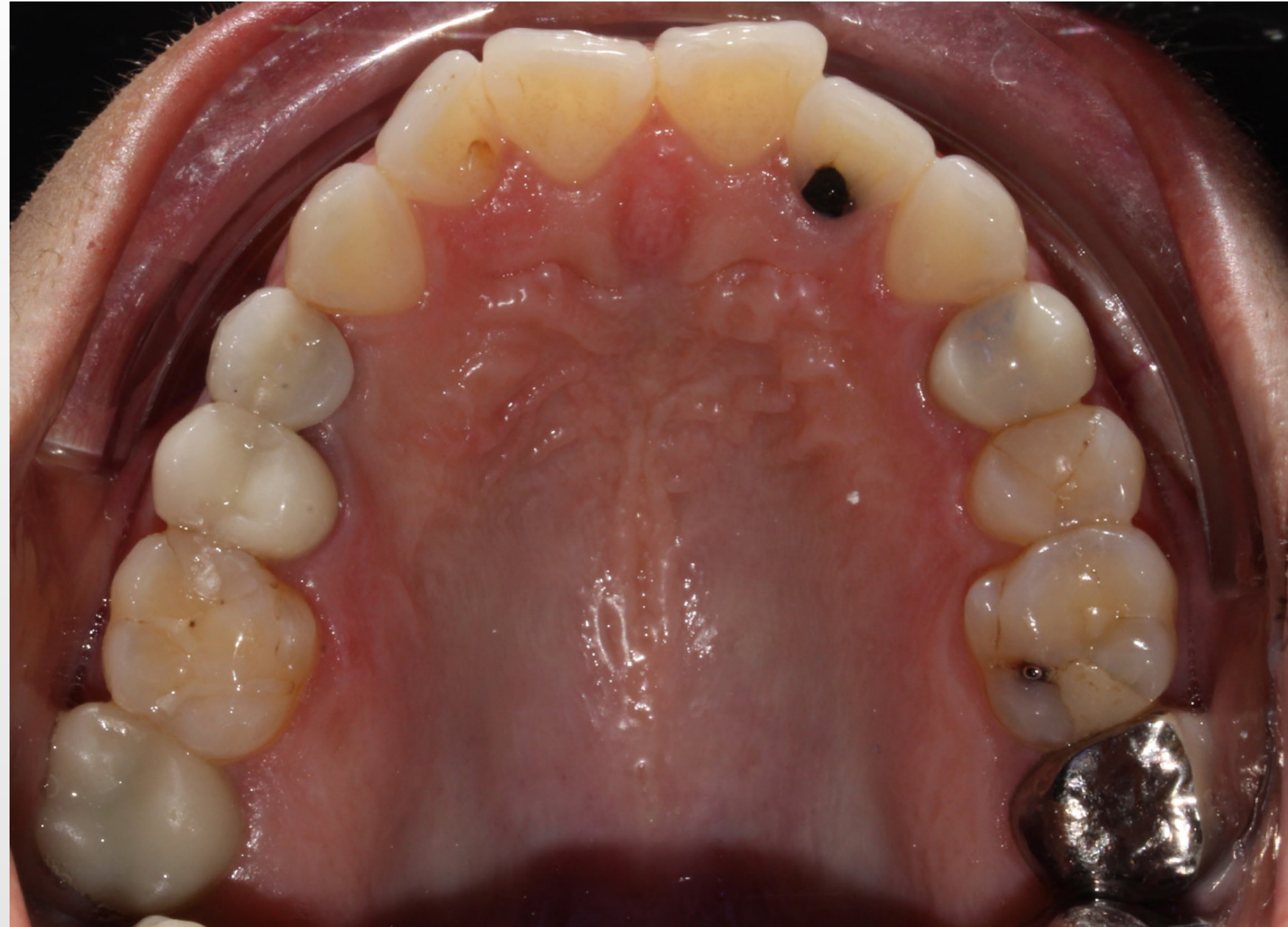**Progress**



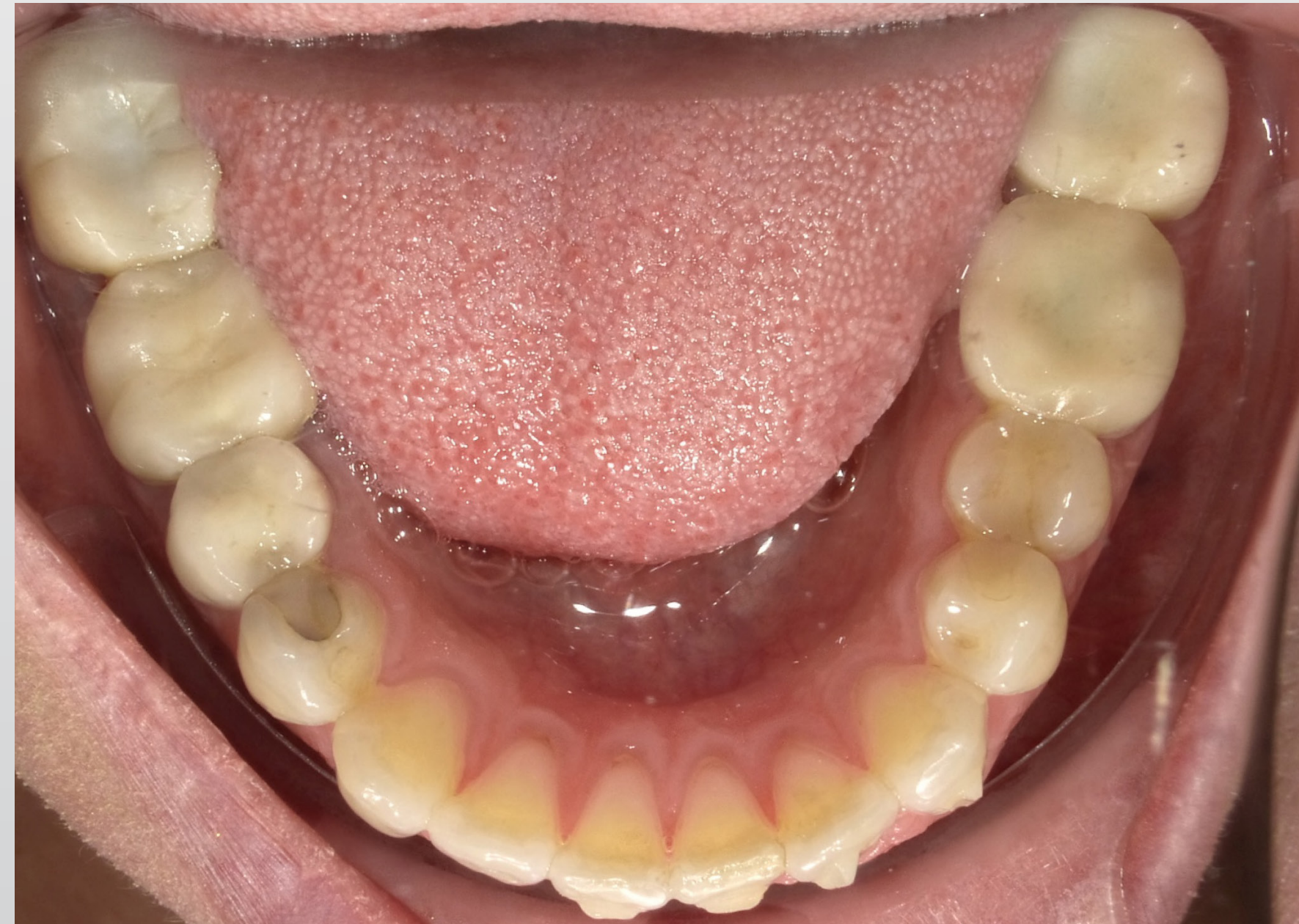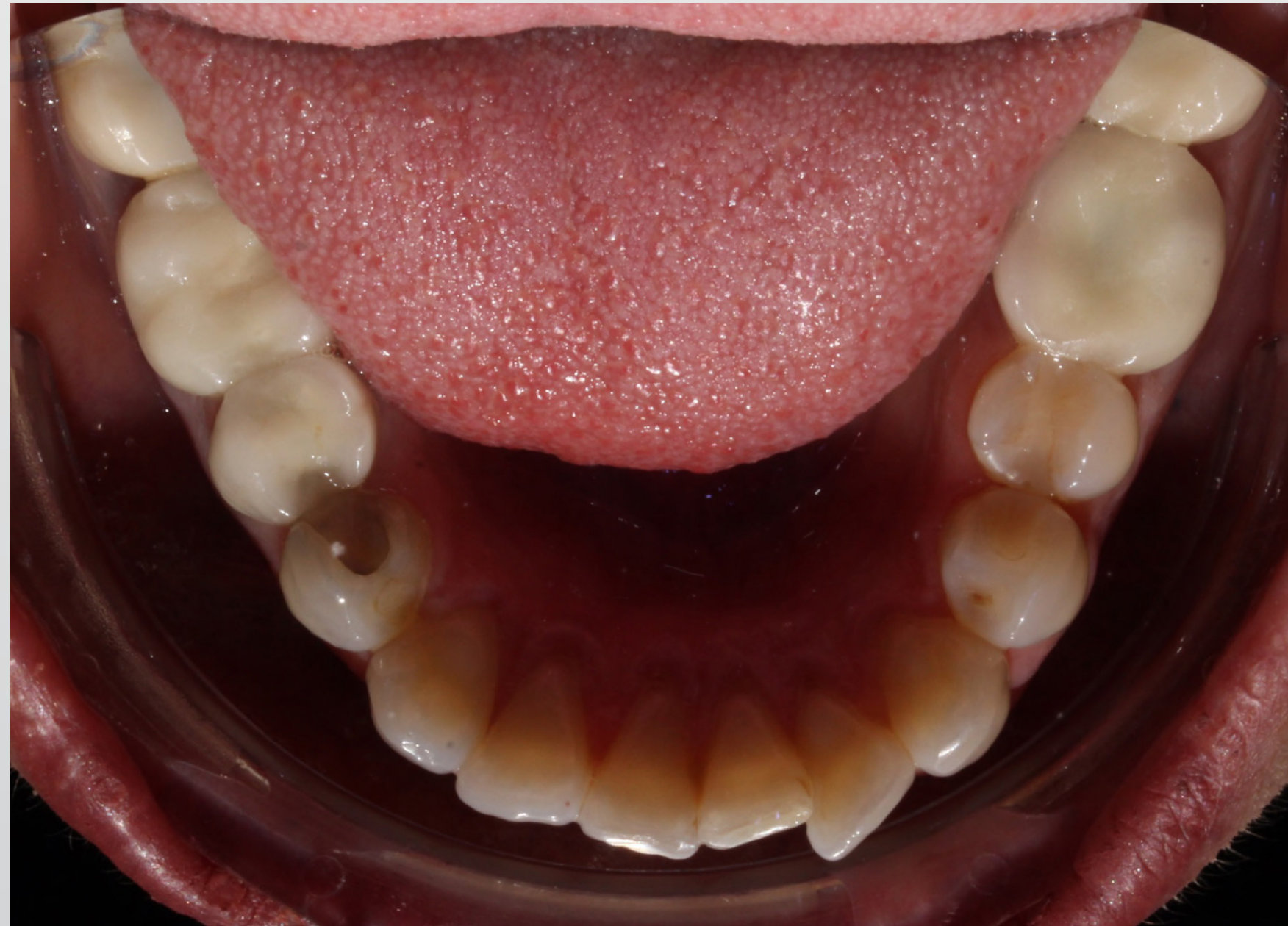**Initial**

**Progress**

**Occlusal –  
maxillary**



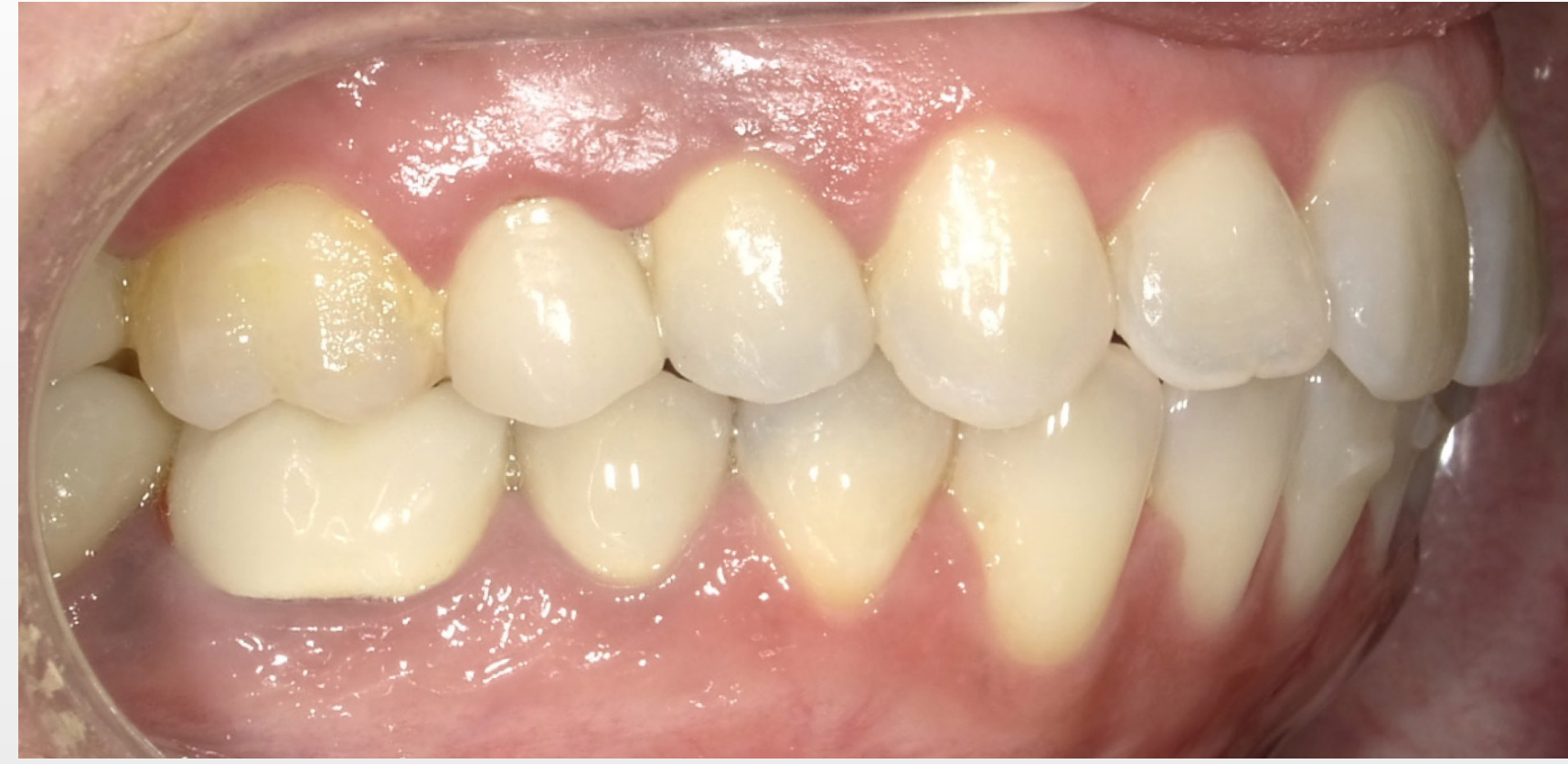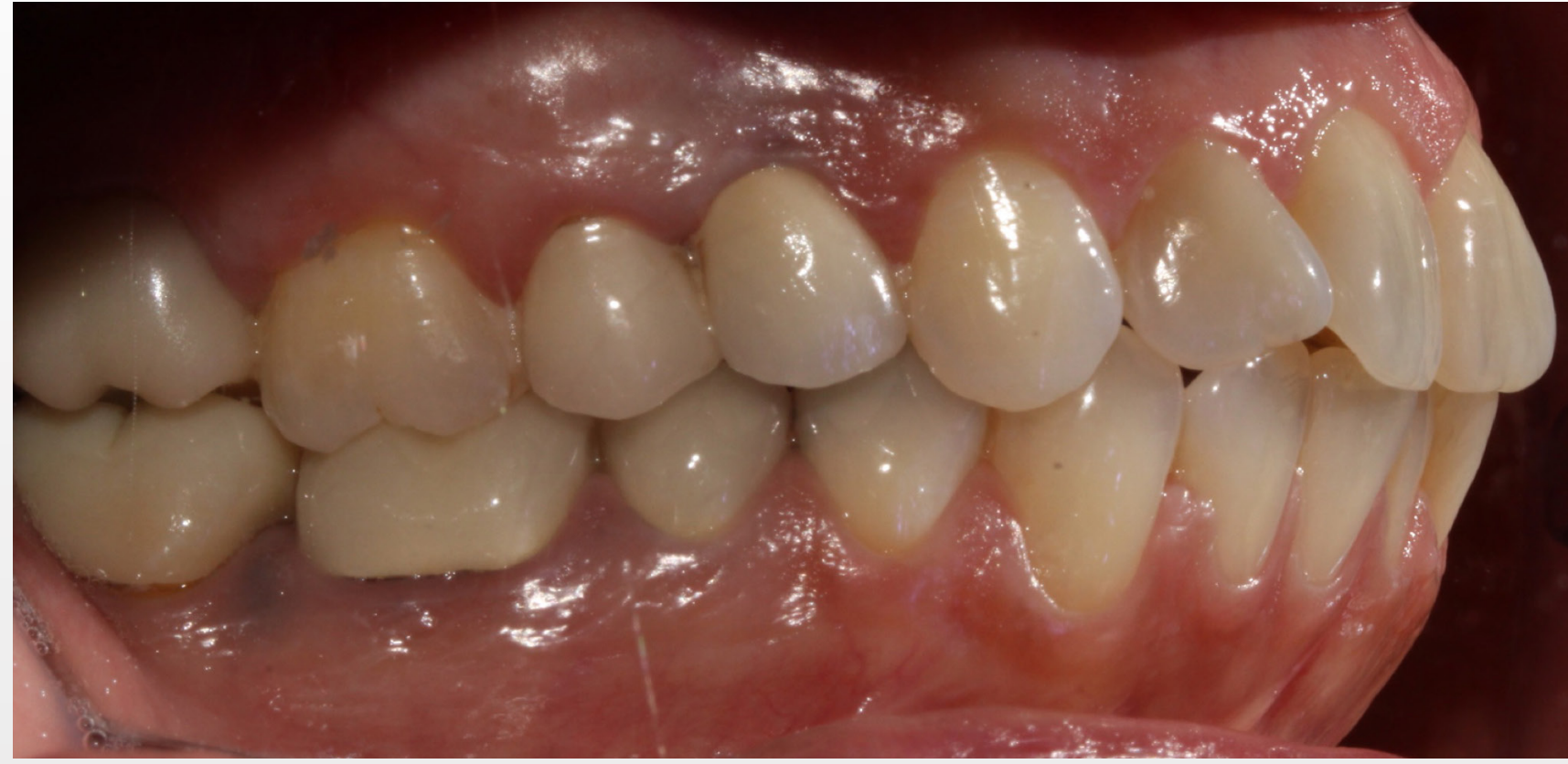**Occlusal –  
mandibular**



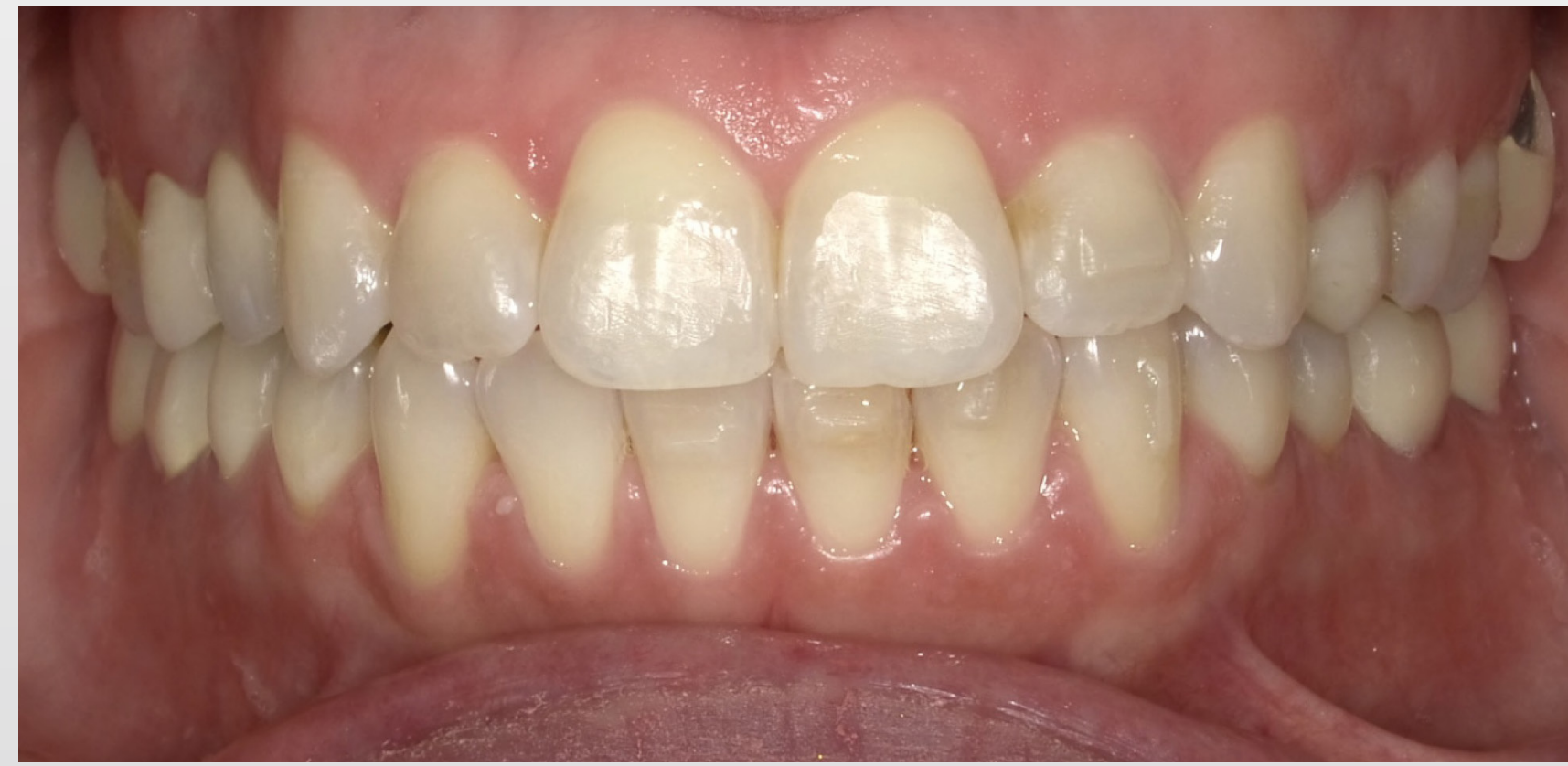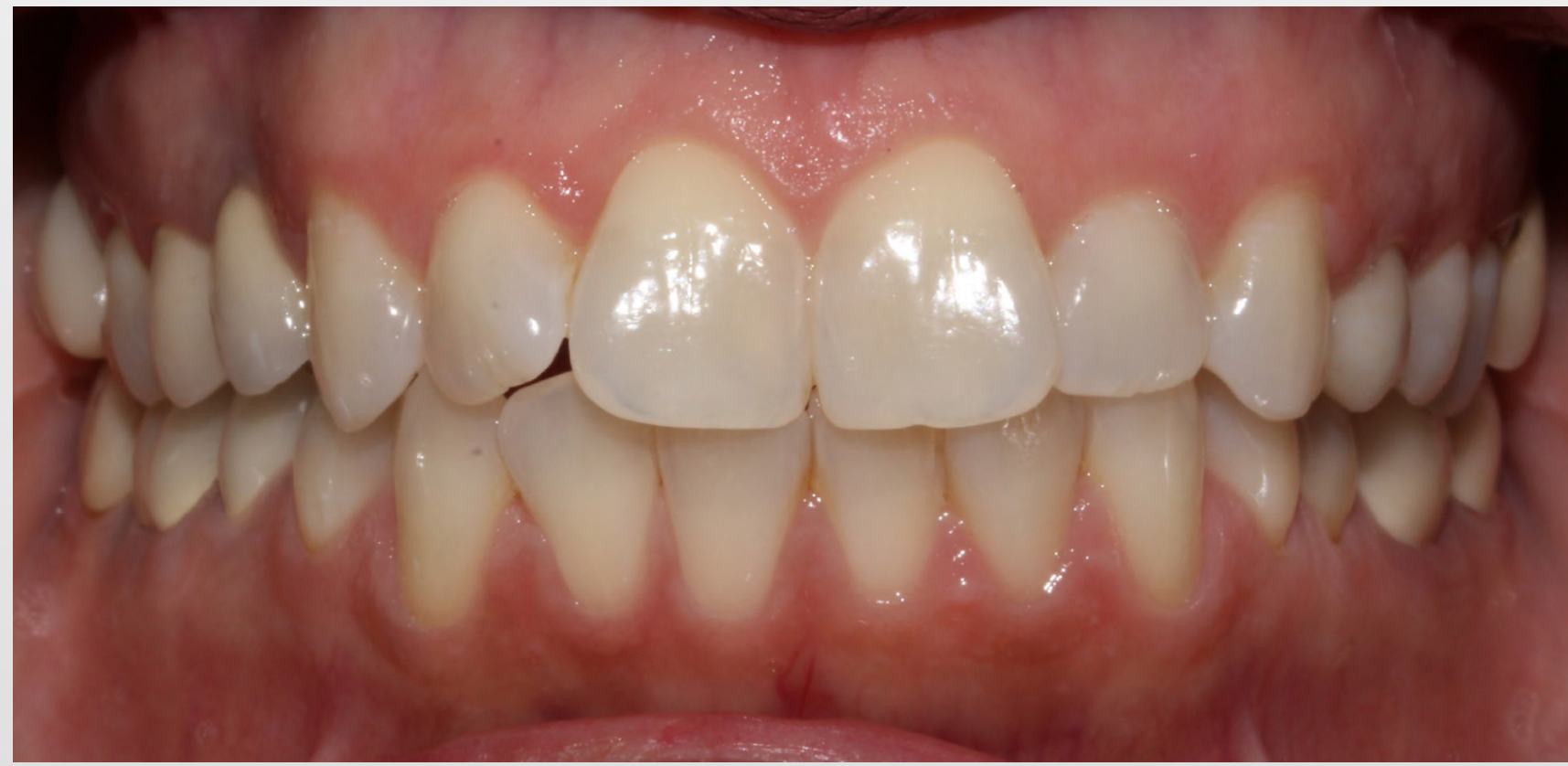**Initial**

**Progress**

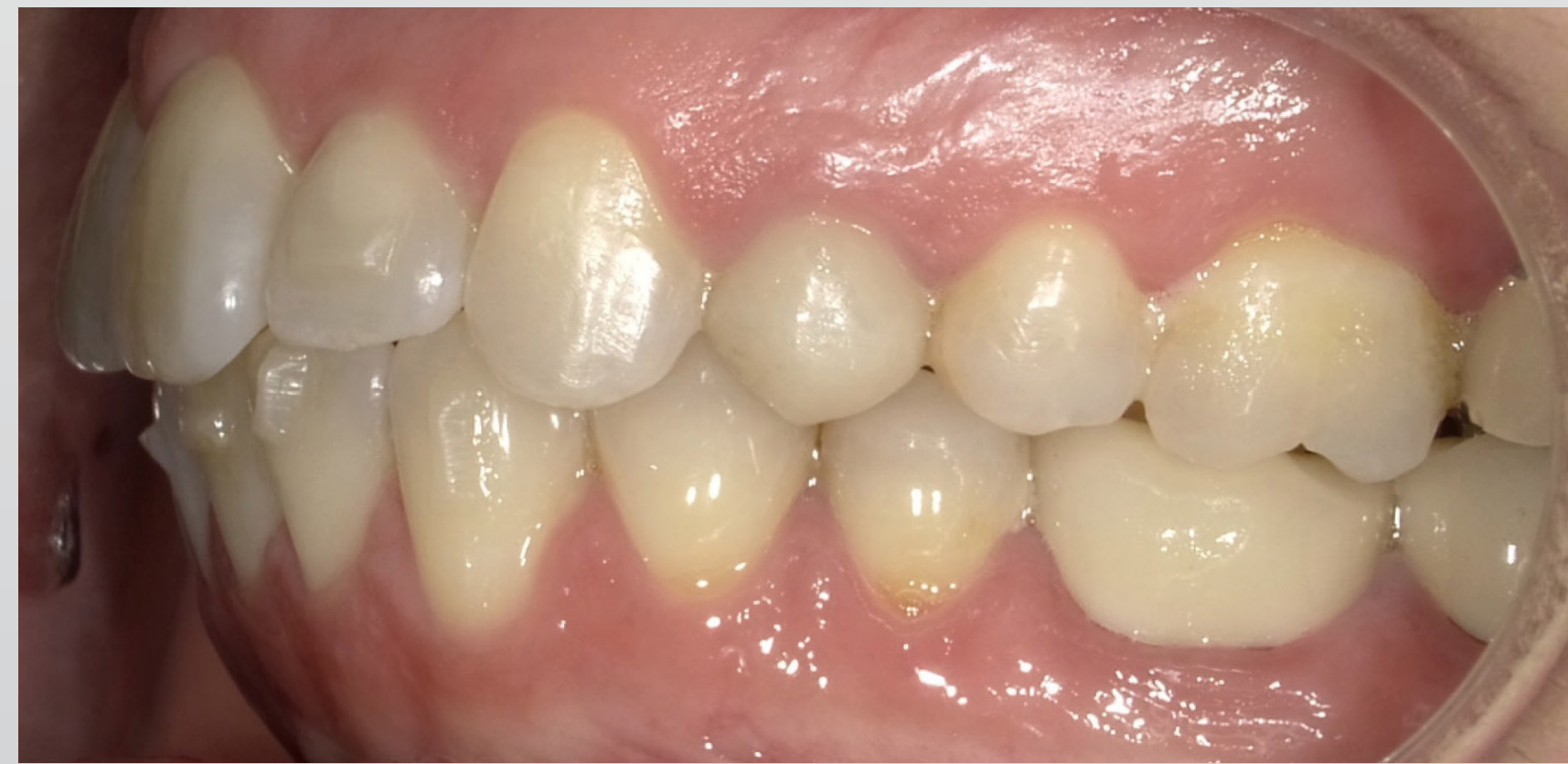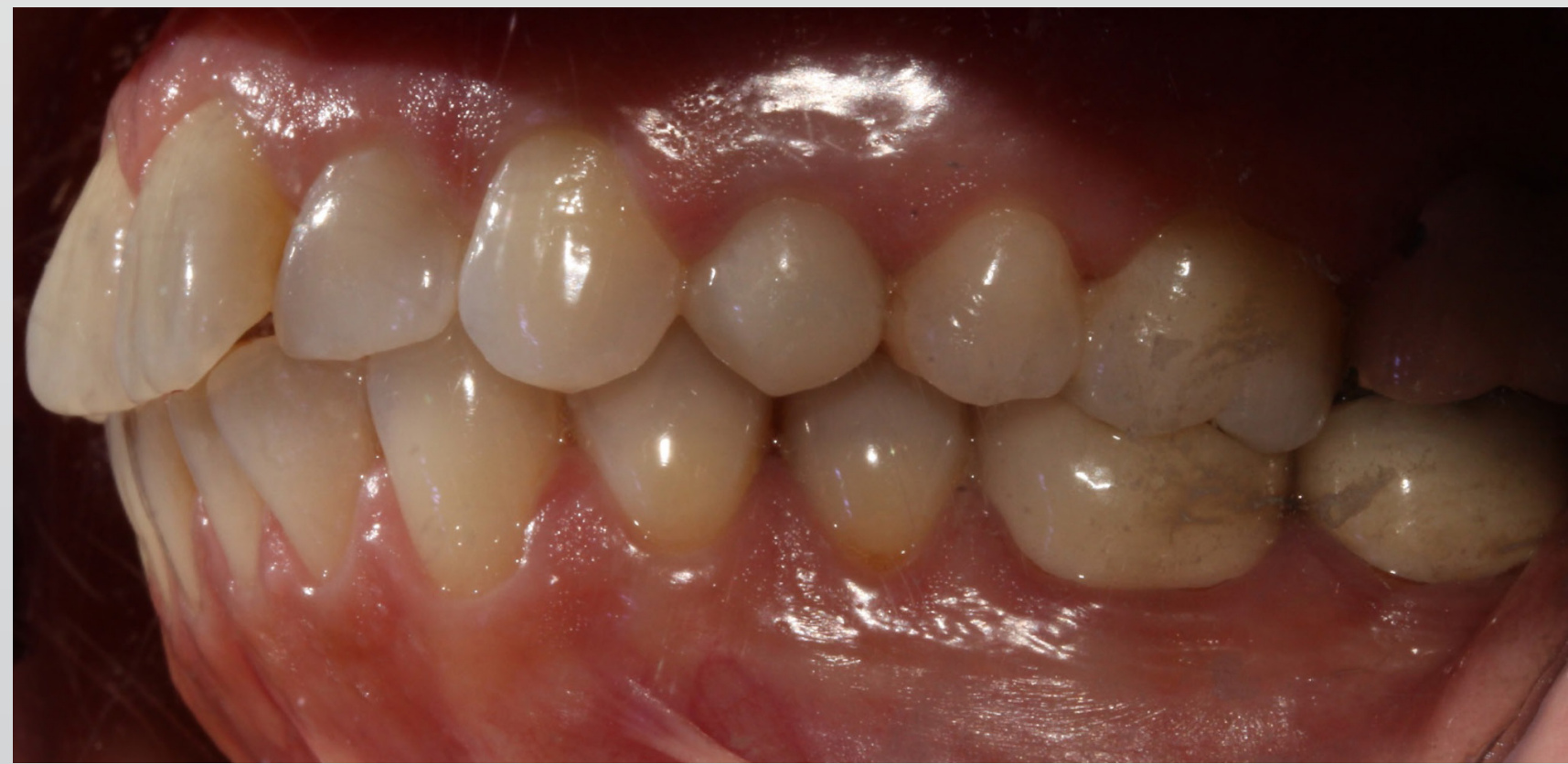**Retracted  
buccal – right**



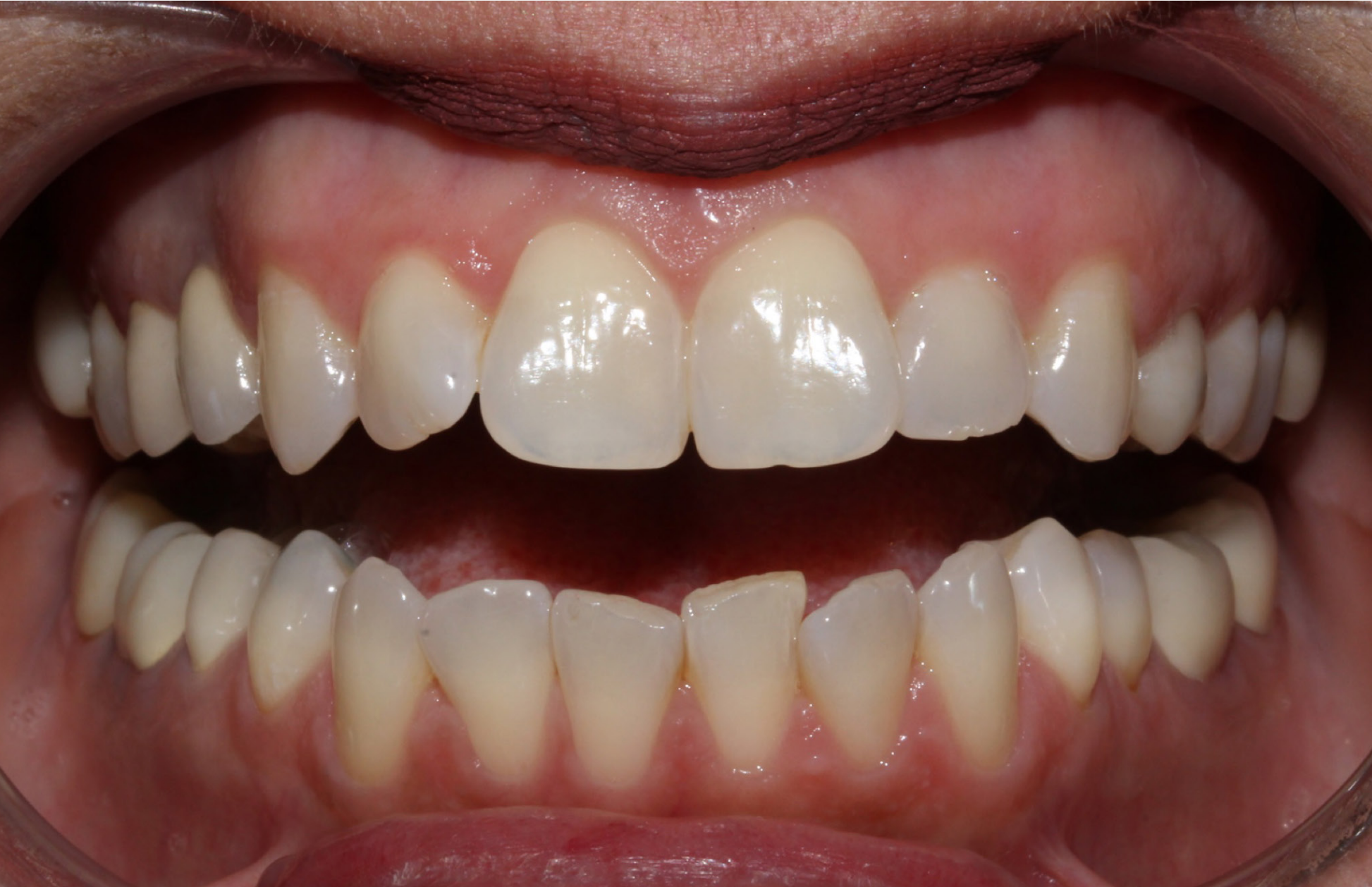**Retracted  
anterior biting**



**Retracted  
buccal – left**



**Initial**



**Anterior  
open**

**Progress**



