

Case Study: 3M<sup>™</sup> Clarity<sup>™</sup> Aligners

# Esthetically reducing embrasures with barrel-shaped incisors without bonding.

Age: 16

Original malocclusion: Class I

Total number of aligners: 13 (dual arch)

Wear interval: Weekly

Treatment time: 3 months

IPR: Total IPR Upper Arch = 0.2 mm

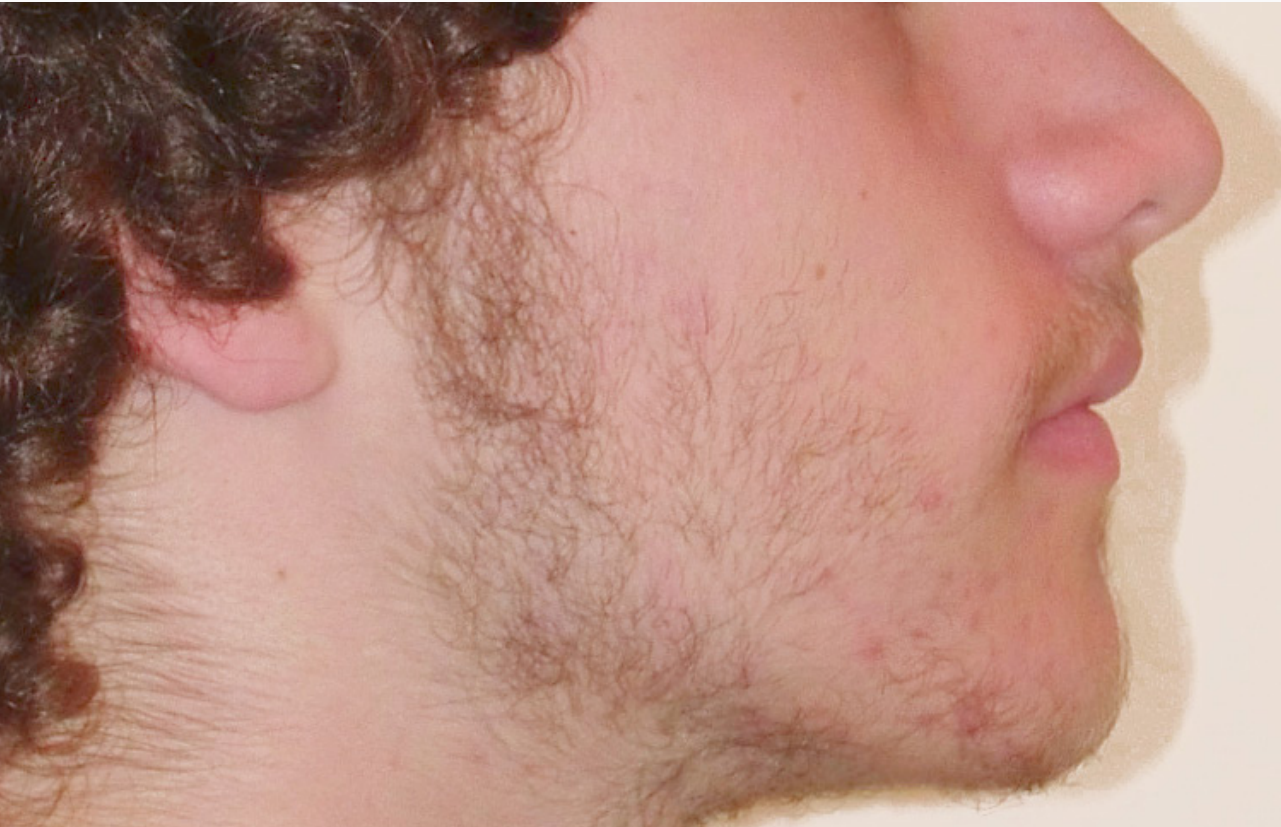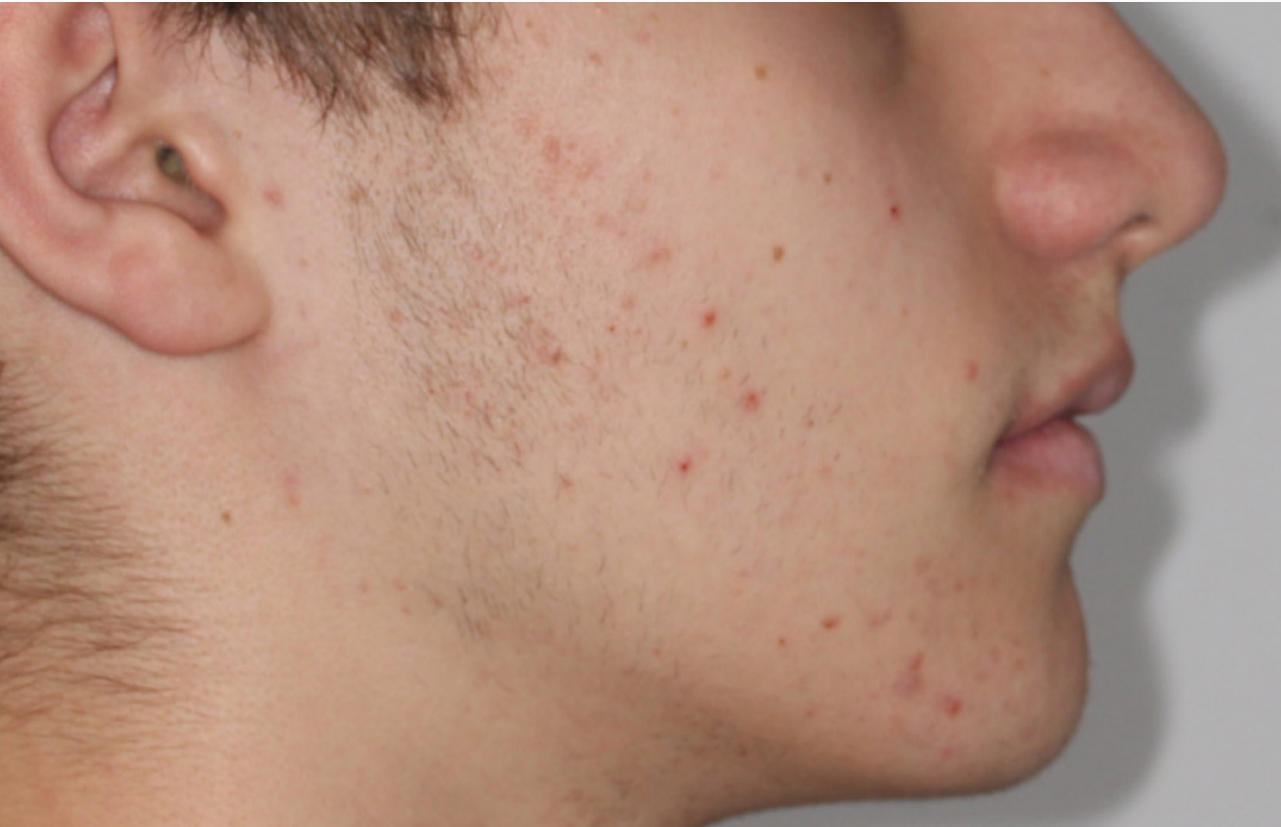	By Stage													Entire Case				Total IPR Upper Arch = 0.2mm								Total IPR Lower Arch = 0mm							
	R8	R7	R6	R5	R4	R3	R2	R1	L1	L2	L3	L4	L5	L6	L7	L8																	
Upper Arch									.2																								
Lower Arch																																	

Case courtesy of:  
Dr. Adam Schuhof  
Oradell, NJ – USA

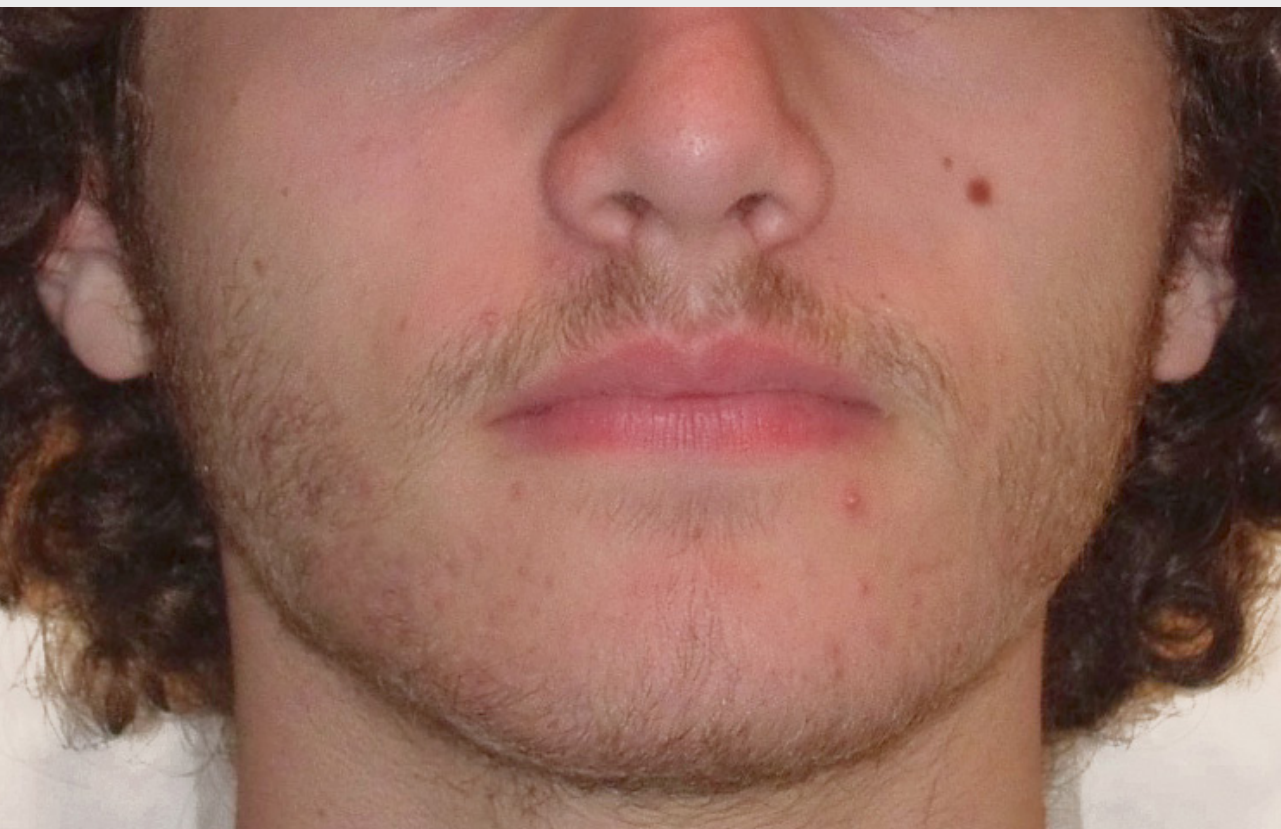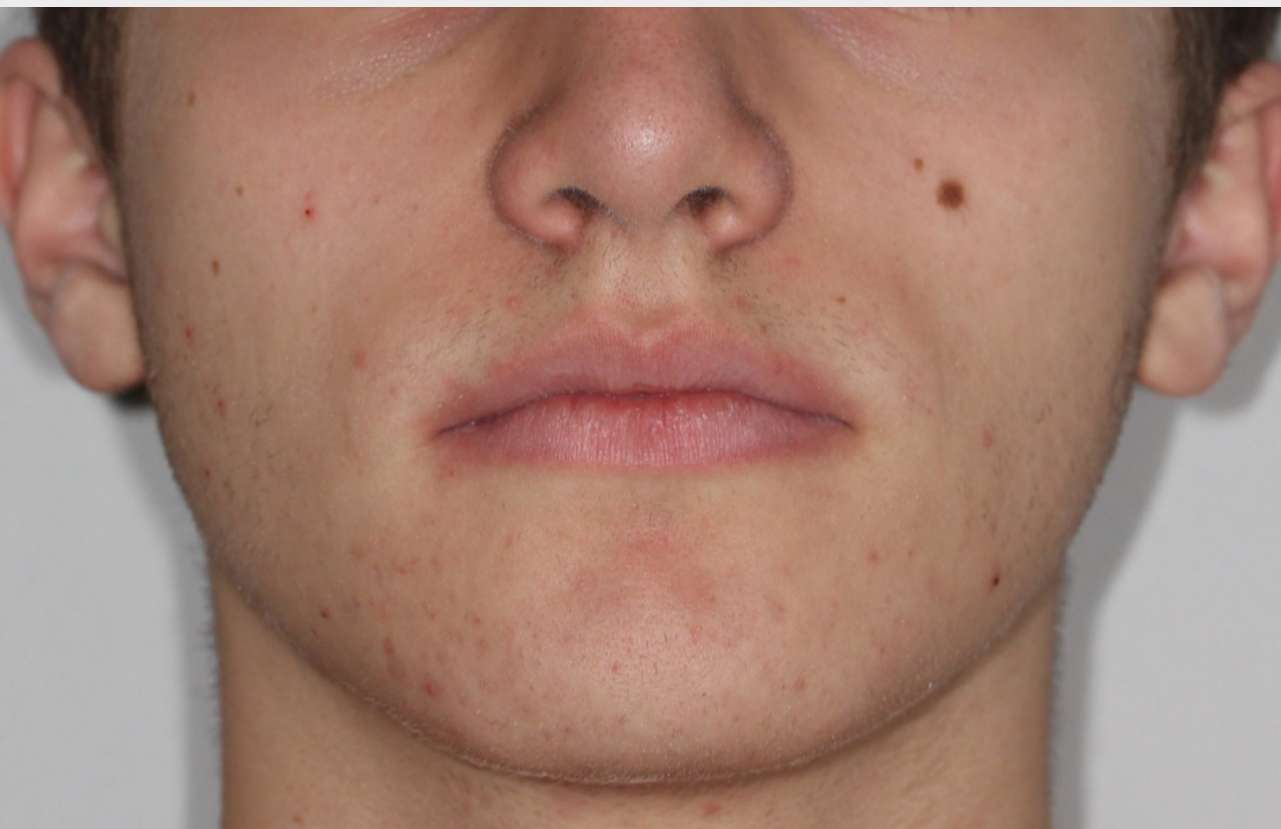Initial

Final

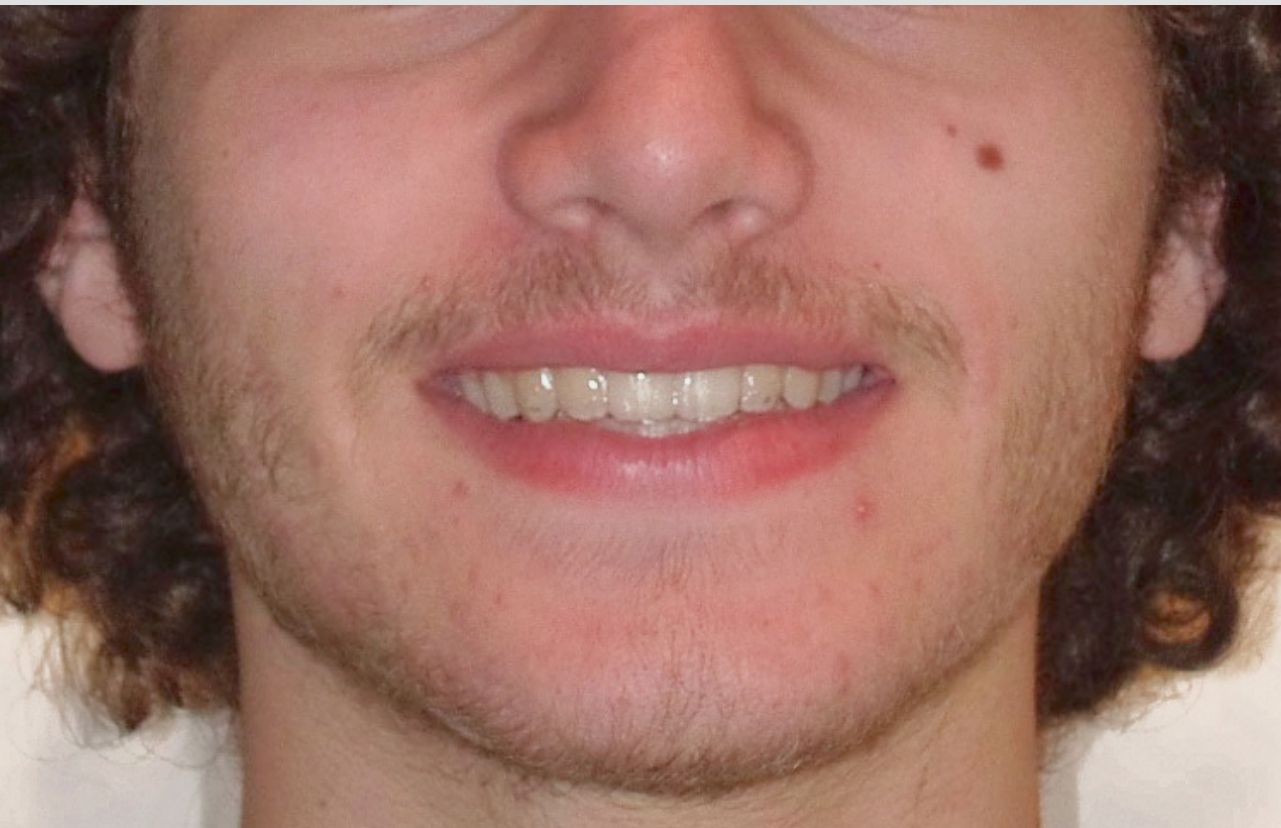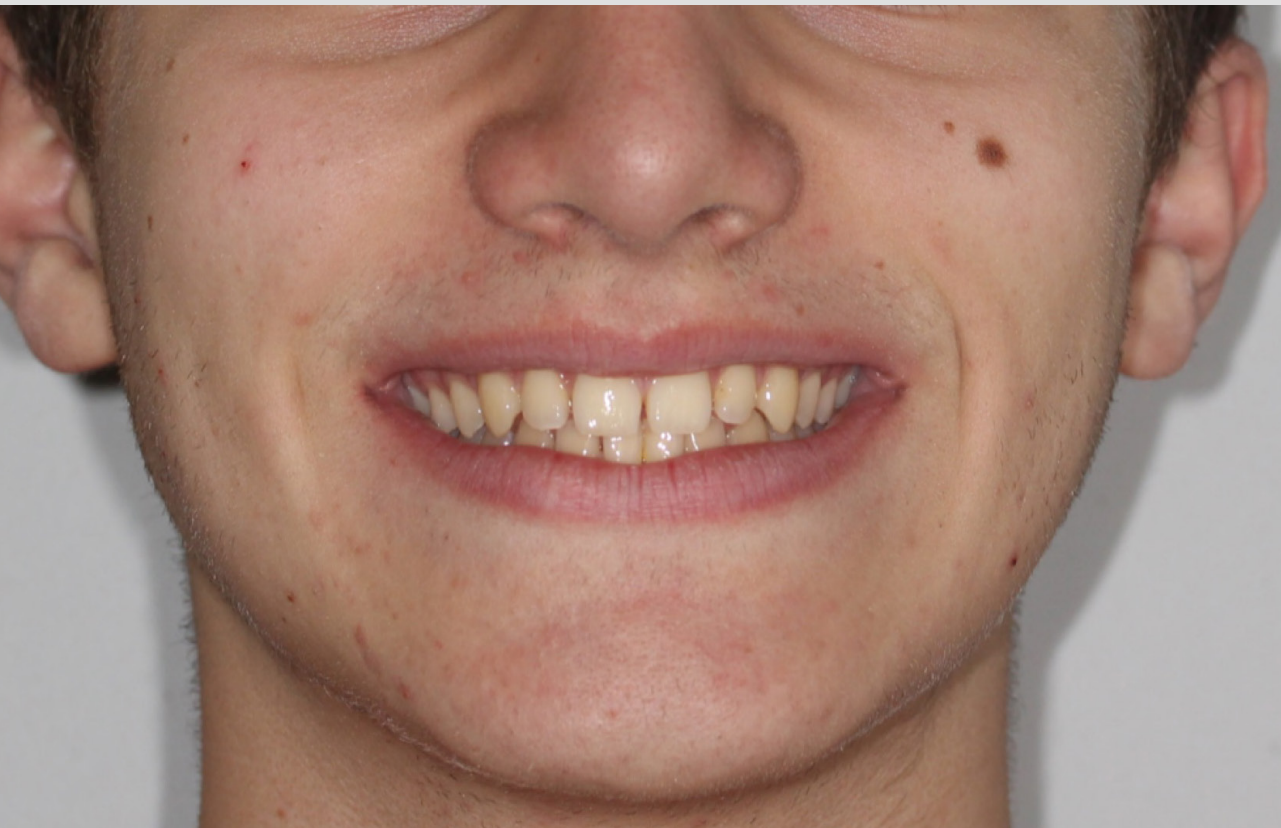Profile at rest



Face at rest



Face smiling

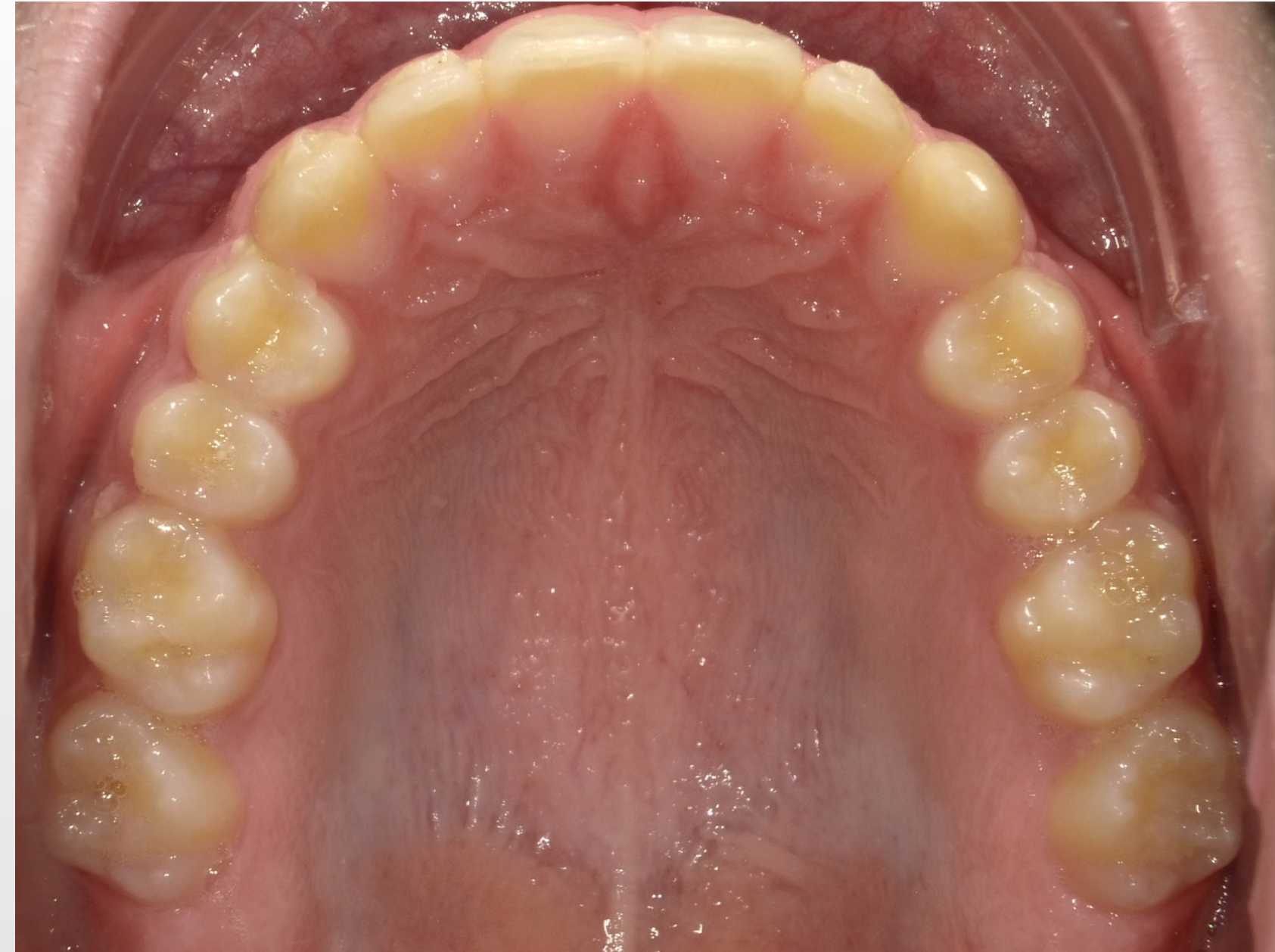
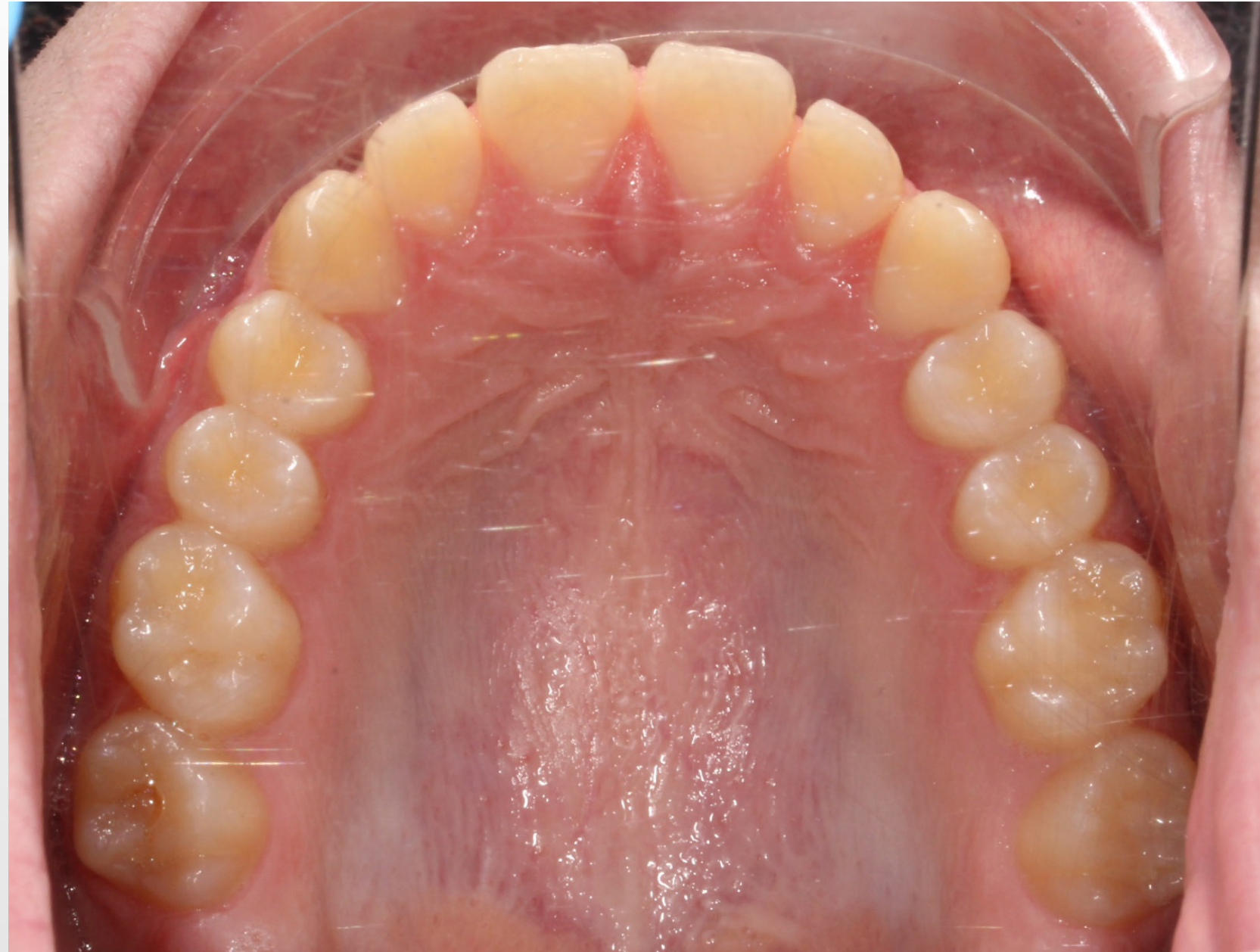



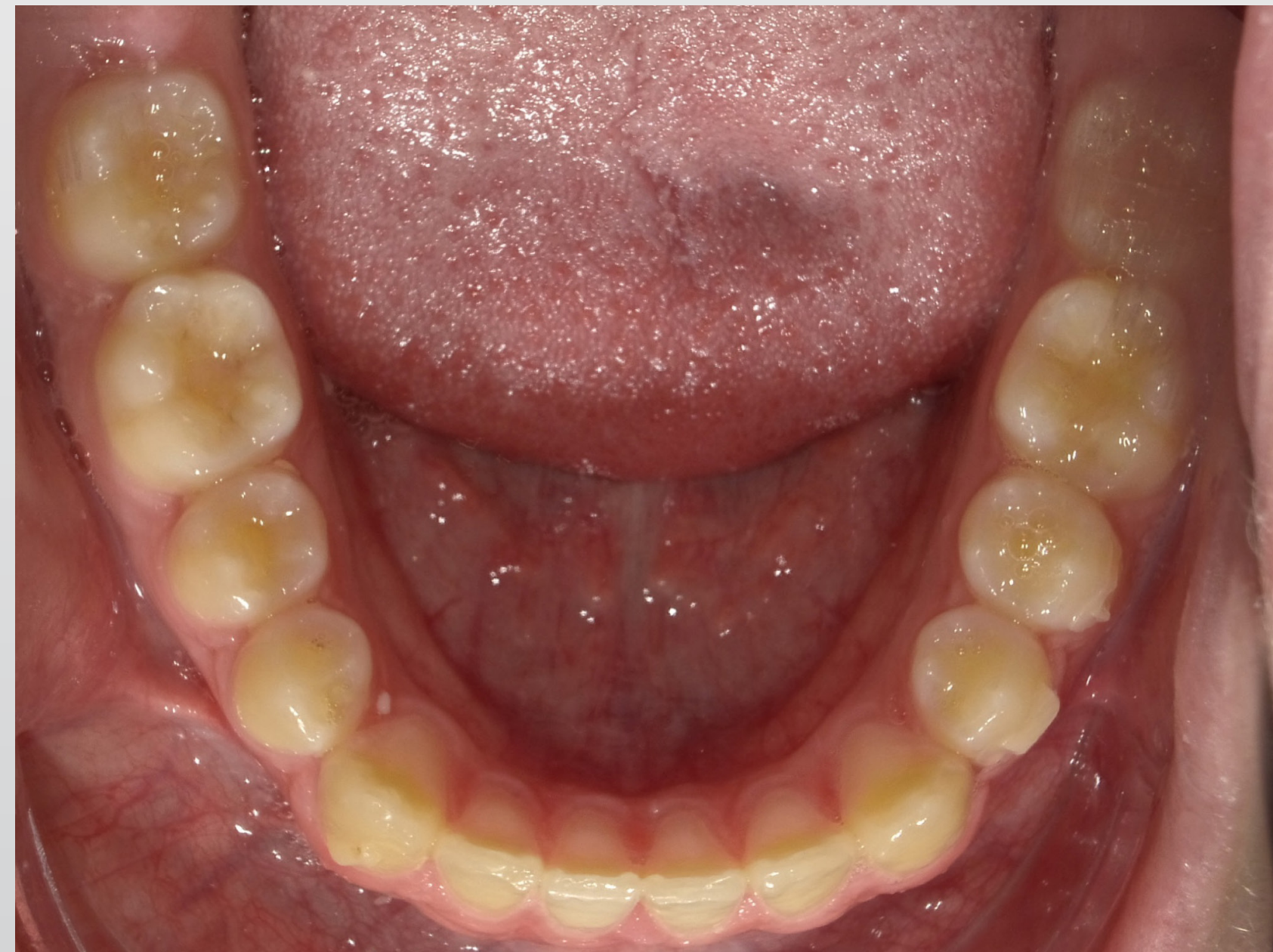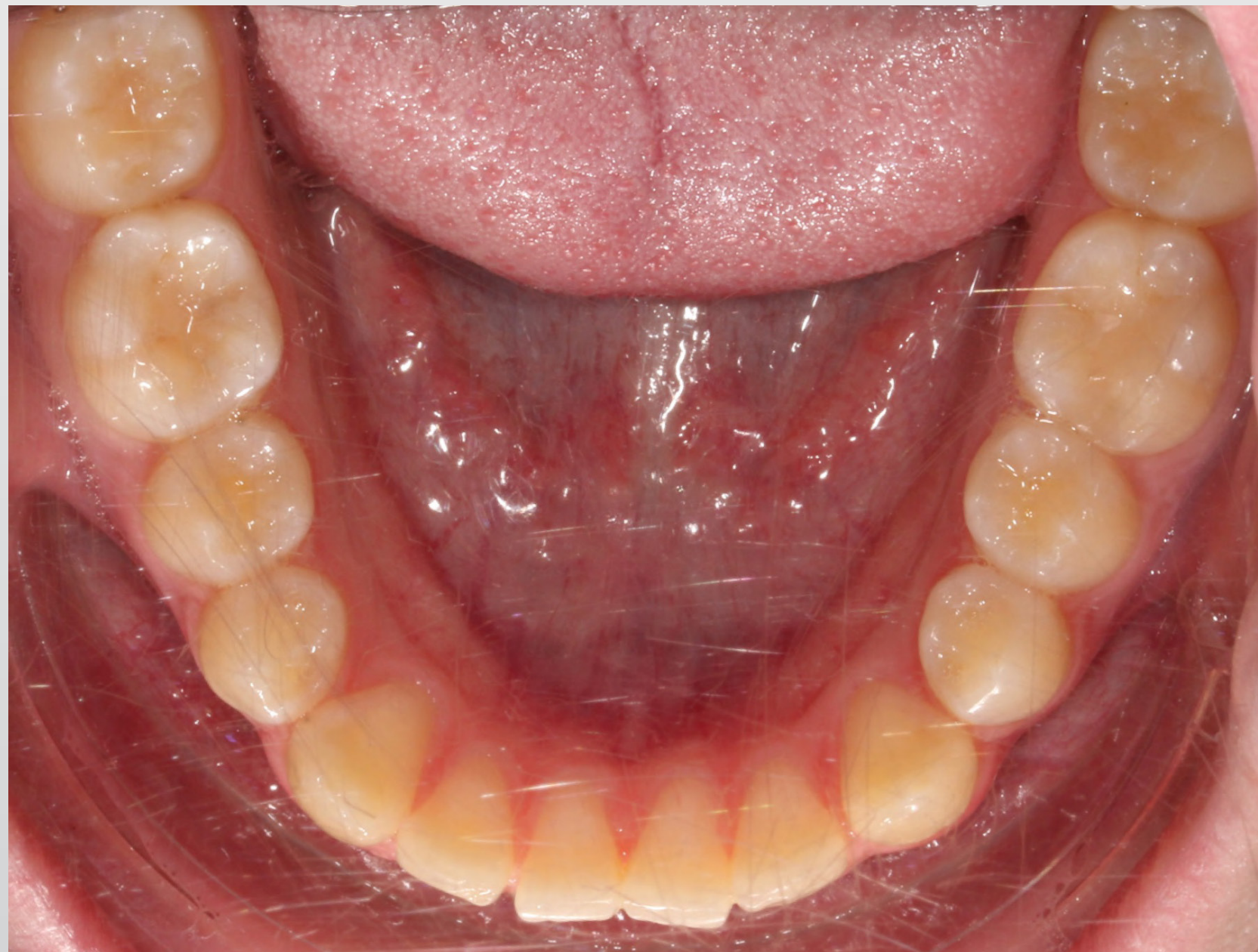**Initial**

**Final**

**Occlusal – maxillary**



**Occlusal – mandibular**

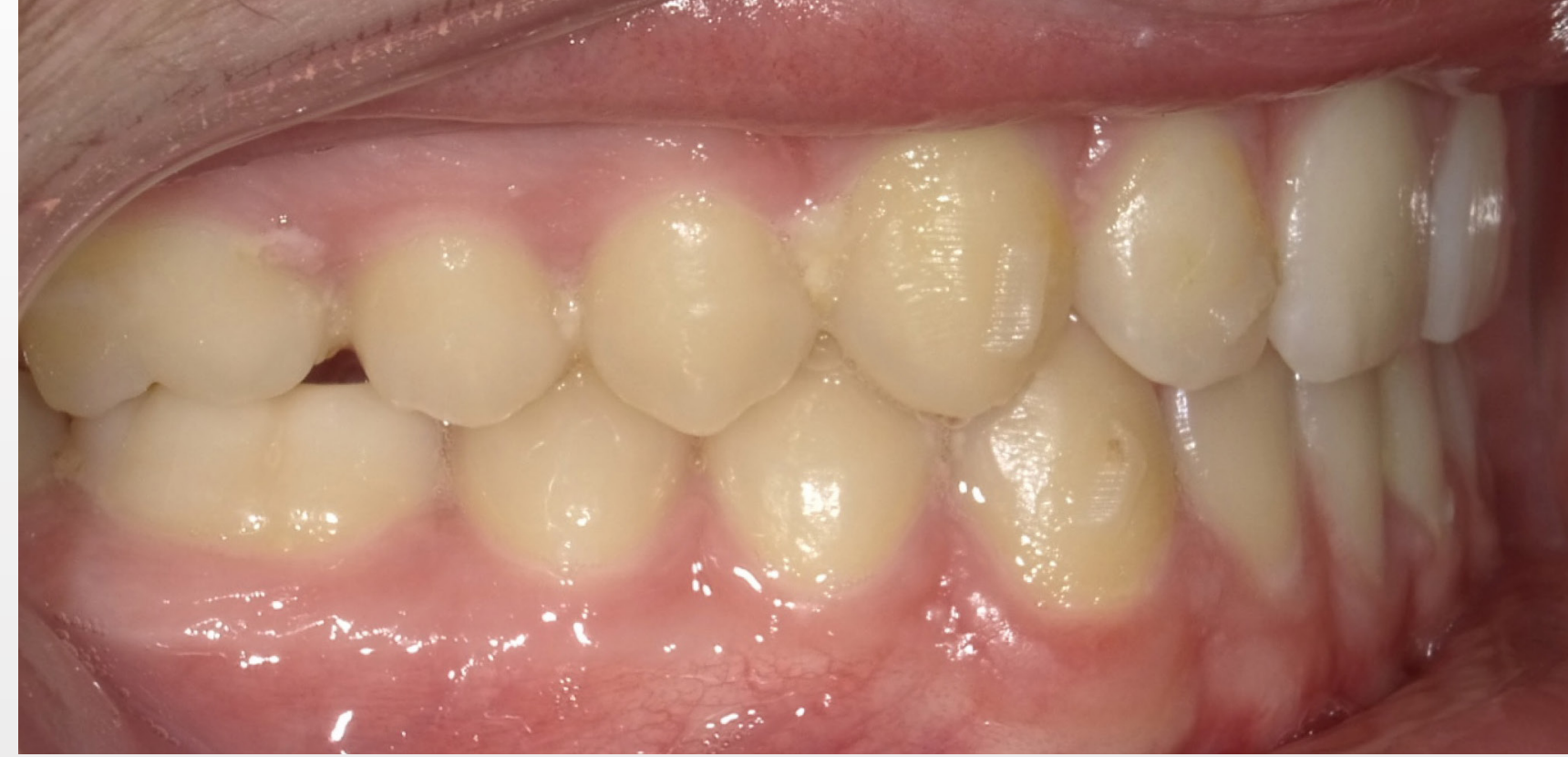
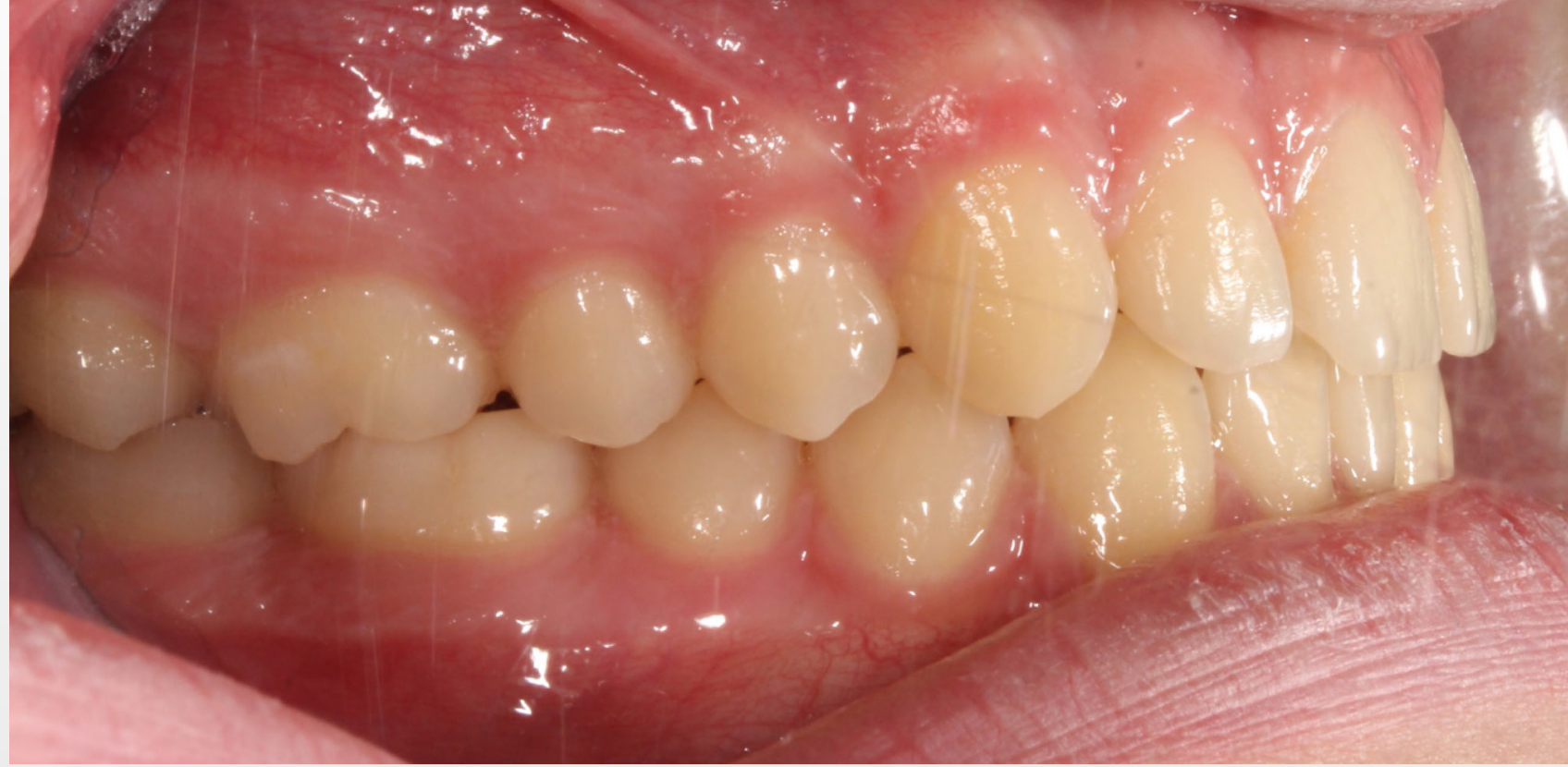


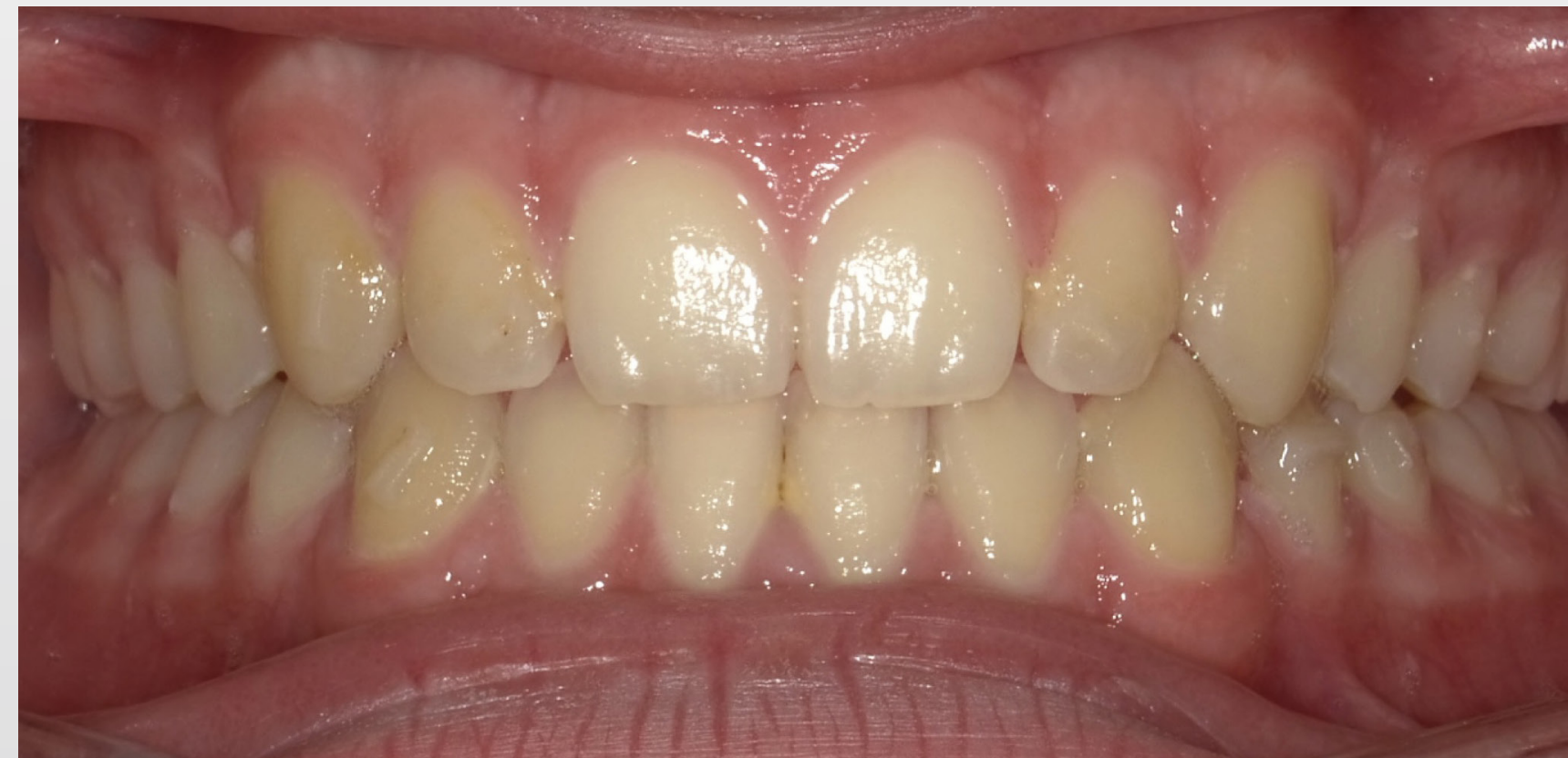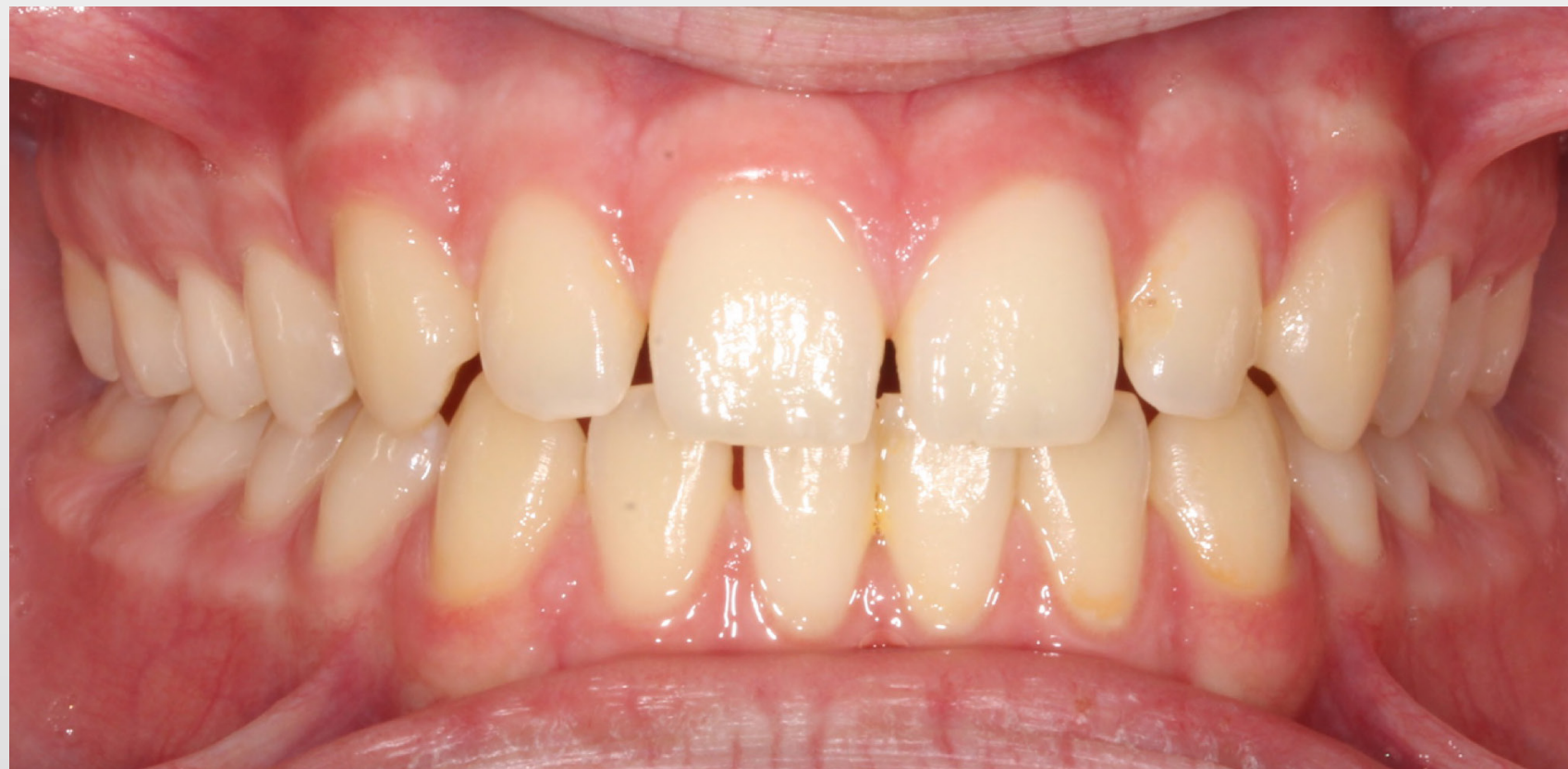**Initial**

**Final**

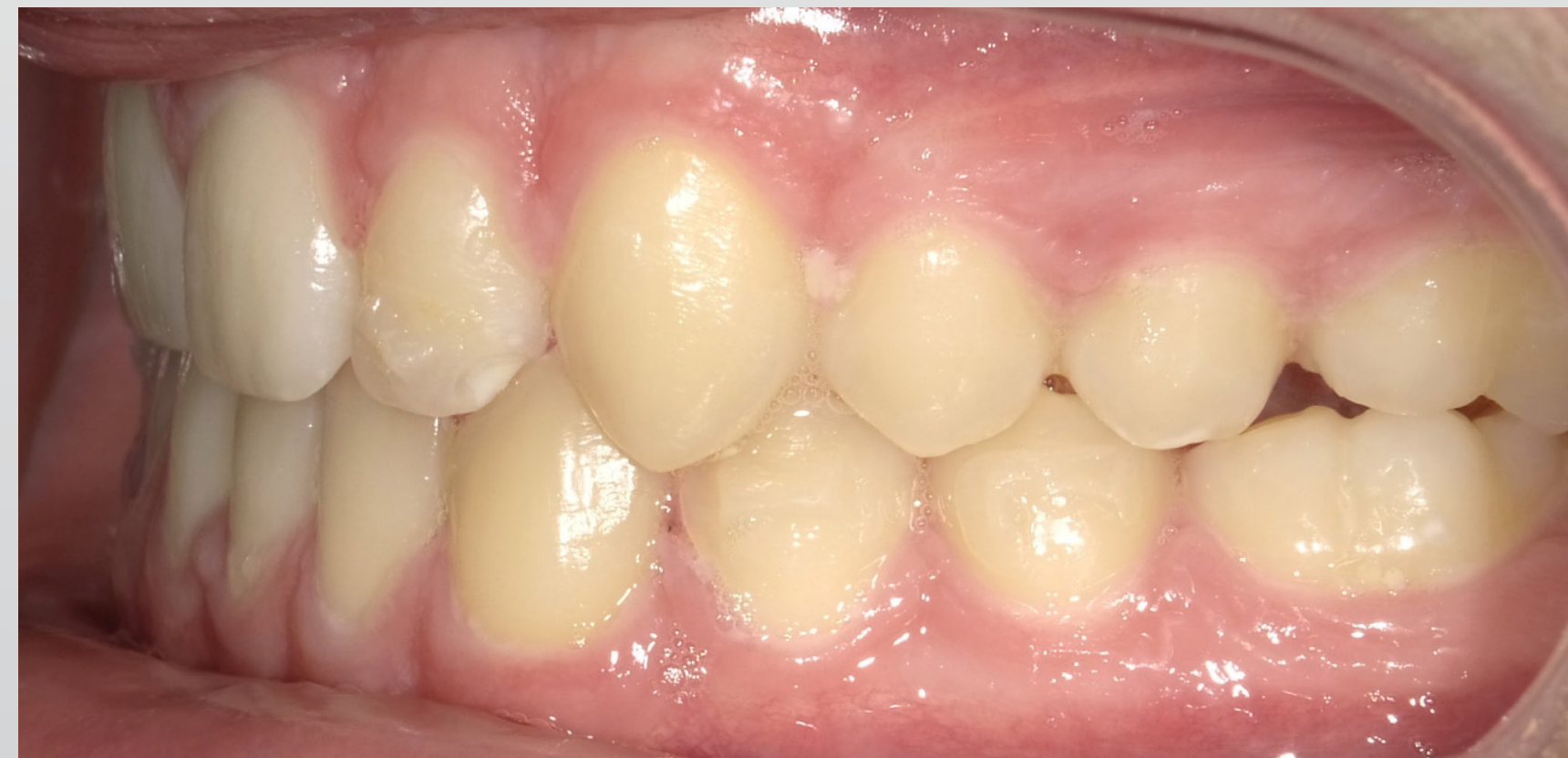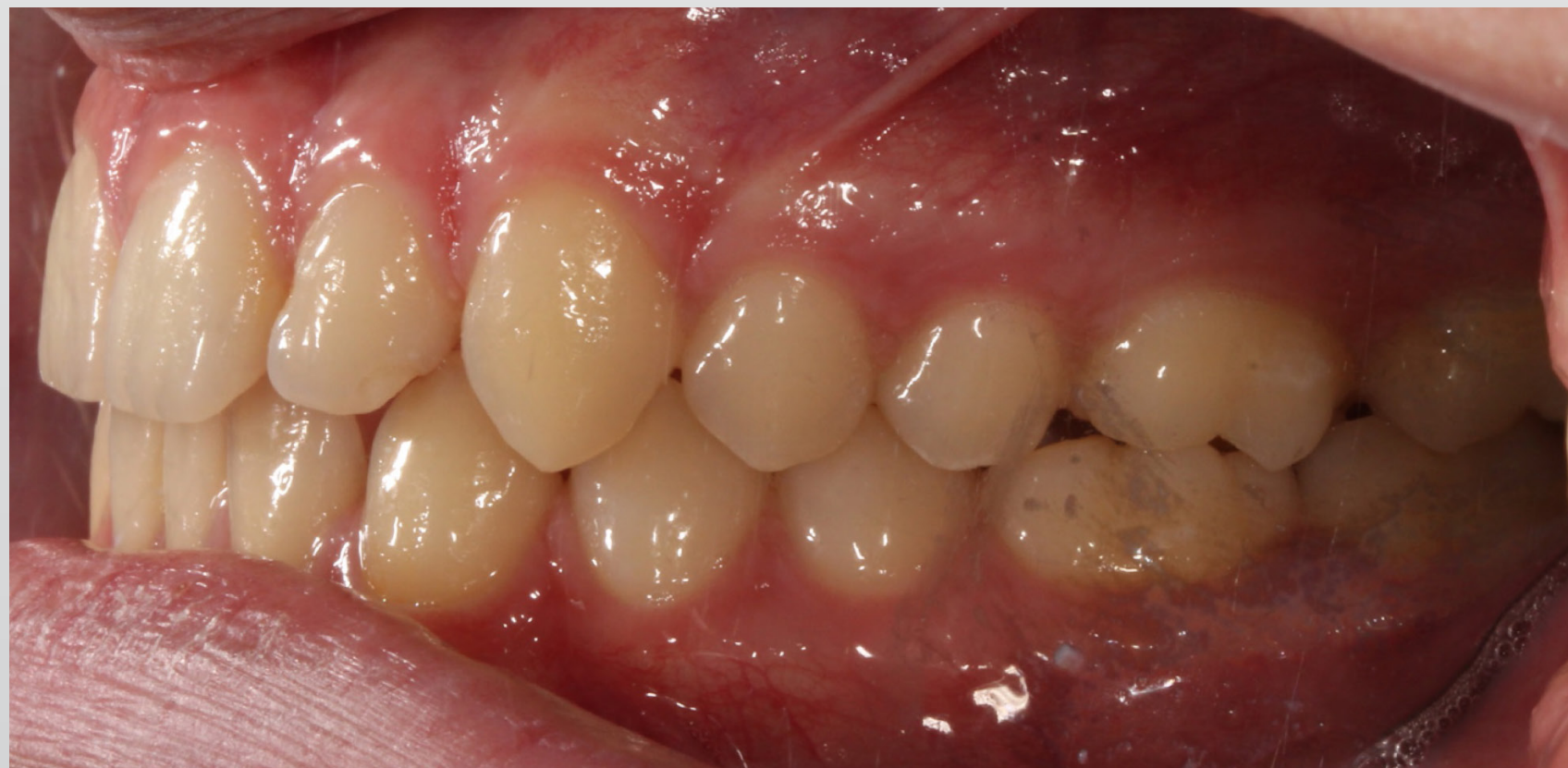**Retracted  
buccal – right**



**Retracted  
anterior biting**



**Retracted  
buccal – left**

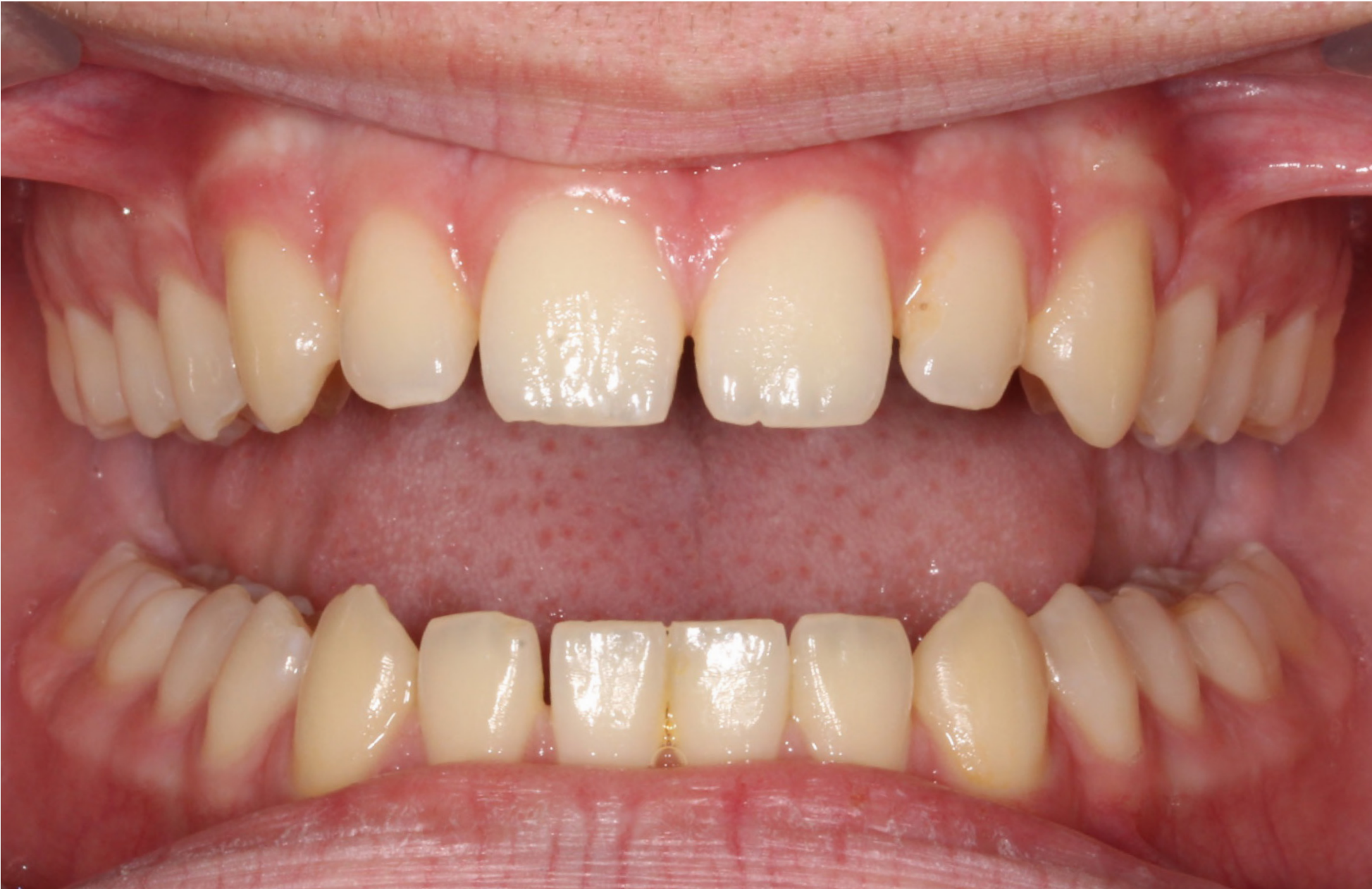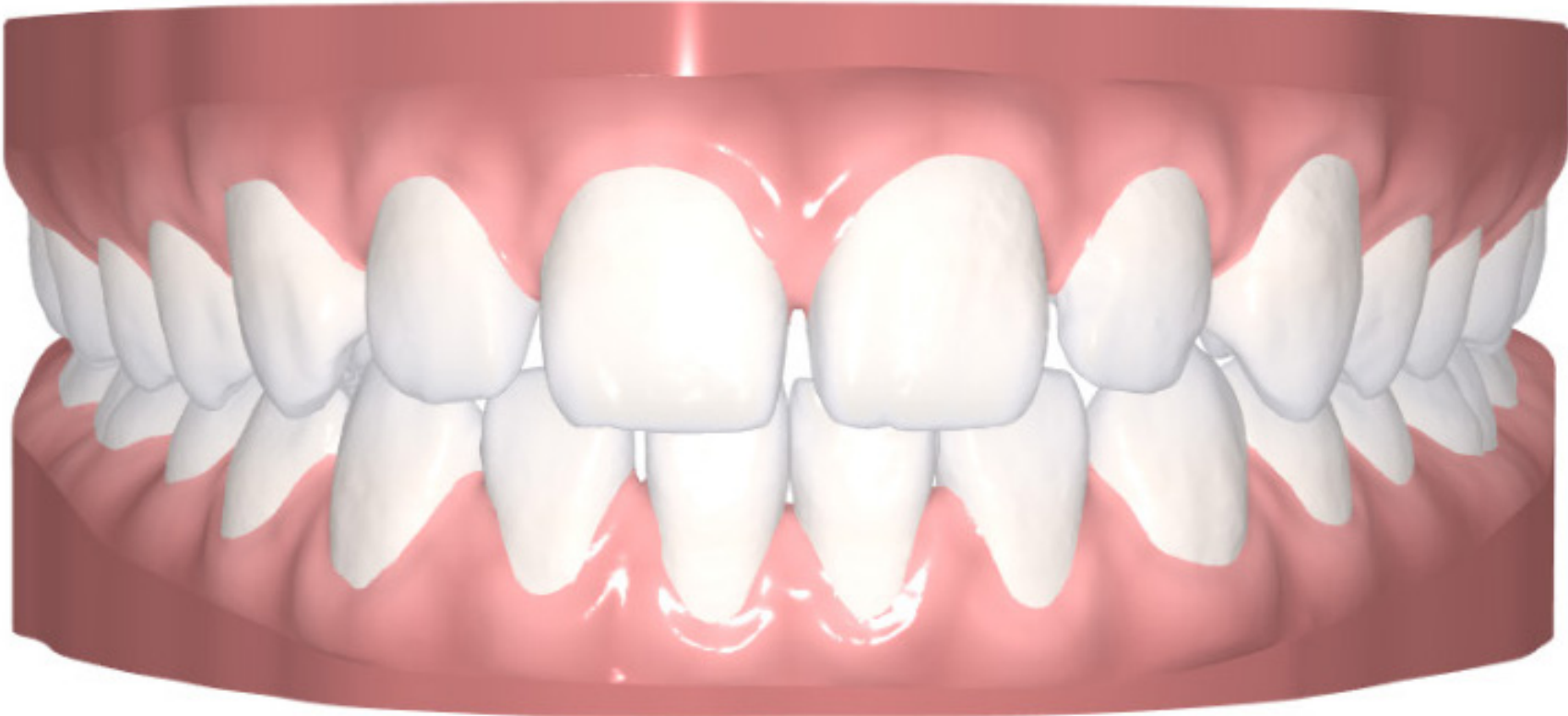




Tx design

Anterior open

Initial



Final

