

Case Study: 3M™ Clarity™ Aligners

Correction of severe anterior spacing and flaring, tipped central incisors and missing upper left 3 with posterior constriction.

Age: 32

Original malocclusion: Class I right and Class II left

Total number of aligners: 30 (dual arch)

Wear interval: Weekly

Treatment time: 8 months

IPR: Total IPR Upper Arch = 0.4 mm

Total IPR Lower Arch = 1.5 mm

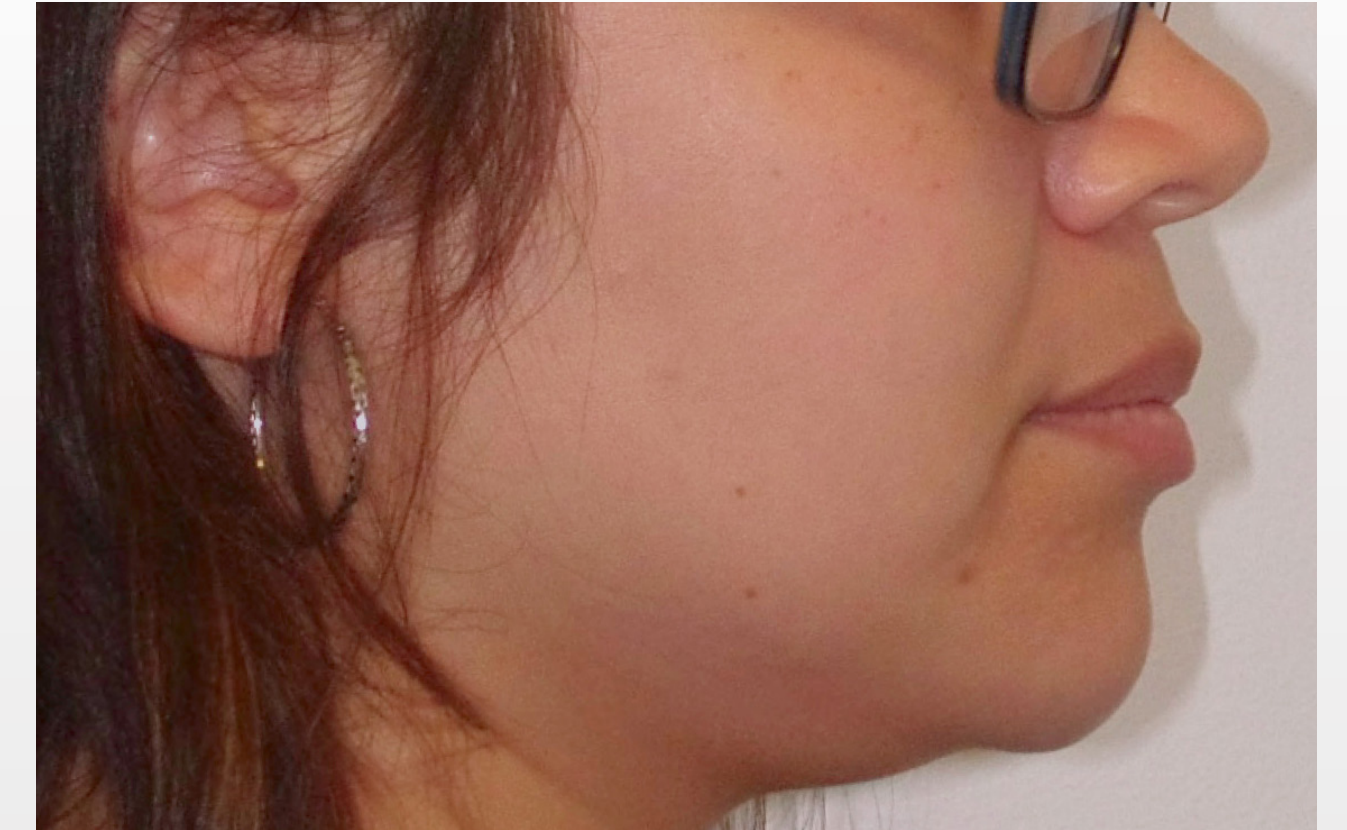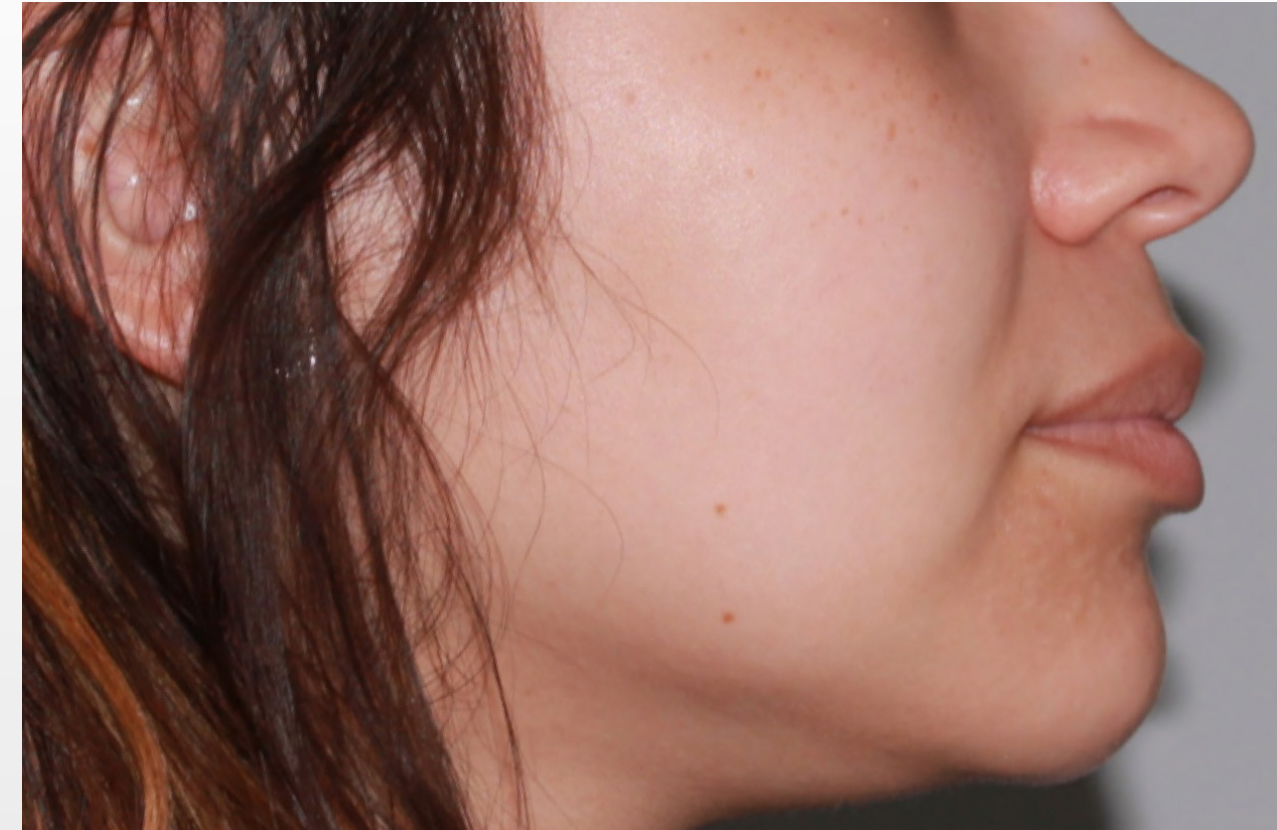By Stage	Entire Case															
	Total IPR Upper Arch = 0.4mm								Total IPR Lower Arch = 1.5mm							
	R8	R7	R6	R5	R4	R3	R2	R1	L1	L2	L3	L4	L5	L6	L7	L8
Upper Arch								.4								
Lower Arch					.3	.5	.5	.2								

Case courtesy of:
Dr. Adam Schuhof
Oradell, NJ – USA

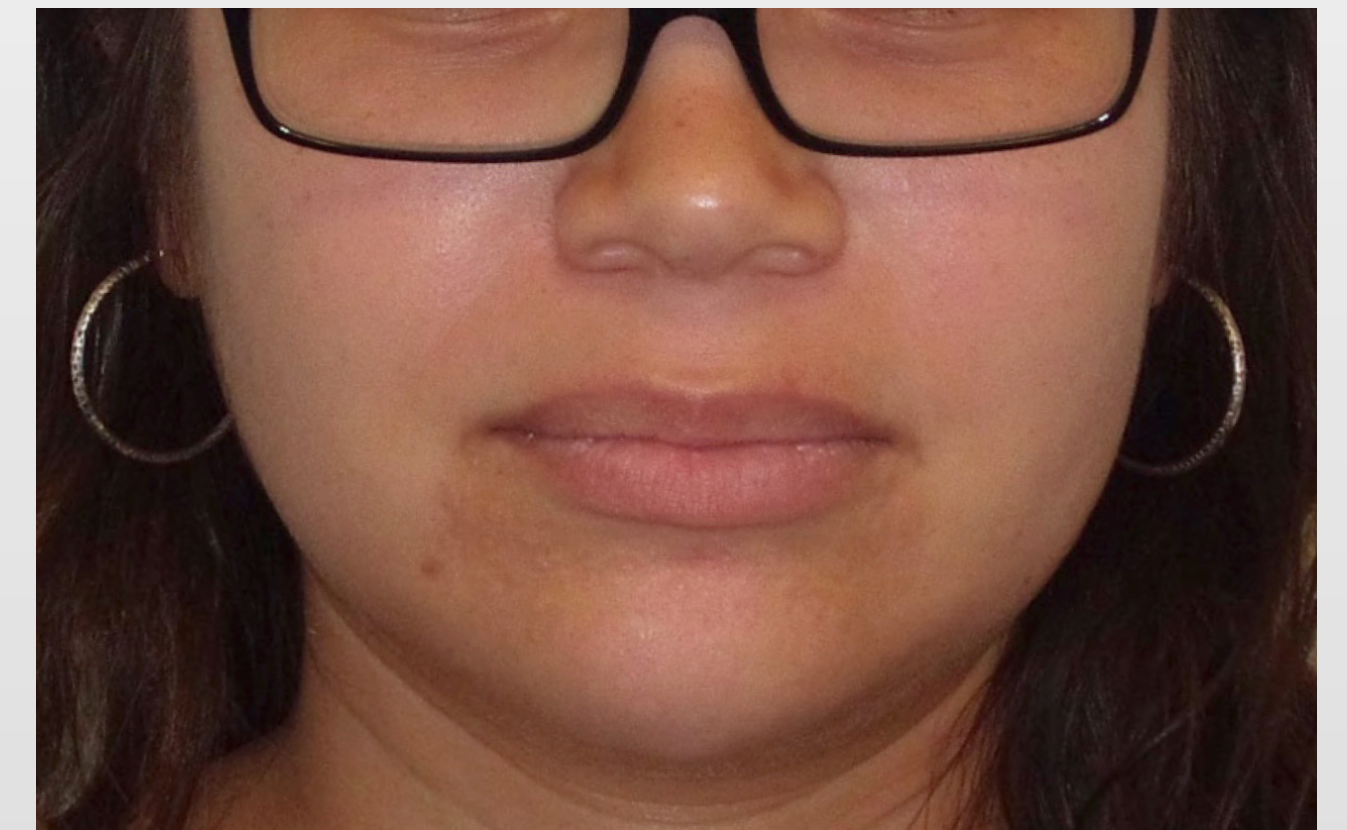
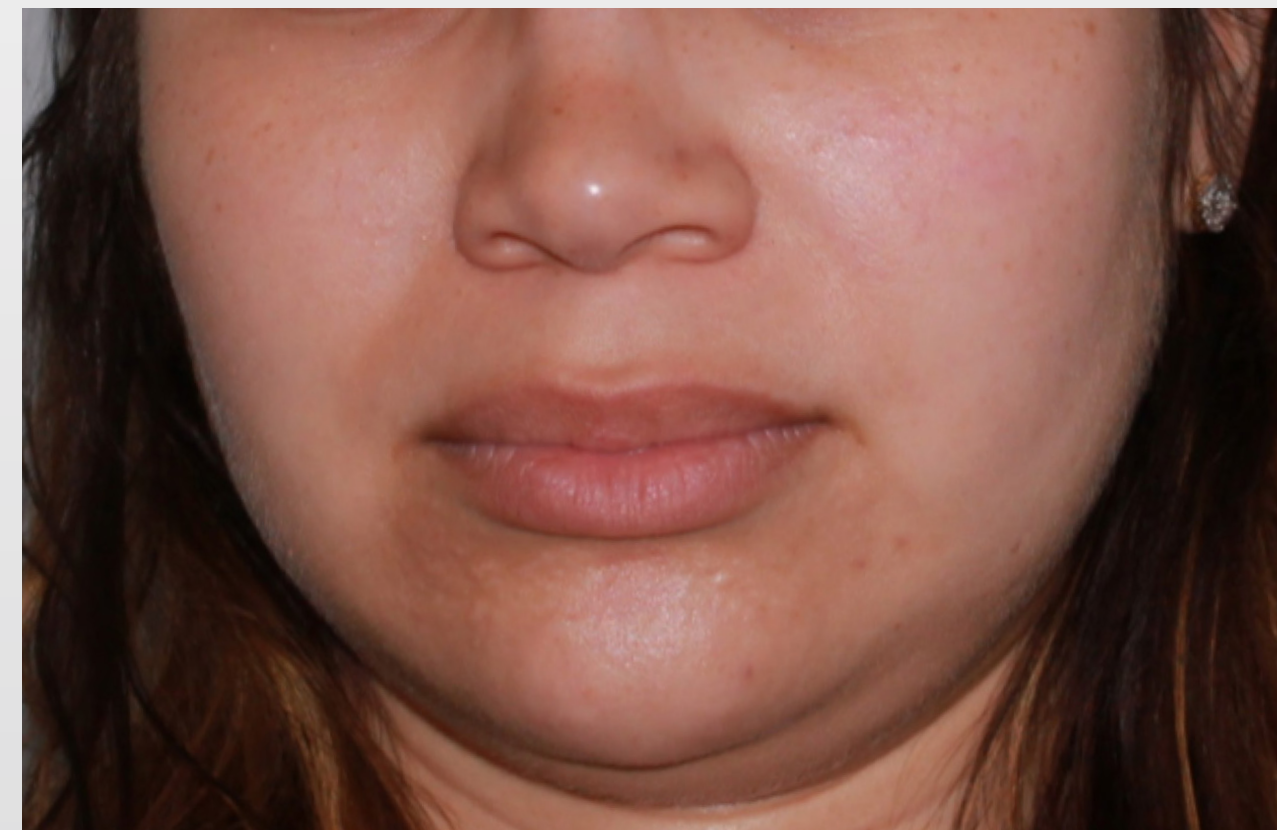Initial

Final

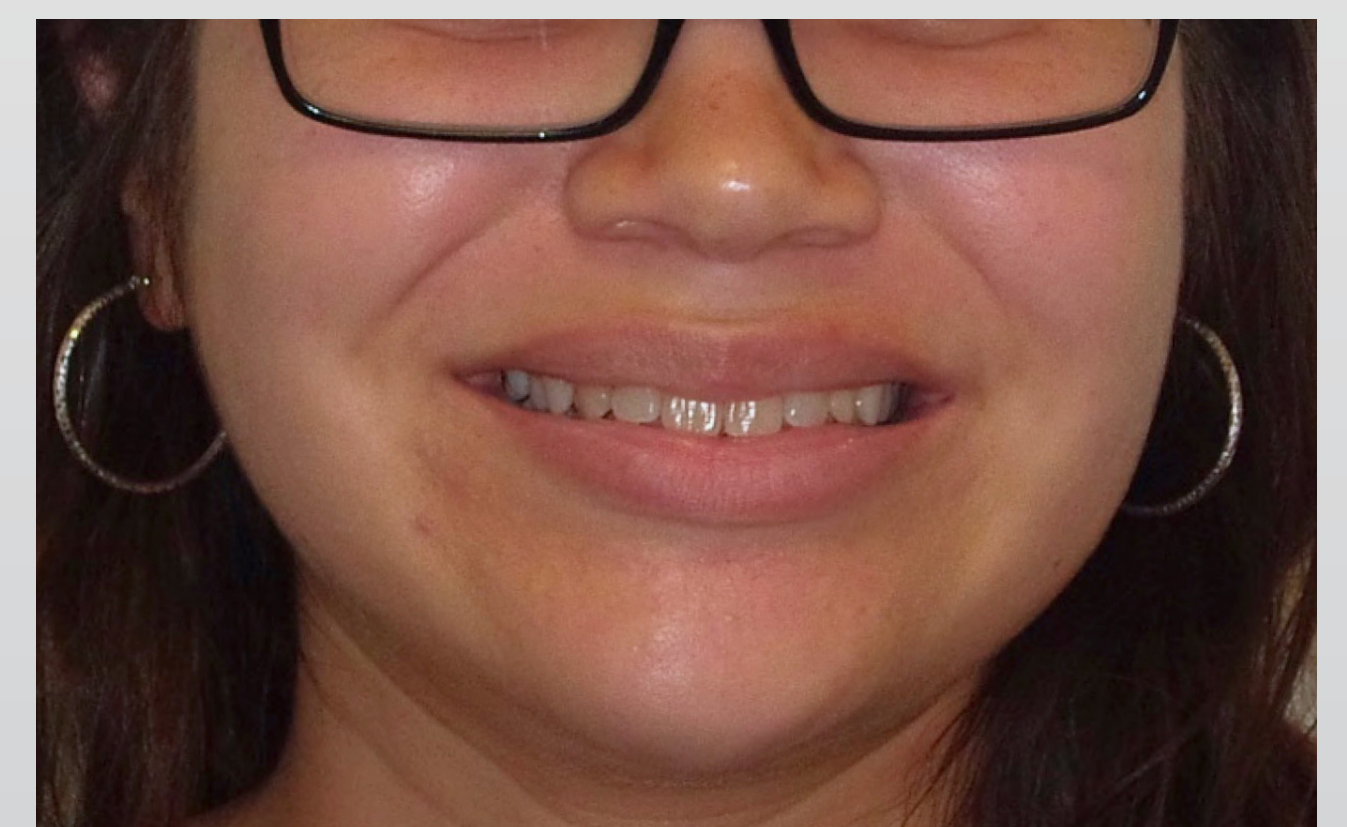
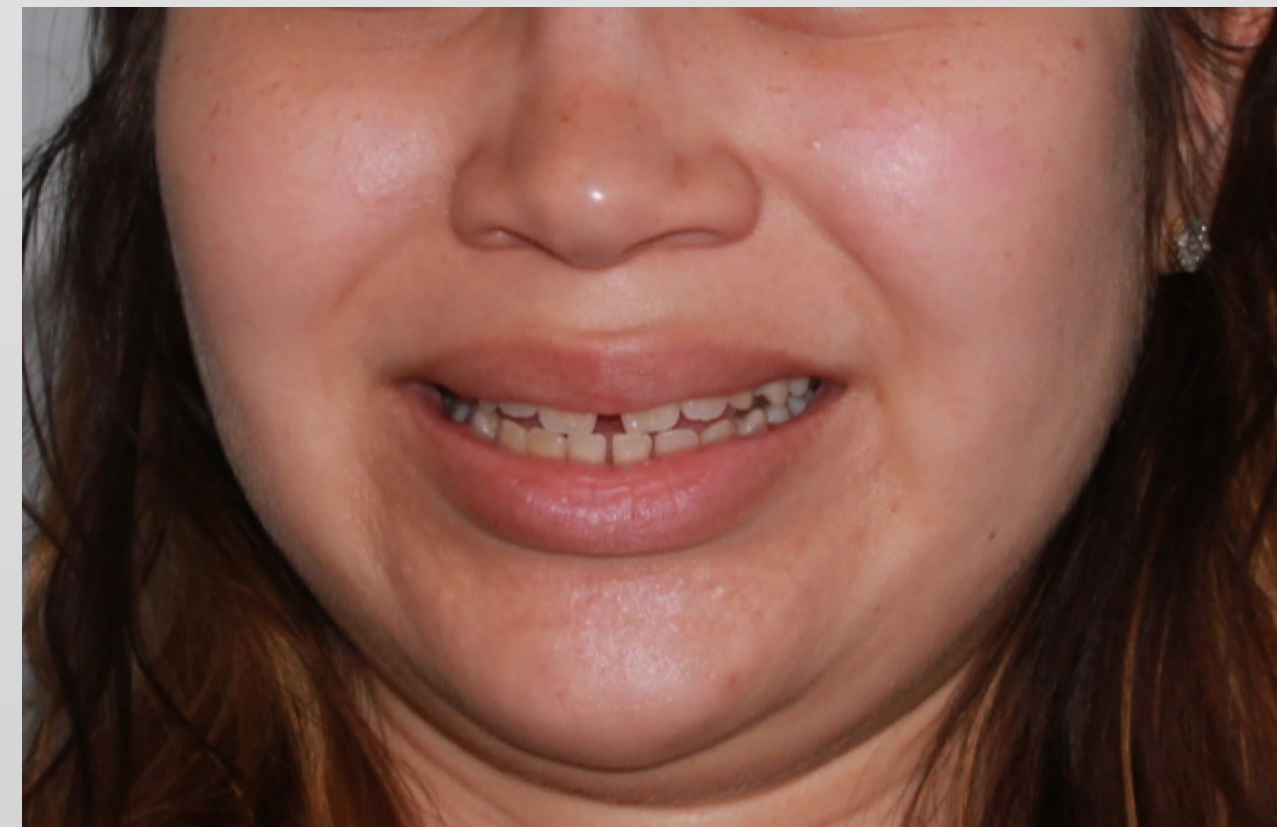Profile at rest



Face at rest



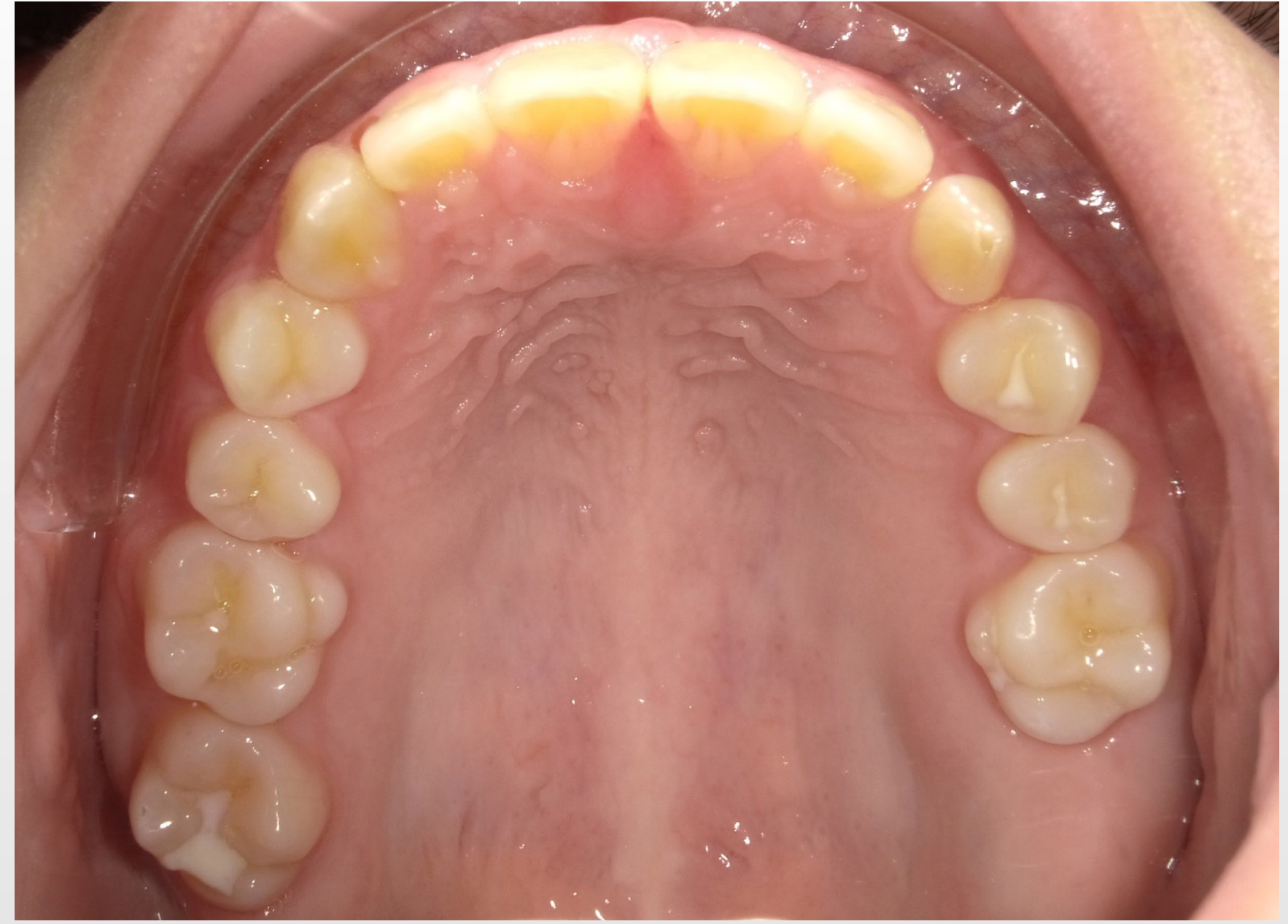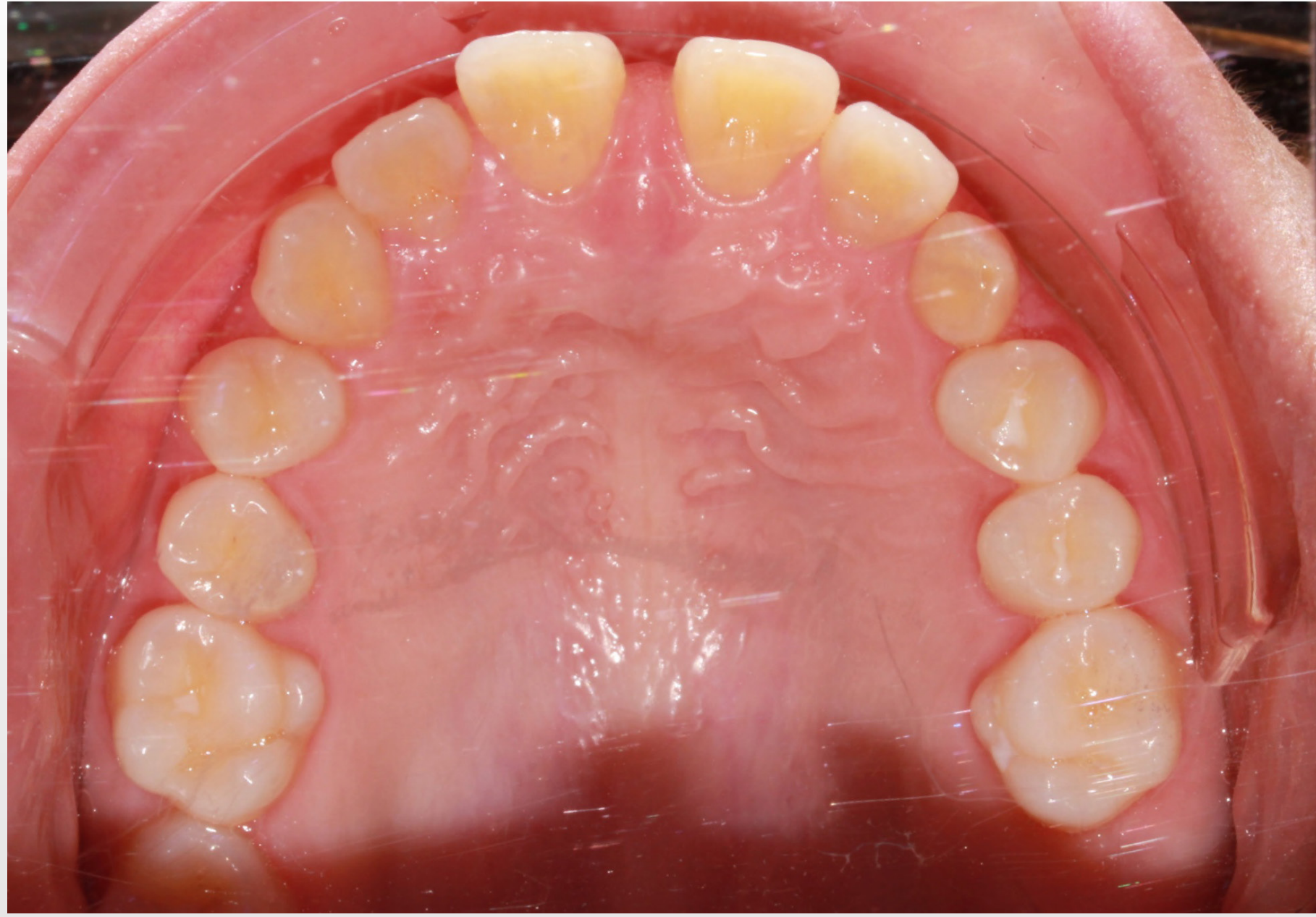Face smiling



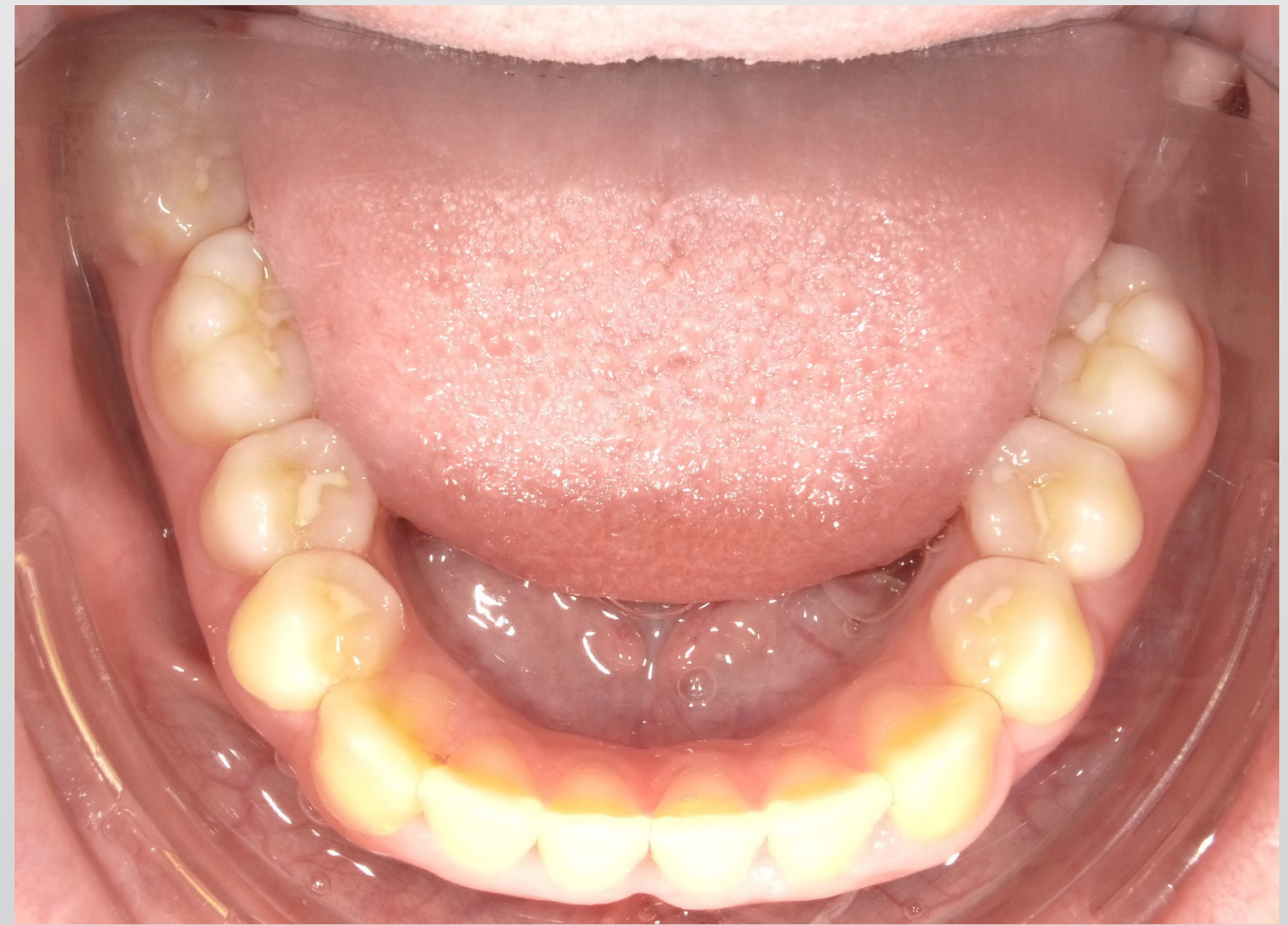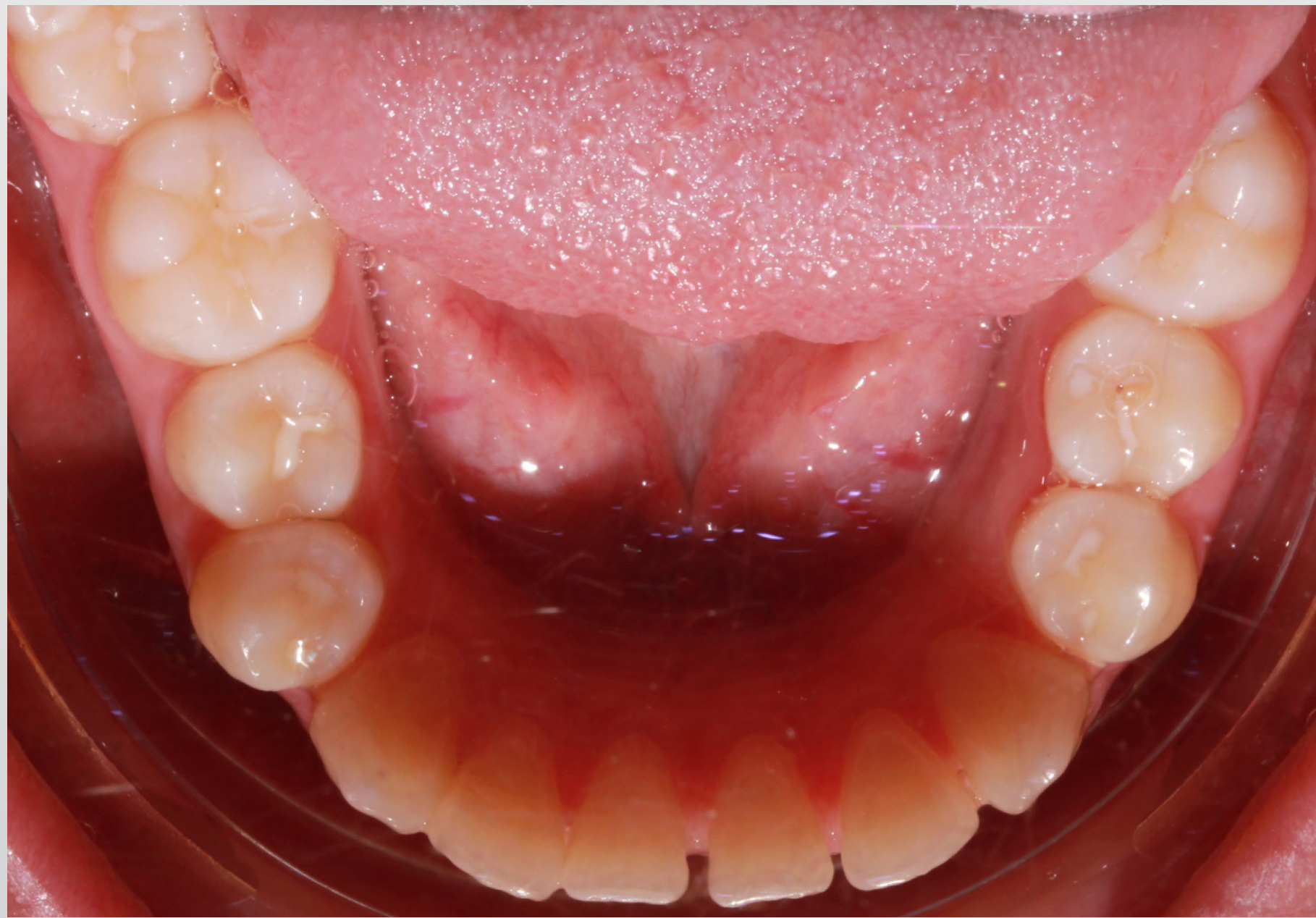Initial

Final

**Occlusal –
maxillary**



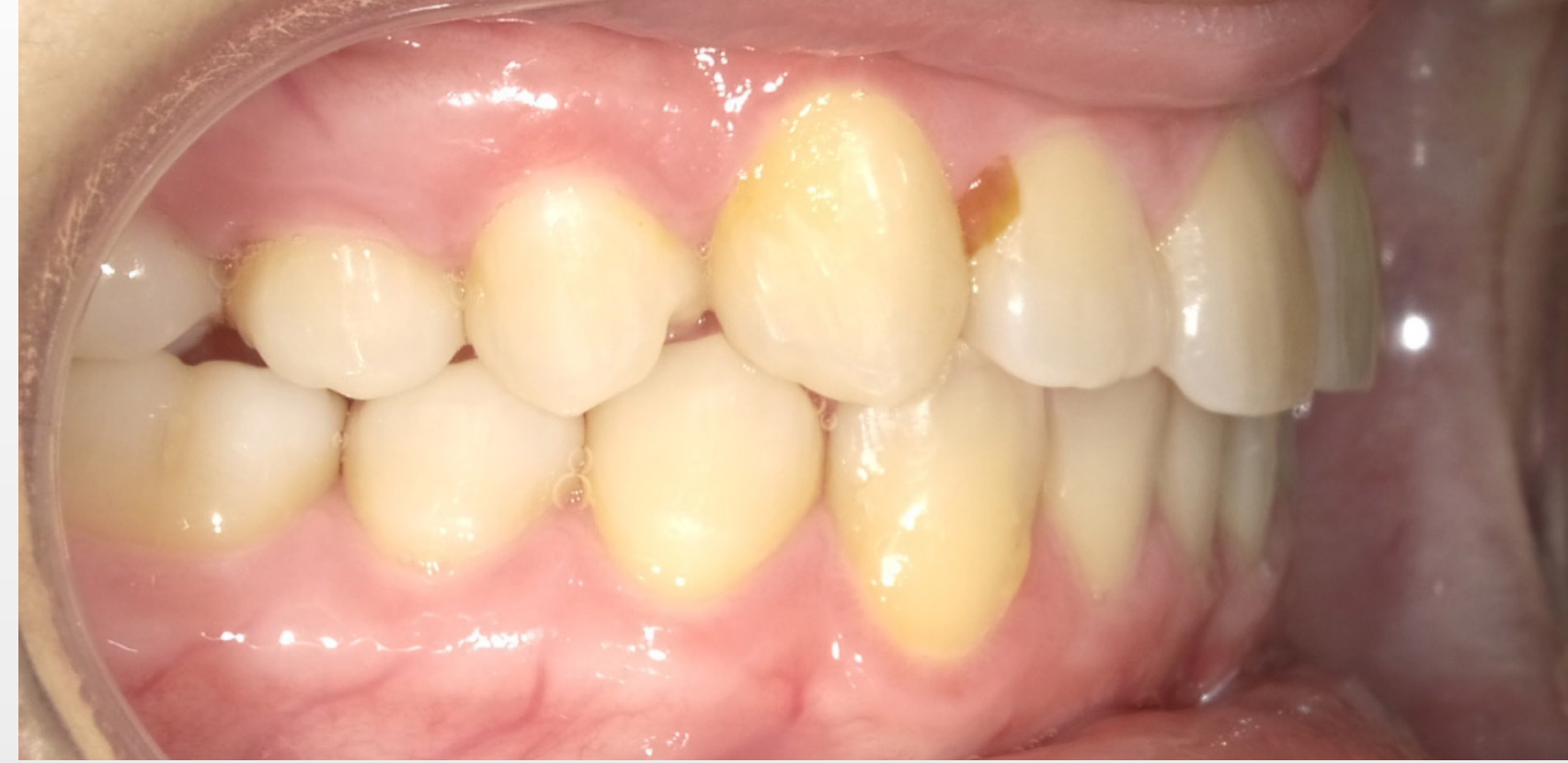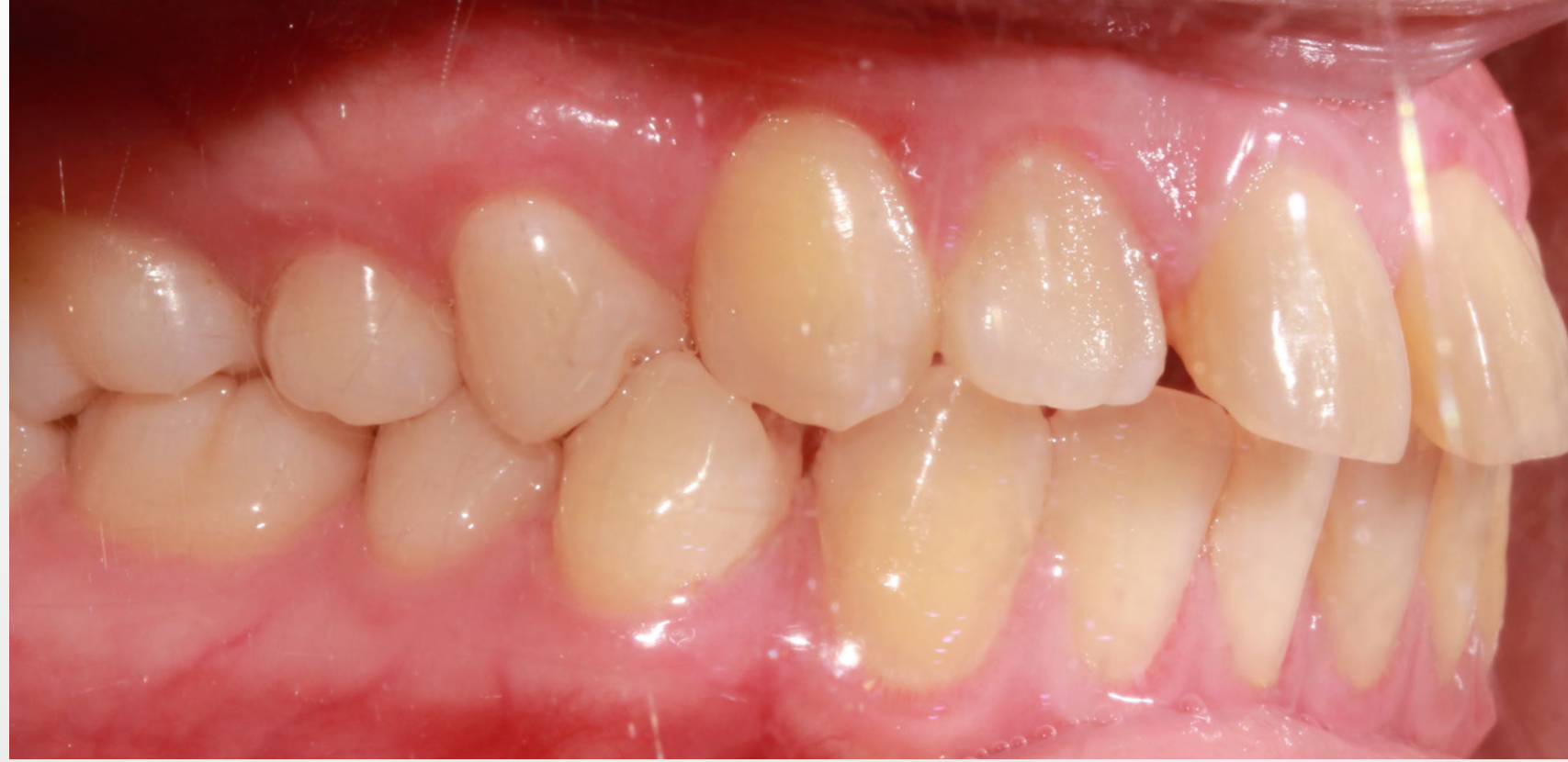**Occlusal –
mandibular**



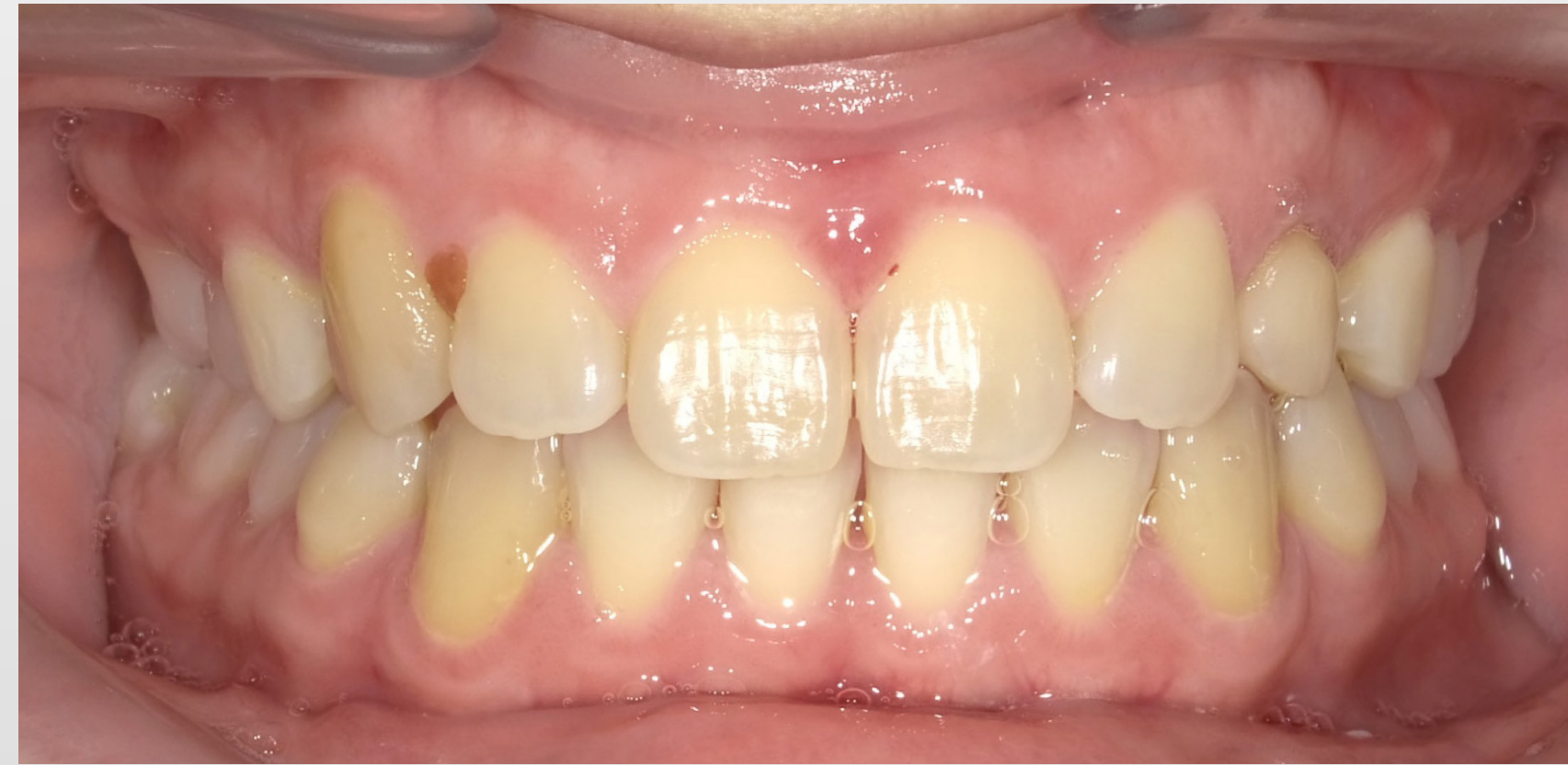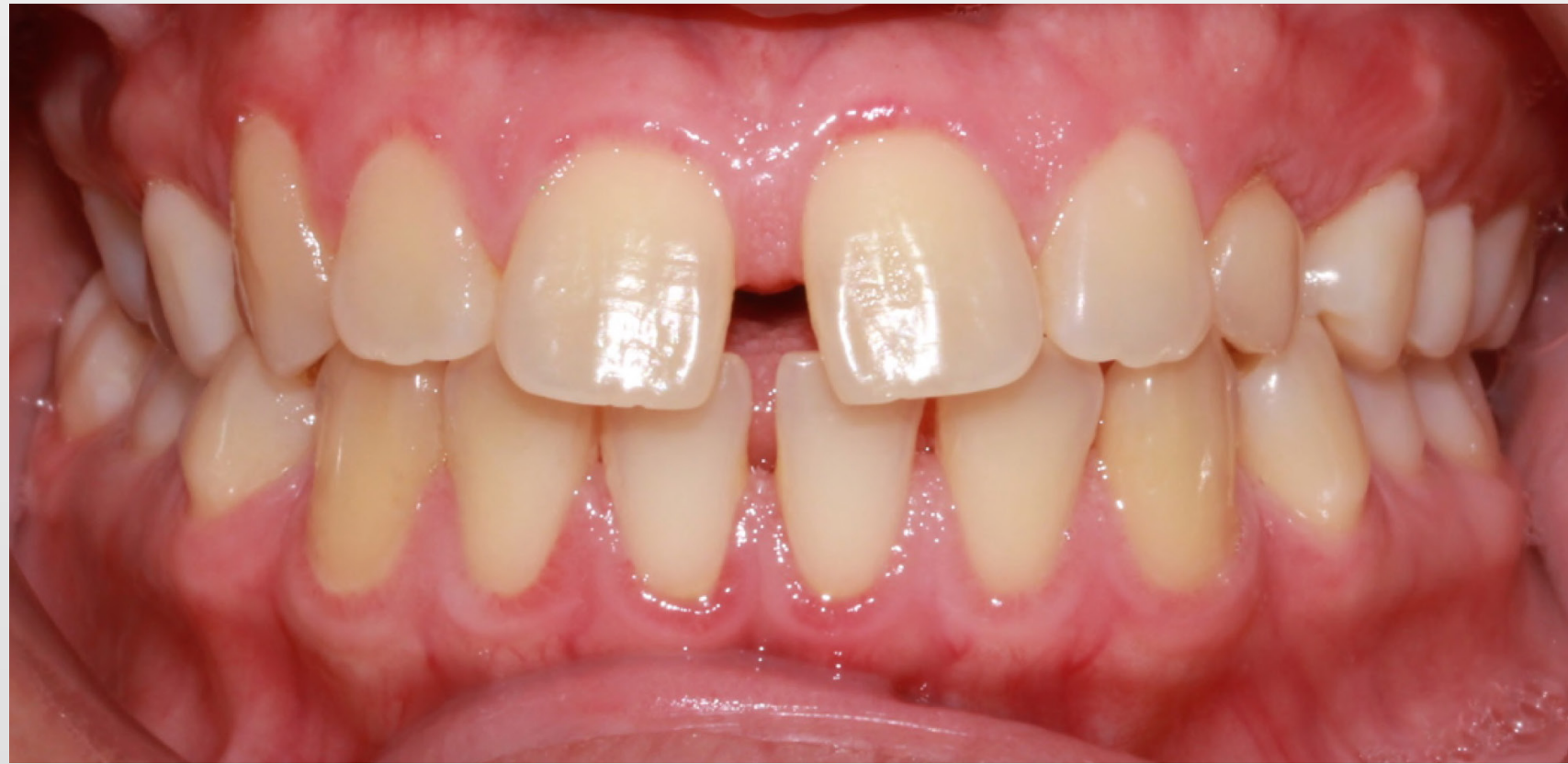Initial

Final

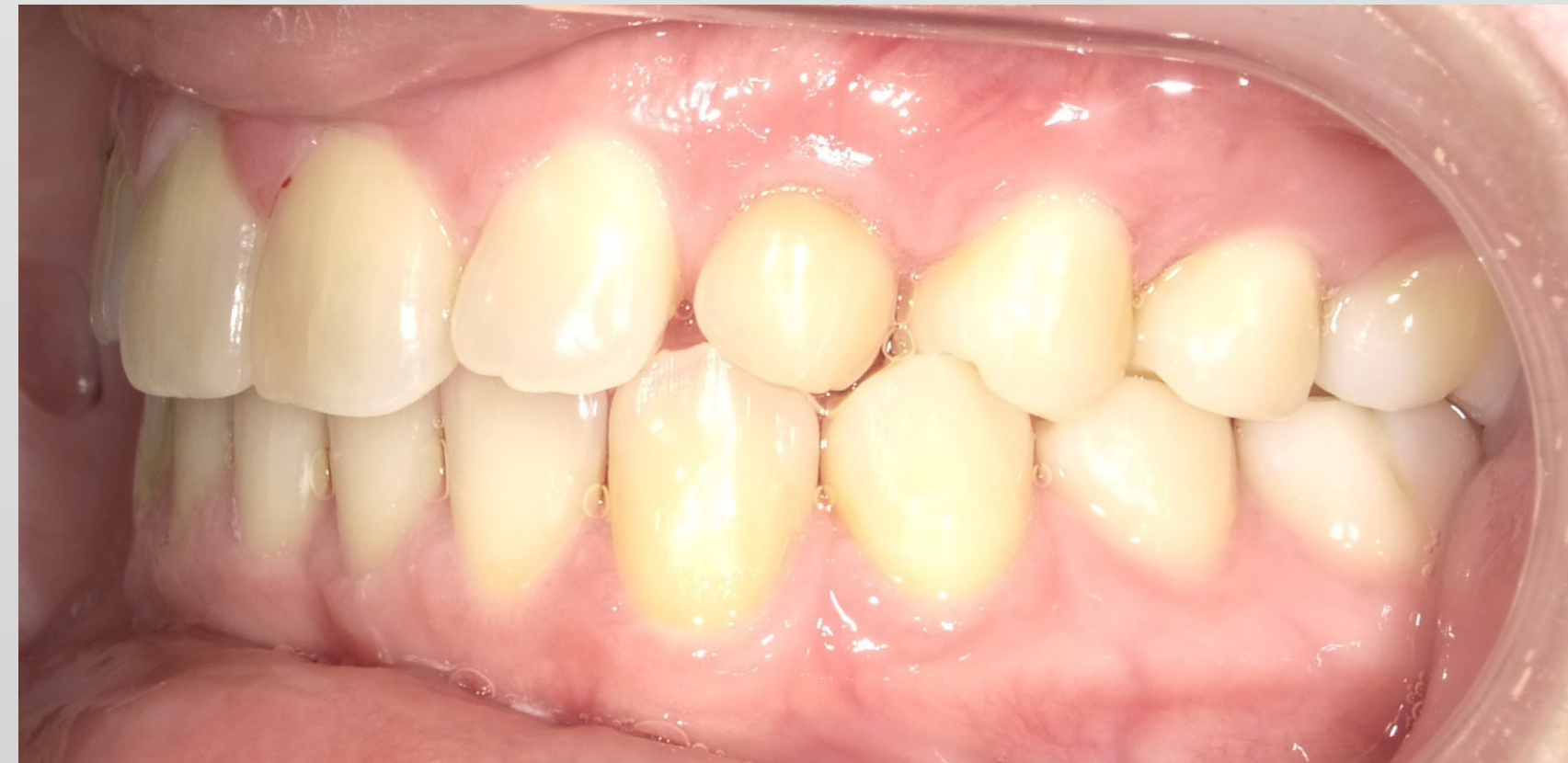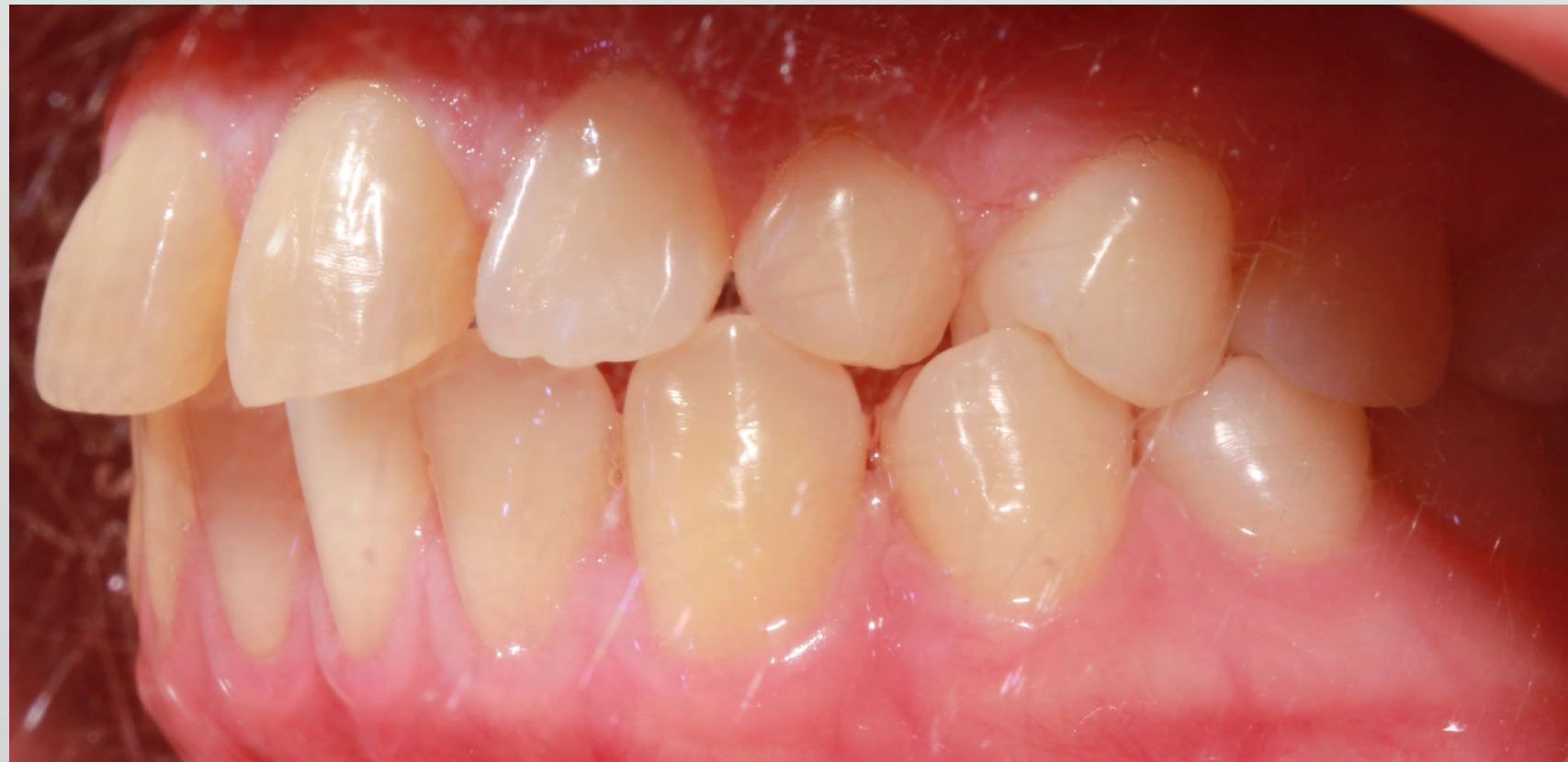**Retracted
buccal – right**



**Retracted
anterior biting**



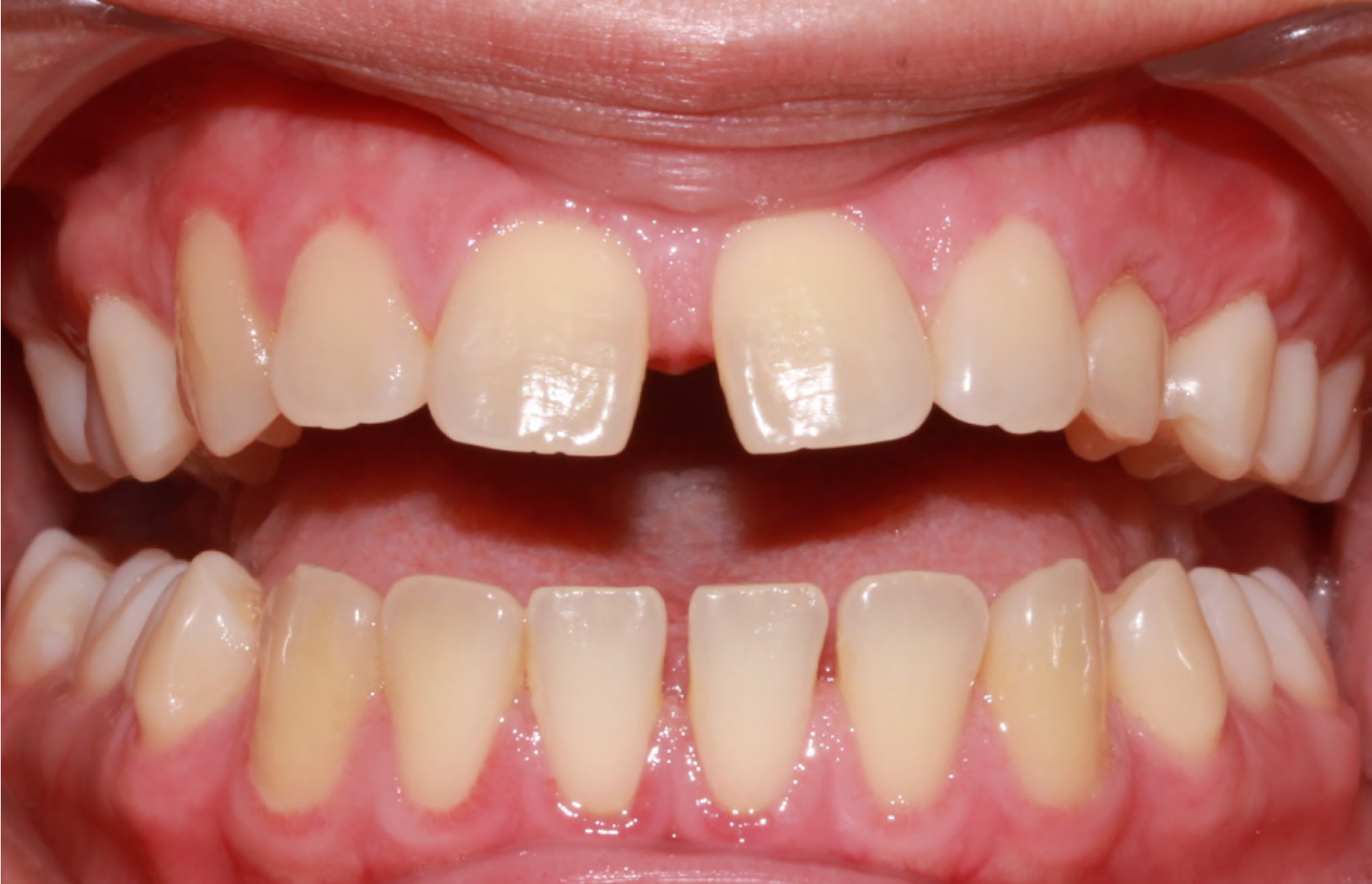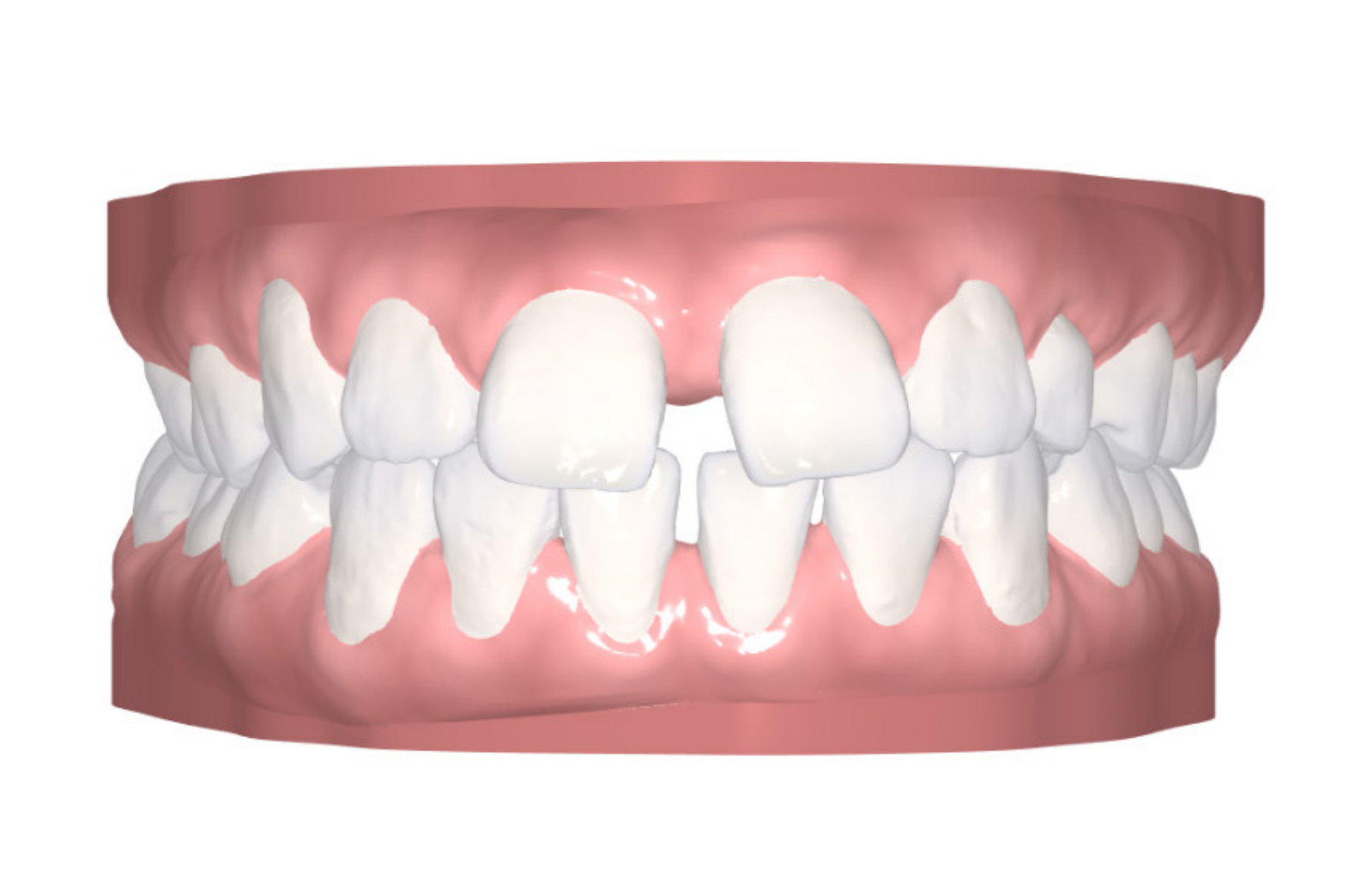
**Retracted
buccal – left**



Tx design

Anterior open

Initial



Final



