

Case Study: 3M[™] Clarity[™] Aligners

Achieved midline correction,
left side crossbite, deep bite,
and retroclined incisors.
Held space for bonding due
to undersized laterals.

Age: 15

Original malocclusion: Class I molar relationship
with posterior and anterior crossbite on left side

Total number of aligners: 36 stages (dual arch)

Wear interval: Weekly

Treatment time: 9 months

IPR: Total IPR Lower Arch = 2.4 mm

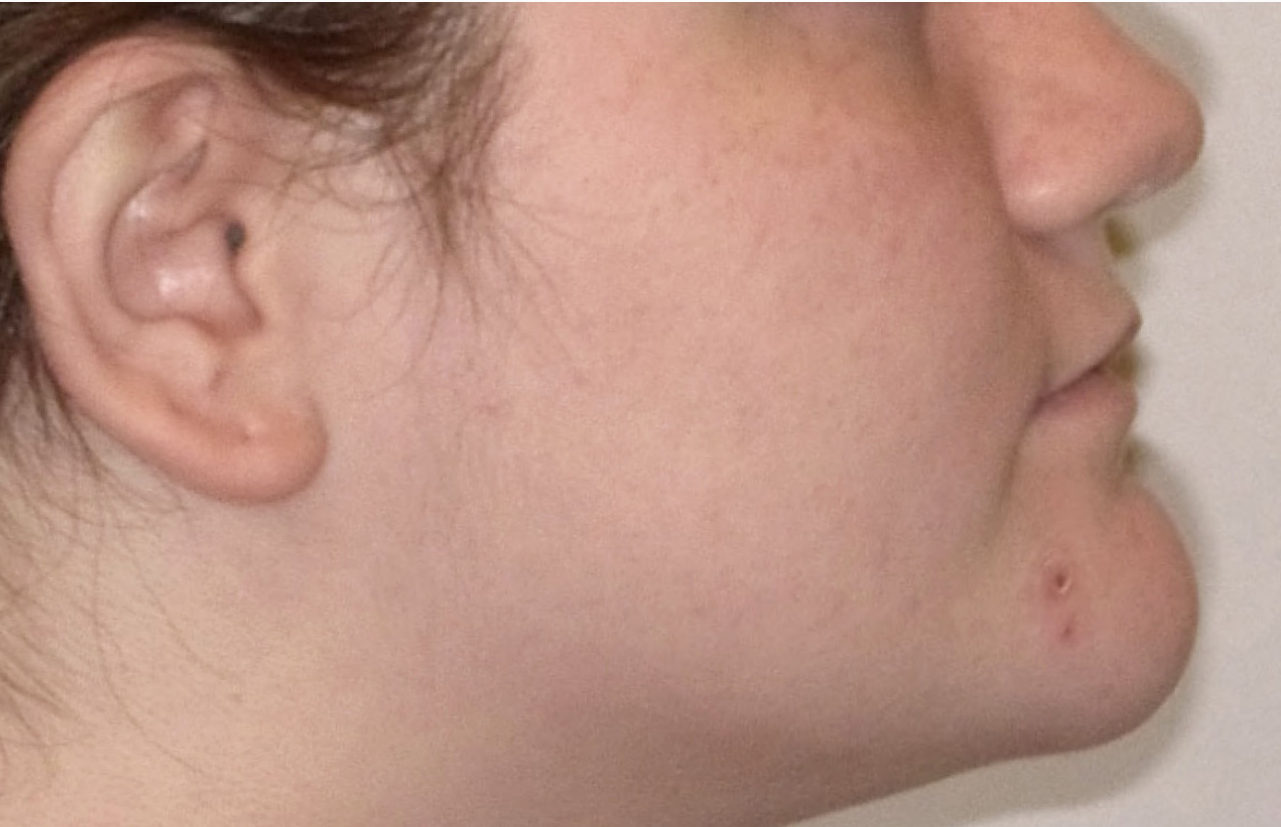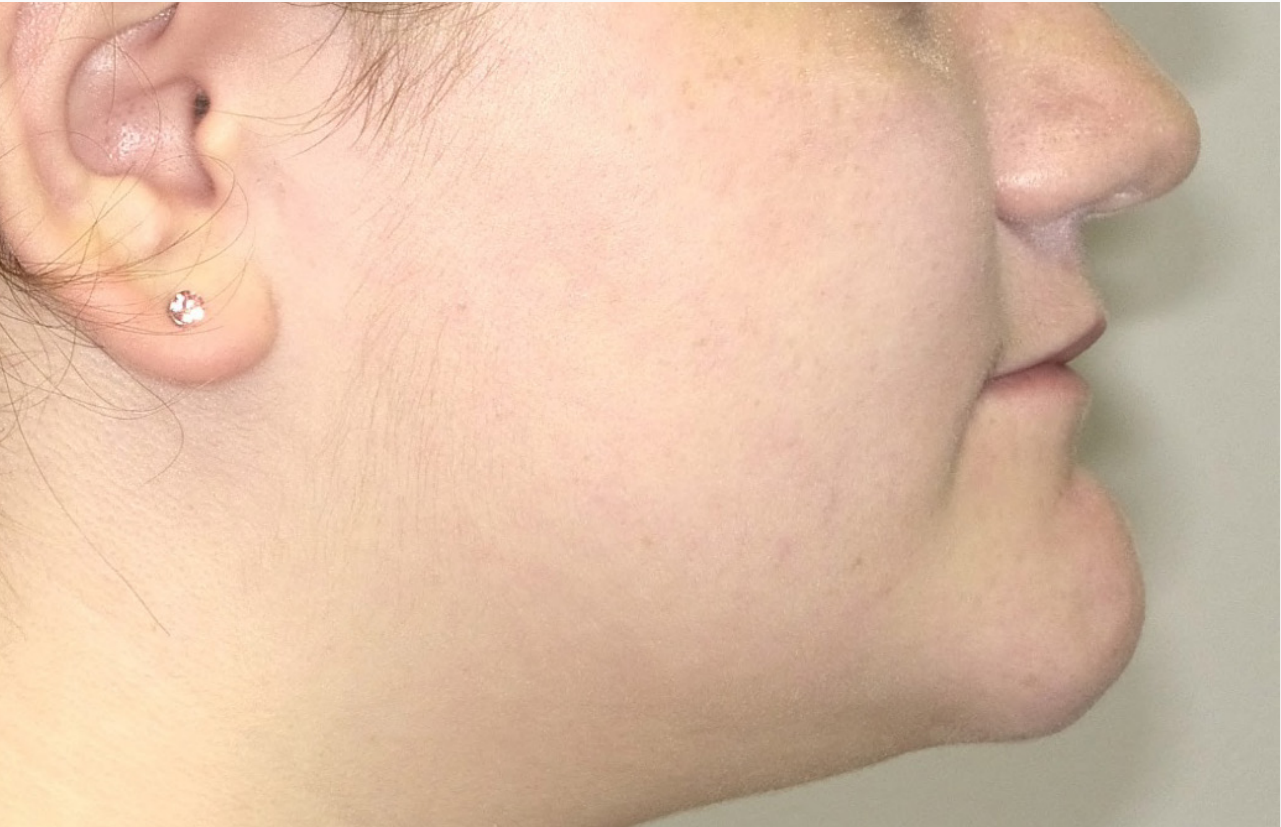	By Stage		Entire Case		Total IPR Upper Arch = 0mm										Total IPR Lower Arch = 2.4mm									
	R8	R7	R6	R5	R4	R3	R2	R1	L1	L2	L3	L4	L5	L6	L7	L8								
Upper Arch																								
Lower Arch						.2	.4	.4	.4	.4	.4	.2												

Case courtesy of:
Dr. Adam Schulhof
Oradell, NJ – USA

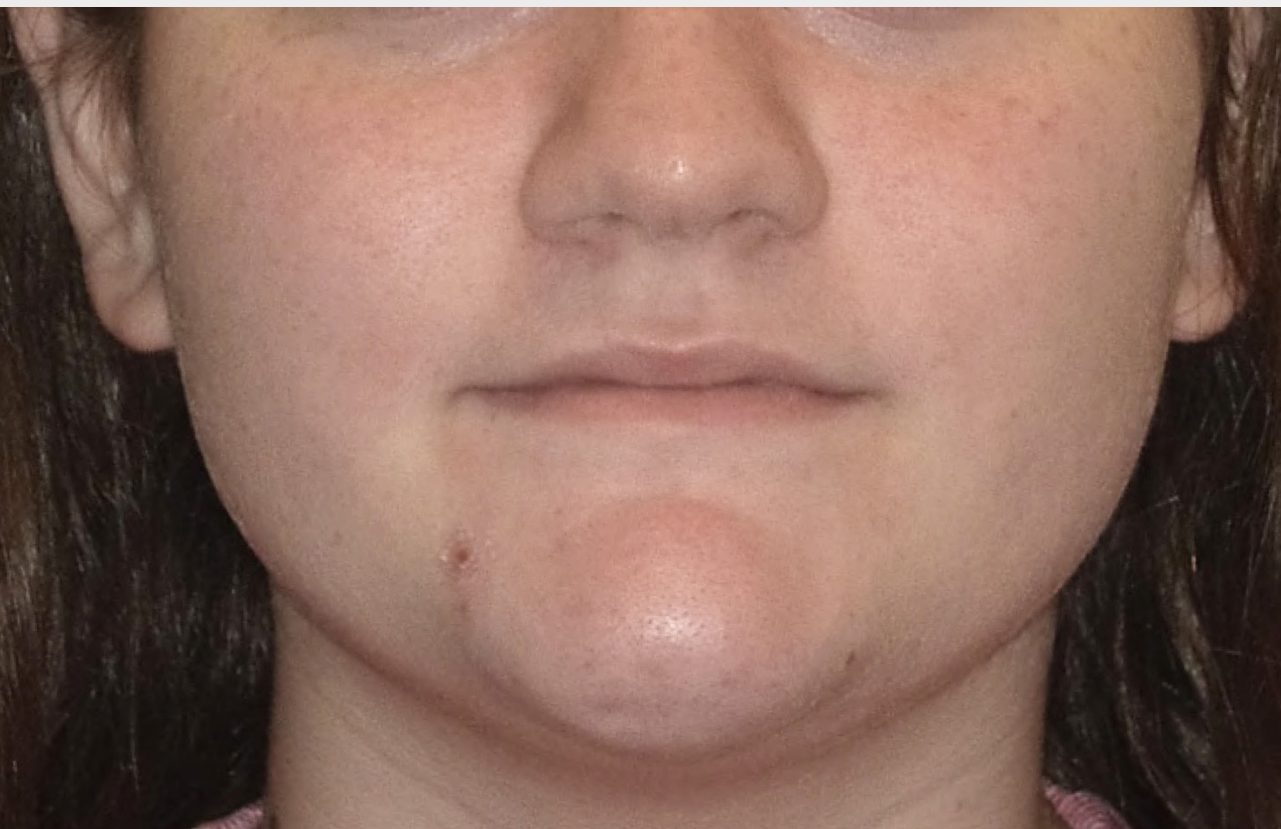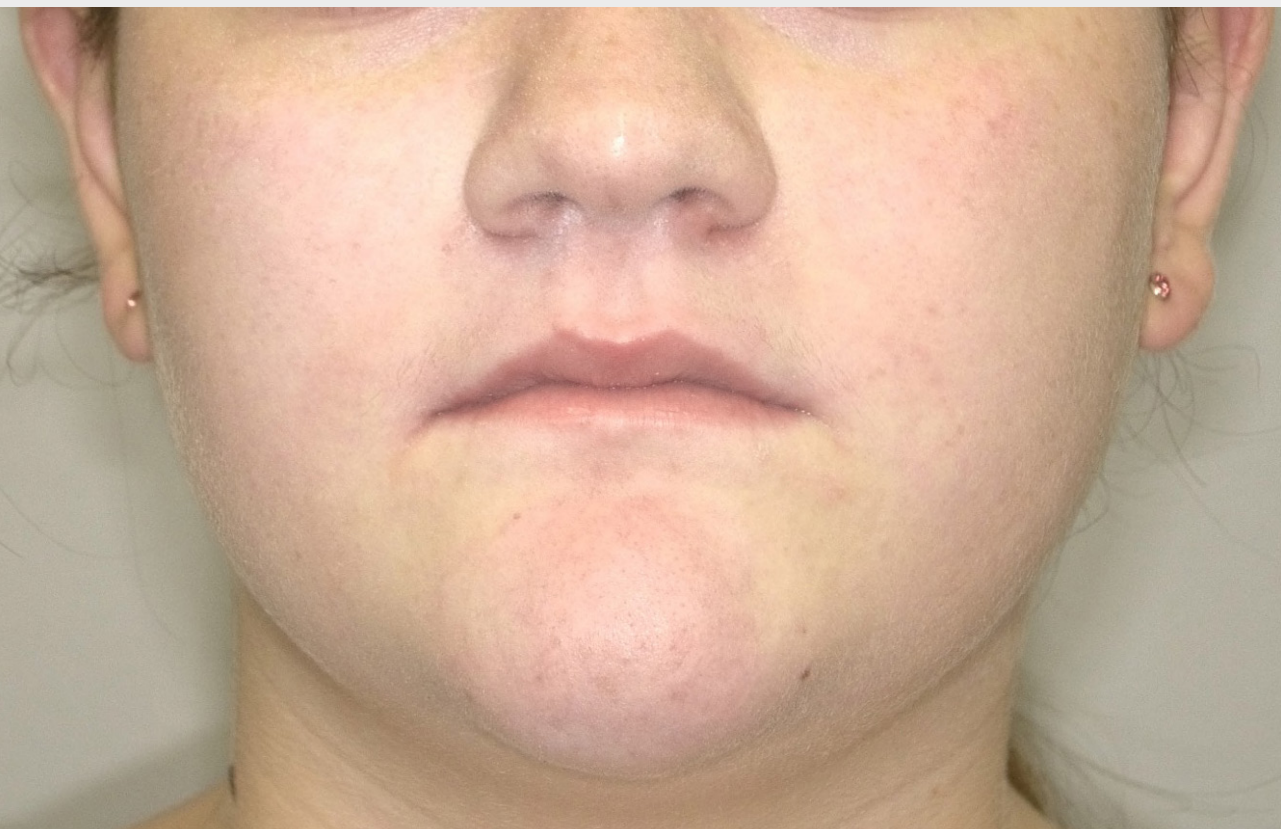Initial

Final

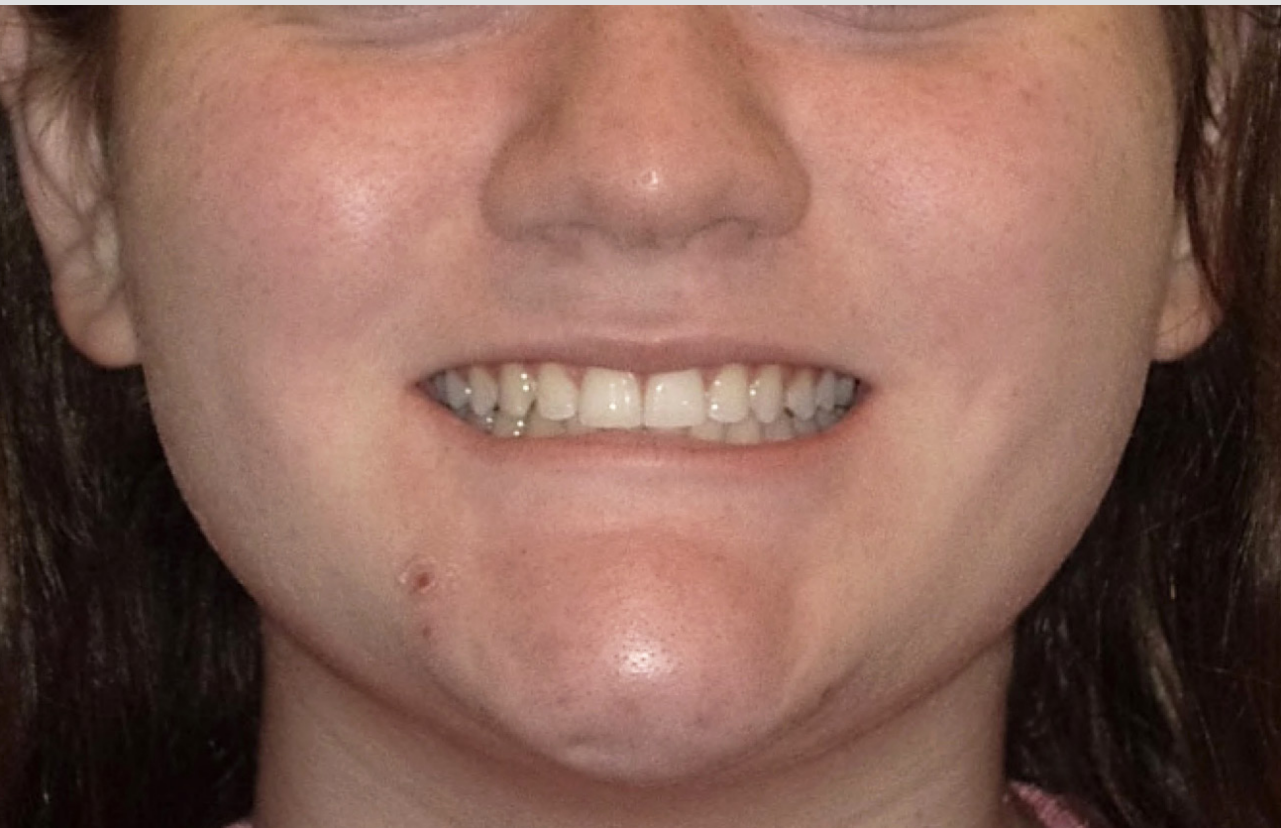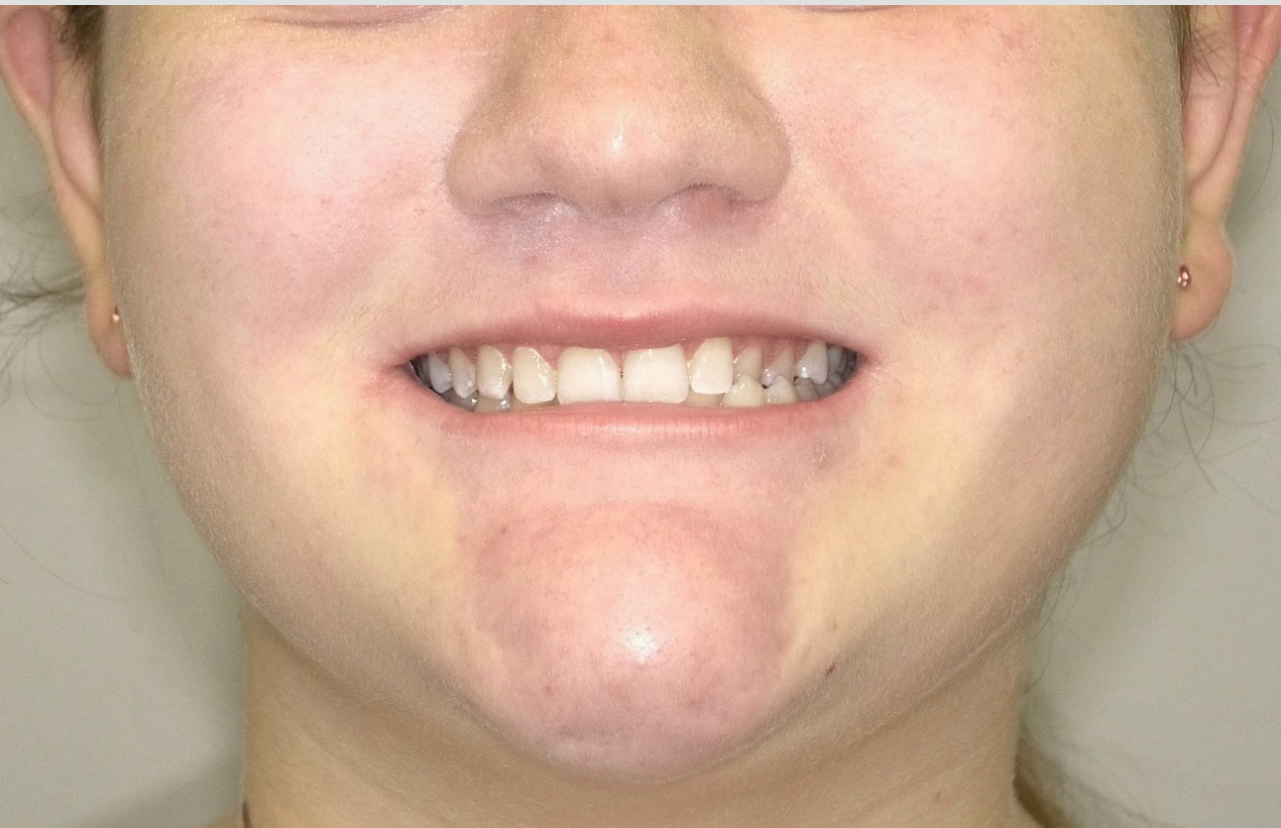Profile at rest



Face at rest



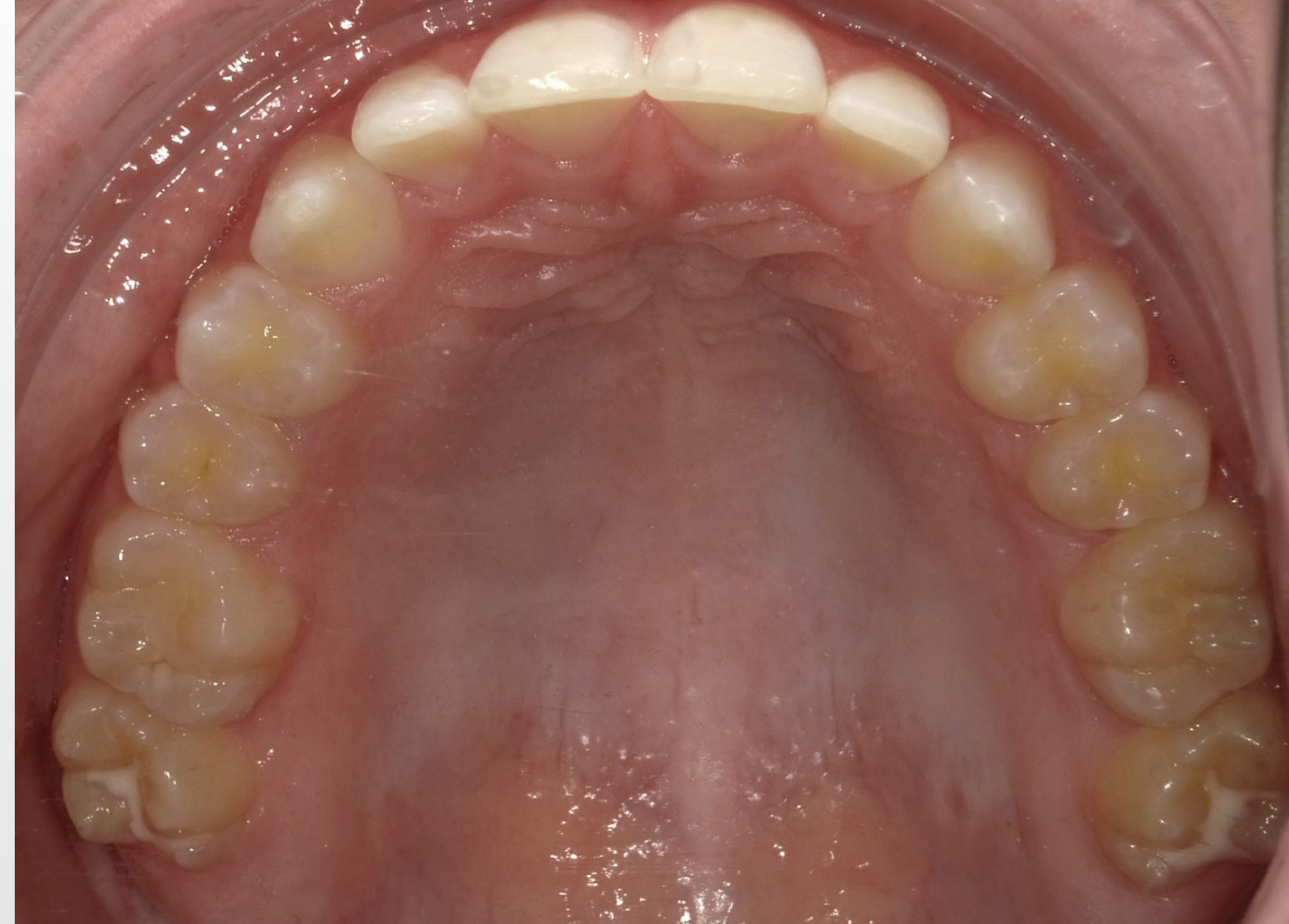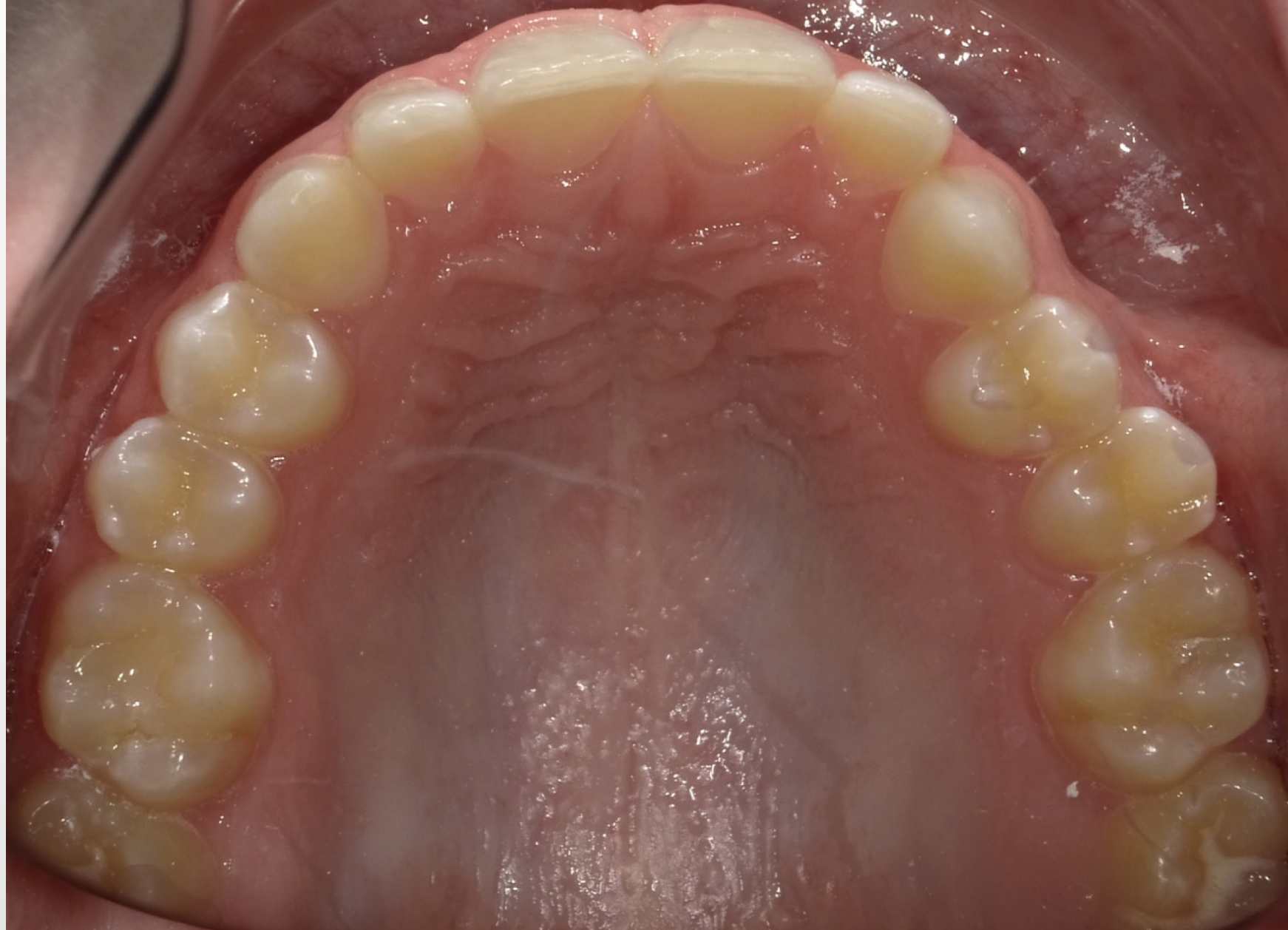
Face smiling



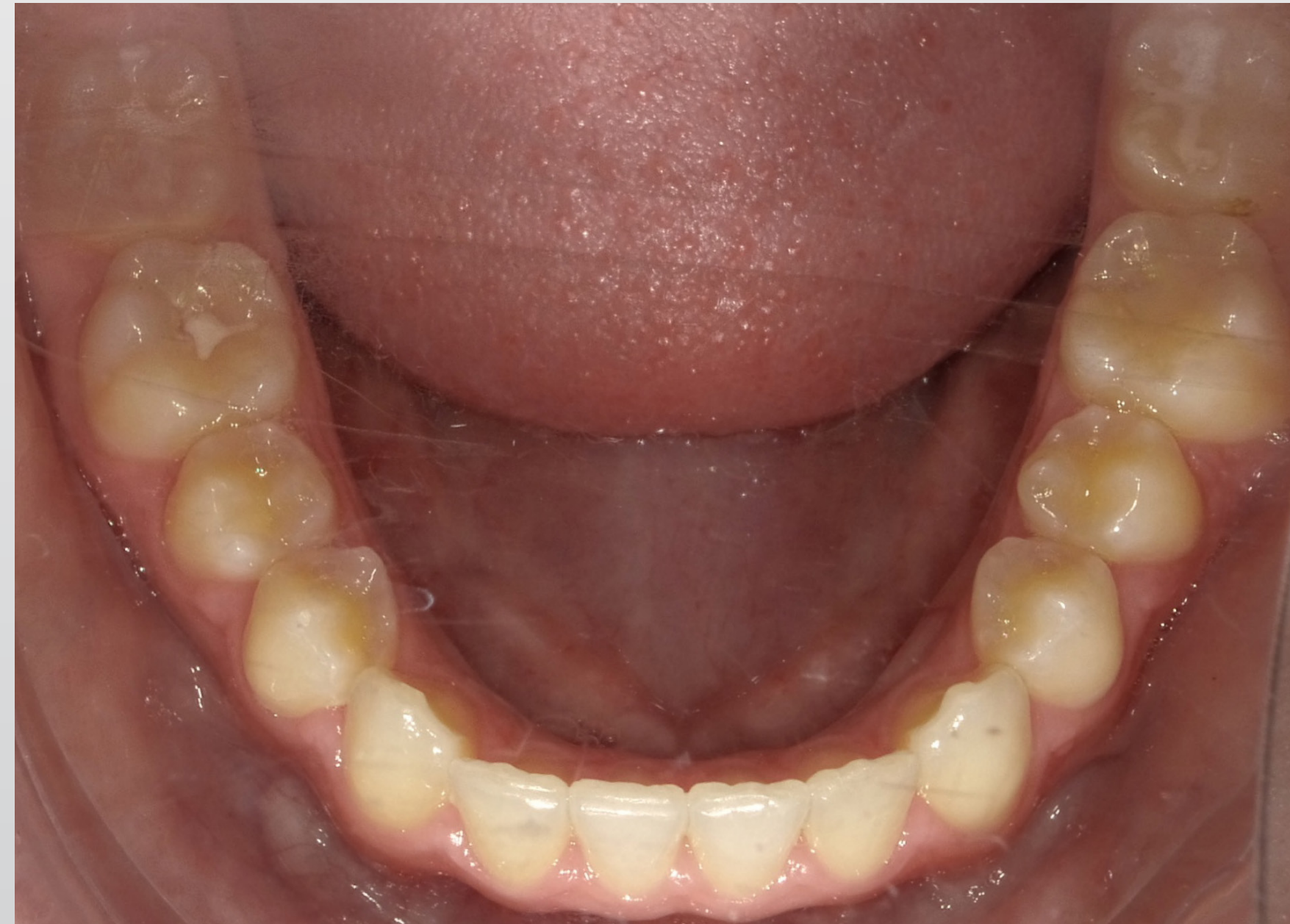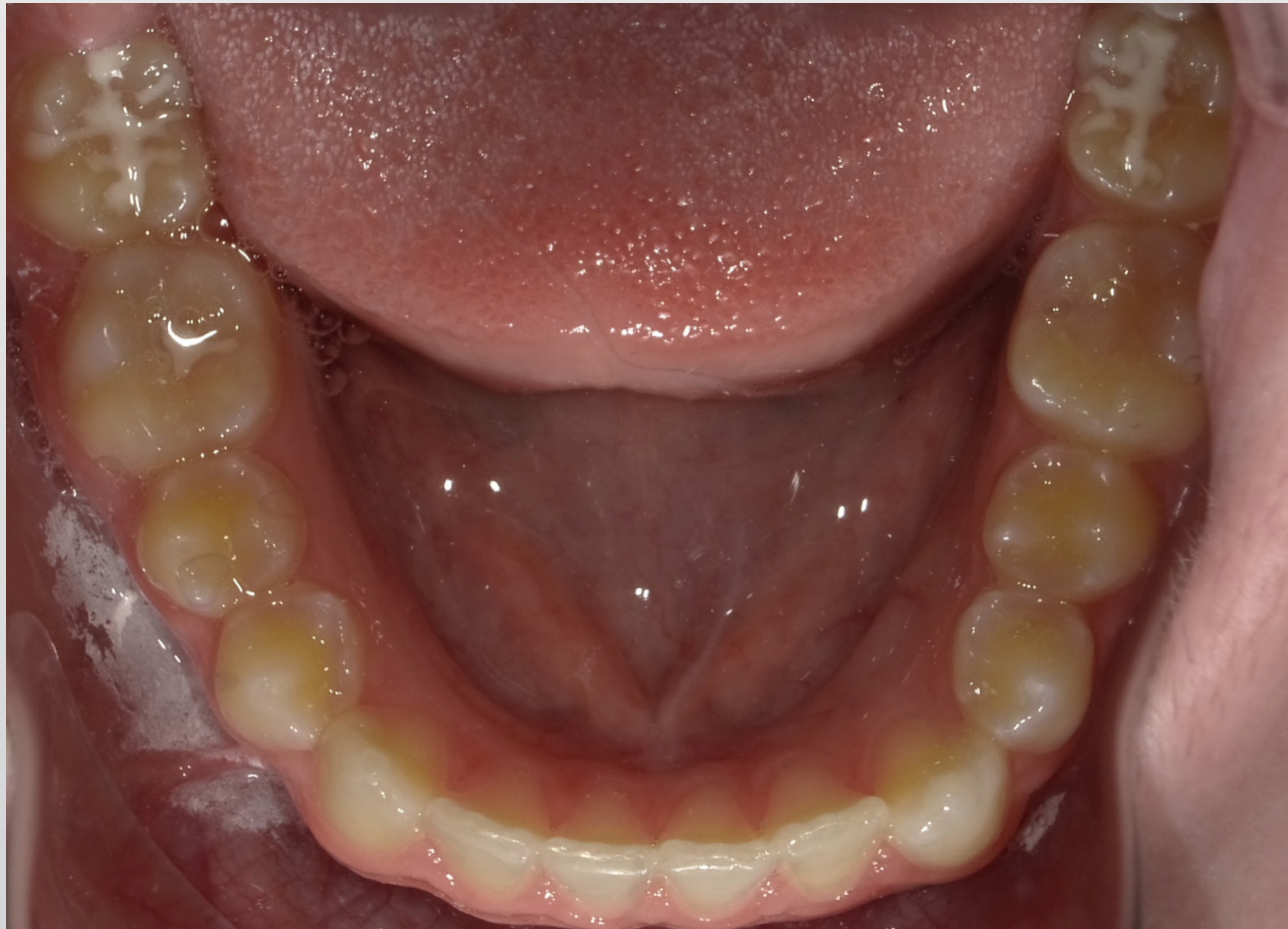Initial

Final

**Occlusal –
maxillary**



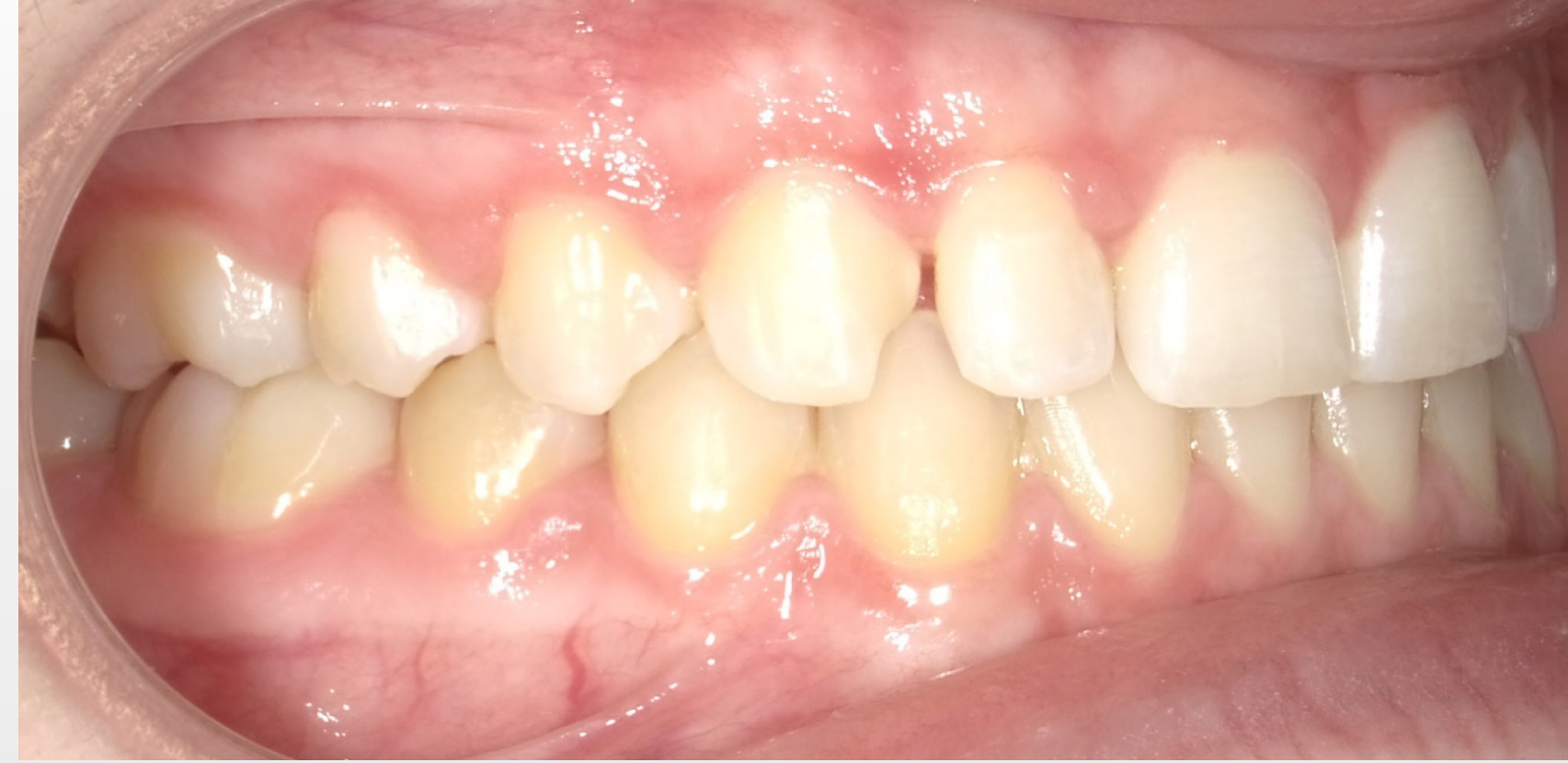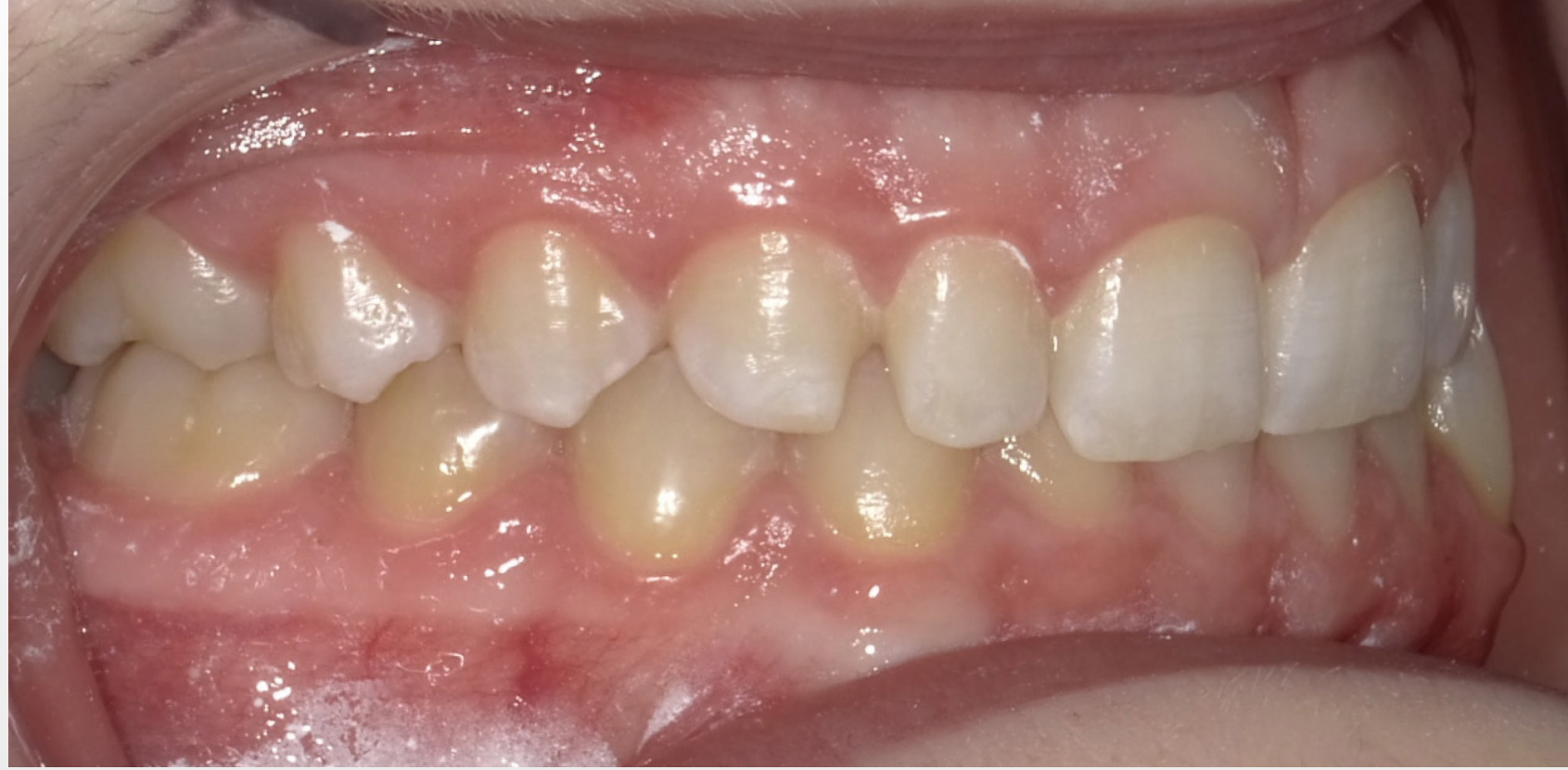**Occlusal –
mandibular**



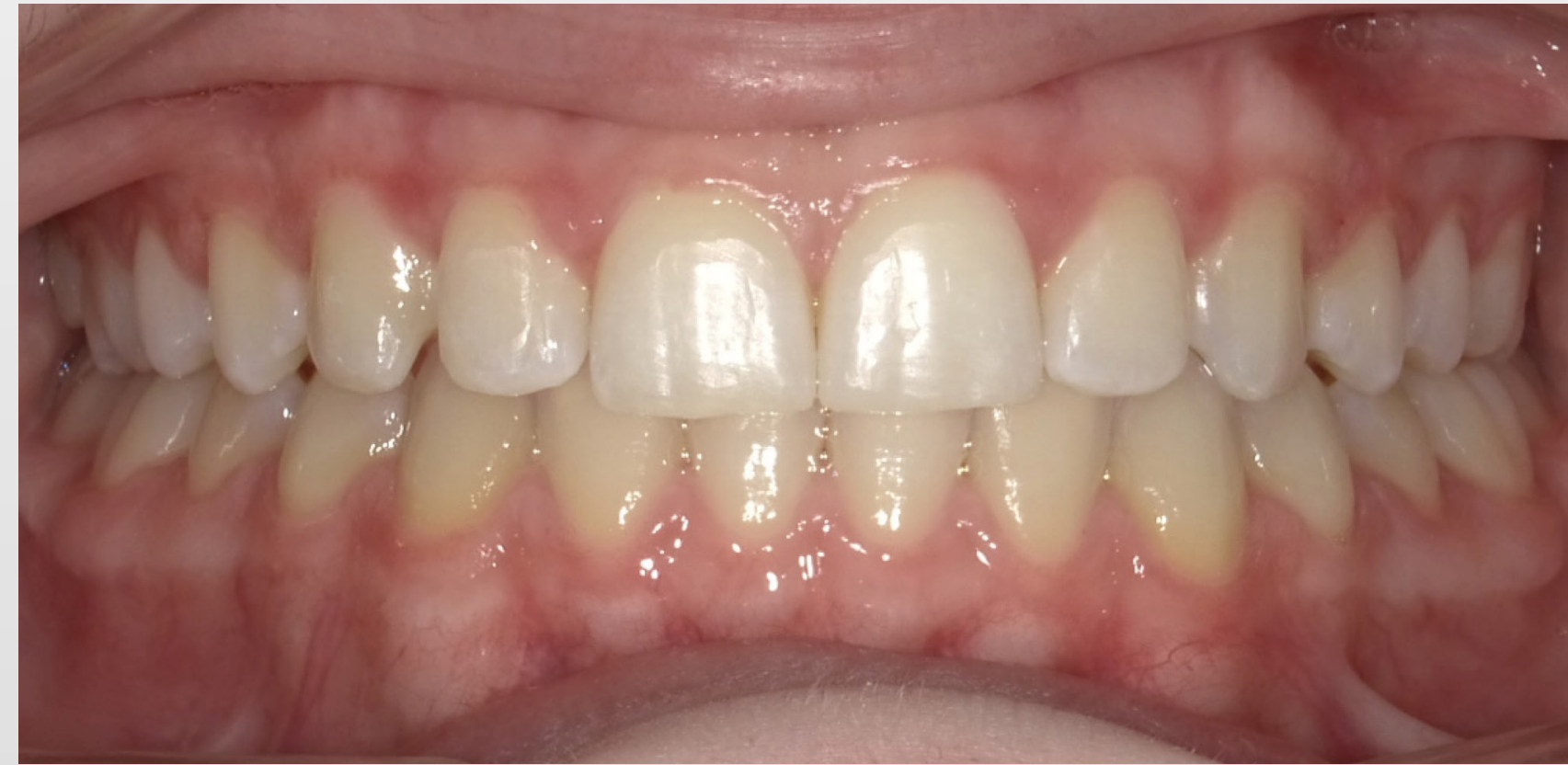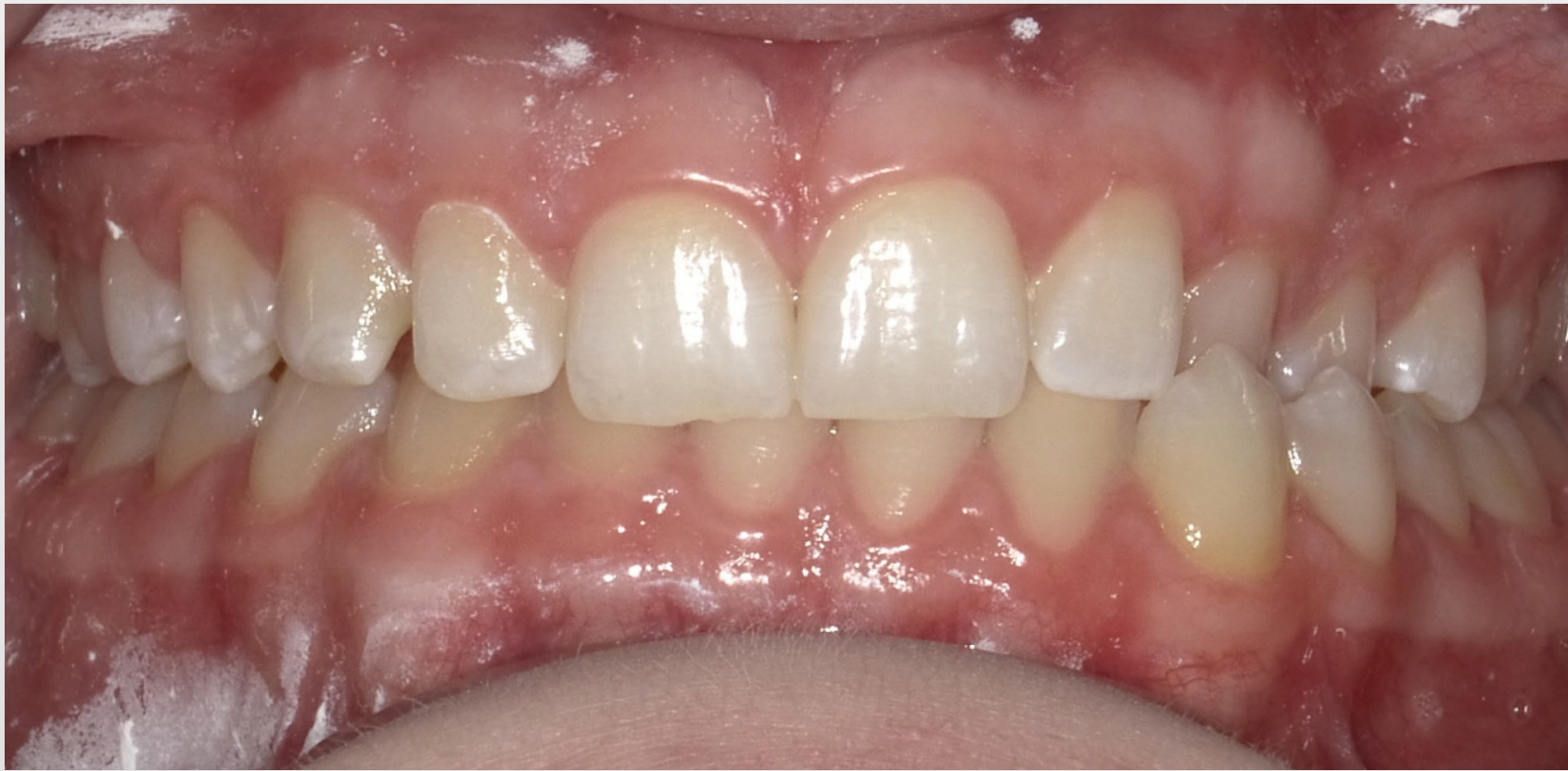Initial

Final

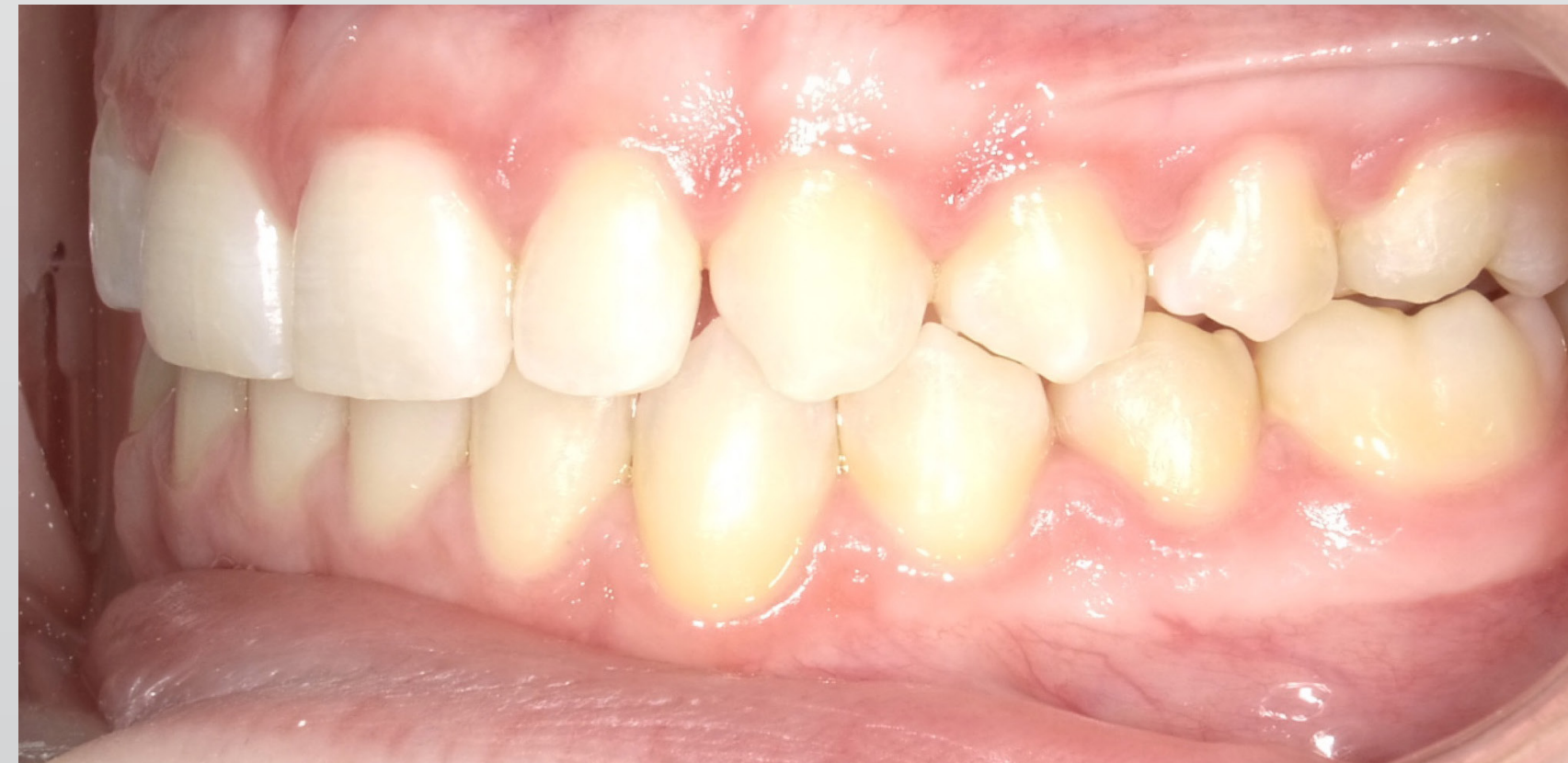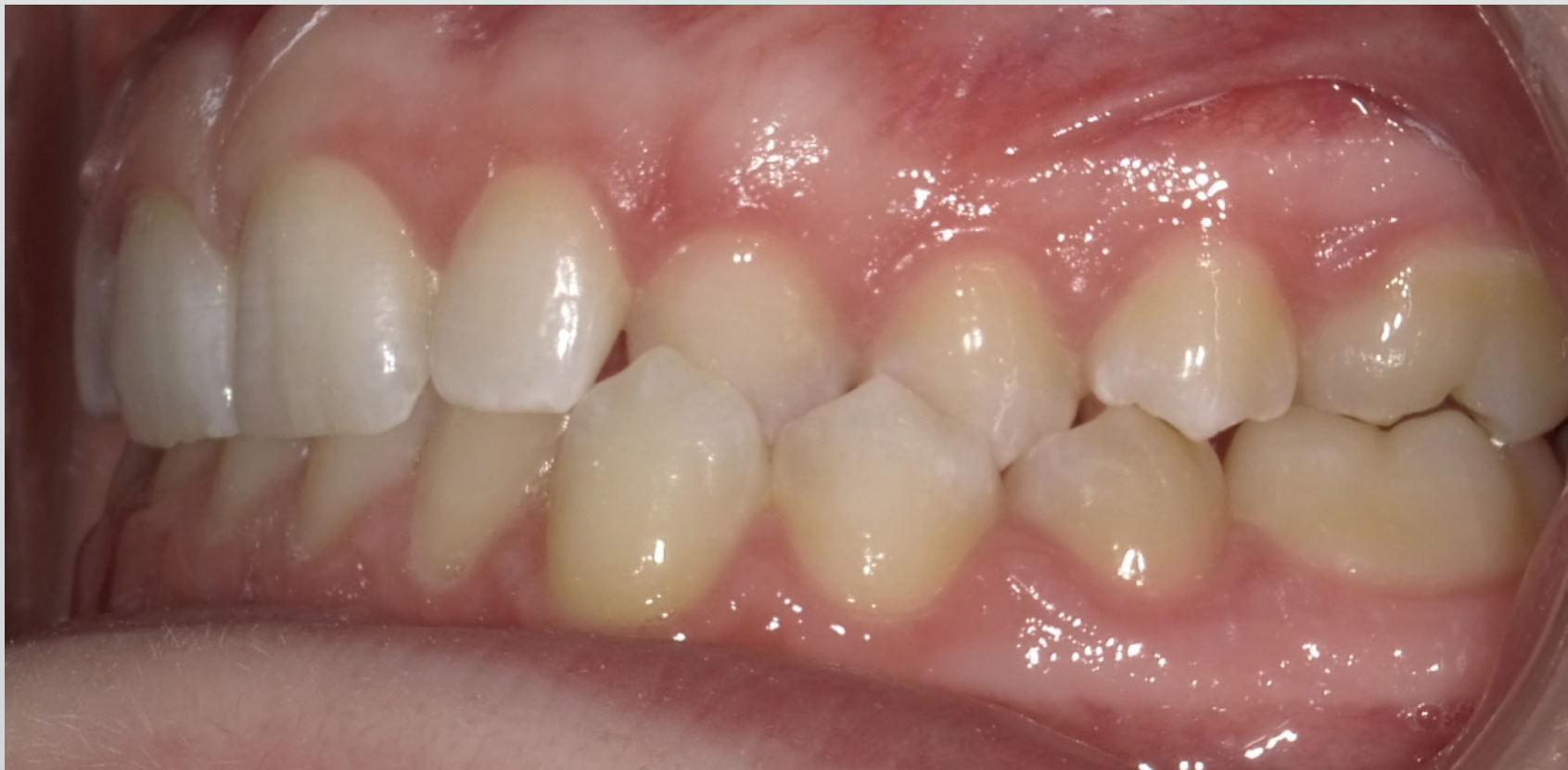**Retracted
buccal – right**



**Retracted
anterior biting**



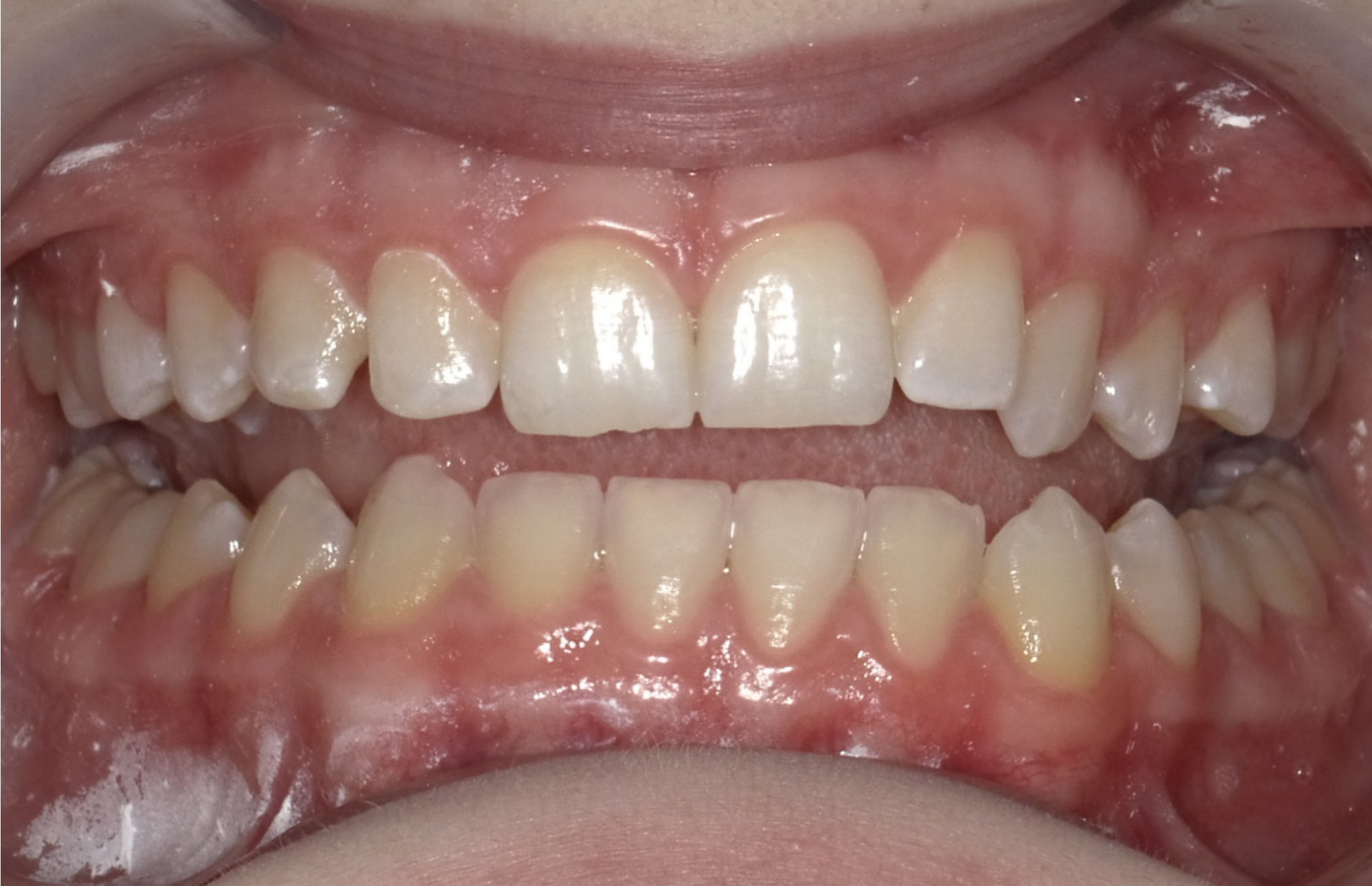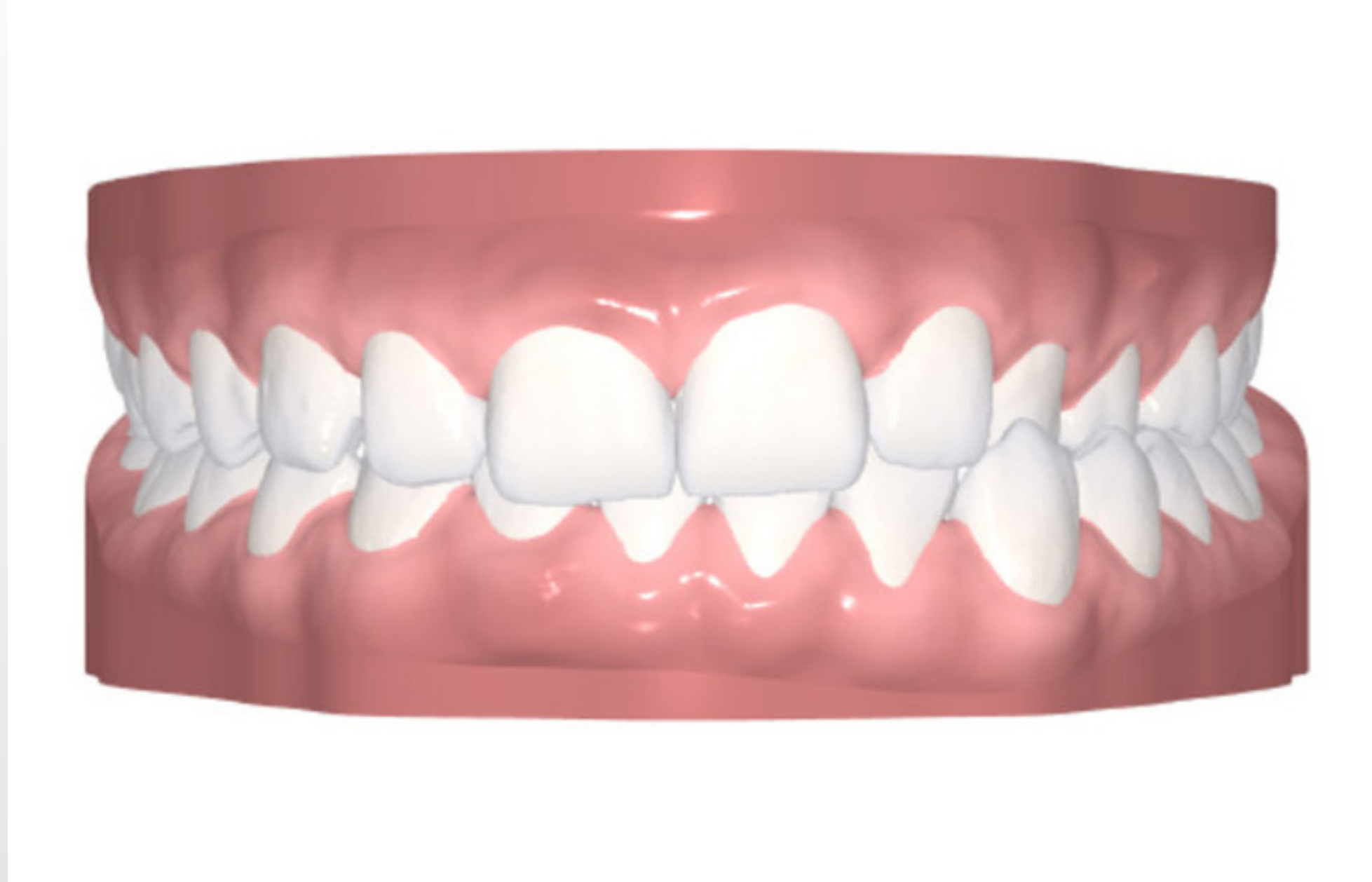**Retracted
buccal – left**



Tx design

Anterior open

Initial



Final



