

Case Study: 3M™ Clarity™ Aligners

Class II deep bite with mild to moderate crowding.

Age: 70

Total number of aligners: 36 (dual arch)

Wear interval: Weekly

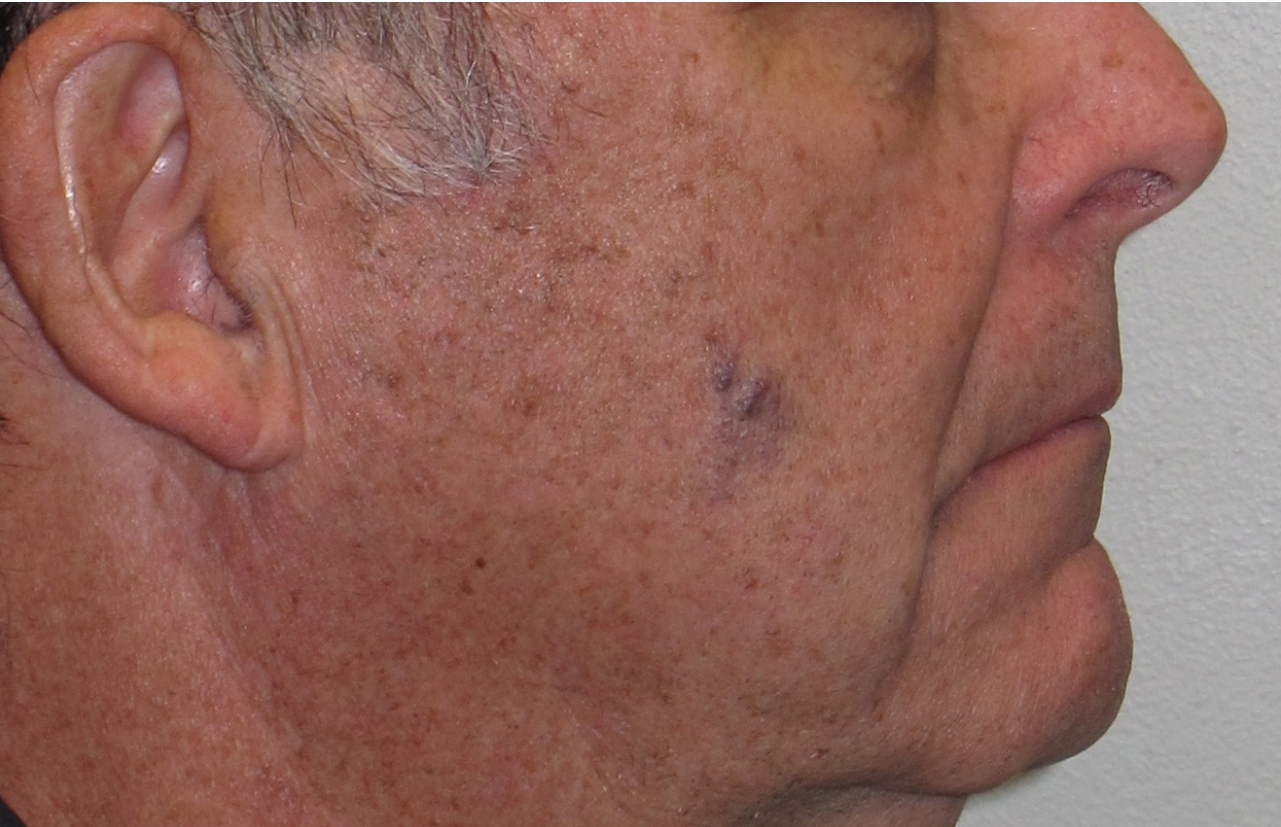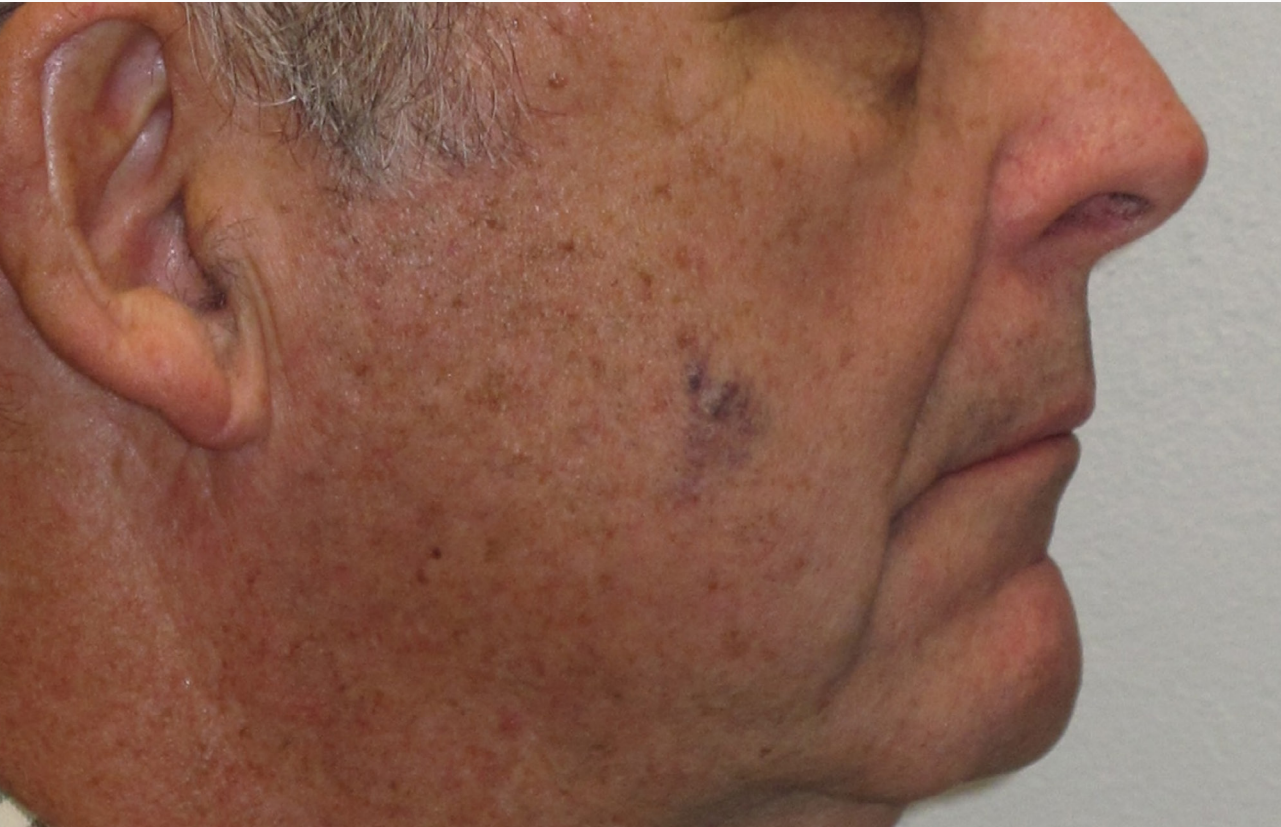Treatment time: 9 months

Case courtesy of:
Dr. Shane Langley & Dr. Rick O’Neil
South Alabama Orthodontics, Fairhope, AL – USA

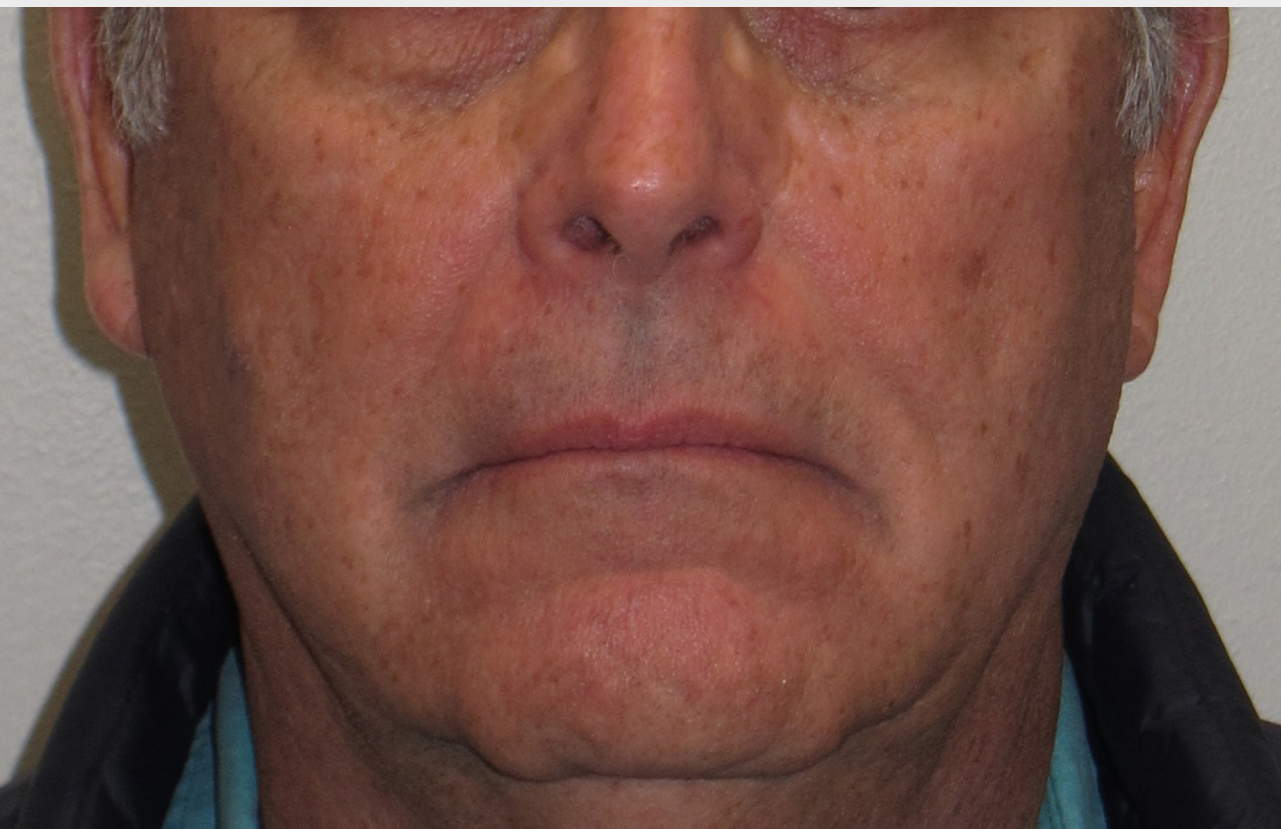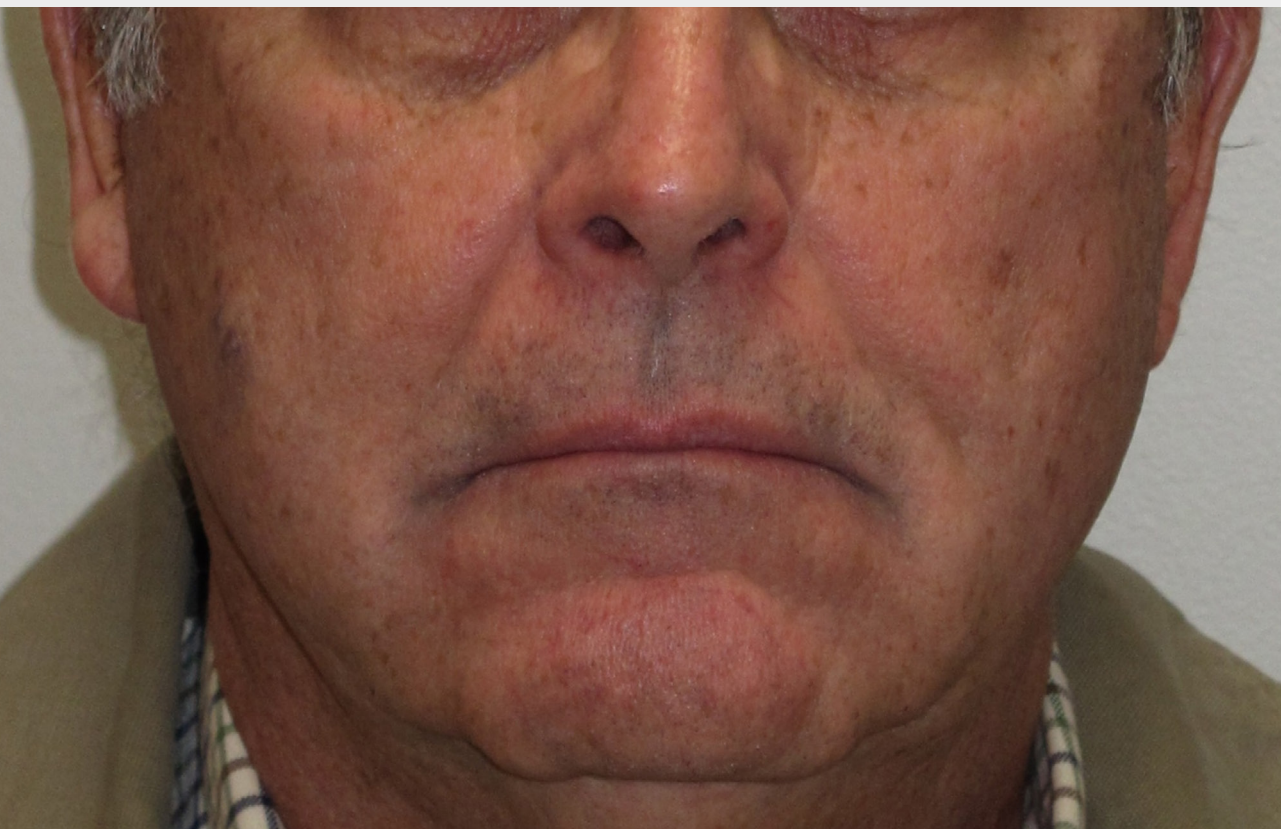Initial

Final

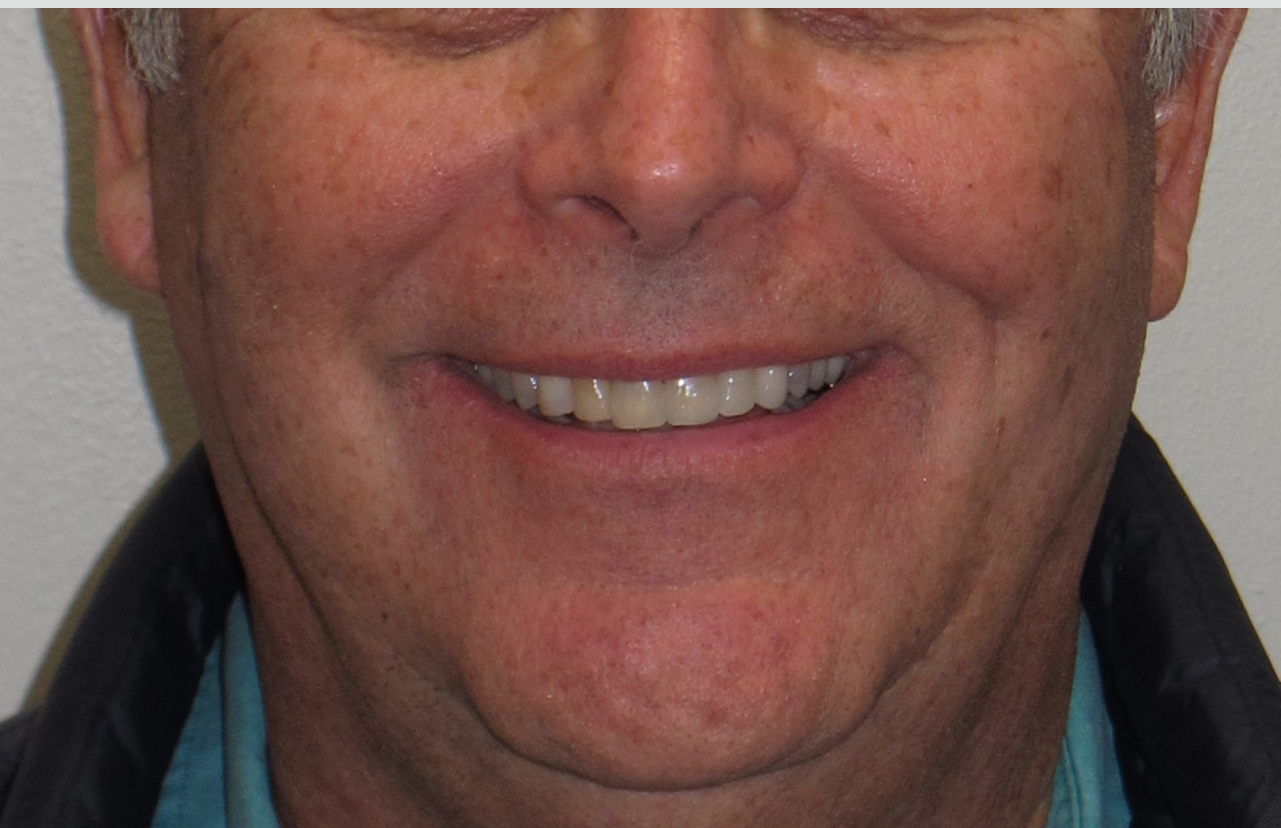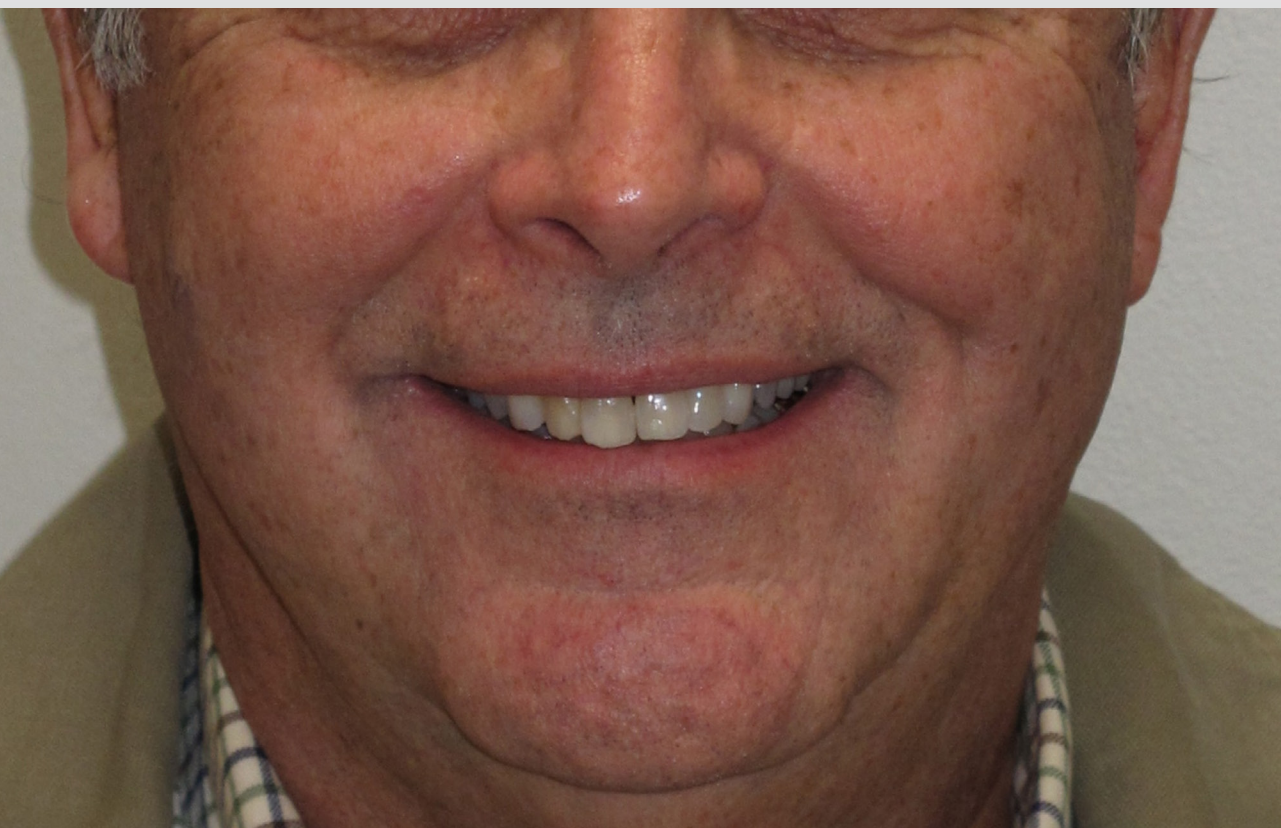Profile at rest



Face at rest



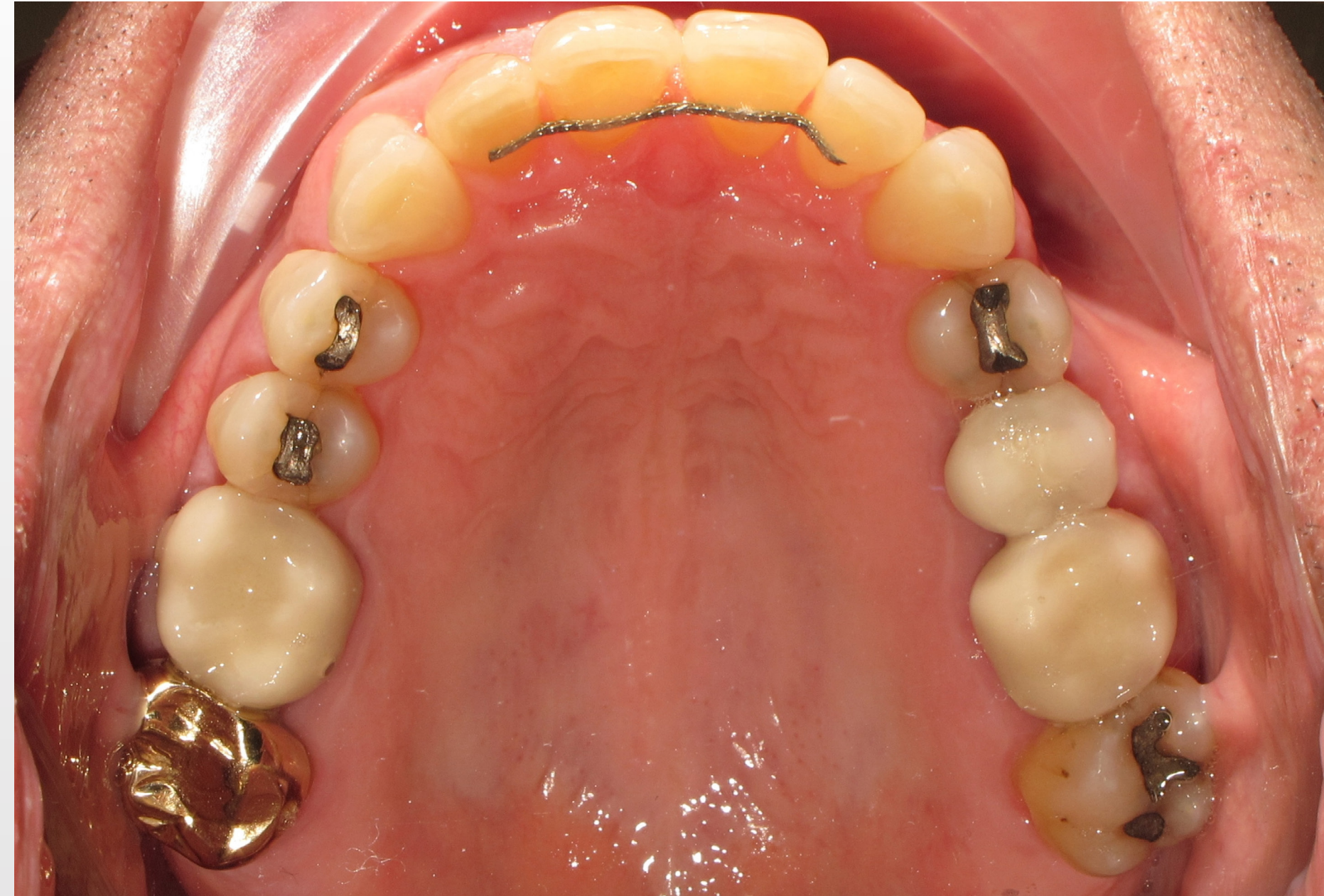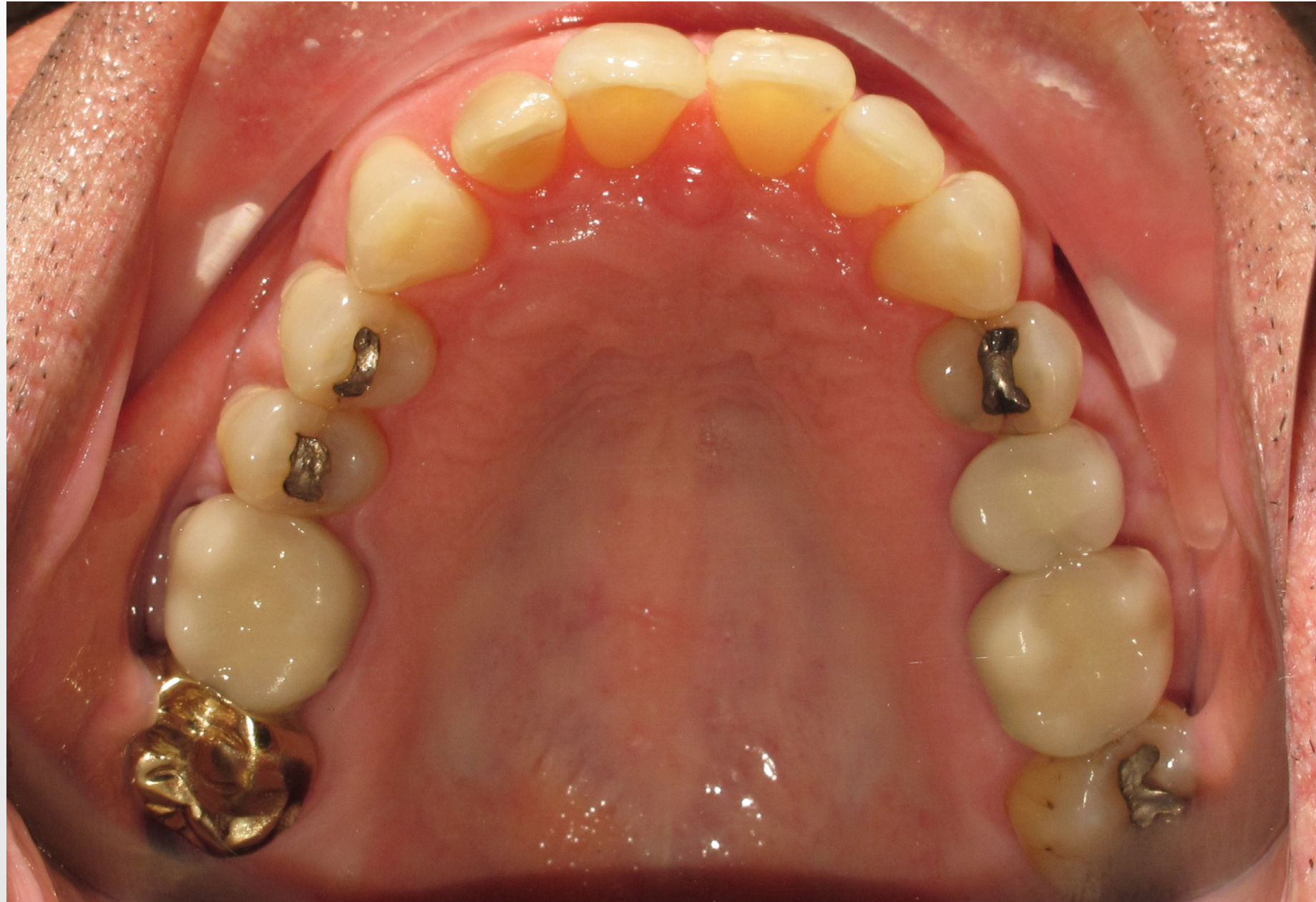Face smiling



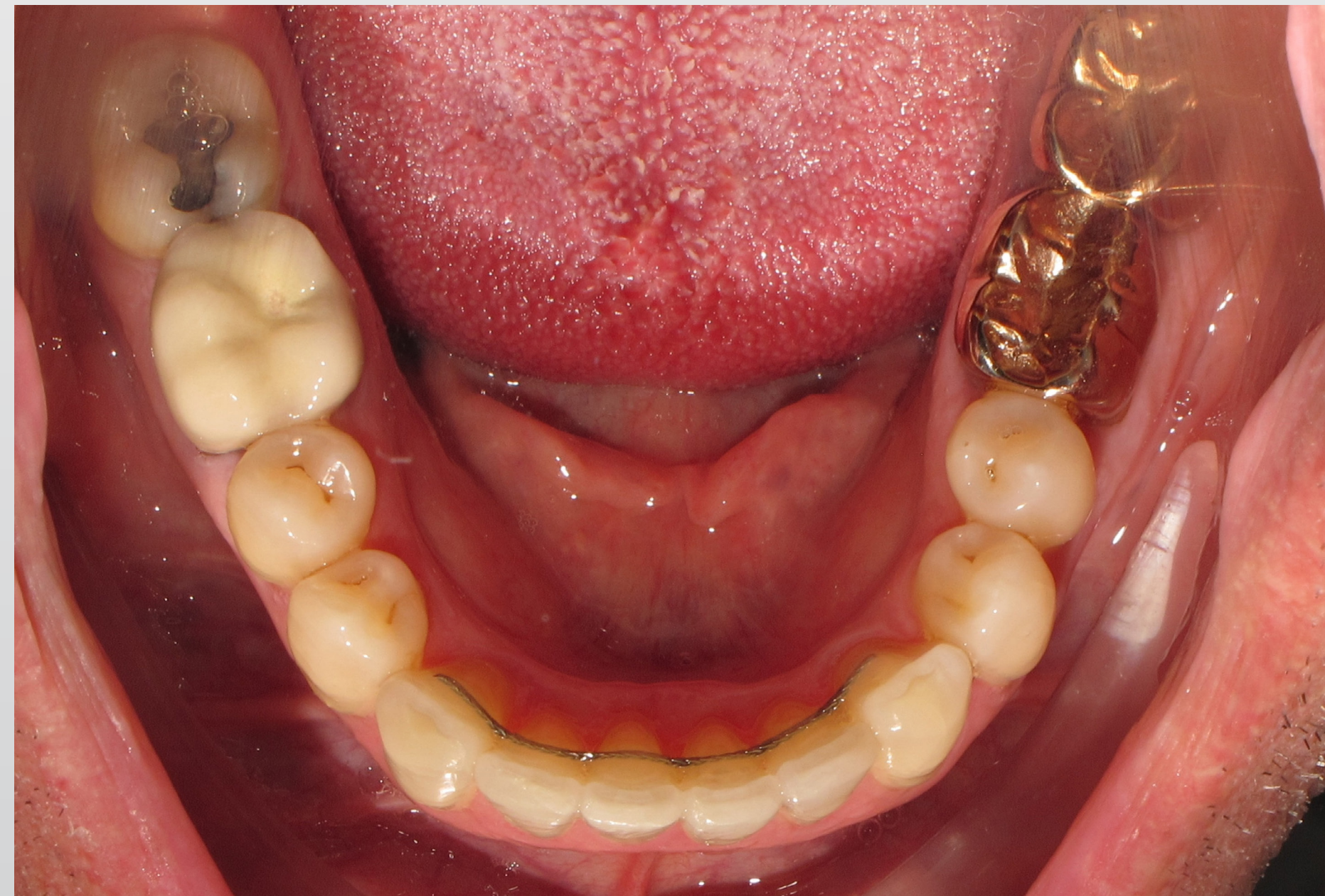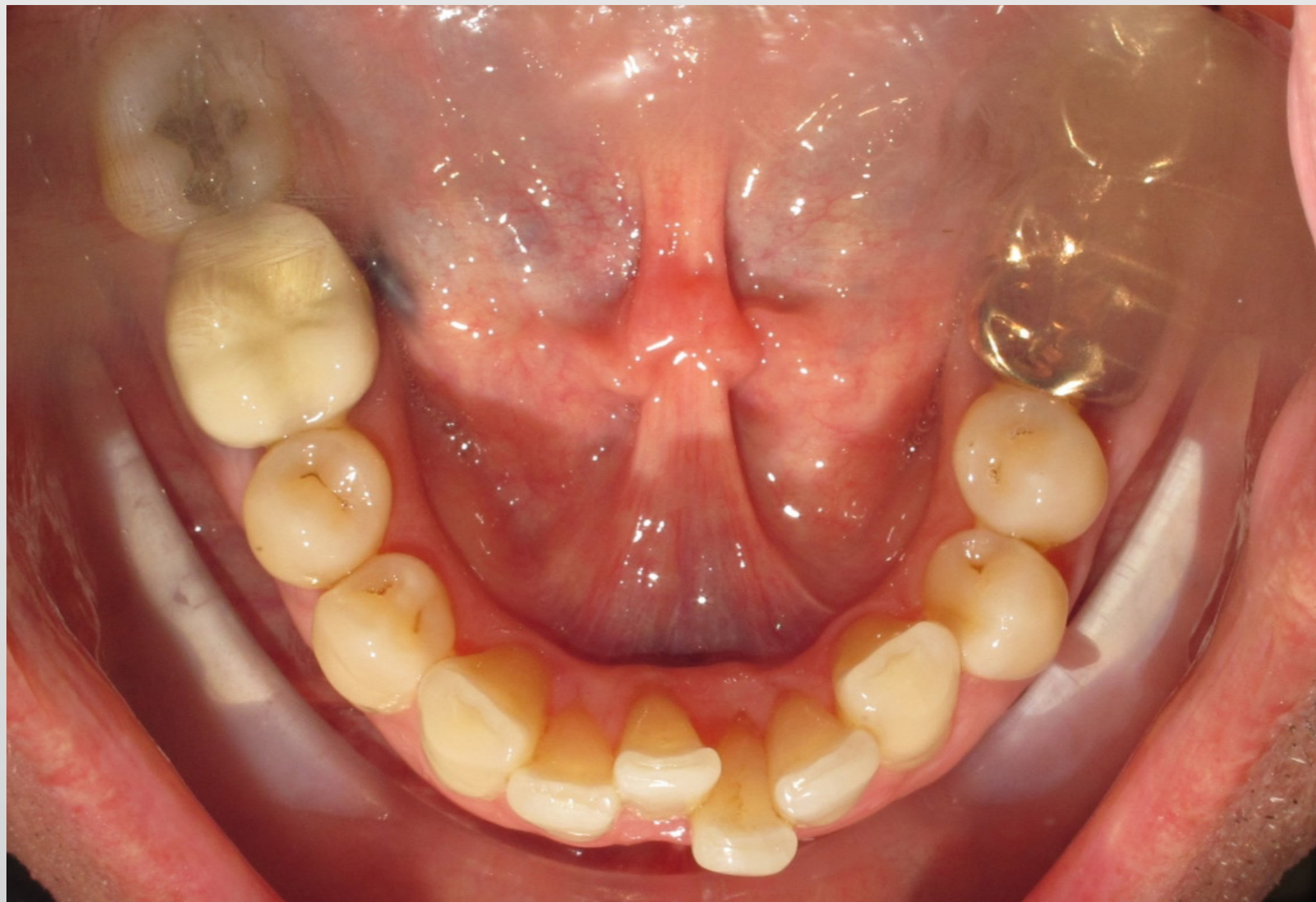Initial

Final

**Occlusal –
maxillary**



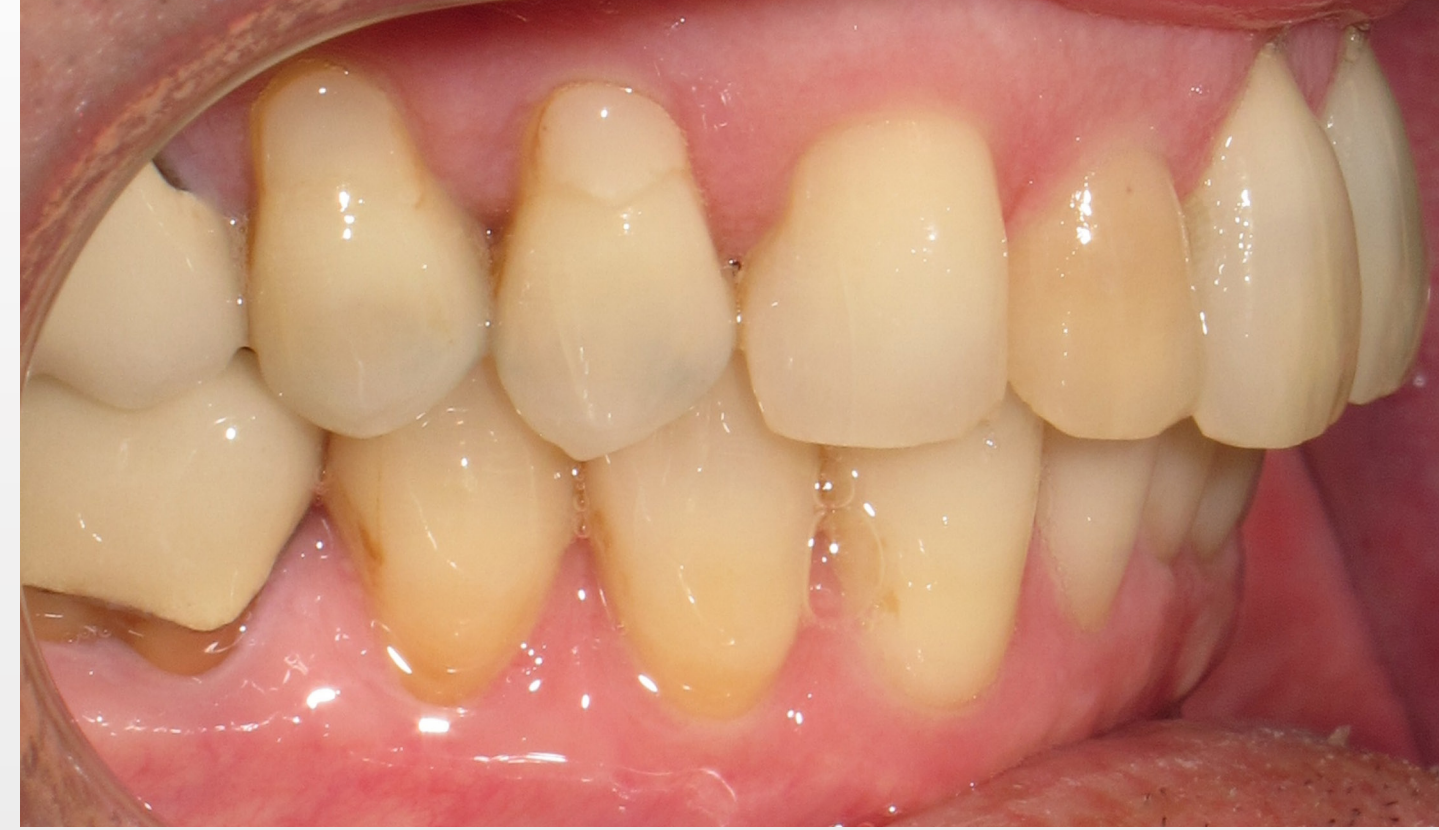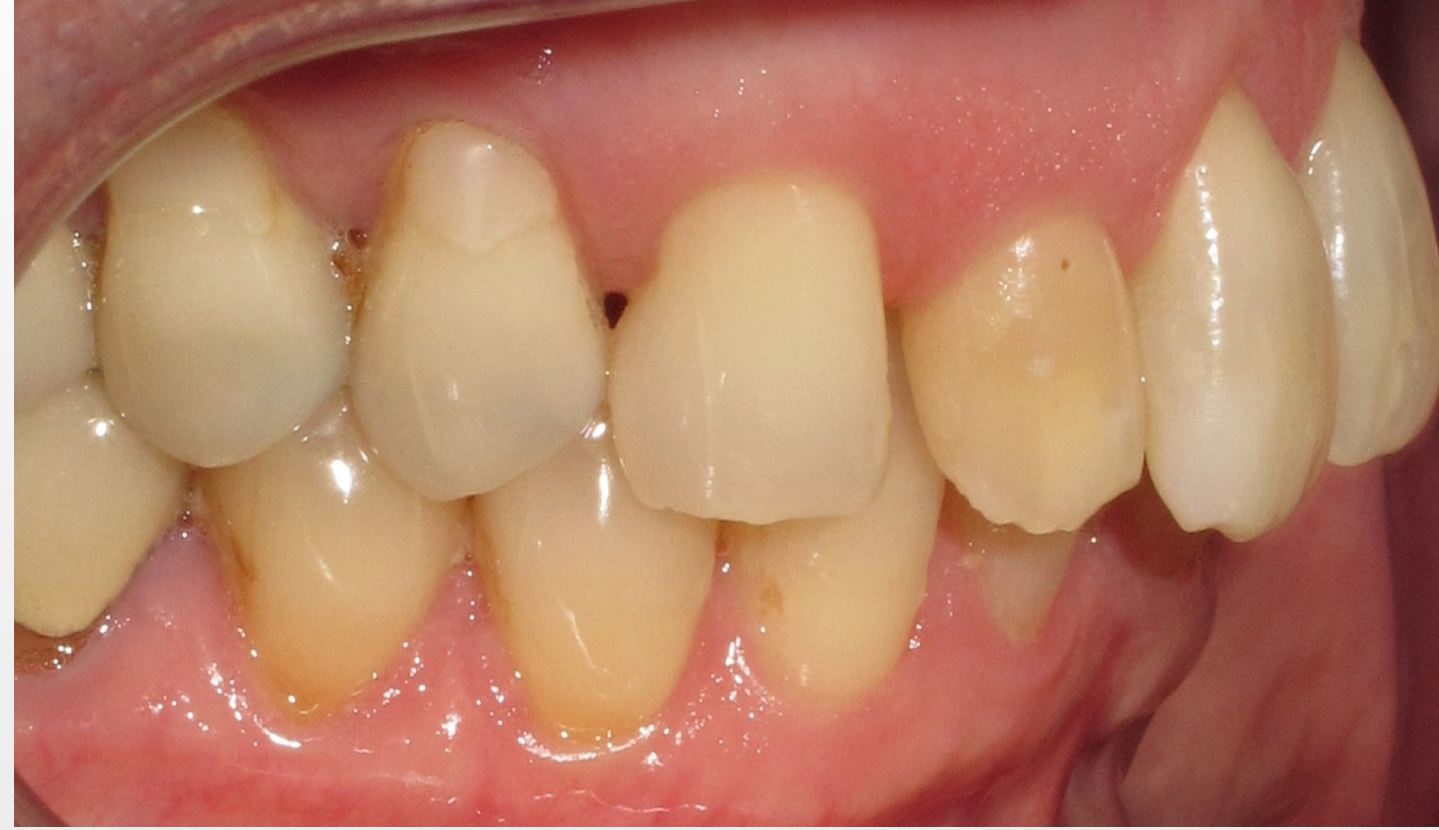**Occlusal –
mandibular**



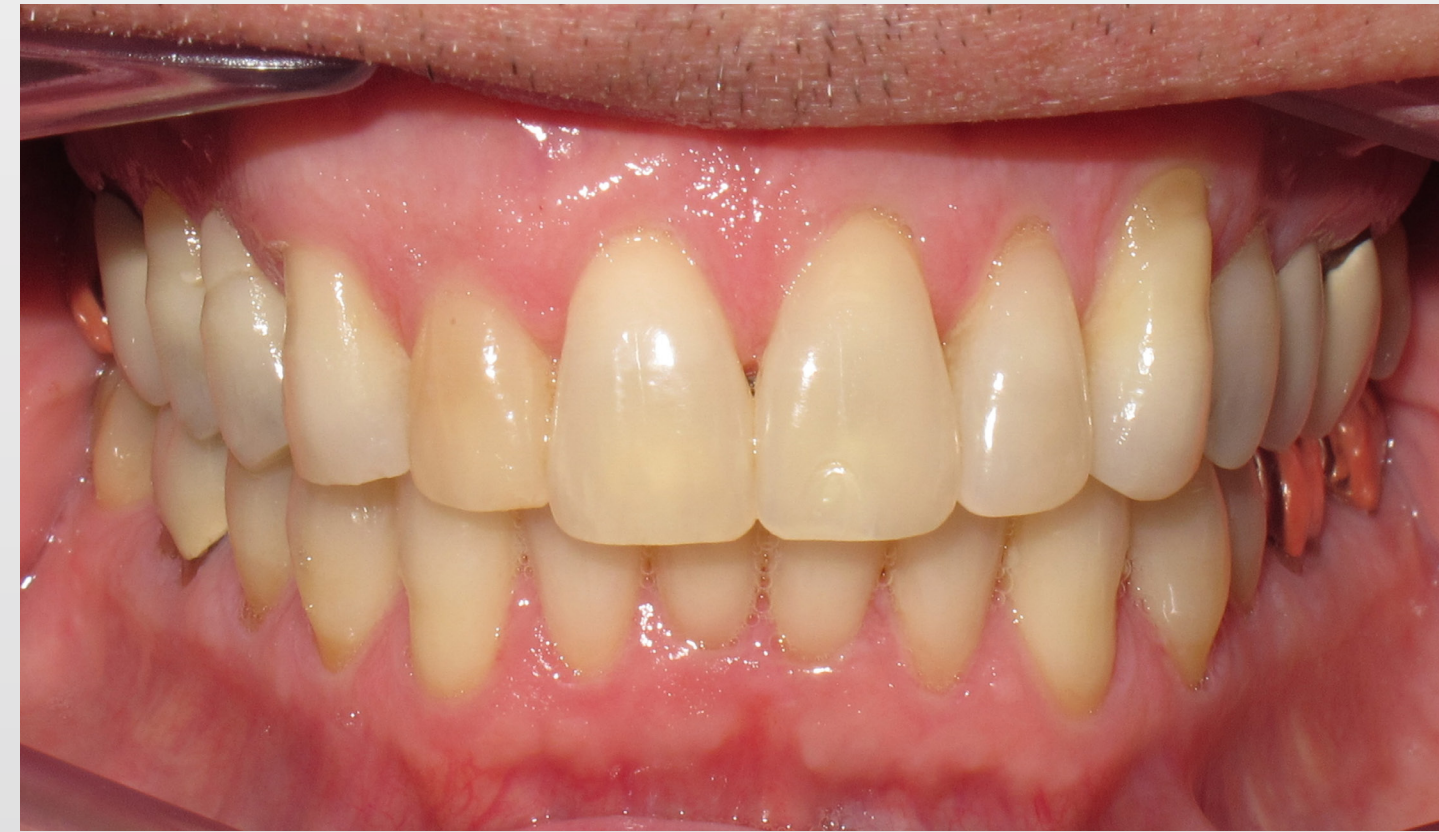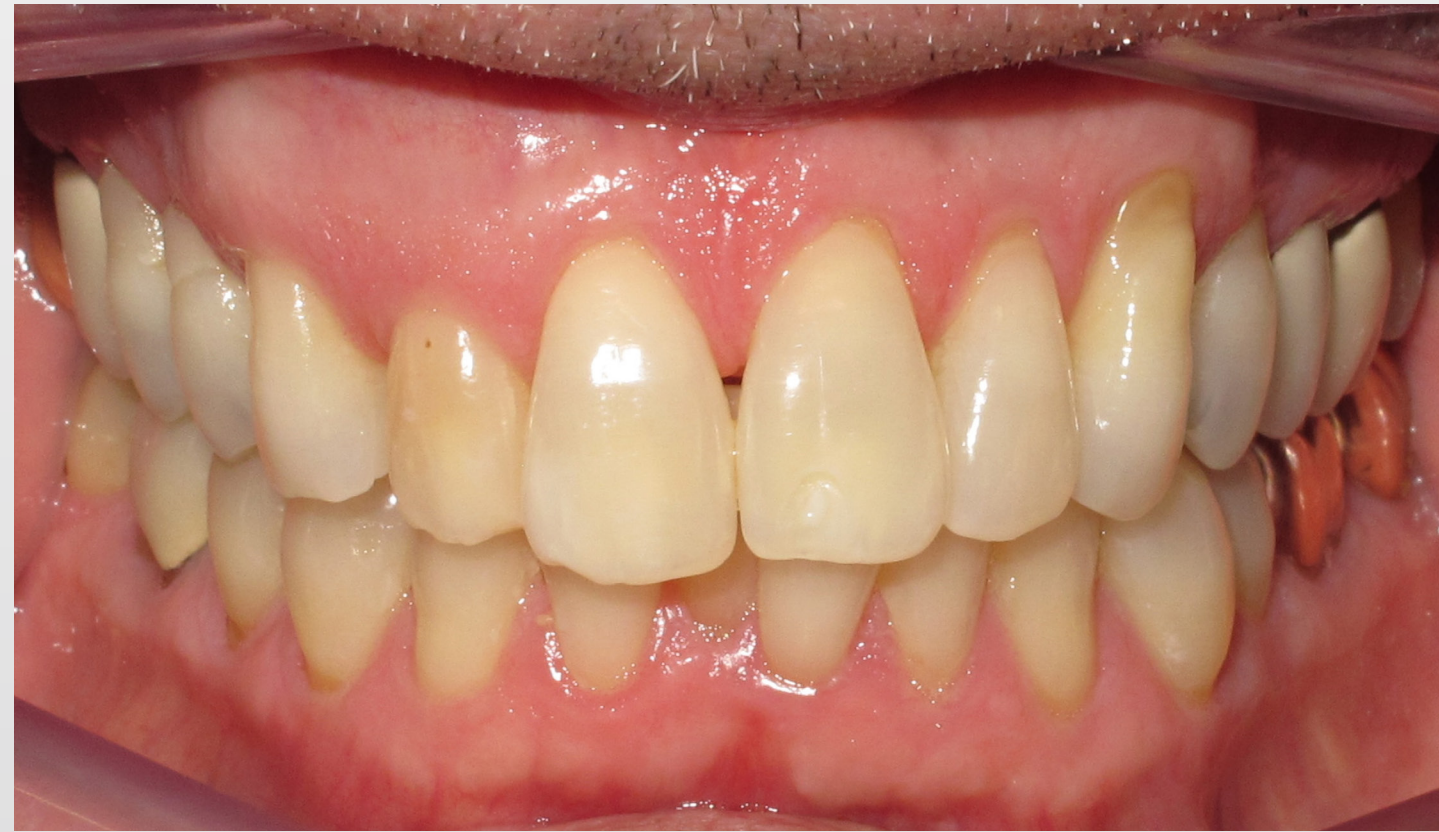Initial

Final

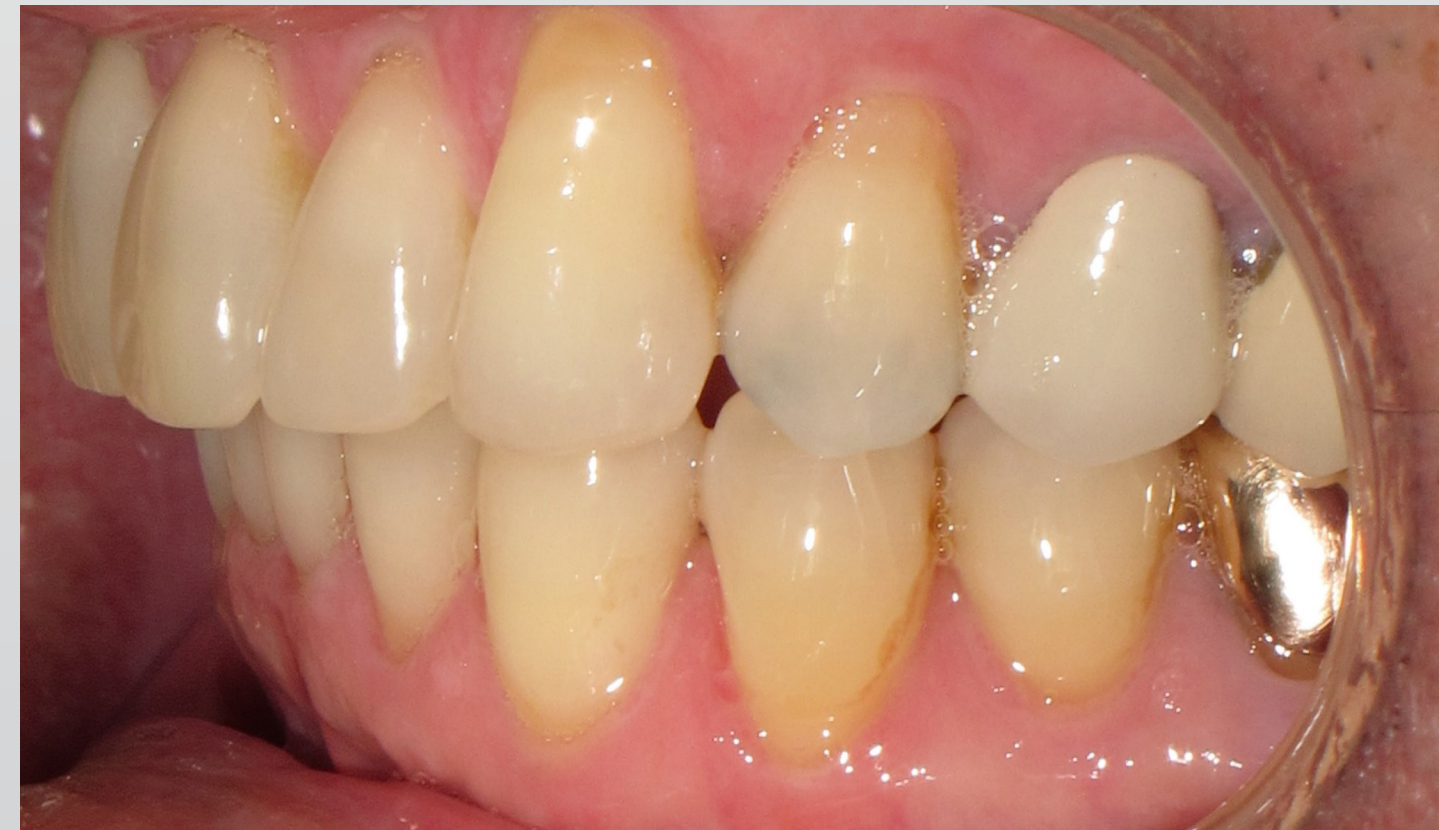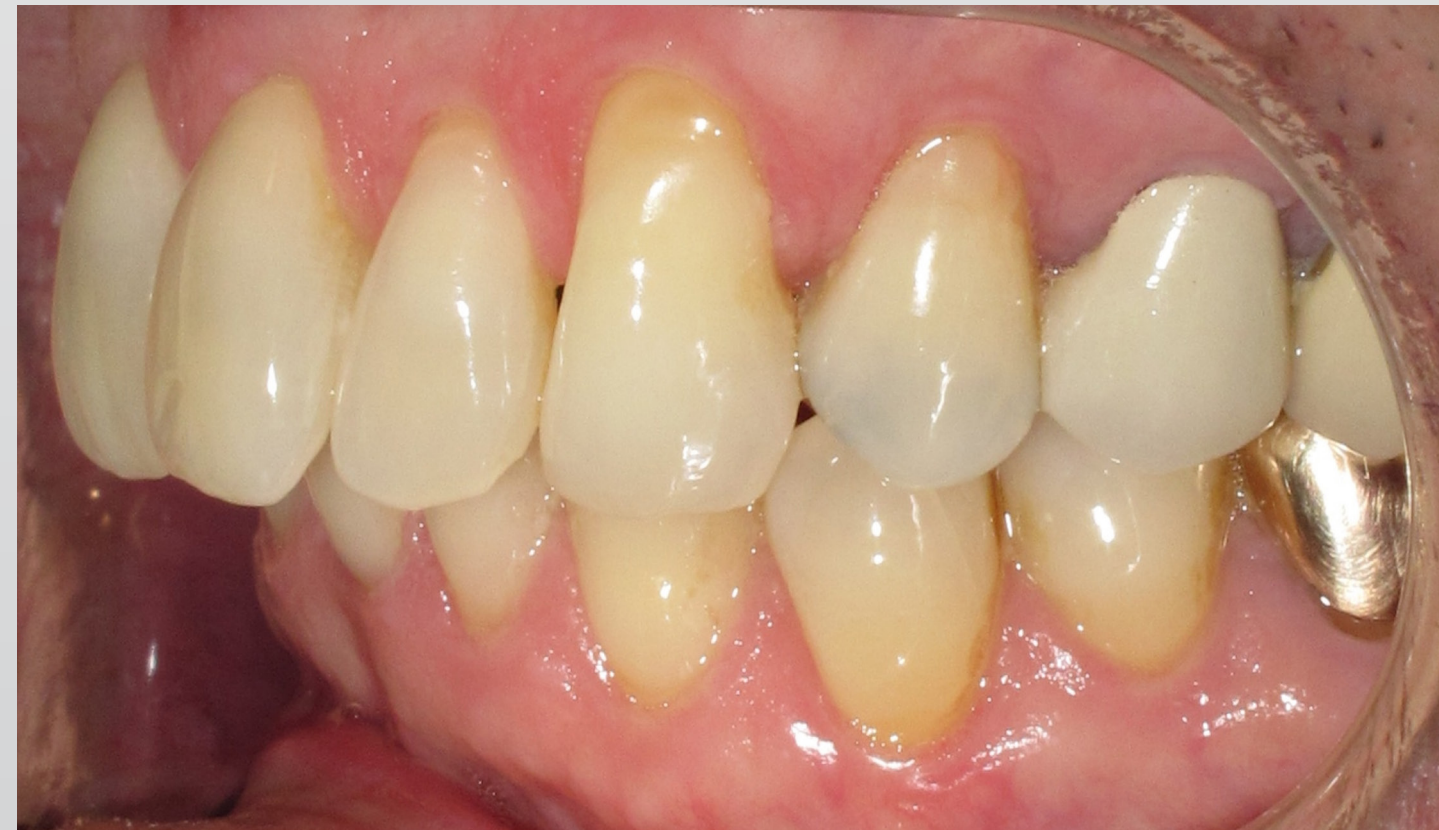Retracted buccal – right



Retracted anterior biting

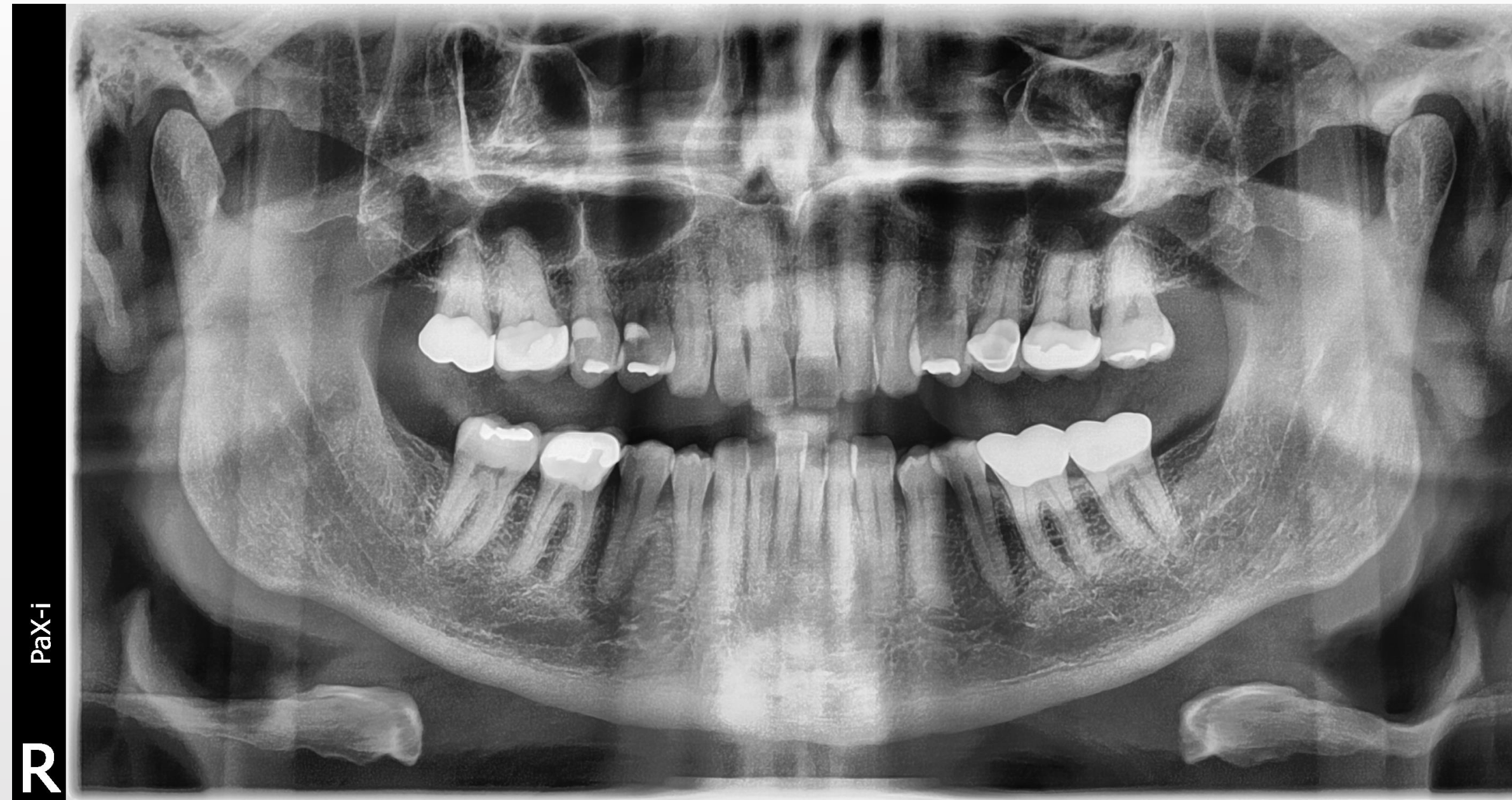

Retracted buccal – left

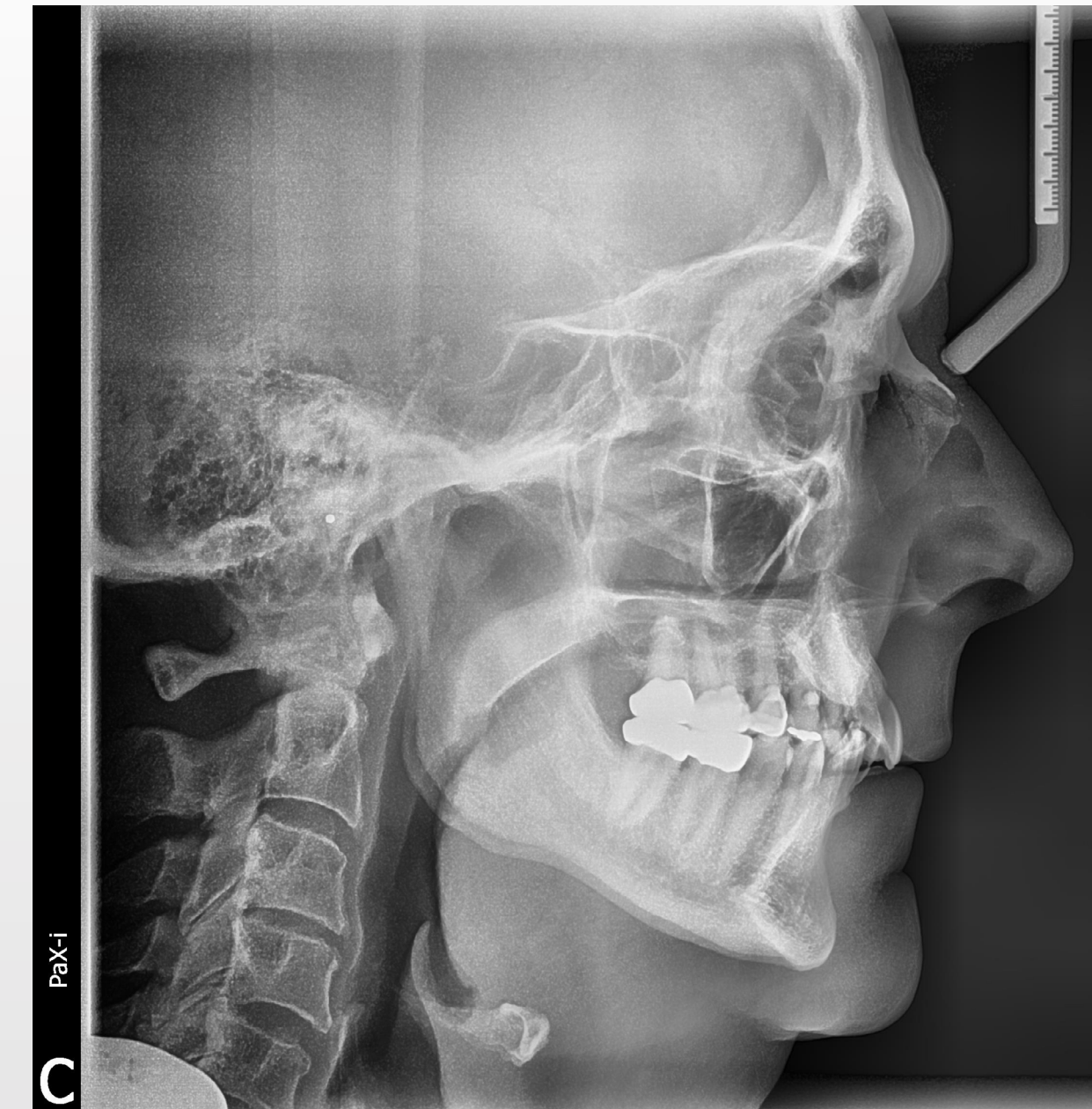


Initial

Panoramic radiograph



Ceph.



Final



