

**Case Study:** 3M™ Clarity™ Aligners

## Non-extraction adult treatment of crowding and deep bite through arch expansion.

**Age:** 51

**Total number of aligners:** 33 (dual arch)

**Wear interval:** Weekly

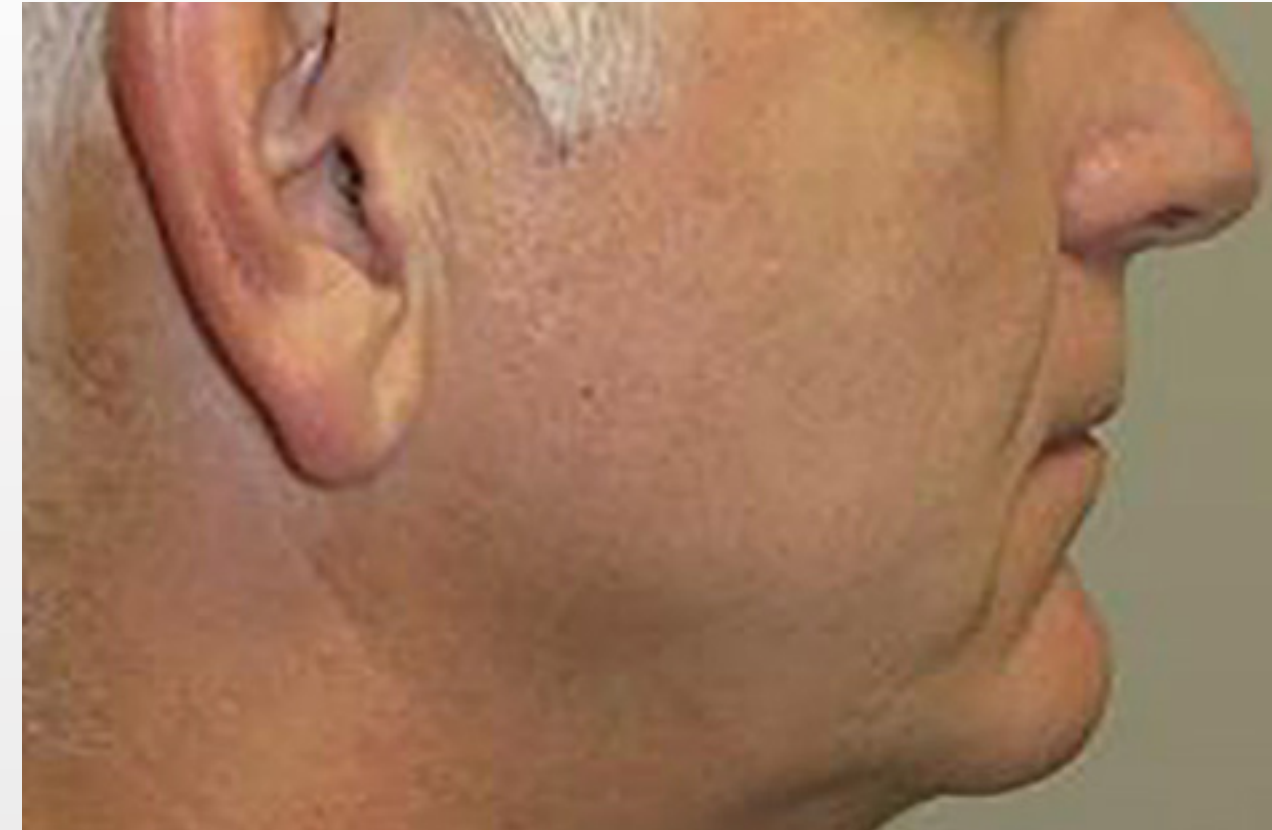**Treatment time:** 17 months

**IPR:** Total IPR Upper Arch = 0.2 mm

**Case courtesy of:**

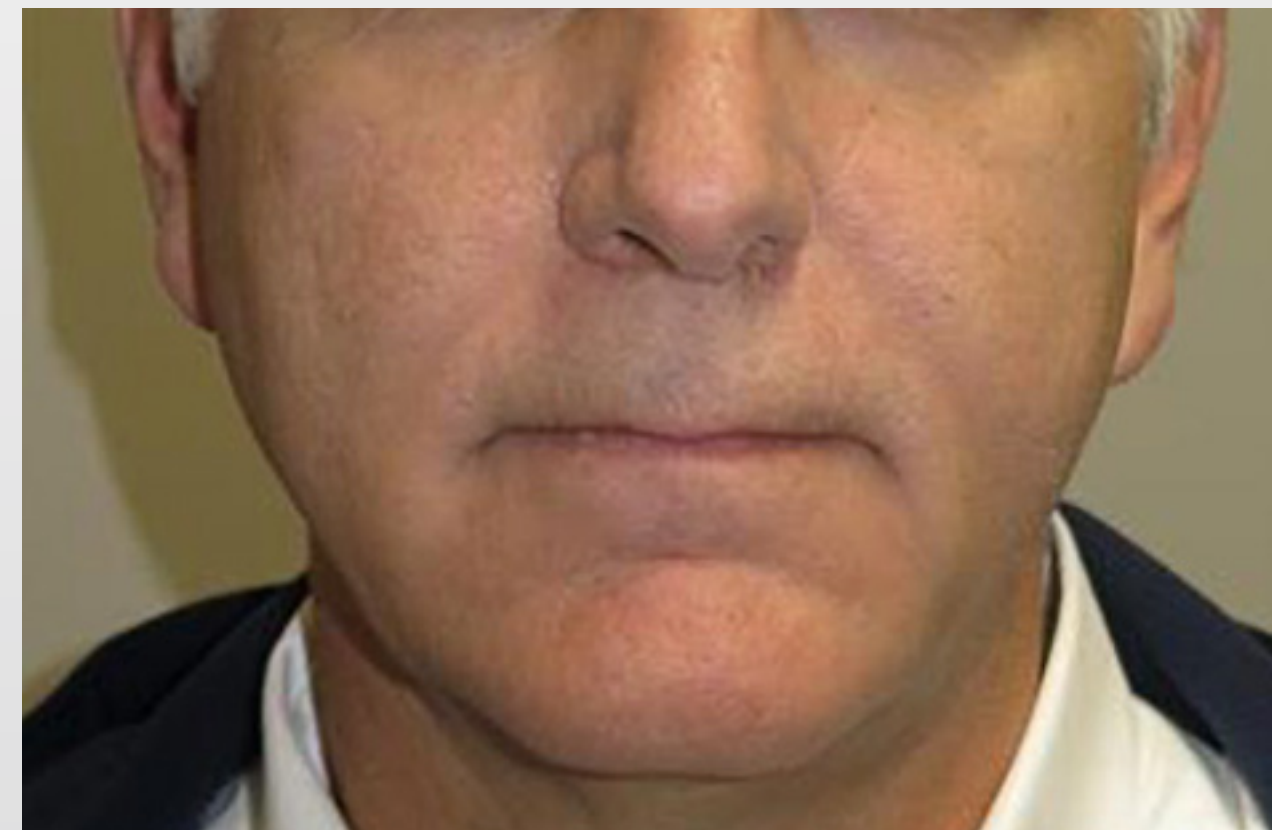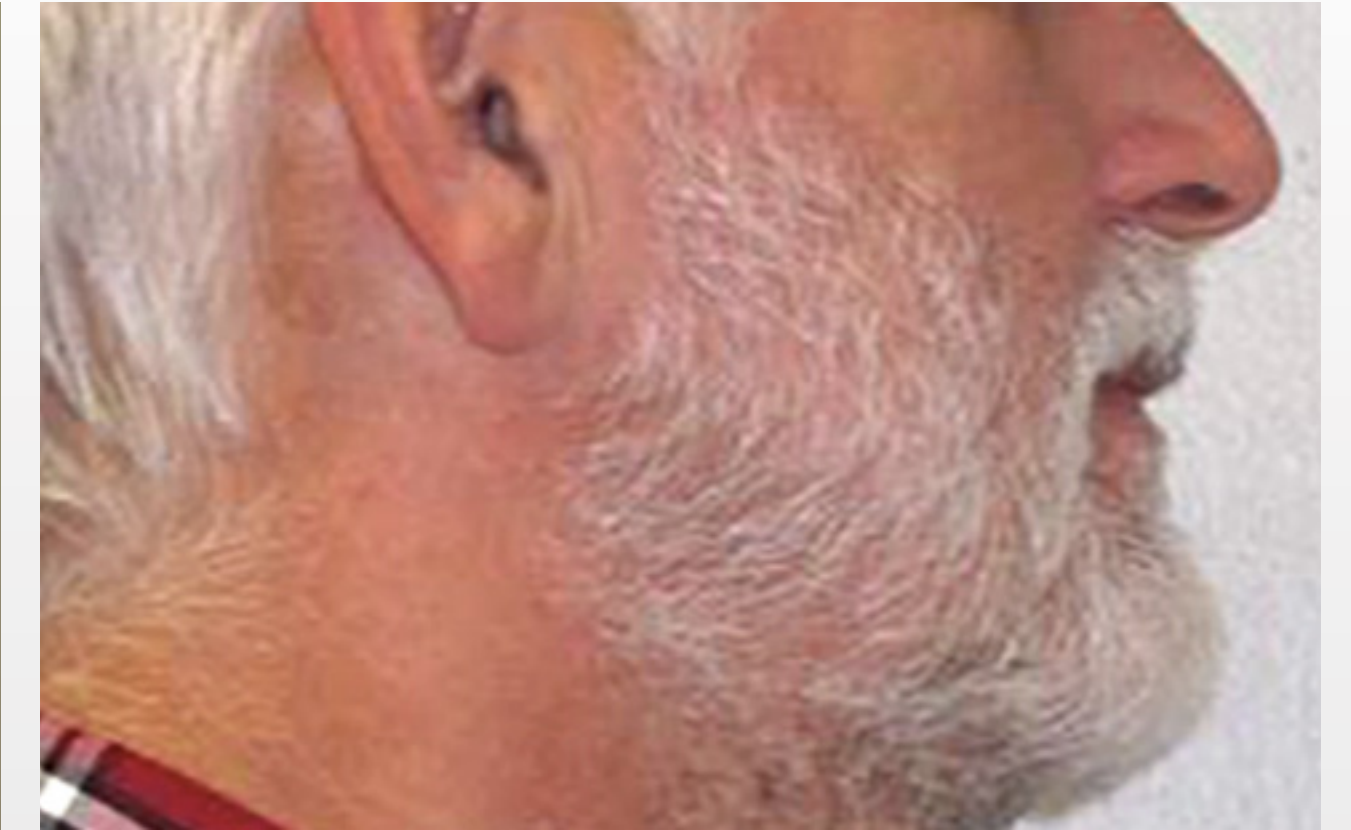Dr. Shane Langley & Dr. Rick O'Neil  
South Alabama Orthodontics, Fairhope, AL – USA

**Initial**

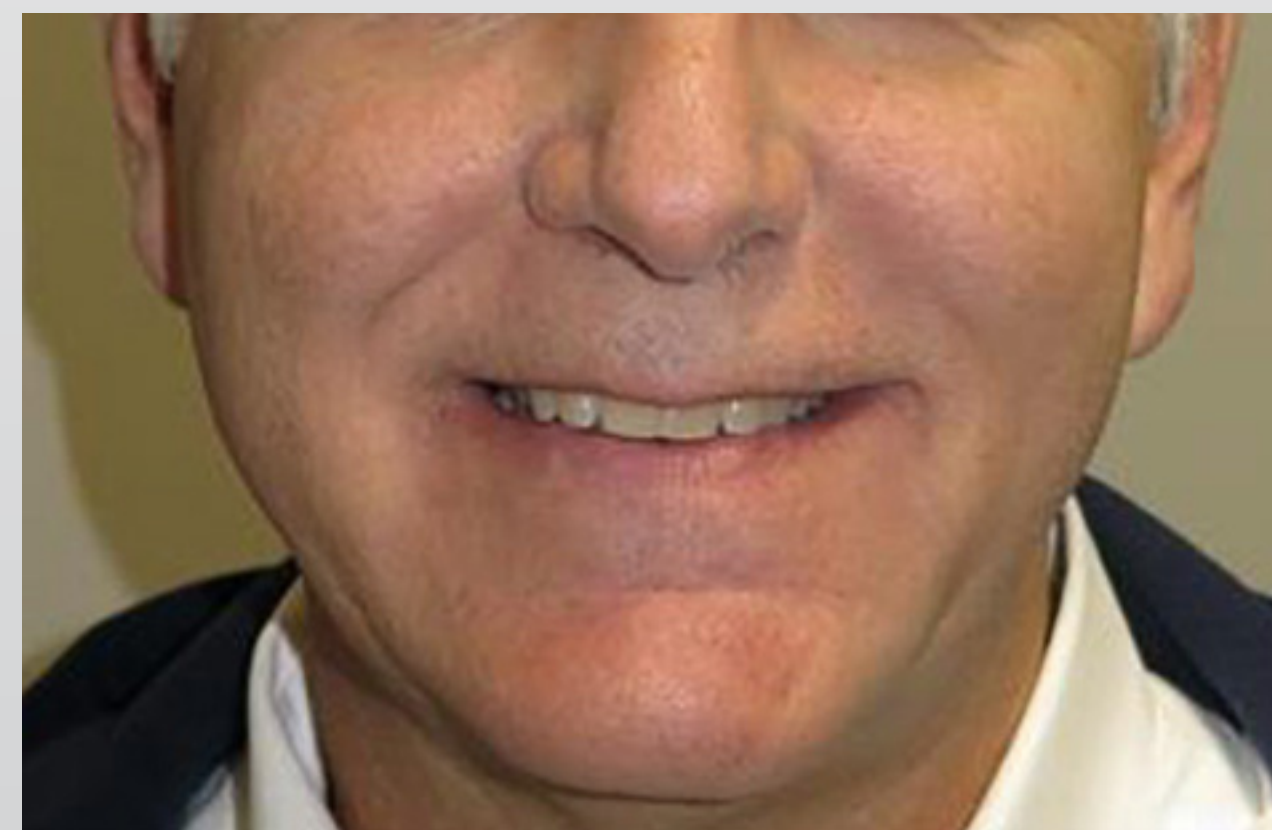
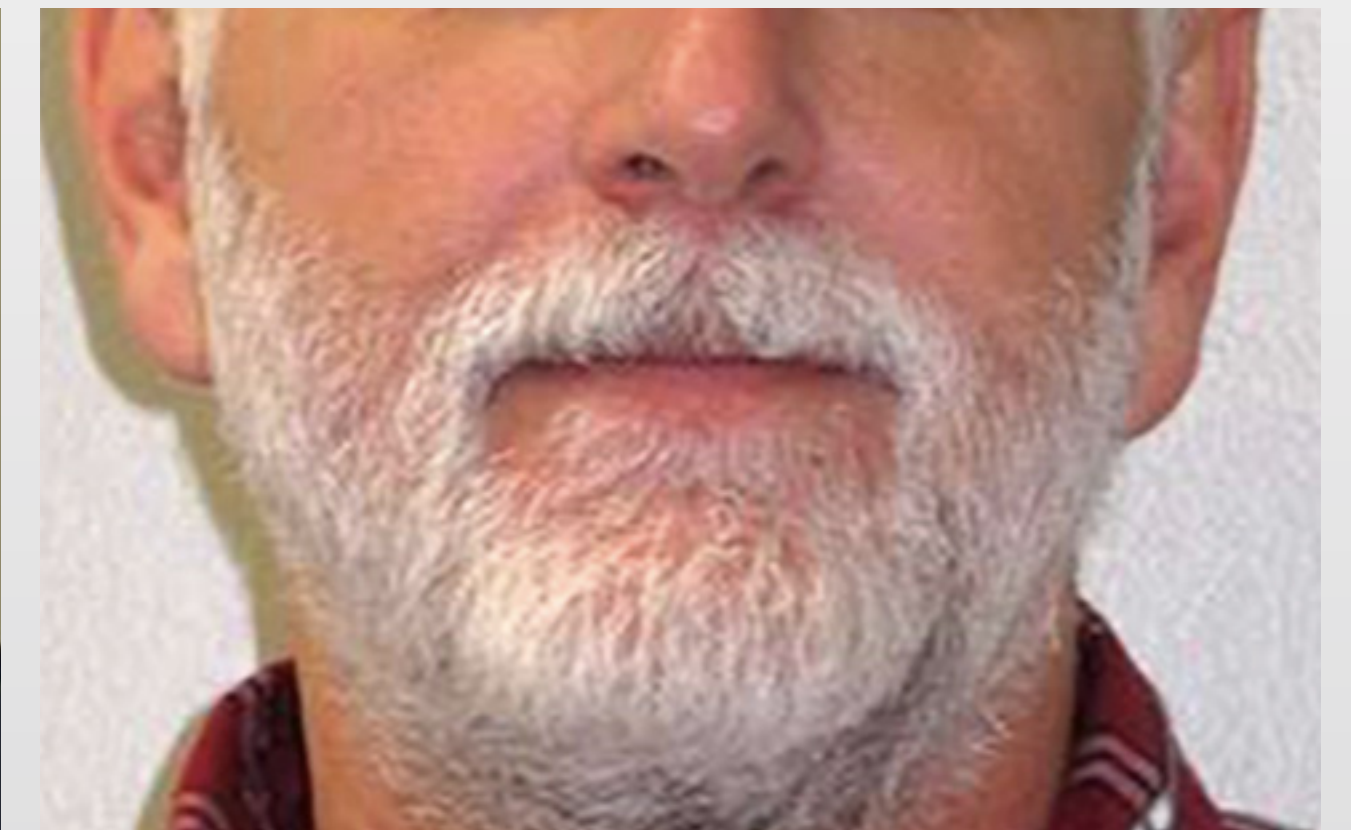
**Profile at rest**

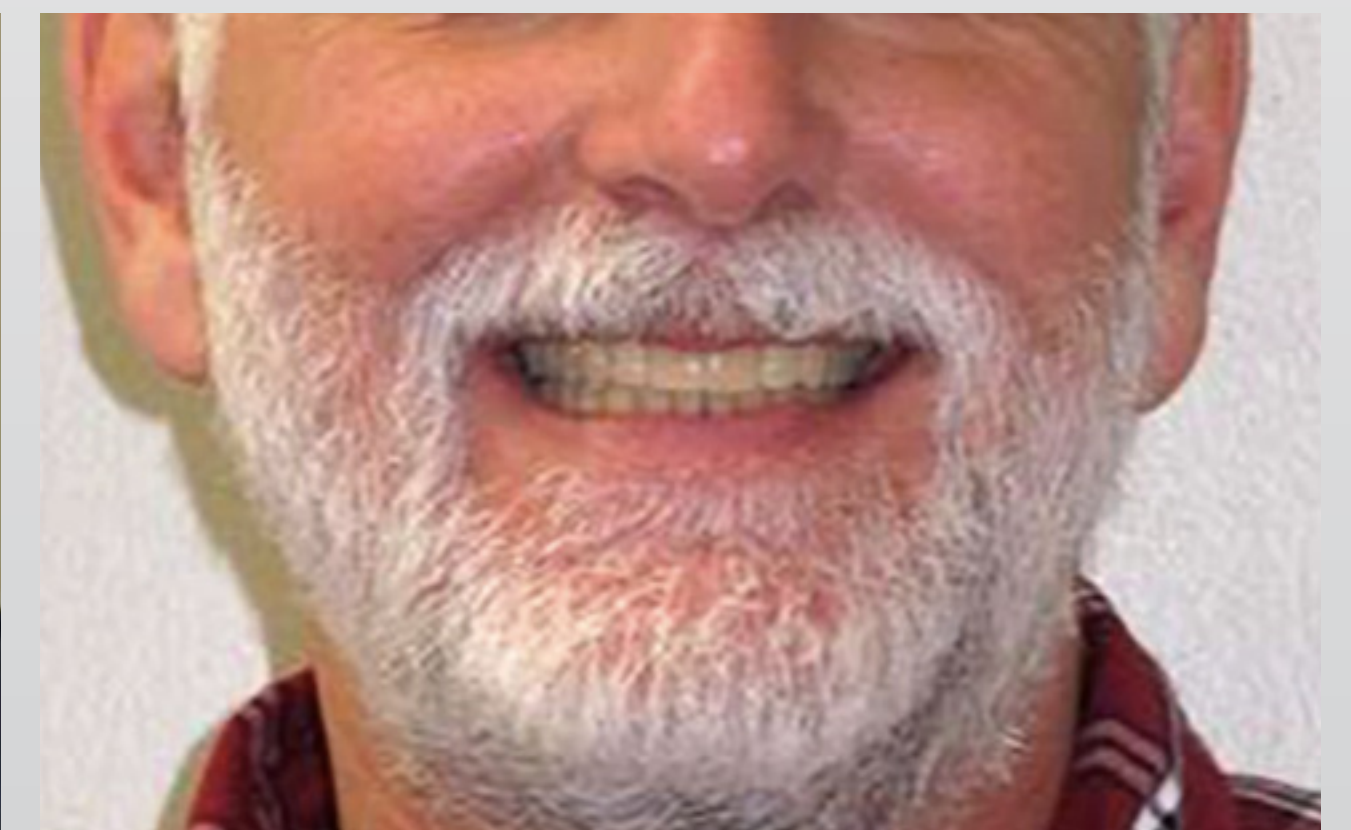
**Final**



**Face at rest**



**Face smiling**

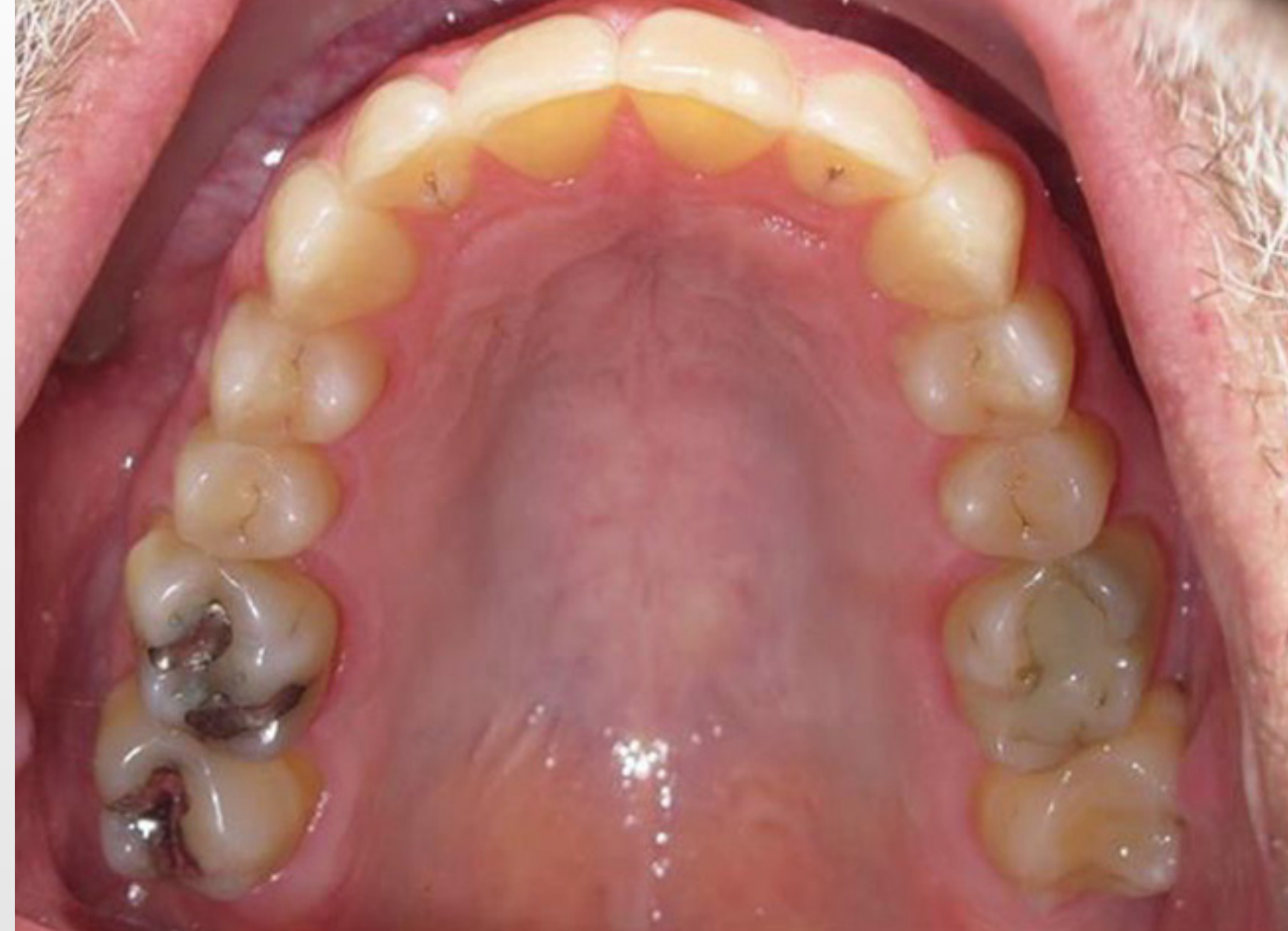
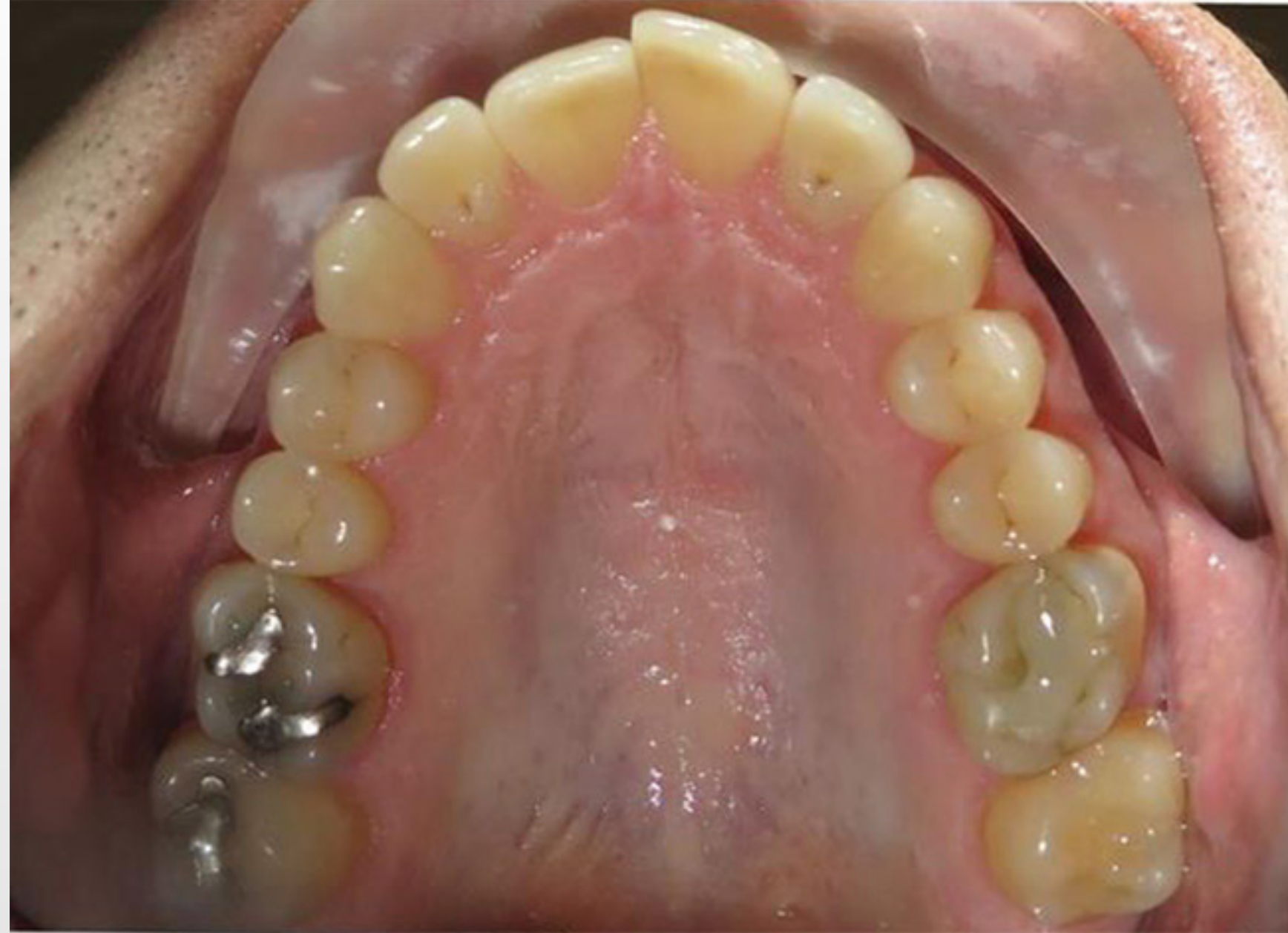


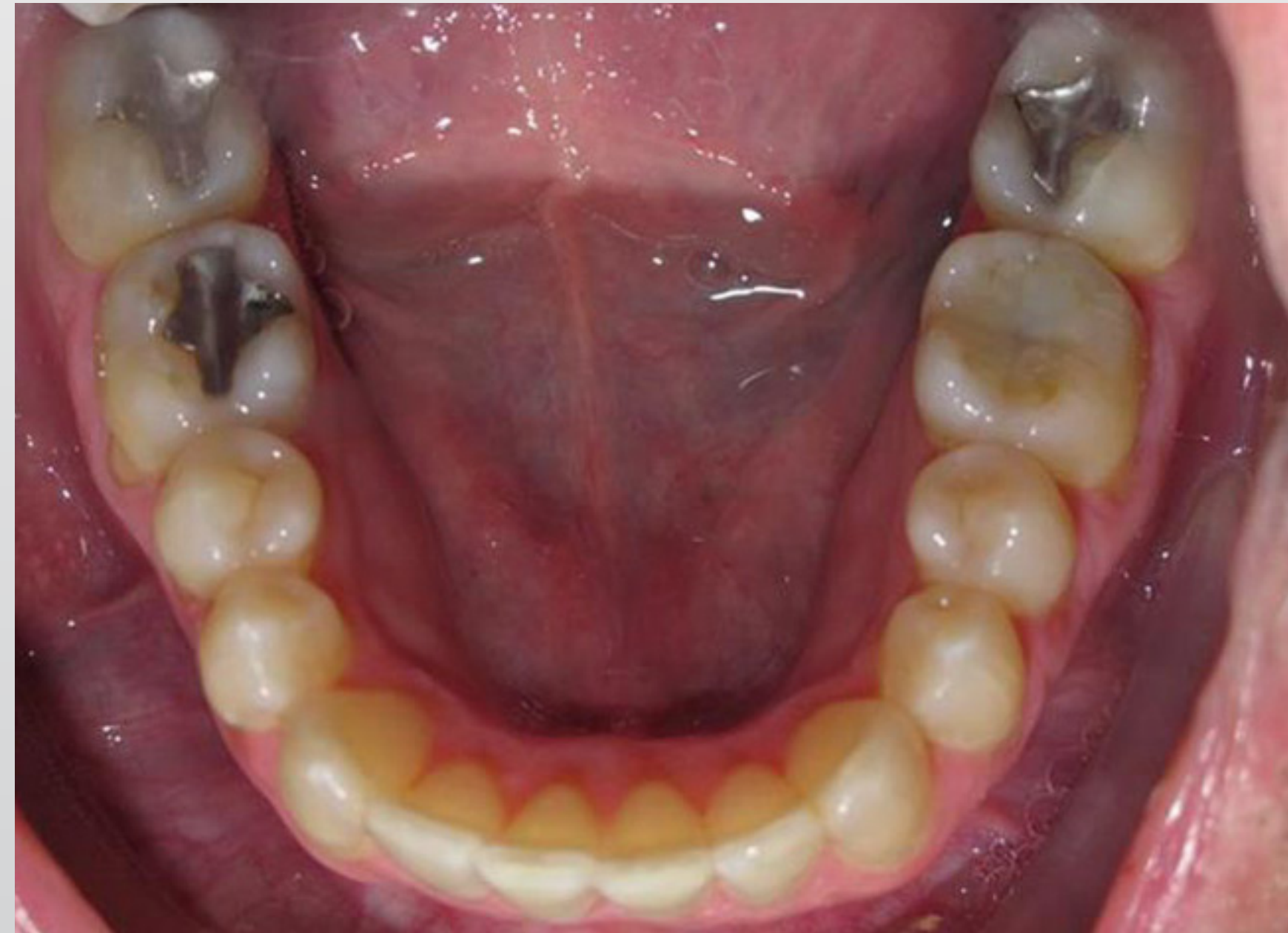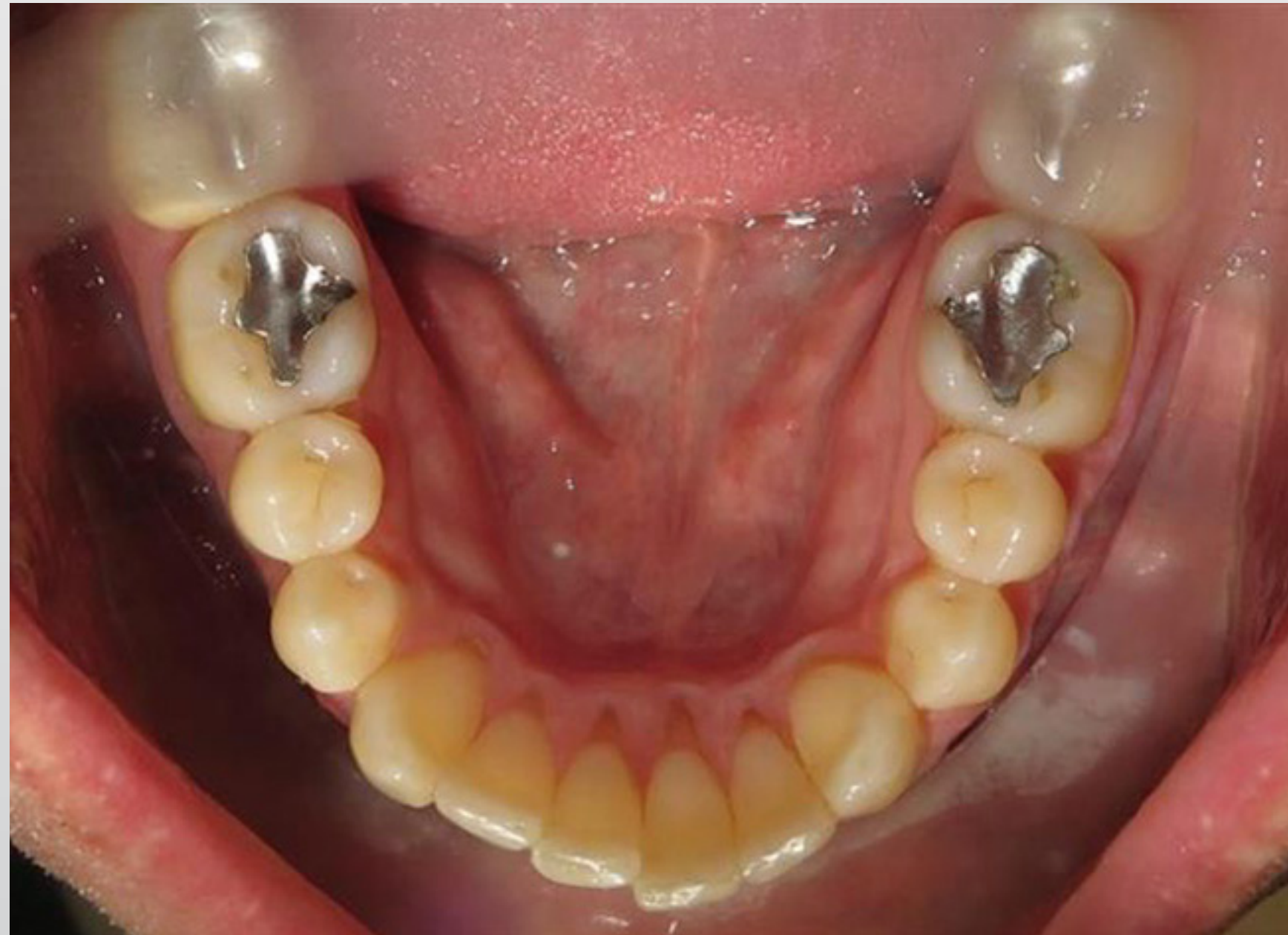**Initial**

**Final**

**Occlusal –  
maxillary**



**Occlusal –  
mandibular**

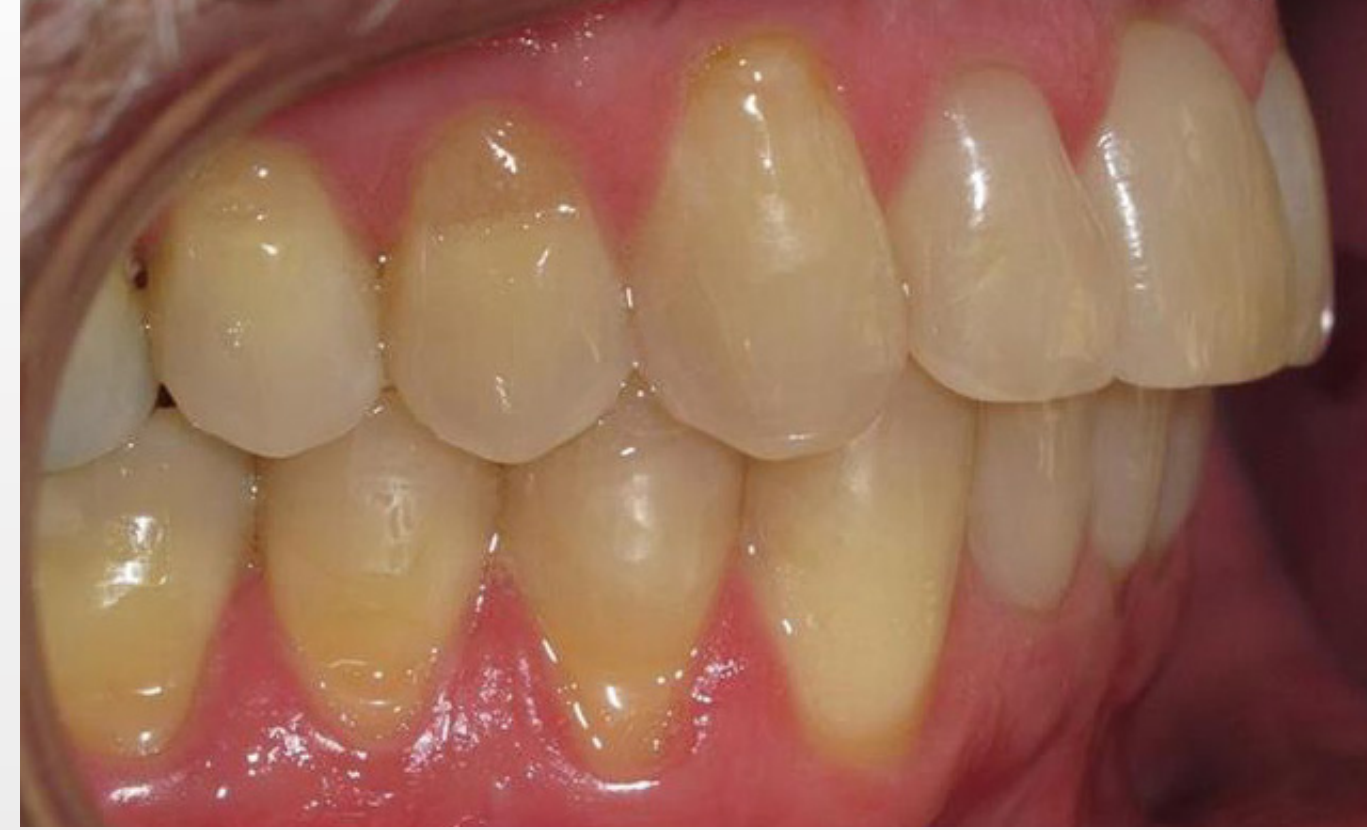
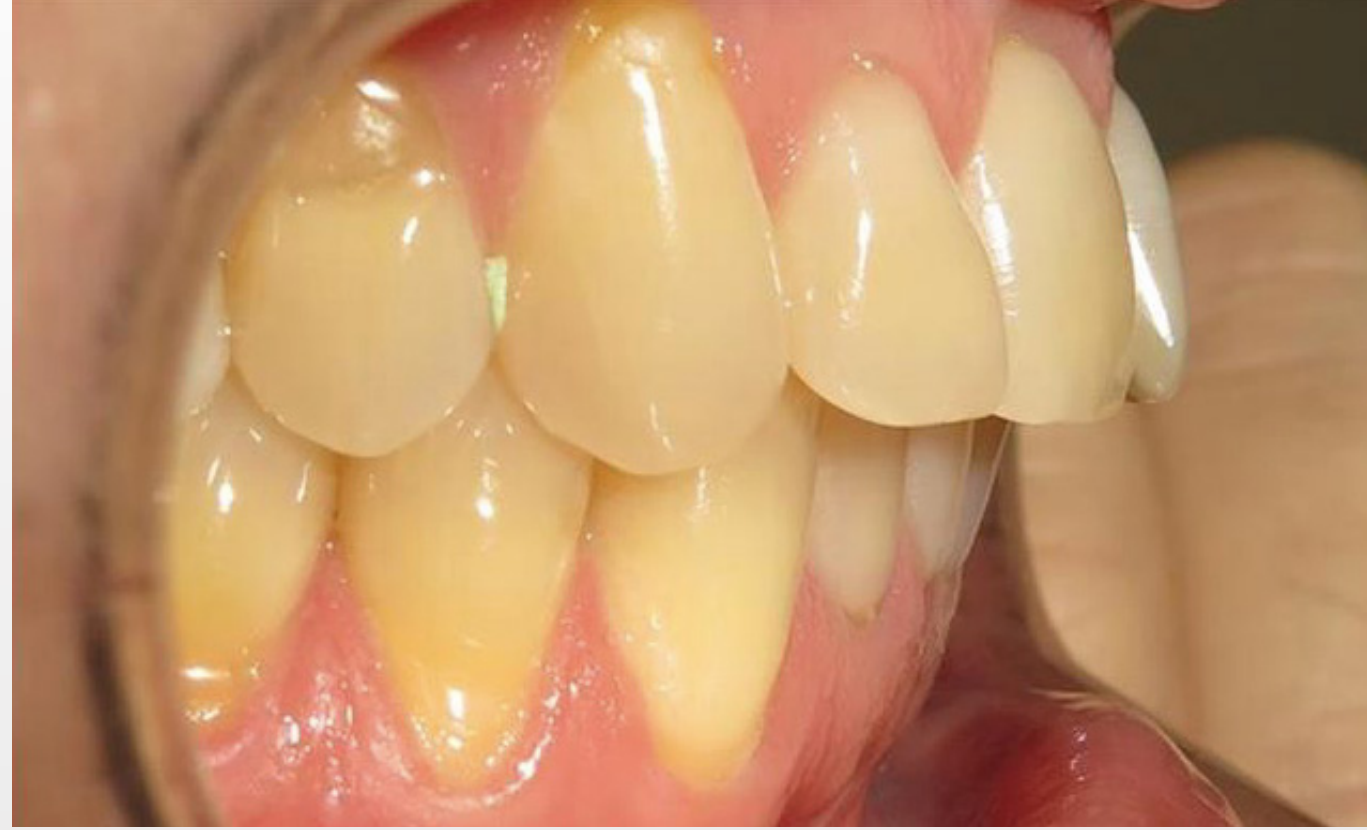


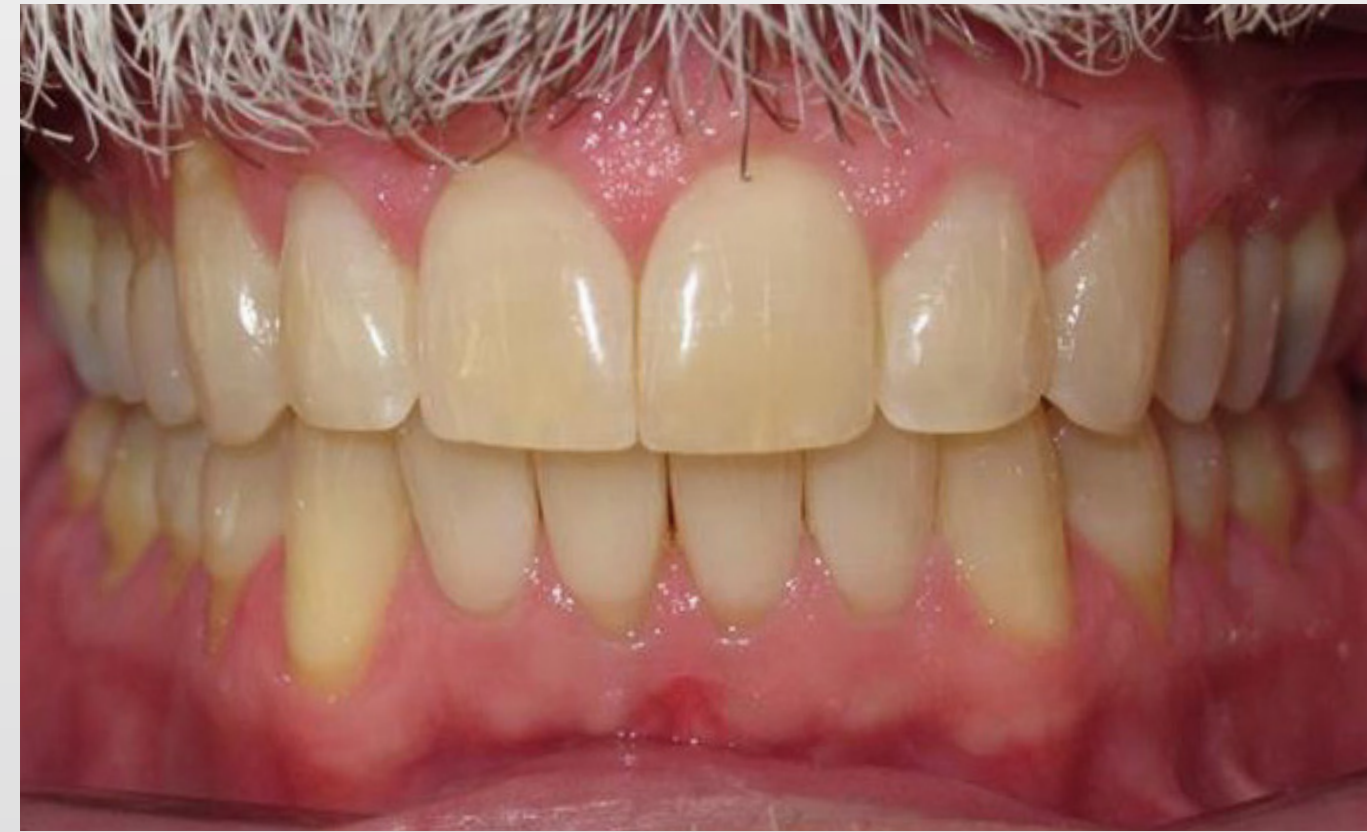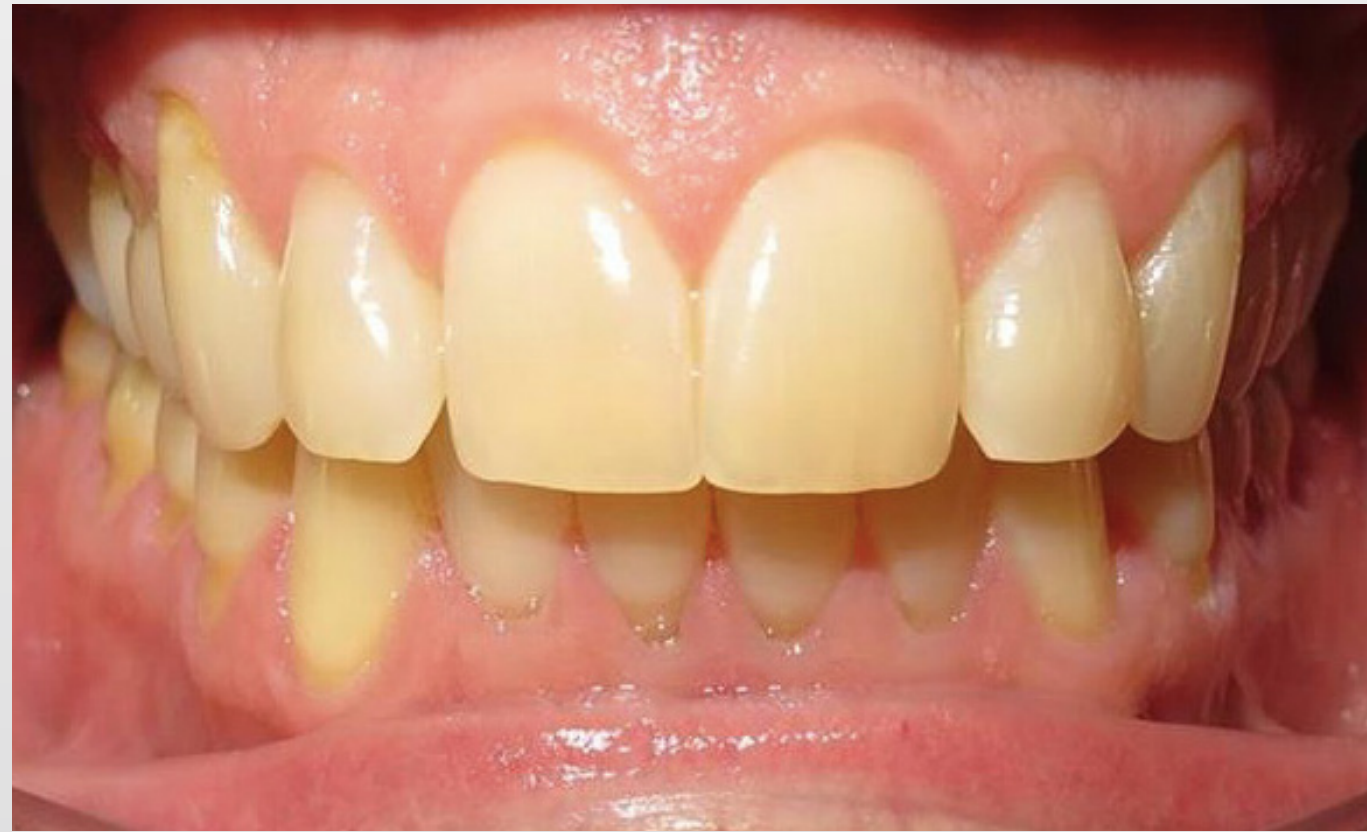**Initial**

**Final**

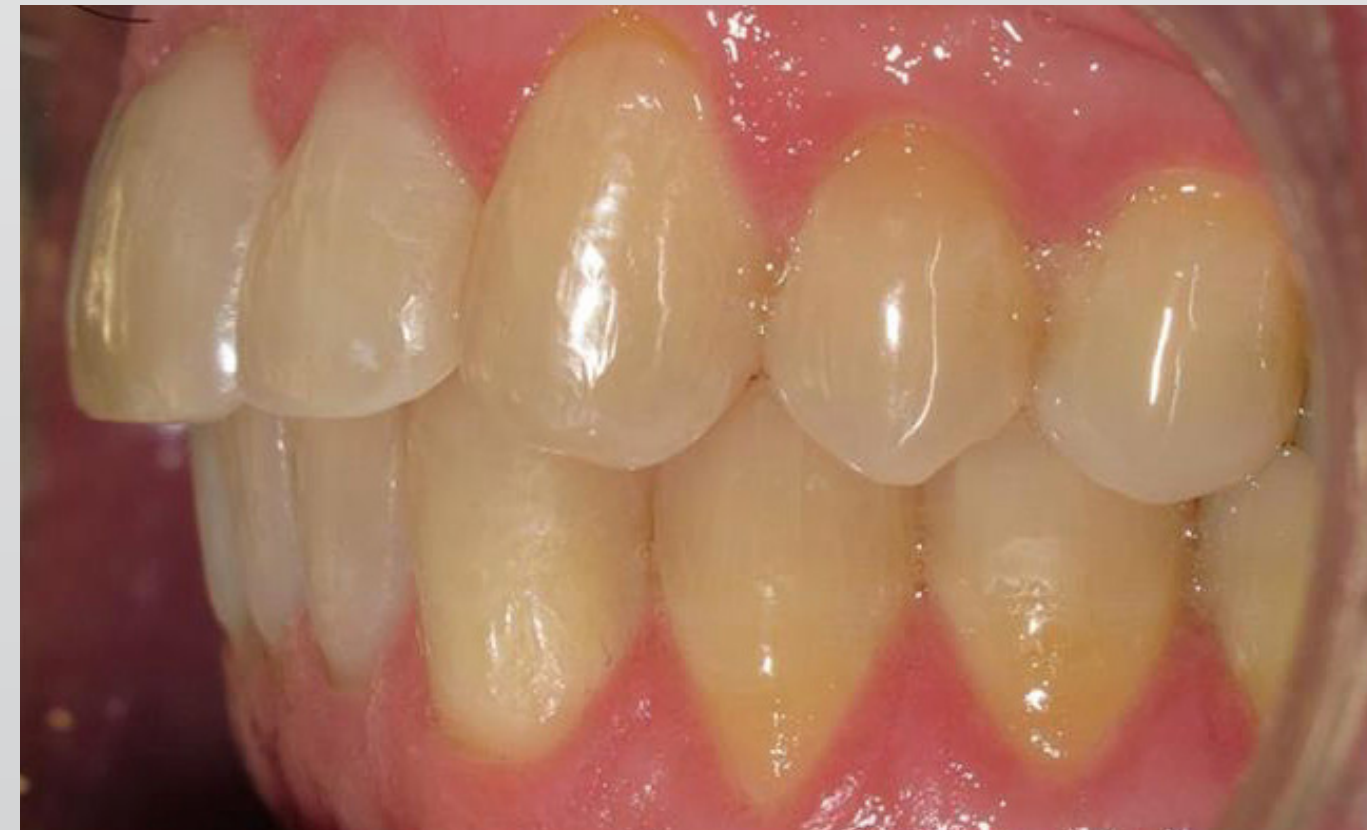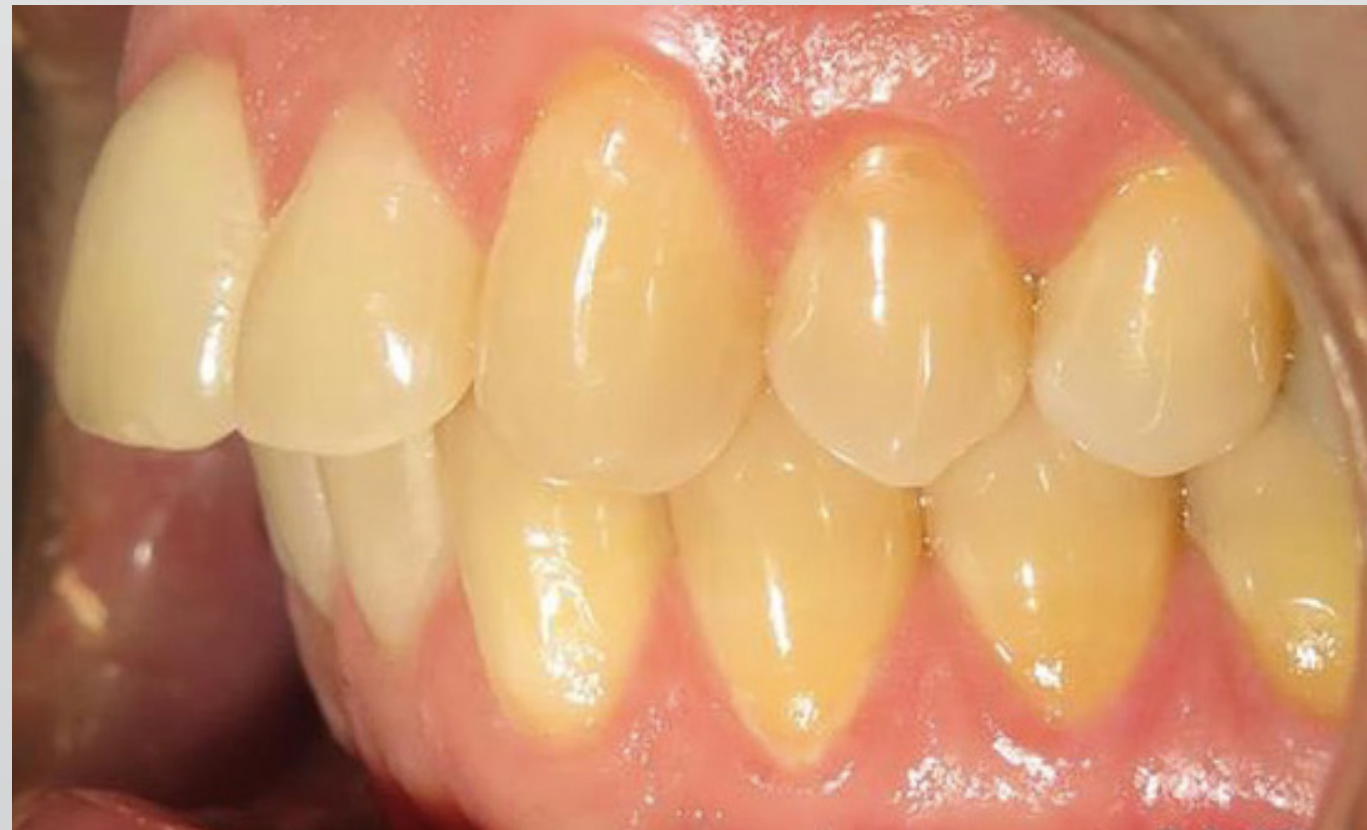**Retracted buccal – right**



**Retracted anterior biting**



**Retracted buccal – left**





**Panoramic radiograph**

**Initial**



