

Case Study: 3M™ Clarity™ Aligners

Class II treatment with a deep bite.

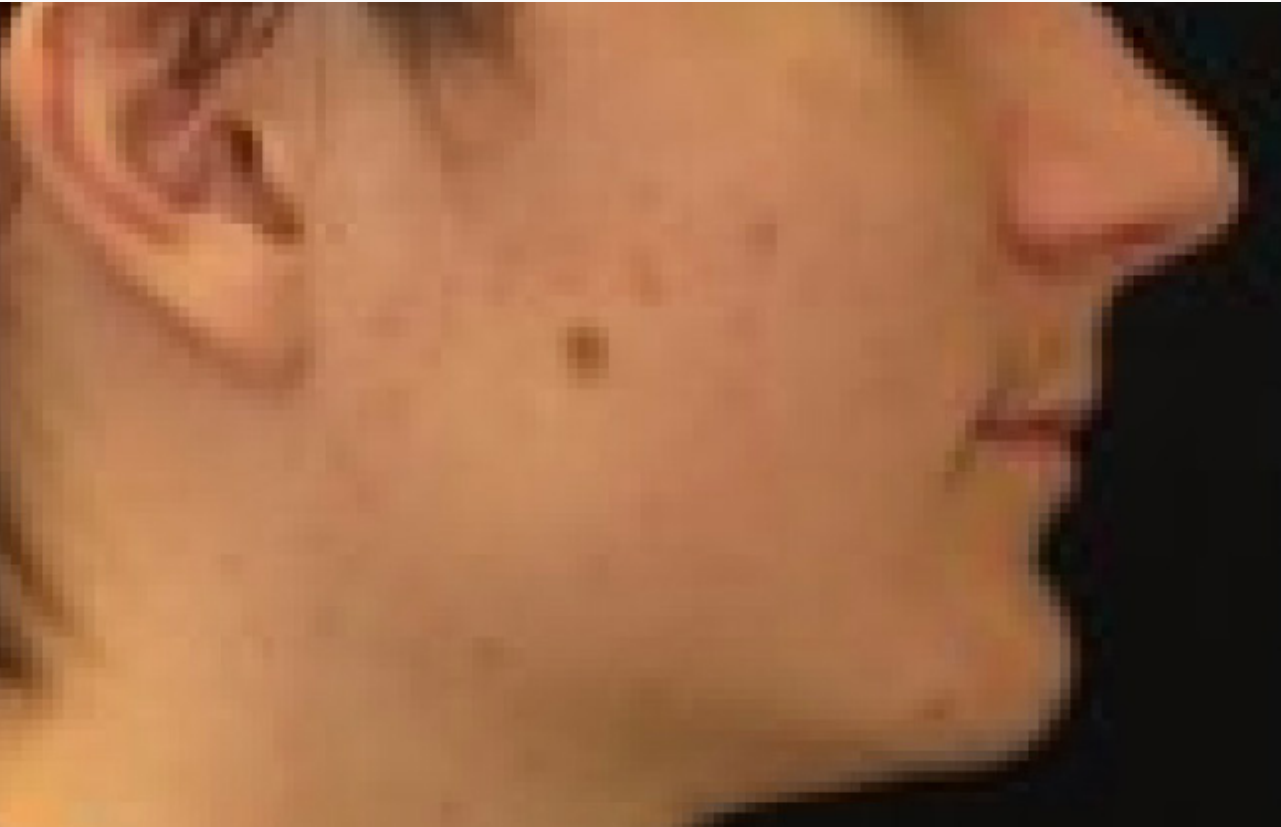
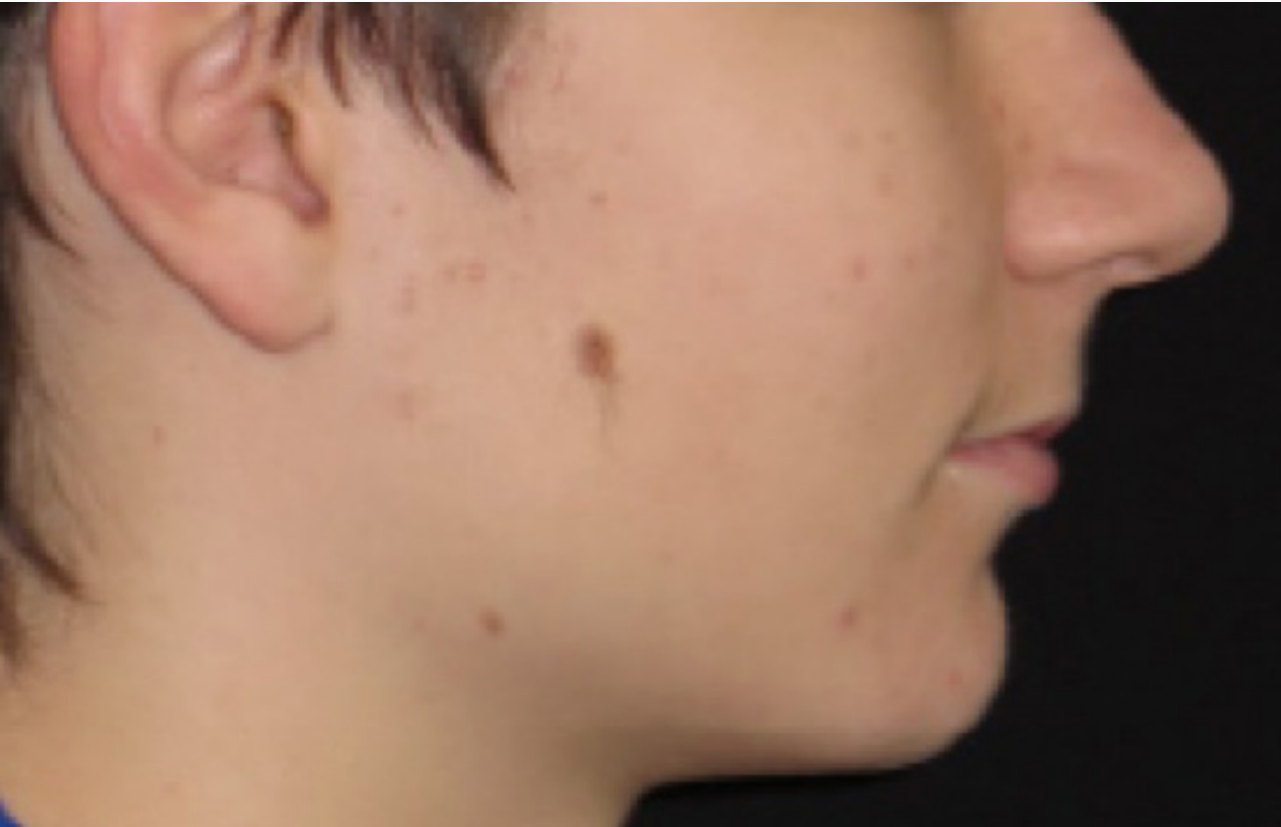Age: 13
Total number of aligners: 30 (dual arch)
Wear interval: Weekly
Treatment time: 9 months

Case courtesy of:
Hughes Orthodontics
Alexandria, VA – USA

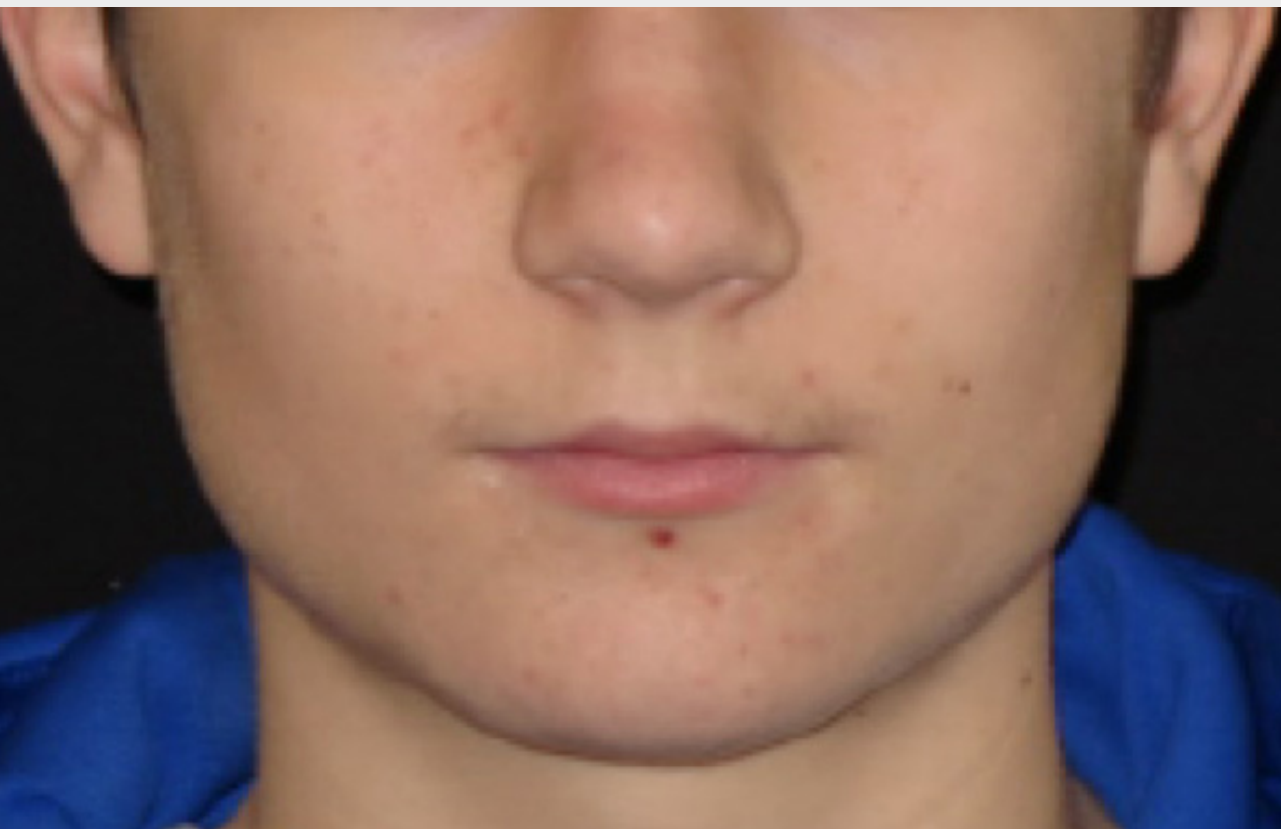
Initial

Final

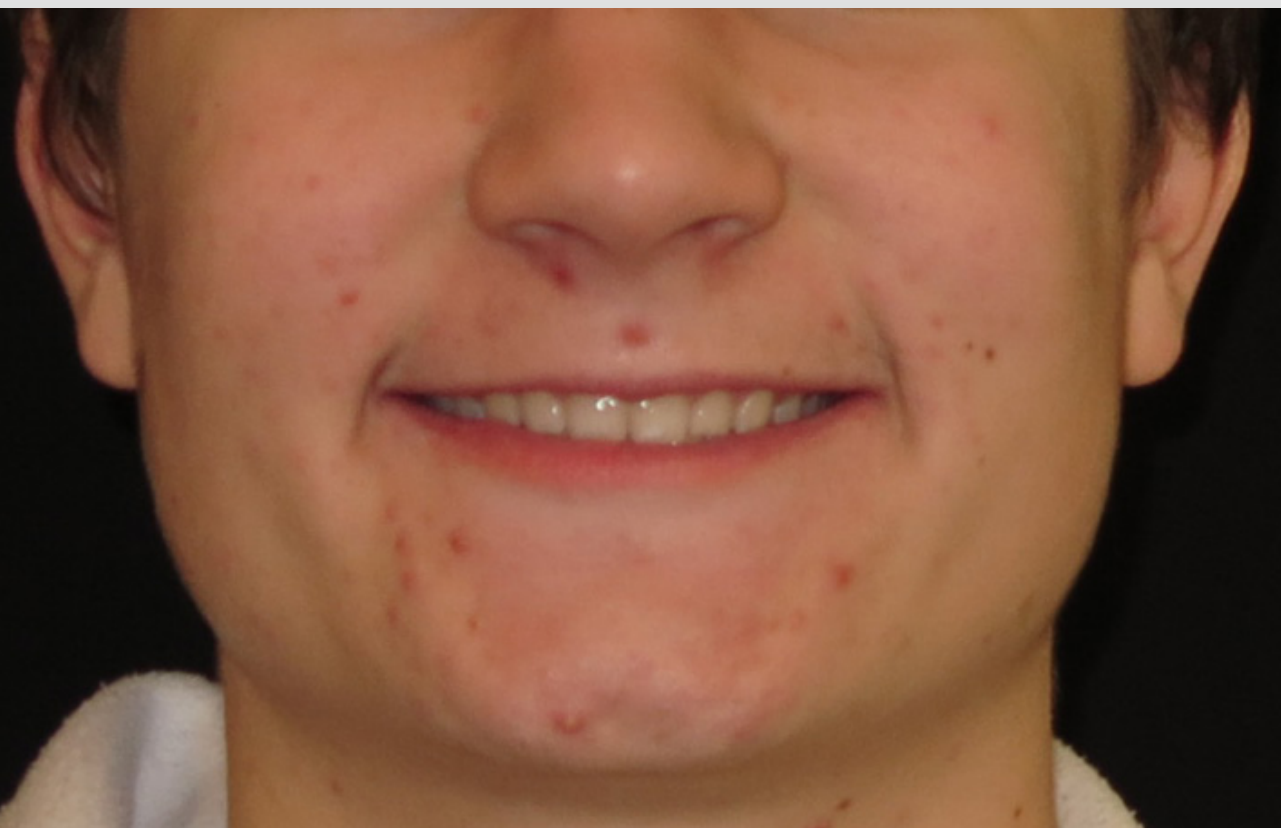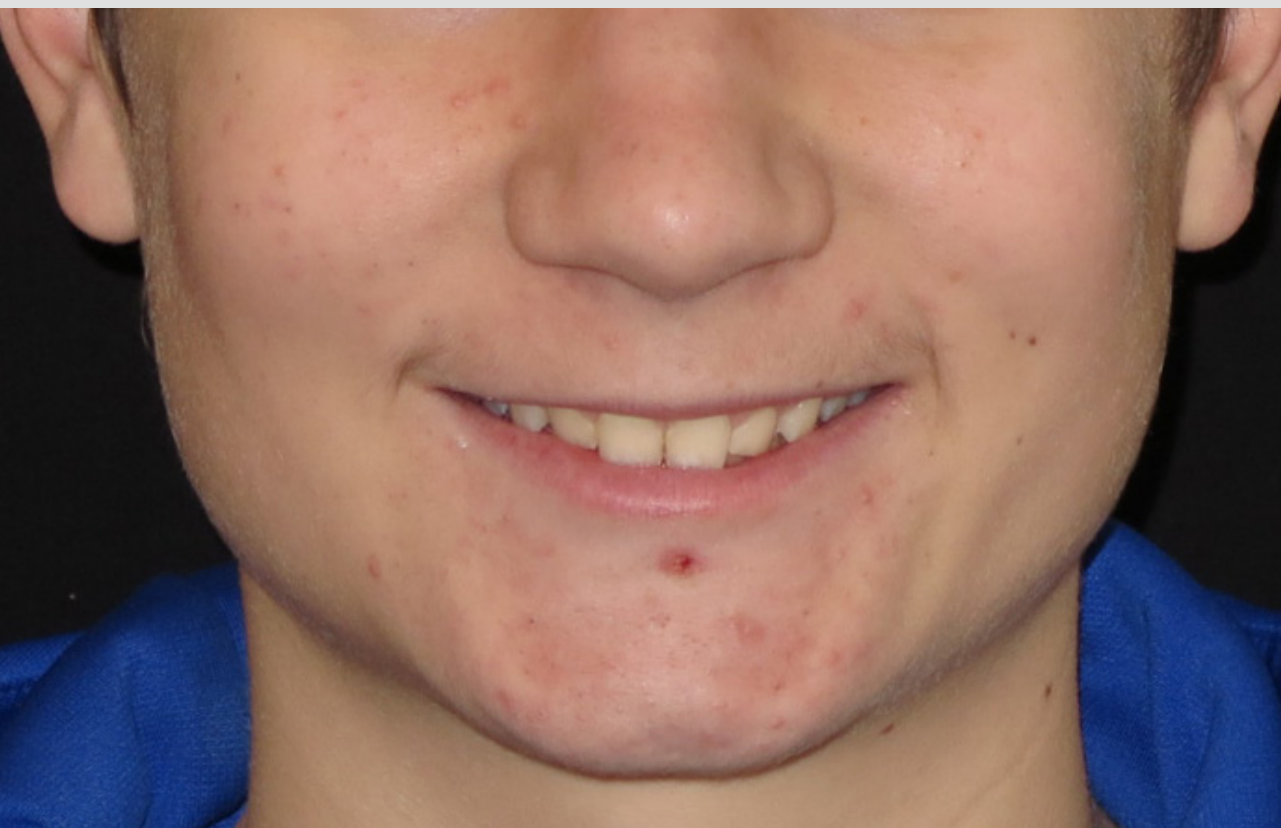Profile at rest



Face at rest



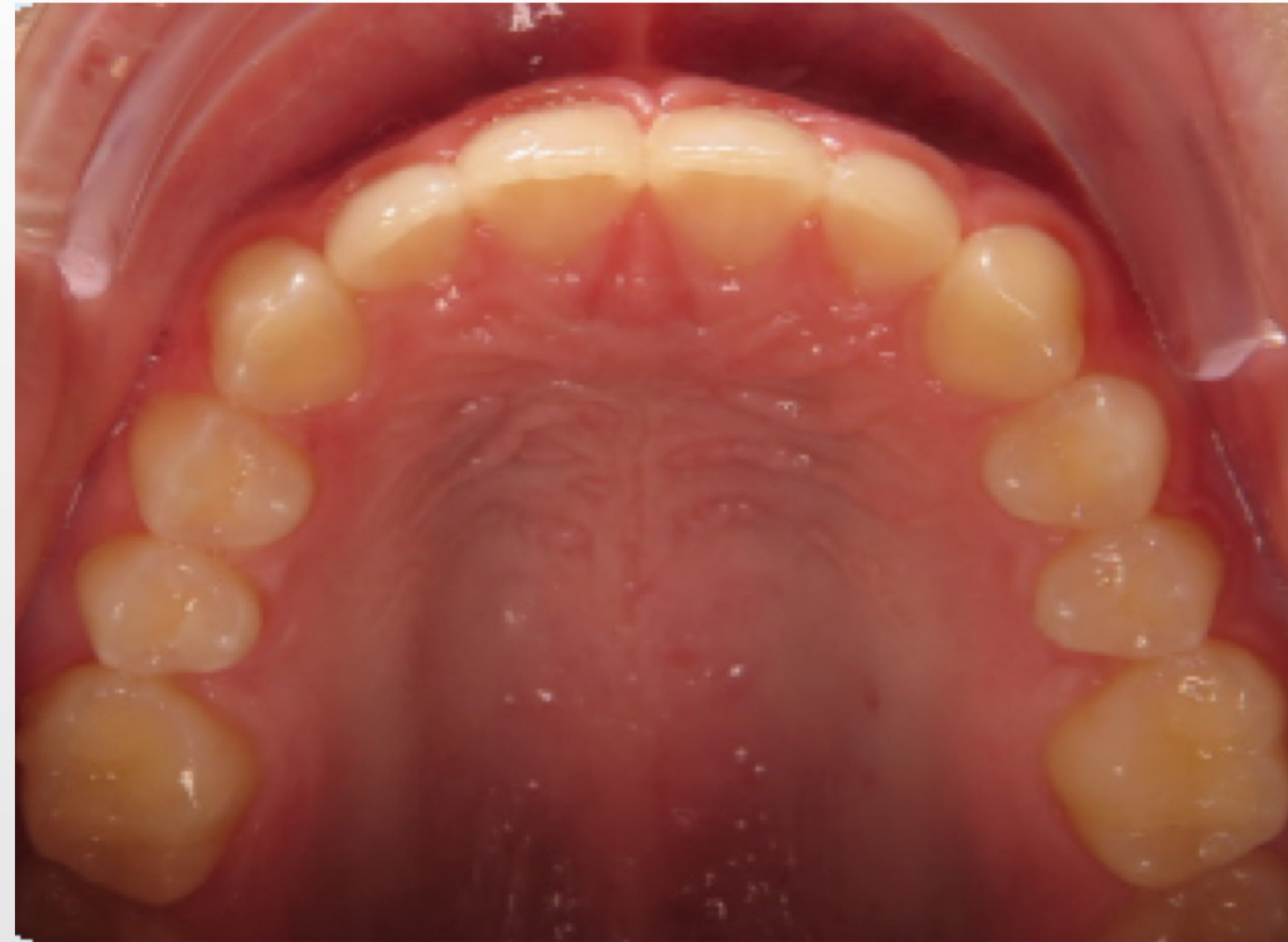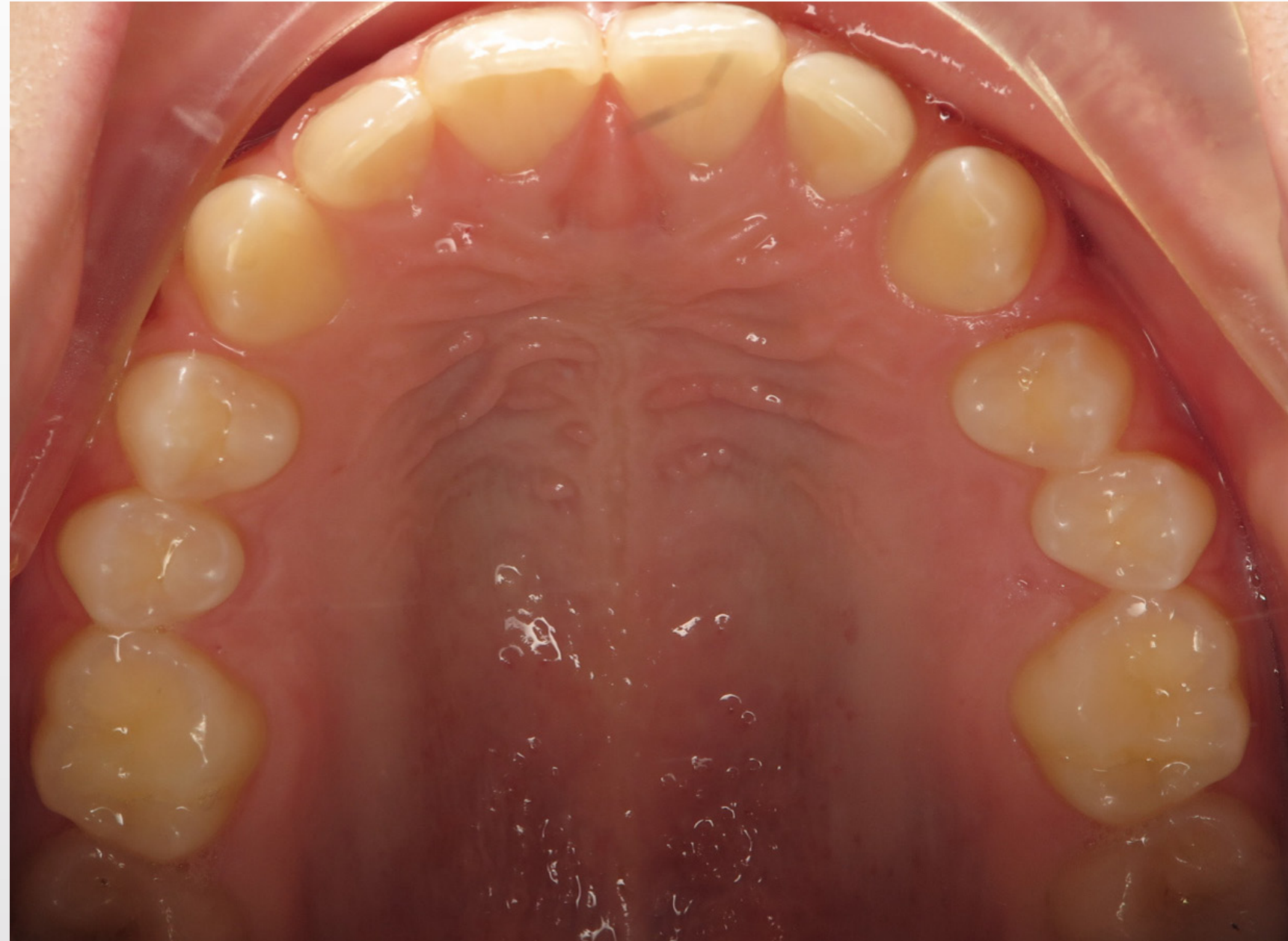
Face smiling



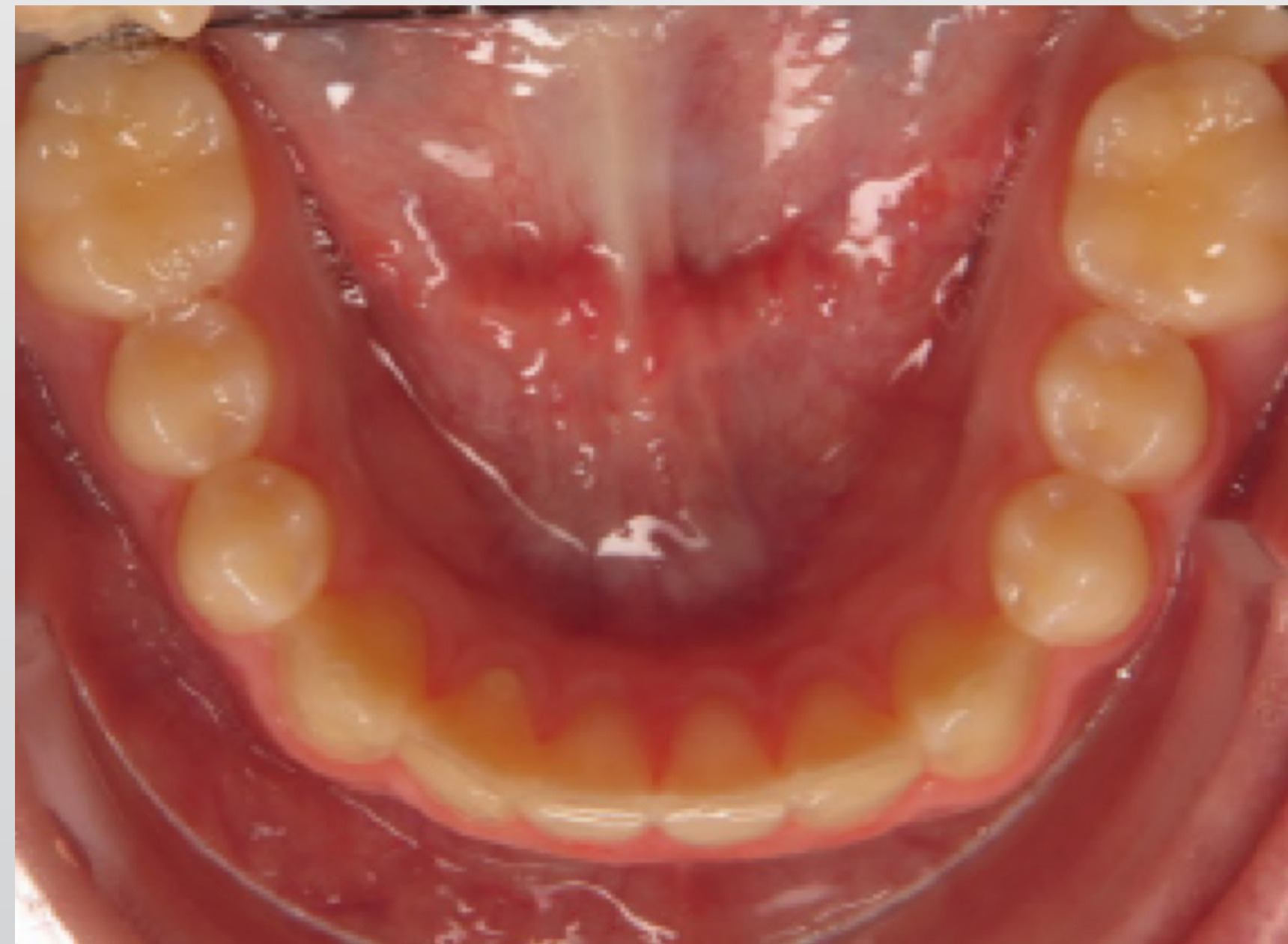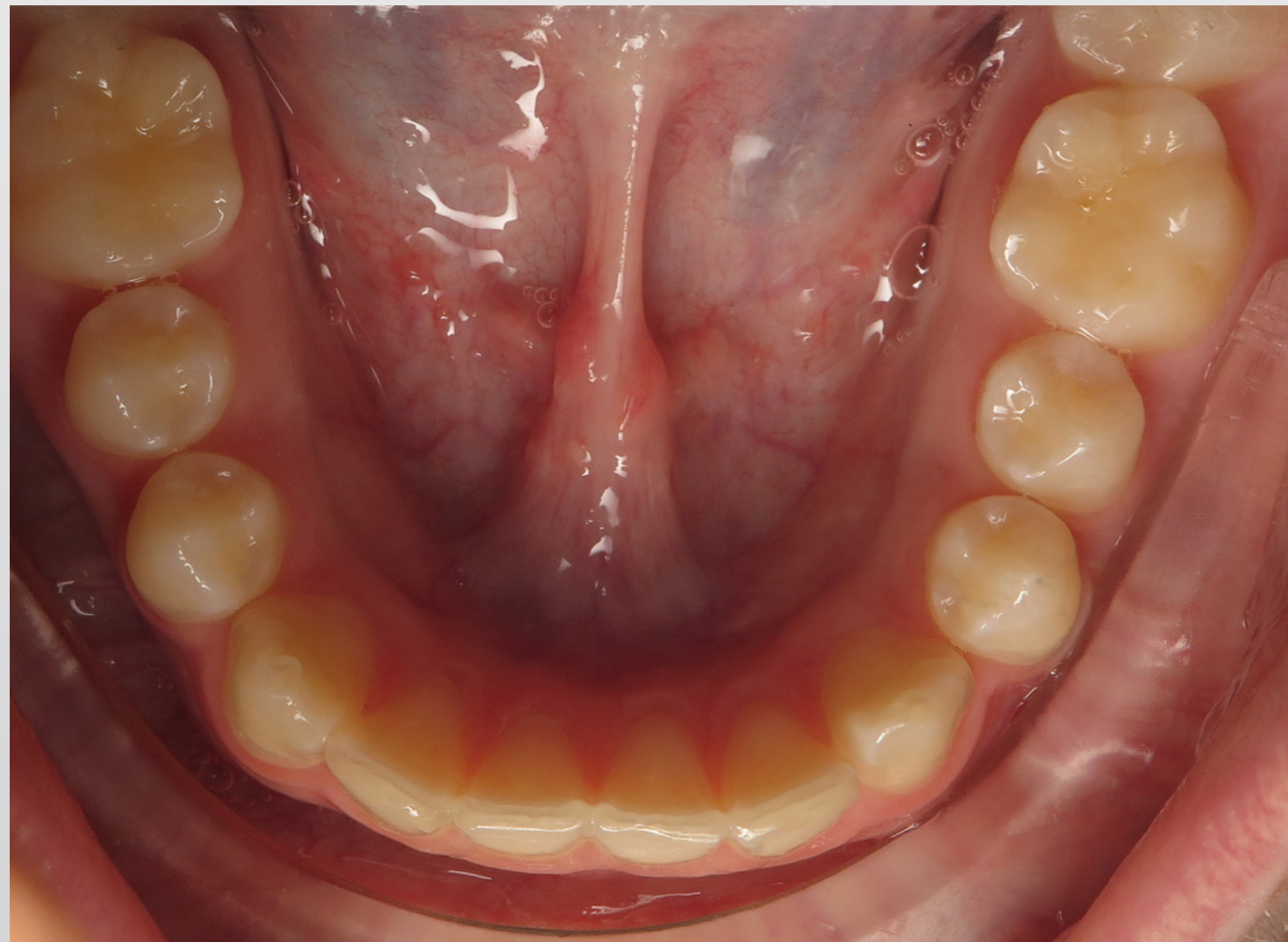Initial

Final

**Occlusal –
maxillary**



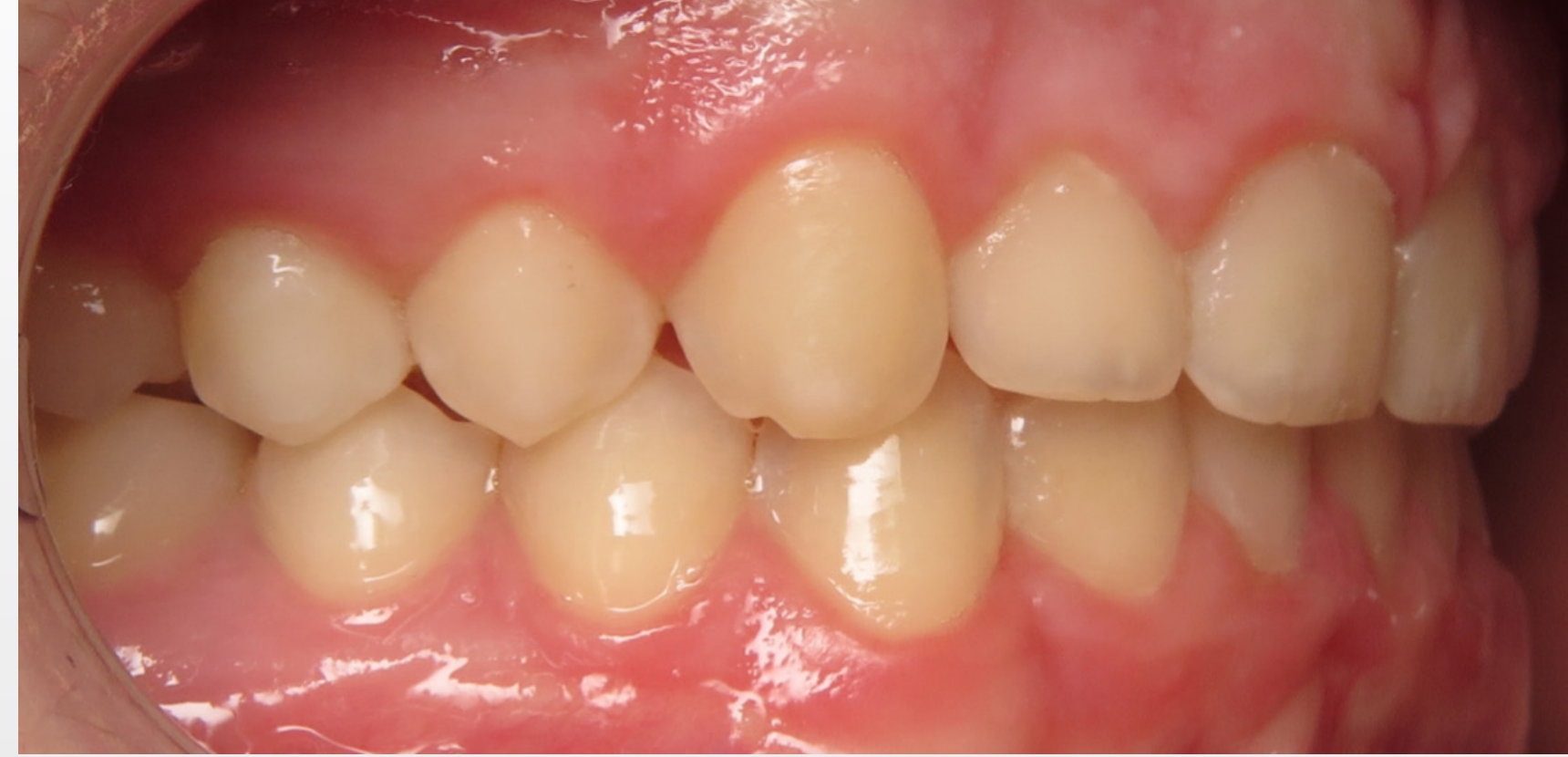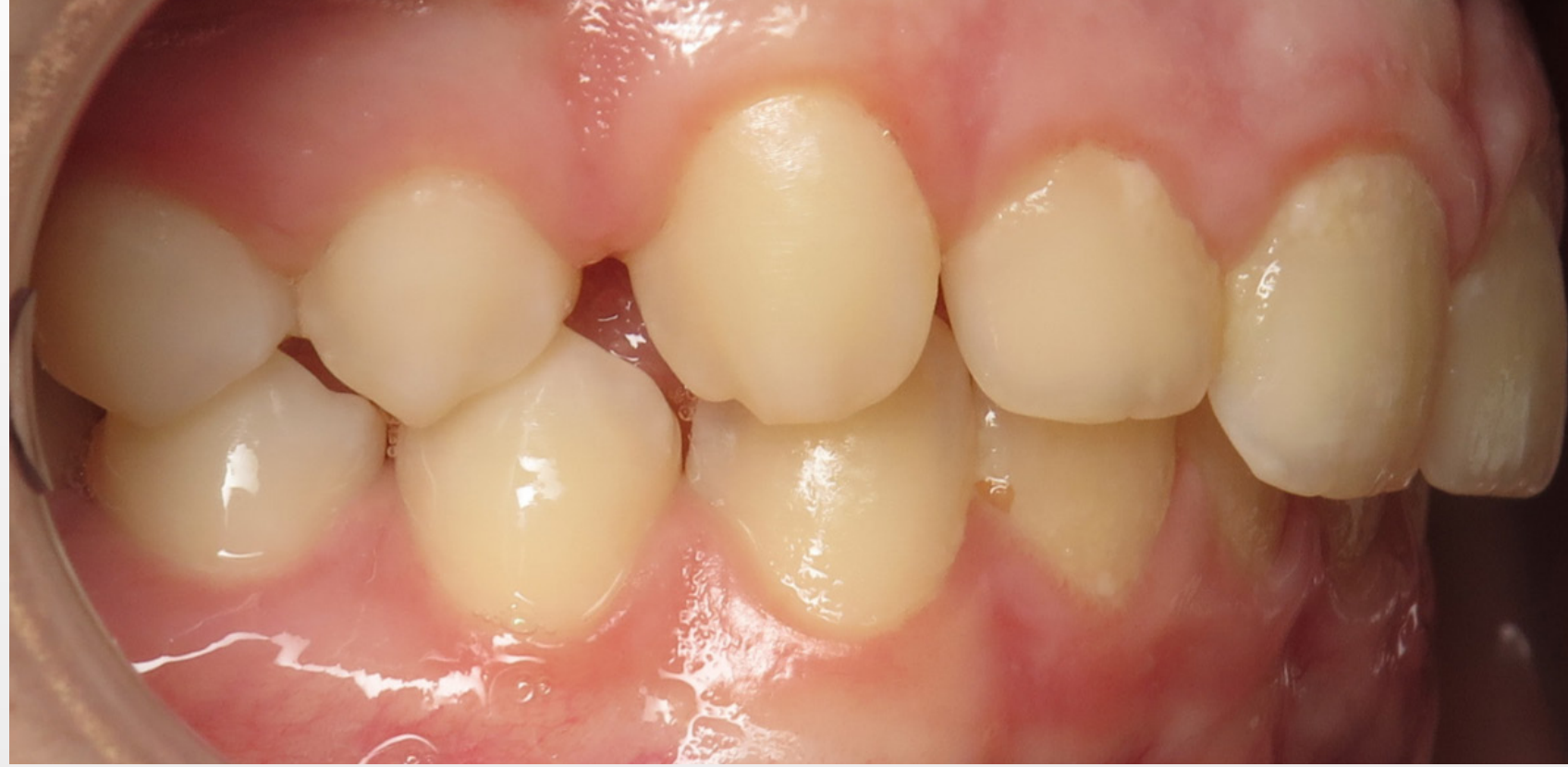**Occlusal –
mandibular**



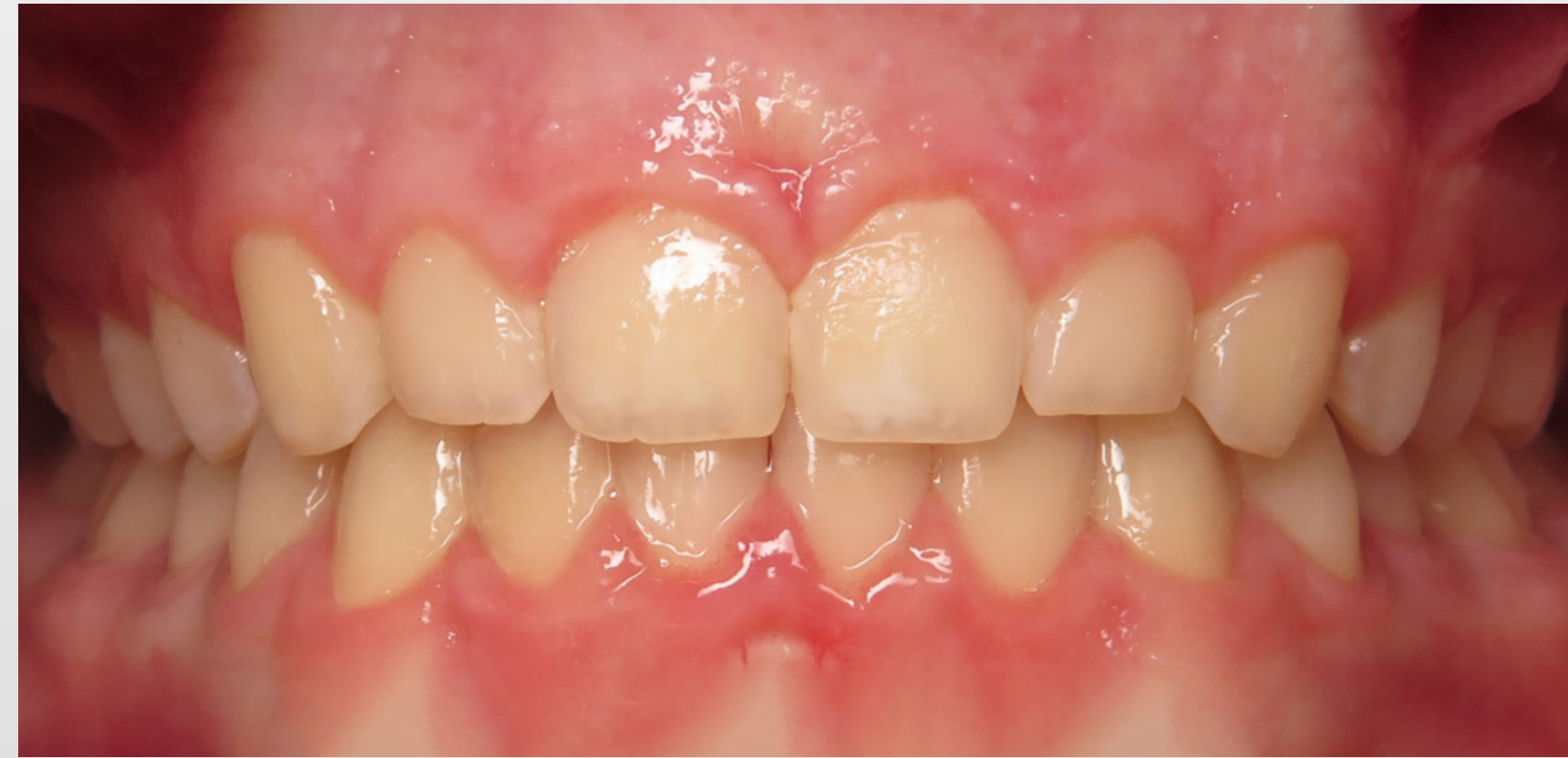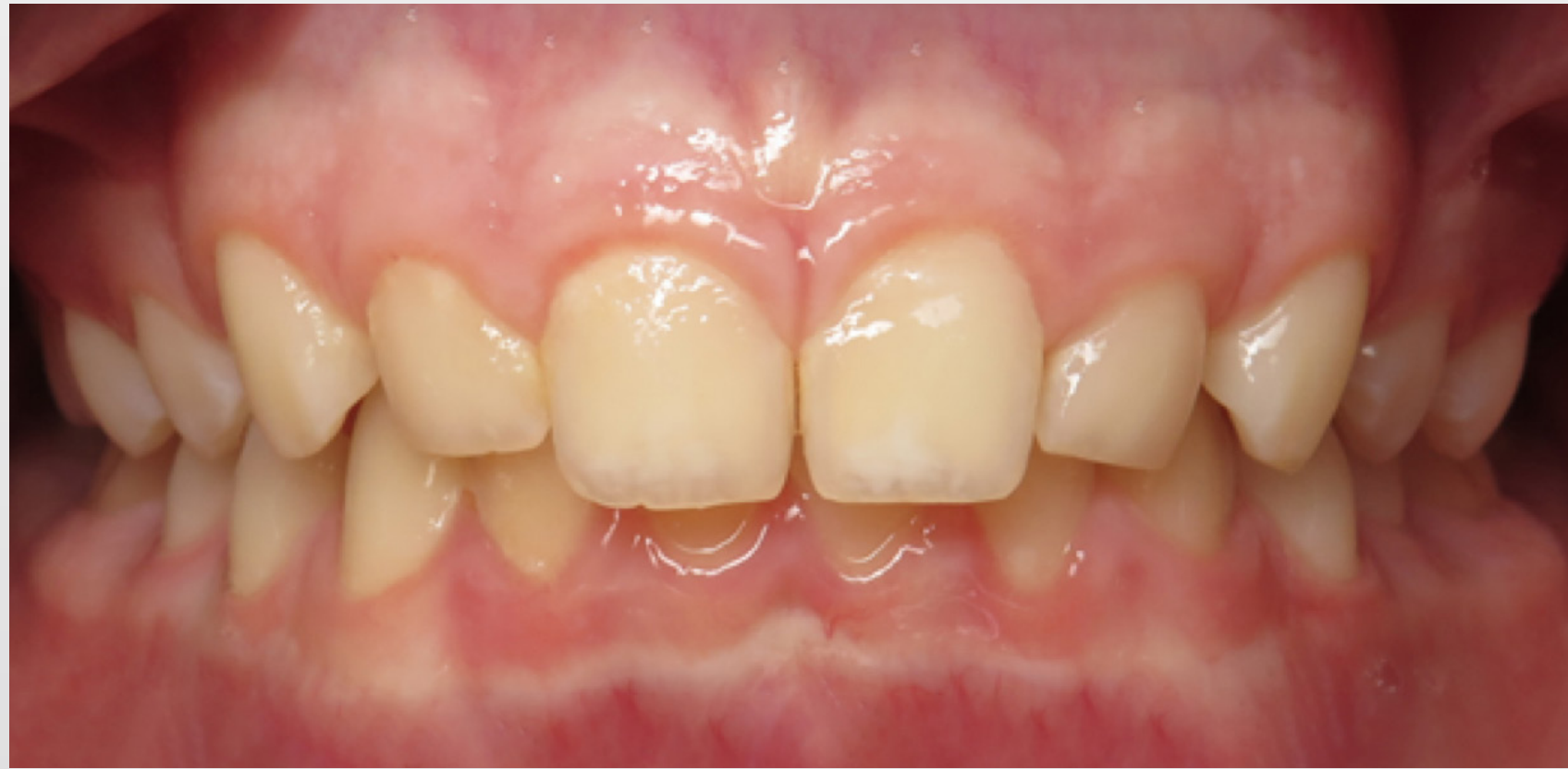Initial

Final

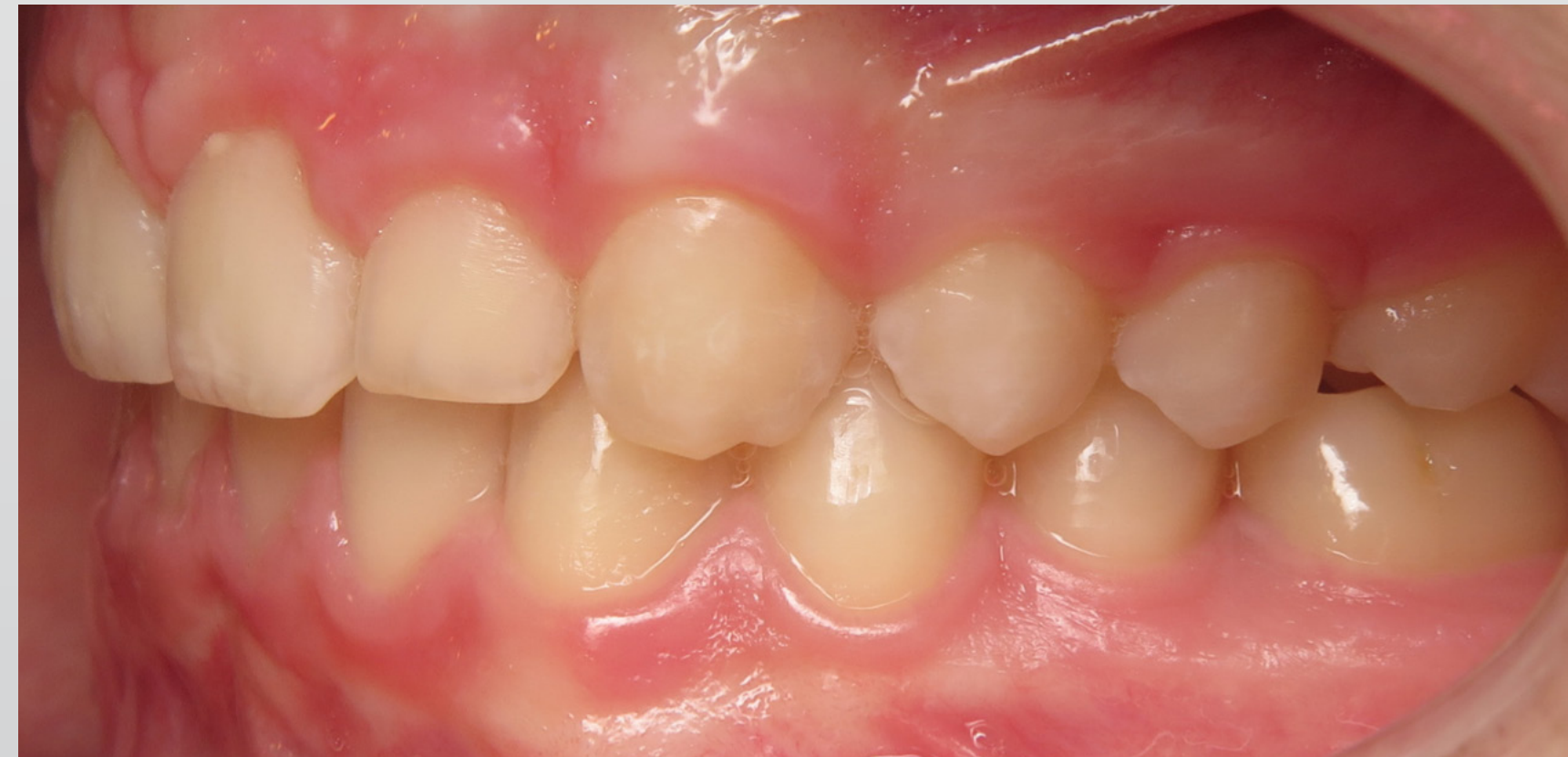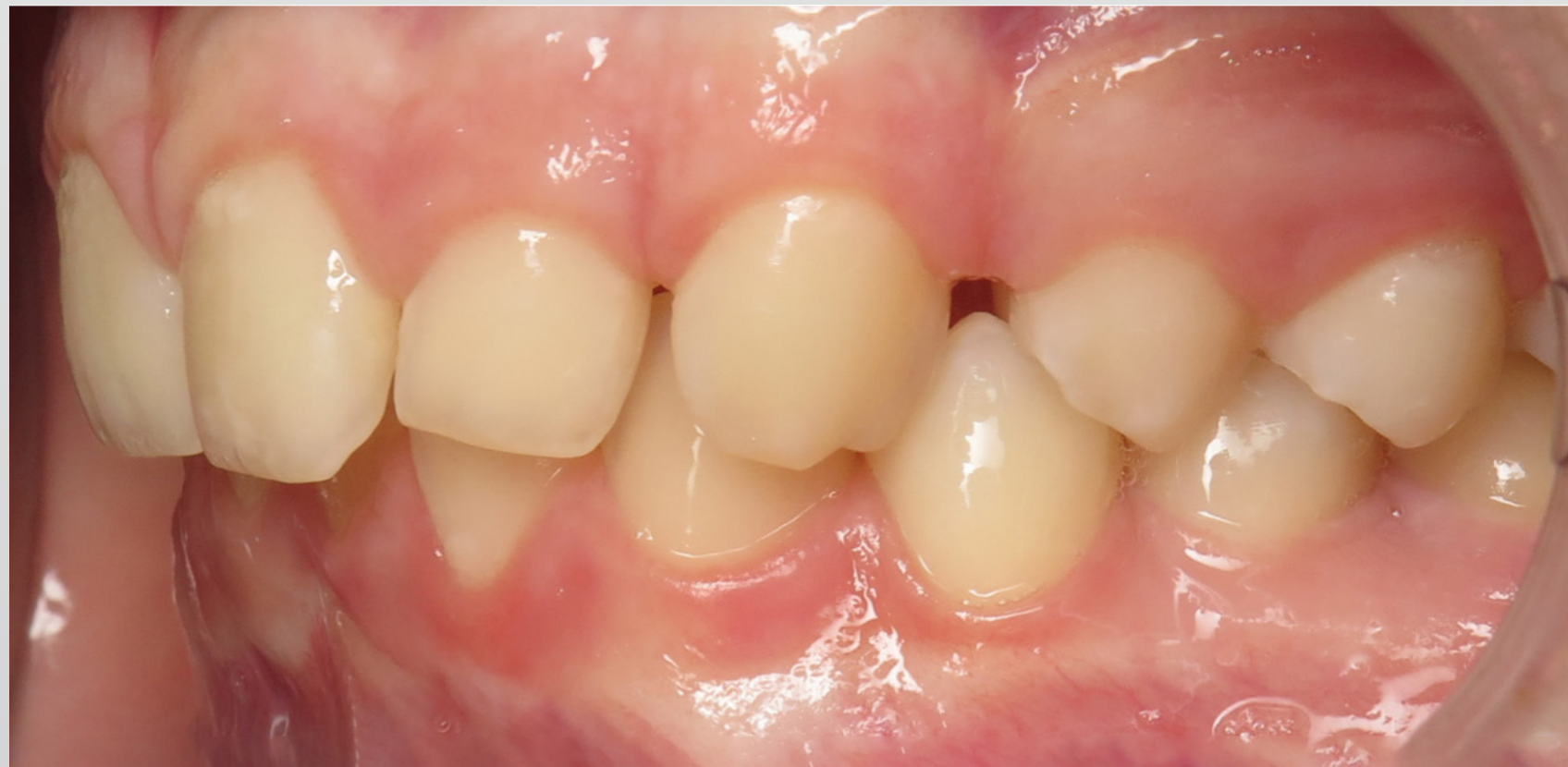**Retracted
buccal – right**



**Retracted
anterior biting**

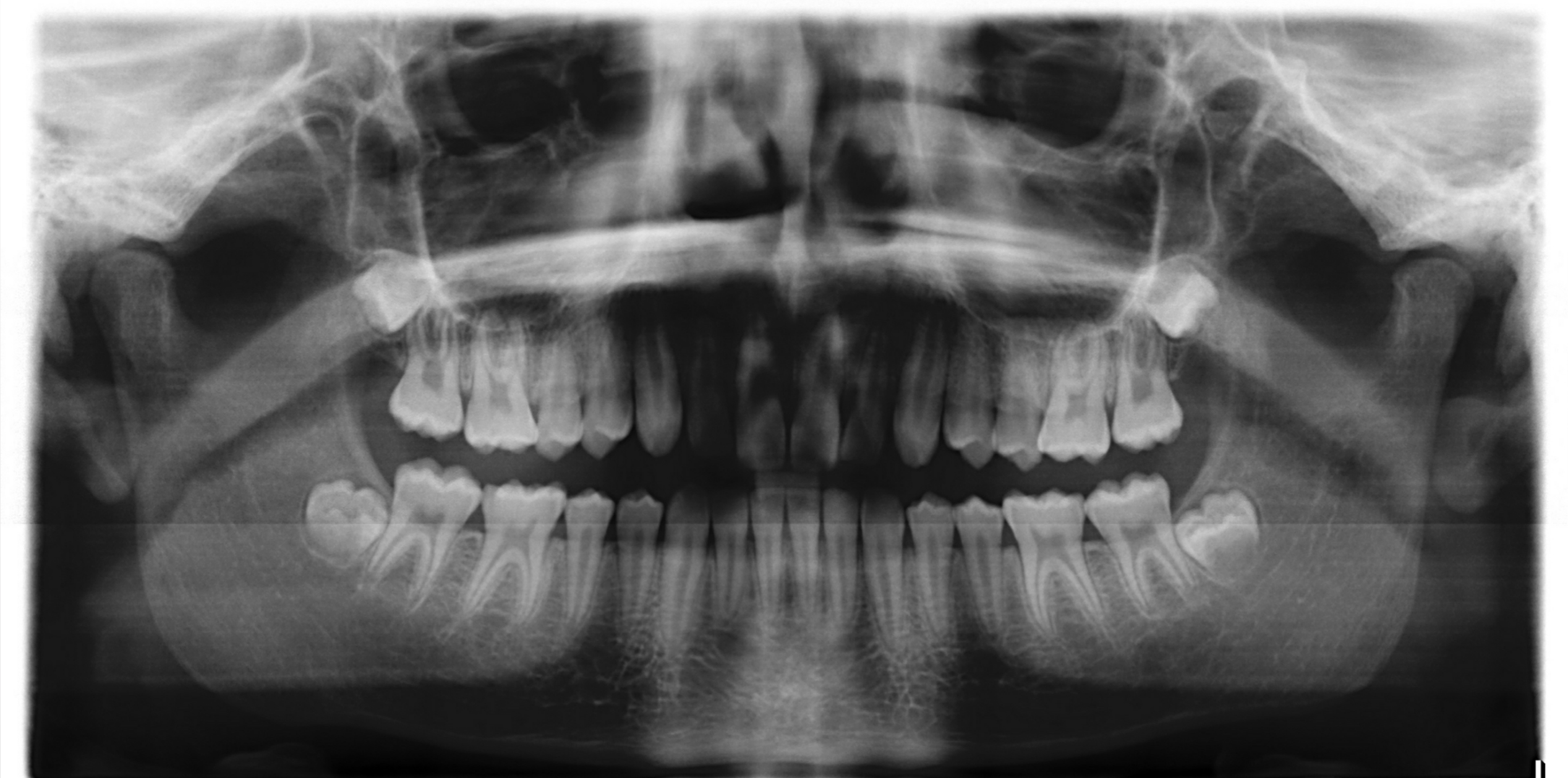

**Retracted
buccal – left**



Panoramic radiograph

Initial



Final



