

Treatment of a deep carious lesion of second lower premolar with 3M™ Filtek™ One Bulk Fill Restorative

Clinical dentistry and photography by: Dr. Filippo Dini, Viareggio, Italy

About the Case:

Male patient 47 years old.

Patient reported pain when drinking cold beverages.
The x-ray showed the extension of caries close to pulp.
Endodontic treatment was required.

Challenge:

The deep cervical margin and the preservation of tissue for the post-endo restoration posed challenges in this case. Excellent adaptation between the material and cavity walls is critical.

Step-by-Step:

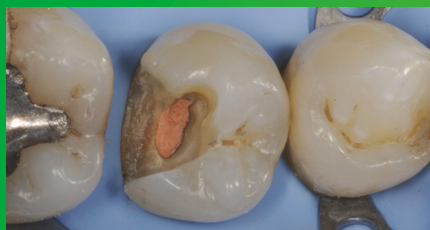

Fig. 1: Initial Situation: Second lower right premolar with a deep carious lesion restoration that required endodontic treatment. Image is showing the final preparation after removing the temporary filling.

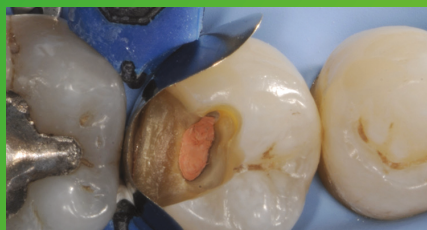


Fig. 2: Placement and adaptation of the sectional matrix.

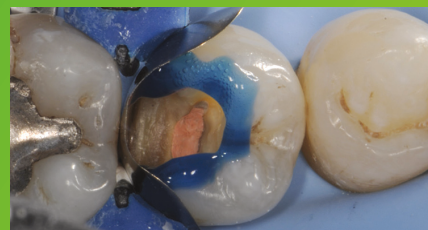

Fig. 3: Enamel is etched for 15 seconds using 3M™ Scotchbond™ Universal Etchant for a selective etch approach, followed by rinsing and drying.

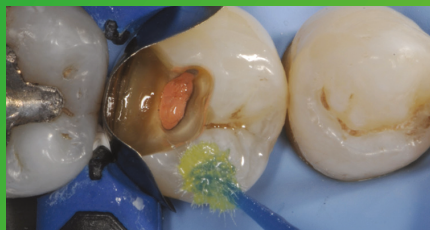

Fig. 4: 3M™ Scotchbond™ Universal Adhesive is applied and scrubbed into the surface for 20 seconds.

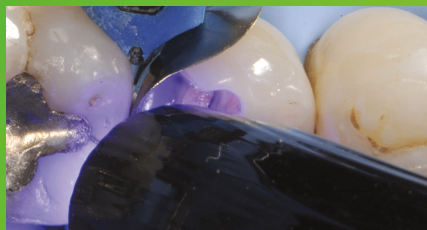

Fig. 5: After air drying for approximately 5 seconds, the adhesive is light cured for 10 seconds with 3M™ Elipar™ DeepCure-S LED Curing Light.

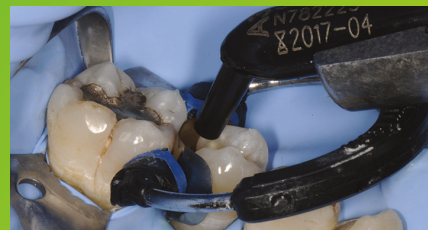

Fig. 6: 3M™ Filtek™ One Bulk Fill Restorative, in shade A3, is directly placed into the cavity in a single increment and then cured according to the Instructions for Use.

Treatment of a deep carious lesion of second lower premolar with 3M™ Filtek™ One Bulk Fill Restorative (continued)

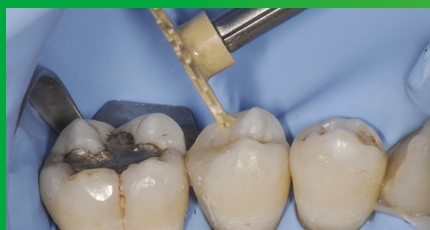

Fig. 7: Following finishing, to achieve the final polish of the restoration, the 3M™ Sof-Lex™ Pre-Polishing Spiral is used, as a first step, on a moist surface.

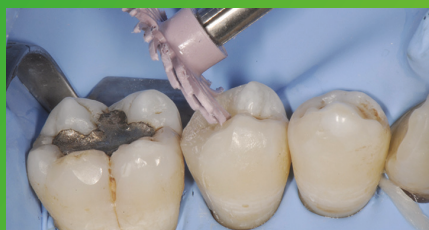

Fig. 8: A final high-gloss polish is created using the 3M™ Sof-Lex™ Diamond Polishing Spiral on a moist surface.

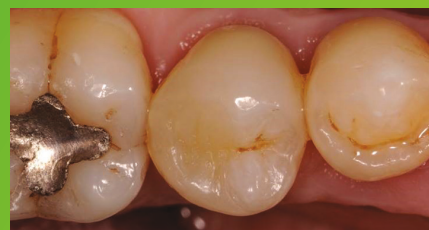

Fig. 9: Final restoration is very natural-looking and aesthetic.

The 3M Difference:

In deep and tight cavities, incremental layering can be a timely challenge and lead to poor marginal adaptation. With its easy handling and excellent adaptation, 3M™ Filtek™ One Bulk Fill Restorative enables one-step placement up to 5 mm, without compromising the aesthetics of posterior restorations.

Refer to Instructions for Use (IFU) for complete product information.



3M Oral Care

3M Indonesia

Perkantoran Hijau Arkadia, Tower F, 8th floor

Jl TB Simatupang | Jakarta Selatan 12520 Indonesia

Office : +621 2997 4000

Phone : +62 813 1554 0844

3M, Elipar, Filtek, Scotchbond and Sof-Lex are trademarks of 3M Company.
All other trademarks are owned by other companies. Please recycle. © 3M 2017.
All rights reserved.