

# Orthodontic Perspectives Innova

**News, Information, and Clinical Case Studies**



**James Ingebrand**  
Vice President and  
General Manager  
3M Oral Care

What does success mean to you? At 3M Oral Care, we think that's a very important question. Of course, even more important than the question ... is your answer. Because understanding how we can help you succeed is paramount to everything we do, from the products we develop to the services we provide.

First and foremost, we know our products must deliver clinical success. As a combined orthodontic company, a health care company and a global technology company, we rightly spend a substantial amount of time and effort on technical innovations. New materials, new processes, and the ability to combine technology from across the company and around the world has led to some exciting new technologies – like our APC™ Flash-Free Adhesive bonding system, SmartClip™ and Clarity™ SL Self-Ligating Brackets and Forsus™ Class II Correctors. To be truly useful, these innovations must help doctors solve difficult cases and drive outstanding clinical success.

But while clinical success is important, we know that it is not enough. So the second dimension is professional success. The orthodontic market is more competitive than ever before. A great doctor can provide fabulous treatment, but ultimately, professional success won't follow unless treatment is done efficiently and with a growing number of patients. A thriving practice must be part of the success equation. That is why in addition to great clinical results, we work to ensure 3M products drive efficiency by saving time and effort. Additionally, 3M products like Clarity™ ADVANCED Ceramic Brackets and the Incognito™ Appliance System help differentiate and grow practices. They do this by giving both doctors and patients what they want – a highly aesthetic alternative to metal brackets, and a preferred alternative to the cost, complexity and limitations of clear tray aligners.

The third area of focus is personal success. While this concept can mean different things to different people, to us it includes helping the entire practice feel good about what is done every day. We're fortunate to work in a field that can change lives in a profound manner. Restoring a smile and helping to maintain good oral health that will last a lifetime is challenging but deeply meaningful work. When we can help deliver clinical and professional excellence, we also help doctors and their staff feel proud and enthusiastic about what they do every day ... and that makes us pretty happy too.

3M Oral Care is committed to a continuing investment in the overall improvement of oral health worldwide. That means helping you to help patients have a healthy and beautiful smile, today and in the future. That's a good thing for everyone.

Please enjoy this issue of *Orthodontic Perspectives Innova*. We have informative articles for you from your colleagues around the world, who share their success using 3M products in treatment. And we invite you to contact us and let us know if we've got it right.

**3M** Science.  
Applied to Life.™

# Table of Contents

*Orthodontic Perspectives Innova* is published periodically by 3M to provide information to orthodontic practitioners about 3M orthodontic products and services. 3M welcomes article submissions or article ideas. Contact address: Editor, Orthodontic Perspectives Innova, 3M Oral Care, 3M Center, 275-2W-08, St. Paul, MN 55144-1000. To call for more information: In the United States and Puerto Rico, call (800) 852-1990 ext. 4399. In Canada call (800) 443-1661 and ask for extension 4399. Or, call (651) 736-7690 (direct).

Copyright © 3M 2016. All rights reserved. No part of this publication may be reproduced without the consent of 3M. Some of the doctors contributing to the *Orthodontic Perspectives Innova* publication may receive compensation from 3M.

3M, APC, Clarity, Forsus, Incognito, MBT, SmartClip, Unitek, and Victory Series are trademarks of 3M. 3M Health Care Academy is a service mark of 3M. Used under license in Canada. All other trademarks are property of their respective holders.

Visit our website at  
**3M.com/ortho**

## News and Information

<b>Introduction from Jim Ingebrand</b> .....	1
<b>The Forsus™ Appliance. Clinical efficiency in Class II correction.</b> <i>An interview with Dr. José Chaqués-Asensi</i> .....	3
<b>The Aesthetic Class II System from 3M</b> .....	7
<b>Clarity™ ADVANCED Ceramic Brackets with APC™ Flash-Free Adhesive (User Survey)</b> .....	8
<b>The future is flash-free.</b> <i>by Armineh Khachatoorian</i> .....	10
<b>Powered by science to work like magic.</b> .....	11
<b>SmartClip™ SL3 Self-Ligating Brackets:</b> <b>Improved clip enhances usability and adds more rotation control.</b> <i>by Darrell James and Ming-Lai Lai</i> .....	13
<b>Unitek™ Treatment Management Portal (TMP) serving the Incognito™ Appliance System.</b> <i>by Dr. Aurélie Guidoux</i> .....	16
<b>Upcoming Educational Opportunities</b> .....	19

## 3M™ Health Care Academy

### Clinical Cases

<b>Deep bite correction with ceramic brackets.</b> <i>by Dr. Patrice Pellerin</i> .....	21
<b>The Three E's: Efficiency, Effectiveness and Excellence</b> <i>by Dr. Anoop Sondhi</i> .....	26
<b>Enhancing Class II treatment efficiency with Clarity™ SL Self-Ligating Brackets and Forsus™ Class II Correctors.</b> <i>by Dr. Ricardo Moresca</i> .....	30
<b>An orthodontic system optimal for passive self-ligating brackets – “JETsystem.”</b> <i>by Dr. Shinichi Narita</i> .....	36

# The Forsus™ Appliance. Clinical efficiency in Class II correction.

*An interview with Dr. José Chaqués-Asensi.*



**Dr. José Chaqués-Asensi**

Dr. José Chaqués-Asensi received his MD degree in 1980 and a Specialist in Stomatology degree (DDS) in 1986 from the University of Seville. In 1990, he received a master's degree from Case Western Reserve University, Cleveland, Ohio and in 1995 received a PhD degree from the University of Seville. He has published numerous papers of major impact in national and international orthodontic journals, and has given oral presentations and lectures at the Congress of the Spanish

Orthodontic Society (SEDO), the European Orthodontic Society (EOS), the American Association of Orthodontists and in the World Orthodontic Congress of San Francisco (1995) and Chicago (2000). He has been a guest speaker for National Orthodontic Societies in Europe and the Middle East, and for Universities in Spain, Europe and the USA. He is an active member of the American Association of Orthodontists (AAO), a Diplomate member of the Spanish Orthodontic Society (SEDO), board-certified in the European Orthodontic Society, and an active member of the Angle Society of Europe (ASE). Since 1990, he has worked at his orthodontic practice in Seville, Spain.

## Foreword

**David Solid, Scientific Affairs Manager, 3M Oral Care**

*Class II correction is one of the most common, and one of the most difficult, modes of orthodontic treatment. There are multiple variables to consider when deciding on the method of treating a Class II malocclusion, and, unfortunately, the most common techniques involve some amount of patient compliance, which can be yet another variable.*

*Dr. José Chaqués-Asensi, MD, DDS, MSD, PhD, has several years of experience in correcting Class II malocclusions using the Forsus™ Class II Corrector. He teaches courses on the options and biomechanics of using this Class II corrector. Dr. Chaqués agreed to an interview on the unique properties of the Forsus Corrector and the reduction in variables when using it in treatment.*

### **Q: What are key considerations when deciding how to treat Class II?**

Dr. Chaqués: There are three key considerations when deciding how to treat Class II. The first is whether the patient is a growing patient or a non-growing (adult) patient. The second would be the amount of skeletal discrepancy, that is, the degree of mandibular retrognathism, since the mandible is the jaw mainly affected in Class II skeletal malocclusions. The third factor, directly connected with the two previously mentioned, is the need or indications for extractions.

### **Q: Given those considerations, what are the most common methods to perform orthopedic correction of the Class II?**

In a growing patient with a mild to moderate skeletal discrepancy, functional appliances have been used with the aim of “jumping the bite” and make the mandible grow forward. However, the available data does not support the notion that there is a significant difference in the global amount of mandibular growth in patients treated with functional appliances. Today, the most accepted concept is that the effects observed with the use of these appliances are due to dentoalveolar compensation.



In the same trend, the use of the headgear, with or without Class II elastics, has undergone a significant decline over the years. The main reasons are that we would be treating the wrong jaw (the maxillary base is normally positioned in most Class II skeletal cases) and because the effects are not significant from the skeletal point of view. It is important to remark that both approaches (functional appliances and headgear use) require a great amount of patient cooperation. In the last three decades, intermaxillary hinge devices, like the Herbst®, the Forsus™ Appliance and some others have come into place, mainly because they avoid patient cooperation to a great extent and because they are more efficient in achieving the Class II correction.

**Q: What about treatment of non-growing patients?**

In young adults, with a good periodontal status and a mild to moderate skeletal Class II, dentoalveolar compensation can be considered and could be applicable in certain cases. In that sense, both the Herbst and the Forsus Appliance have been used with successful results in non-extraction cases. However, extractions may be indicated for several reasons: the amount of crowding (mainly in the lower arch), proclination of the upper incisor and protrusiveness of the upper lip, severity of the overjet or convexity of the face. In these cases extractions should be considered a form of dentoalveolar compensation and must be limited to upper bicuspid.

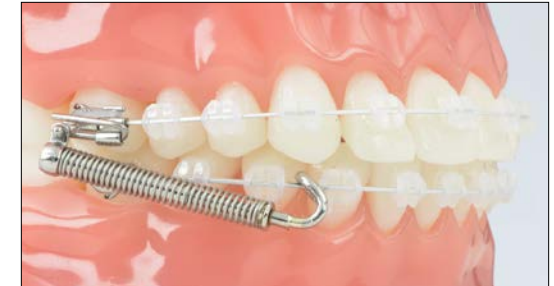The only exception to this rule is when the lower arch absolutely demand extractions and these cases, very often, are not good for orthodontic compensation. When the degree of skeletal discrepancy is severe, so the mandible is severely retrognathic, a combined approach of orthodontics and orthognathic surgery must be indicated. If the patient rejects the surgical treatment a “limited treatment” could be advised, consisting in leveling and aligning both arches and leaving the malocclusion as such. If neither the upper incisor nor the upper lip are protrusive and the nasiolabial angle is within normal limits, upper extractions, very commonly used in the past in order to correct the overjet, are to be absolutely avoided.

**Q: When do you recommend the use of a fixed appliance?**

The ideal case would be a growing or young adult patient with a mild to moderate Class II skeletal discrepancy and acceptable facial pattern, presenting with a Class II division 1 malocclusion, normal to slightly proclined upper incisor after the alignment of the upper arch and normal or retroclined lower incisor after the alignment of the lower arch. From the clinical management point of view, maximizing clinical efficiency, reducing treatment time and minimizing patient cooperation are major reinforcements of the indication of a fixed appliance.

**Q: How does the Forsus Appliance meet your requirements for a fixed appliance?**

The popularity of the Herbst® appliance in the last 25 years has brought about a new interest in the potential use and application of inter-maxillary hinge devices for the correction of the Class II malocclusion. The Forsus™ Fatigue Resistant Device belongs to the new generation of such appliances. The Forsus Appliance is an easy-to-use, yet dependable appliance that can be used effectively and efficiently in different clinical scenarios where the correction of the skeletal or dental components of the Class II malocclusion is needed. All the parts of the appliance are pre-made and, therefore, no lab work is required. The ideal size of the rod can be easily selected and the parts can be assembled together, adjusted and located in the mouth of the patient within a few minutes.



**Q: Can Forsus Correctors be used in skeletal cases?**

The initial purpose of the use of intermaxillary hinge devices of the Herbst type (as it happened before with Functional appliances) was to enhance and promote mandibular growth. However, the scientific evidence available today does not permit to support the concept that a significant skeletal modification can be achieved with the use of these appliances. So, the skeletal effects, albeit noticeable to some extent in some cases, are not clinically significant and do not justify its use.

Nevertheless, in mild to moderate Class II skeletal patients, the Forsus Appliance is very effective in introducing dentoalveolar compensations that would carry out a very successful correction of the Class II malocclusion. Furthermore, I am aware of the suggestion that the Forsus Appliance, as it has been proposed for the Herbst, could induce a remodeling of the glenoid fossa, allowing a forward position of the condyle in the joint and, therefore, a sagittal forward repositioning of the whole mandible. However, sufficient scientific evidence to support this concept is not available at this moment. In fact, the time of wearing of the appliance rarely exceeds six months and, from a biological point of view, this time span does not seem enough to generate a craniofacial response of this nature. Finally, in severe skeletal cases other treatment alternatives should be considered, like a surgical procedure in adult patients or a “limited treatment” both in growing and non-growing patients.

**Q: What types of dental cases can be treated with Forsus Appliances?**

The ideal indication for the use of the Forsus Appliance has already been described above. However, the clinical possibilities for the use of the appliance is much wider. Unilateral Class II division 1 malocclusions can be properly handled with a differential force placed on each one of the two rods. Even dentoalveolar compensation of asymmetrical malocclusions with a skeletal component can be achieved with the use of the Forsus Appliance. When the inclination of the lower incisor allows a prolonged use of the Forsus Appliance (6 to 9 months), severe overjets of more than 5 mm can be fully corrected with this appliance. Vertical control can also be achieved by applying the force distal to the lower first premolar instead of the cuspid. In Class II division 2 malocclusions, the Forsus Appliance can be used after leveling and aligning the two arches.

**Q: The Forsus Appliance has been compared with the intraoral molars distalizers, like the Pendulum appliance. What is your opinion?**

You are right. But this is a very common misunderstanding, because the Pendulum (like most of the intraoral distalizers) and the Forsus Appliance are totally different types of appliances. They both share some features, like they both can be used in non-extraction treatment and do not require patient cooperation. But the differences are very significant. First, the main indication for the use of the Pendulum is the Class II division 2 malocclusion, in a Class I or minimal Class II skeletal case with a cusp-to-cusp (no full step) Class II molar relationship. If the Class II molar relationship is complete (7 mm), the Class II skeletal discrepancy involves a retrognathic mandible or the upper incisor is flared, the Pendulum is contraindicated because in the majority of these cases extractions will be necessary in the end unless skeletal anchorage (TADS) is used to prevent further mesial movement of the upper front teeth.

It must be explained that one of the initial indications of the Forsus Appliance was to distalize the upper molars and, in fact, it can be used for that purpose if the upper molars are not connected to the rest of the upper teeth. However, nowadays, the Forsus device is used in the large majority of the cases with the upper arch totally consolidated and the molar position reinforced with a trans-palatal bar.

The other main difference is that the Pendulum is located, works and performs the Class II correction in the upper arch and ... at the expense of the upper arch. That means that the lower arch is unaffected, so there are no side effects in the lower dentition. Conversely, the Forsus Appliance connects the upper and lower arches and has an effect in both of them. However, the effect is far more noticeable in the lower dentition that exhibits mesial migration, as perceived by the proclination of the lower incisor, whereas the upper dentition remains relatively unchanged.

Nevertheless, in recent years I have been using a combined protocol for the treatment of severe Class II division 2 malocclusions (7 mm or more of Class II molar), where the patient shows a Class I or mild Class II skeletal relationship and the lower incisor is retroclined. In such patients, the first part of the treatment is done by molar distalization with the Pendulum, which allows a partial (but not total) correction of the Class II malocclusion. The final part of the Class II correction is done through the use of the Forsus Appliance to achieve a perfect Class I. This combined approach carries out great facial changes in these patients. So, the two appliances have different indications and mechanics but they are compatible in some selected cases.

**Q: What is the process to achieve the patient's acceptance of the appliance?**

Tolerance to the appliance is normally good and the patient must be informed and instructed about the specific features of the appliance, the advantages of its use versus other treatment alternatives and how to overcome the possible initial discomfort. If the patient rejects the use of the appliance from the beginning or does not tolerate the appliance, the possible drawbacks or limitations in the treatment outcome must be explained and discussed with the patient or his/her family.

**Q: After removal of the Forsus Appliance, are there any recommended steps to ensure good retention of the correction?**

One of the main, and logical, concerns with the use of this appliance is stability. During treatment the check-ups of the patient must include the check-up of the bite. After two or three months of appliance wearing, the spring must be removed from the headgear tube and the bite must be checked, looking for a double or "Sunday" bite. While the occlusion is cusp-to-cusp the bite is not stable in many cases and the position of the lower arch may relapse easily. However, after four to six months of appliance wearing the occlusion is normally in Class I without the patient posturing the mandible forward.

At this point we must also monitor the changes in the inclination of the lower incisor. When in doubt, a follow-up cephalogram can be taken in order to assess the changes. An increase in the axial inclination of the lower incisor as compared to the initial situation will certify that the dentoalveolar compensation has taken place. At this point, the position of the mandible is stable in the large majority of the cases and the correction of the malocclusion can be considered completed.

Mandibular positioners or occlusal positioners have been recommended in order to ensure or stabilize the position of the mandible. In my protocol, and according to my experience, such devices are not necessary on a routine basis and are not part of my armamentarium. After removal of the Forsus Appliance, a brief period of vertical or short Class II elastics, as needed, may be necessary to settle the occlusion before debanding. My retention protocols are the same for these patients as for any other patient of my office.

**Q: What has been your patient's response to the use of Forsus Appliances in their treatment?**

Proper indication is a key factor to achieve a successful treatment response with this appliance, as it is with any other appliance of any kind. Class II dental correction can be performed with a high level of accuracy and in a very efficient way, reducing treatment time and avoiding to rely on patient cooperation.

As stated before, there is a wide range of clinical situations where the Forsus Appliance can be used. In mild to moderate skeletal Class II malocclusions the Forsus Appliance is capable of producing a controlled dentoalveolar compensation that allows to achieve a Class I occlusal relationship with positive facial changes. A favorable skeletal response in mandibular growth and/or mandibular position has been observed in some cases, although this type of treatment outcome is not to be expected and can't be fully explained from the biological point of view. The correction obtained with the Forsus Appliance has been proven to be very stable over time and the retention protocol of these patients do not require any specific variation from a common case.

**Q: Any final considerations?**

Well, the Forsus Appliance is a wonderful tool that can become a great help for the orthodontist in a variety of clinical scenarios. Understanding of the parameters that define a proper indication for its use is fundamental to obtain satisfactory results. Good clinical management of the adequate patient can be accomplished within a limited amount of time, since the learning curve is not long. Once the clinician learns when to use it and how to use it, a wide range of possibilities are open for the orthodontist. I would make a sincere and strong recommendation to any orthodontist to get familiar with the appliance, since the Forsus Appliance has changed my approach of treating Class II malocclusions. And I am sure it can do the same for others.

**Thank you very much, Dr. Chaqués.**

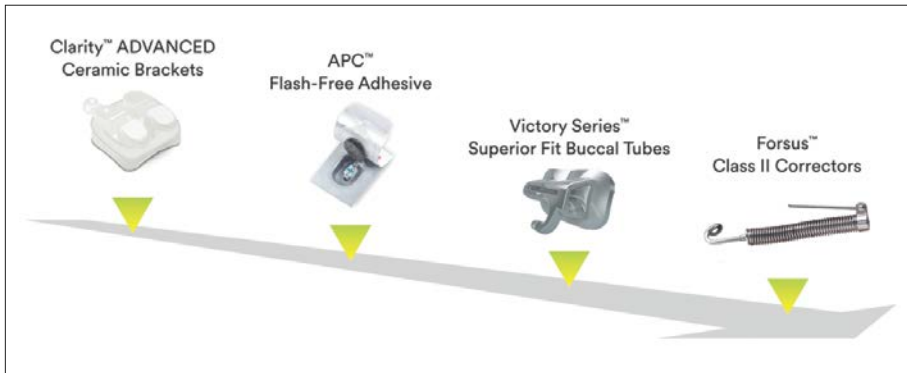
It has been a pleasure.

*Editor: Dr. Chaqués was interviewed by David Solid, Scientific Affairs Manager with 3M Oral Care. July 2016.*

# The Aesthetic Class II System from 3M – for a beautiful smile, throughout treatment.

Your patients expect you to enable their most beautiful smile, even while they're undergoing orthodontic treatment. While aesthetics might begin with ceramic brackets with clear or colored ligatures – it doesn't end there. Class II correction is an everyday part of your practice, and it's a process that can be aesthetic too. 3M has put years of science to work to develop a system of proven products that allows your patients to be comfortable, happy and confident while you're correcting their Class II malocclusion.

## The Aesthetic Class II System from 3M.



Patient-pleasing aesthetics begin with the leading ceramic system. **Clarity™ ADVANCED Ceramic Brackets** provide exceptional aesthetics and strength in a small size, with smooth surface uppers and lowers that resist staining and discoloration throughout treatment. These ceramic brackets are proven – offering predictable debonding and enhanced patient comfort. Clarity ADVANCED brackets are the first step to truly aesthetic Class II correction.

Adding efficiency and time savings, **APC™ Flash-Free Adhesive** provides an improved patient bonding experience. The system eliminates the flash removal step completely, reducing bonding time, and there is no compromise in bond strength. Early users have reported less than a 2 percent bond failure rate. The adhesive on

**CLARITY™** | **ADVANCED**  
advanced ceramic brackets

**APC™ Flash-Free**  
Adhesive Coated Appliance System

**Victory Series™**  
Superior Fit Buccal Tubes

**FORSUS™**  
Class II Correctors

the tooth after bonding has been shown to protect enamel under the adhesive, further contributing to a beautiful smile after treatment.

Designed with extensive user input, **Victory Series™ Superior Fit Buccal Tubes** eliminate the need to band molars. They feature a complex-contour curvature base for superior fit, are easy to place and handle, and offer a sleek, low profile and tapered body for patient comfort. Availability with APC Flash-Free Adhesive coating means increased efficiency at placement, and superior strength.

Treatment for Class II malocclusion has traditionally been limited to products that are easy to install, but require patient compliance, or products that are fixed but difficult to work with. Many appliances are worn outside the mouth. With **Forsus™ Class II Correctors**, treatment becomes both hidden and fixed – but without the hassle. Forsus correctors can be added at any time, without molar bands. Cheek bulges are eliminated, and the device remains in place 24/7 without the need for patient compliance. Today, Forsus correctors been used in the treatment of more than 1 million patients.



Actual patient in treatment wearing Clarity™ ADVANCED Brackets and Forsus™ Class II Correctors

## The result? Simply beautiful.

For you and your practice, this intelligent system works around the clock to speed progress and help ensure optimal, aesthetic results. External hardware is eliminated, with no headgear, face bow or elastics that can be embarrassing for patients of all ages, and compliance issues are no longer a threat to effective treatment. Pair this with brilliant, patient-pleasing aesthetic brackets and more efficient application means you can spend more time with patients, and more time building a successful practice.

For more information, visit [3M.com/Aesthetics](http://3M.com/Aesthetics), or call your local 3M Oral Care representative.



# Clarity™ ADVANCED Ceramic Brackets with APC™ Flash-Free Adhesive

*More than 91% of surveyed users would recommend this bracket to their colleagues.*

**CLARITY™ | ADVANCED**  
advanced ceramic brackets

**APC™ Flash-Free**  
Adhesive Coated Appliance System

Today, more than ever, patients are seeking treatment options that are aesthetic, with fast, high quality results. Clinicians want to provide this kind of treatment without sacrificing efficiency or accuracy. 3M has long been committed to bringing innovation to orthodontics that will help address the needs of both patients and practitioners.

Aesthetic Clarity™ ADVANCED Ceramic Brackets, featuring APC™ Flash-Free Adhesive, is the most recent example of this innovation. Together, these products deliver a system that provides aesthetic treatment, designed for performance, patient comfort, and treatment efficiency. This article summarizes recent survey findings from 68 doctors across Western Europe who have treated with these brackets.

## Aesthetics

Of those surveyed, over 96% of doctors expressed patient satisfaction with the aesthetics of the bracket at bonding and after the first appointment (Charts 1, 2). 88% of doctors indicated they were satisfied or very satisfied with patient satisfaction in comfort of the brackets after bonding (Chart 3). In aesthetics and comfort, 0% indicated dissatisfaction.

## Efficiency

More than 78% of respondents indicated that bracket positioning was easy or very easy (Chart 4). With the step of flash clean-up eliminated, 92% responded that they were satisfied or very satisfied with APC Flash-Free Adhesive (Chart 5), and more than two thirds indicated that it was better than their current bracket adhesive (Chart 6). 98.5% felt that they had about the same or better bond failure rate with APC Flash-Free Adhesive, with more than half indicating a bond failure rate improvement (Chart 8).

## Quality

Regarding the ability of the bracket to adapt to the contours of the tooth surface, 83% were satisfied or very satisfied (Chart 7). Over 90% expressed satisfaction about the rotational control of the Clarity ADVANCED bracket system.

How was your patient satisfaction with the aesthetic of Clarity™ ADVANCED Ceramic Brackets after bonding?

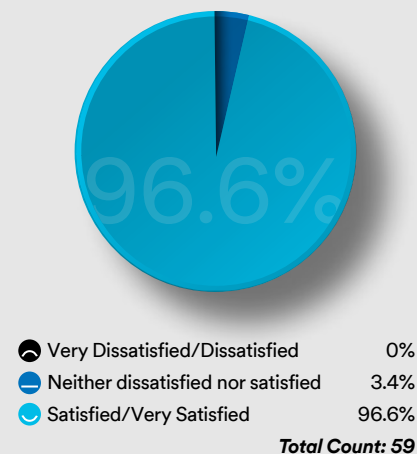


Chart 1

How was your patient satisfaction with the aesthetic of Clarity™ ADVANCED Ceramic Brackets after first appointment?

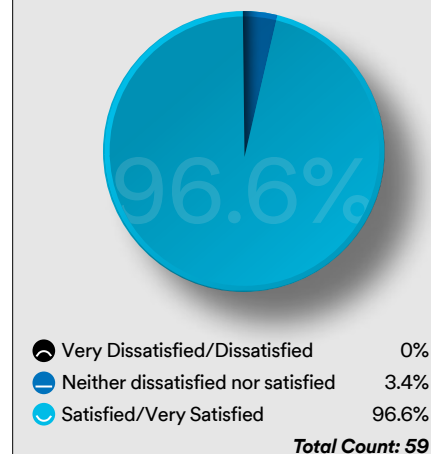
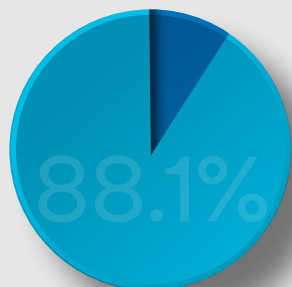


Chart 2

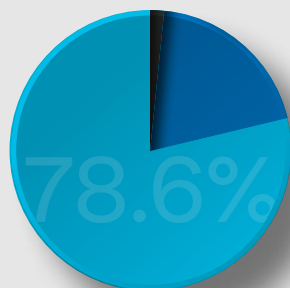
How was your patient satisfaction with the comfort of Clarity™ ADVANCED Ceramic Brackets after bonding?



Total Count: 59

Chart 3

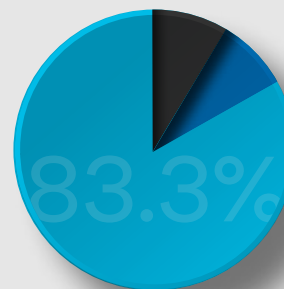
How easy was the bracket positioning with APC™ Flash-Free Adhesive?



Total Count: 61

Chart 4

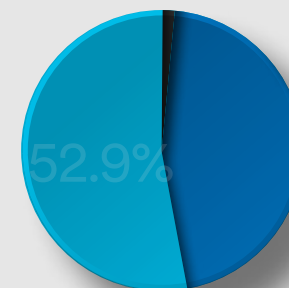
How satisfied were you with the adaptation to the tooth surface combining Clarity™ ADVANCED Ceramic Brackets and APC™ Flash-Free Adhesive?



Total Count: 60

Chart 7

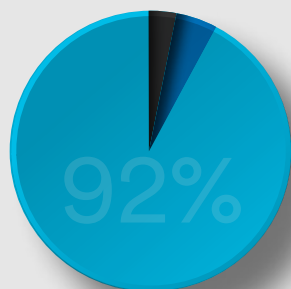
Did you experience more/less bond failures compared to the system you used before?



Total Count: 68

Chart 8

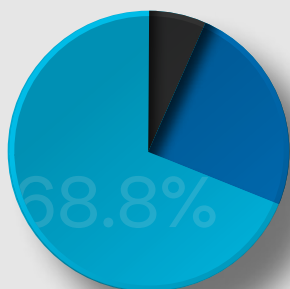
How satisfied are you with the APC™ Flash-Free Adhesive?



Total Count: 62

Chart 5

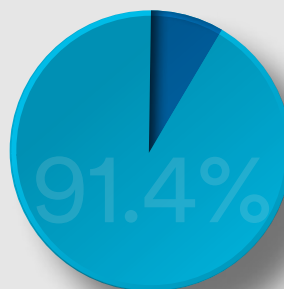
...and compared to your current adhesive?



Total Count: 61

Chart 6

Would you recommend this product to your colleagues?



Total Count: 58

Chart 9

## Summary

Overall, over 91% would recommend Clarity ADVANCED brackets with APC Flash-Free Adhesive to their colleagues (Chart 9). And in a final survey question, 88% of those surveyed consider APC Flash-Free Adhesive to be the most innovative bonding solution available in the market.

Clarity ADVANCED brackets with APC Flash-Free Adhesive continues 3M's tradition of partnering with orthodontic practices to develop new solutions for patient and doctor, and continuing to collect feedback once in practice.

# The future is flash-free.

Complete flash-free bonding now possible, with expanded availability of APC™ Flash-Free Adhesive coated appliances.

**APC™ Flash-Free**  
Adhesive Coated Appliance System



**Armineh Khachatoorian,**  
**3M Oral Care Global Marketer**

Armineh Khachatoorian received her B.S. in Chemistry from the University of Southern California. She joined 3M in 1997 as a Sr. Technical Service Engineer in R&D. In 2002 she became a Marketing Product Manager, and is now brand manager responsible for adhesives, ligated appliances, tubes and bands, and APC™ Adhesive Systems.

Over the past three years, orthodontists around the world have discovered the benefits of the APC™ Flash-Free Adhesive Coated Appliance System from 3M Oral Care. Key advantages of the system include the **elimination of the flash removal** step in bonding and **reduction of bonding time** by up to 40 percent per bracket, enabling increased efficiency at appointments and a more pleasant patient experience.

However, for some orthodontists, **reduction of bond failures** is the most advantageous benefit, increasing their practice efficiency. APC Flash-Free adhesive coated brackets have an average bond failure rate of less than 2 percent. In addition, the APC Flash-Free Adhesive meniscus that covers the tooth enamel protects the tooth under it from acid erosion and contributes to **better patient tooth hygiene**. A more **predictable and easier debonding** experience for both doctor and patient adds to the overall efficiency at the very last appointment of the orthodontic treatment.

In August 2016, the APC Flash-Free adhesive offering was extended to include the **Victory Series™ Low Profile Brackets**. Victory Series Low Profile Brackets are the most popular 3M ligated metal brackets, and now, with the addition of the APC Flash-Free Adhesive, they can also offer the most efficient bonding.

The significance of this launch is that now, any type of orthodontic bonding can be accomplished using the most advanced bonding technology. Regardless of whether your preference is ligated or self-ligating, metal or ceramic, and even bonded molars, you can bond a complete 7×7 U/L system using the APC Flash-Free adhesive coated appliances. The following appliances are available globally\* with the APC Flash-Free Adhesive:



**CLARITY™ | ADVANCED**  
advanced ceramic brackets



**Victory Series™**  
Low Profile Brackets



**SMARTCLIP™ SL3**  
SELF-LIGATING APPLIANCE SYSTEM



**CLARITY™ | SL**  
SELF-LIGATING APPLIANCE SYSTEM



**Victory Series™**  
Superior Fit Buccal Tubes

If you have not experienced this most technologically advanced bonding system, please contact your local 3M representative and discuss the area of bonding that can most benefit from the APC Flash-Free Adhesive system, then try it for yourself to see how it can improve your practice.

\*Contact your local 3M representative for availability in your country.

3M, APC, Clarity, SmartClip, and Victory Series are trademarks of 3M.  
Used under license in Canada. © 3M 2016. All rights reserved.



# Powered by science to work like magic.

*How combining 3M technologies in a novel way sparked a game-changing breakthrough for orthodontic brackets.*

**APC™ Flash-Free**  
Adhesive Coated Appliance System

At 3M, science is at the heart of everything we do. Our 46 technology platforms work together to solve your biggest challenges, and our researchers are always in pursuit of new and surprising connections. APC™ Flash-Free Adhesive, which offers fewer steps, lower bracket bond failures and quicker clean-up, is an example of these connections at work.

Bringing you this time and labor saving advance took equal parts cutting-edge science and good old fashioned human intuition. Want to know more? Here's a look at how it all came together.

## A flash of inspiration

In 2005, 3M scientist Dr. David Cinader was facing a dilemma. Precoated brackets, introduced by 3M in the 1990s, had already made a big difference for orthodontists looking to reduce the number of steps it takes to place and bond brackets. However, customers were telling Cinader they could use an even better solution.

“Our customers were very happy with the time and effort they saved by using precoated brackets, but we still had room for improvement,” Cinader said. “I observed customers struggling with removing adhesive flash and started thinking about how 3M could help.”

Flash clean-up is a known annoyance because it is time consuming and lengthens the overall appointment time, but there are other challenges as well. Cleaning away flash can lead to accidental movement of the bracket, requiring additional repositioning. And uncleared flash can promote plaque accumulation.

Cinader felt that if it were possible to stop flash from occurring in the first place, orthodontists could significantly improve the efficiency of their procedures.

## Collaborative breakthrough

Developing a solution with the right performance meant thinking about orthodontic adhesives in an entirely new way. For as long as they had been made, these adhesives had always been based on the same types of materials found in dental restoratives. But why not try a more novel approach?

Cinader's breakthrough came when he overheard colleagues discussing the properties of foam packaging that was going to be used on another 3M orthodontic product.

“Foam is compressible, and I had been thinking that what we needed was a compressible adhesive,” recalled Cinader. “The idea was to control the flow of adhesive and stop it from flashing.”

After a few experiments it became clear that the foam wouldn't perform as needed, but Cinader kept working to find a solution. Eventually, more collaboration with fellow 3M scientists led him to the idea of using nonwoven material as the adhesive carrier on his reinvented precoated bracket.

## A key technology platform

Nonwoven materials are fabrics made from fibers that aren't joined by weaving or knitting. Instead, they are created by bonding fibers mechanically, thermally or chemically. Like adhesives, nonwovens are among 3M's key technology platforms. They are used in diverse products including Filtrete™ Home Filtration Products, Scotch-Brite™ Scrub Sponges and Thinsulate™ Thermal Insulation.



A tiny nonwoven mat soaked in liquid adhesive resin is the secret behind the flash-free performance of 3M's APC™ Flash-Free Adhesive coated brackets.



Cinader soaked a small amount of nonwoven material in methacrylate-based adhesive resin and attached it to a bracket.

“When placed on the tooth and pressed, the nonwoven mat exudes the resin and creates a smooth meniscus around the edge of the bracket that makes uniform and consistent contact with the surface of the tooth,” said Cinader. Using nanotechnology, another 3M technology platform, Cinader and his colleagues developed a special filler material for the adhesive resin. “This makes the adhesive drift less and appear clearer due to the low amount of filler used, eliminating the need to clean up flash.”

## Superior bonding performance

Available in orthodontics as the APC™ Flash-Free Adhesive Coated Appliance System, this system can reduce bonding time by 40% per bracket. It also provides reliable bond strength and more predictable performance with an average bracket bond failure rate of less than 2%. What’s more, the unique smooth meniscus formed beneath the nonwoven mat seals the tooth surface around the bracket, protecting the enamel from acid erosion caused by microleakage for improved oral hygiene.

Removing the brackets from the patient’s teeth is also easier. The lower amount of filler used means orthodontists can use a low-speed handpiece to remove remnants and maximize patient comfort.

## Innovation continues

Not only do the adhesive coated brackets themselves represent an advance in technology, but they are packaged in an innovative way that enhances their time-saving potential.

Because of the less viscous nature of the adhesive resin, the precoated brackets need to be carefully packaged to avoid resin leakage and damage to the nonwoven mat. To address this challenge, the 3M team designed a funnel-like “blister” package that protects the brackets during shipment while ensuring they can be quickly and easily removed during procedures. They are also presented in the correct position and orientation to go directly into the mouth.



## Choice and convenience

APC Flash-Free Adhesive is now available on Victory Series™ Low Profile Brackets from 3M, which means the entire mouth can be bonded with this innovative adhesive with your choice of 3M premium ceramic or metal ligated or self-ligated brackets and Victory Series™ Superior Fit Buccal Tubes.

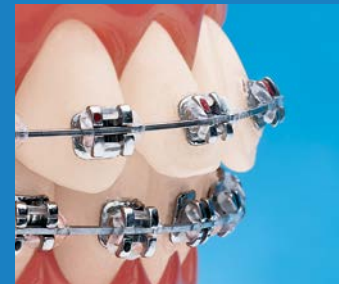The story of how Dr. David Cinader took his idea for flash-free adhesive from idea to finished product is a perfect example of both 3M’s culture of innovation and commitment to making sure the customer’s voice is heard.

For more information on how you can make your practice 100% flash-free, contact your local 3M representative.



Dr. David K. Cinader is a Senior Product Development Specialist in the Oral Care Solutions Division at 3M Company. He holds a B.S. Degree in Chemical Engineering from Michigan Tech University and a Ph.D.

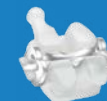in Chemical Engineering from Northwestern University. He is a named inventor on over 50 patent applications on dental and orthodontic adhesives and bonding appliances. David joined 3M Unitek Research and Development in September 1999 and has been involved in orthodontic adhesive development including Transbond™ Plus Self-Etching Primer and APC™ II, APC™ PLUS, Transbond™ IDB, and Transbond™ Supreme Low Viscosity Adhesives.



**APC™ Flash-Free Adhesive is now available for use with the following products:**



**Clarity™ ADVANCED Ceramic Brackets**



**Clarity™ SL Self-Ligating Brackets**



**SmartClip™ SL3 Self-Ligating Brackets**



**NOW! Victory Series™ Low Profile Brackets**



**Victory Series™ Superior Fit Buccal Tubes**

# SmartClip™ SL3 Self-Ligating Brackets: Improved clip enhances usability and adds more rotation control.

**SMARTCLIP™ SL3**  
SELF-LIGATING APPLIANCE SYSTEM



**Darrell James, 3M Oral Care**

Darrell S. James is Senior Technical Service Engineer for 3M Oral Care. He received his Bachelor of Science Degree in Biology from Kent State University in 1983. He has worked at 3M since 1985. For 20 years he was primarily involved in adhesive development. For the last 10 years he has been in Technical Service contributing to a variety of products. His main focus has been in the 3M digital products such as Incognito™ Appliance System and the Unitek™ Treatment Management Portal.




**Ming-Lai Lai, 3M Oral Care**

Ming-Lai Lai received his PhD and MS in mechanical engineering from State University of New York at Buffalo in 1988 and 1984 respectively. He earned his BS in Aeronautical Engineering from National Cheng-Kung University, Taiwan in 1979. He joined 3M in 1989 and moved to 3M Unitek in 1999, where he started work on the SmartClip™ Self-Ligating Appliance concept, leading the team from the concept through product scale-up phase. Later, Ming joined the ceramic bracket teams to develop new, non-self-ligating and self-ligating aesthetic brackets and led design efforts on the next generation of SmartClip Appliance products.

## Leading the science of orthodontic bracket technology.

Introduced in 2004, the SmartClip™ Self-Ligating Appliance System has provided doctors a different and more efficient passive self-ligating system when compared with other available systems. The SmartClip appliance does not have a door that can deform, break or become difficult to open during treatment. Instead, super-elastic nickel-titanium clips permit simple archwire insertion and removal without the need to open or close a sliding door.

The unique design of SmartClip brackets also provides a substantial list of performance features unavailable with other self-ligating brackets. Twin-wing design accommodates ligation if needed, for a passive/active-on-demand system. This also permits selective archwire engagement of a single tie-wing in severe cases, unlike door systems. The open design also helps improve hygiene, with less area where plaque can build up. Also unique is the availability of pre-coating with APC™ Flash-Free Adhesive, for the most efficient bonding in orthodontics.



Used in the treatment of more than one million patients, clinicians using the system have reported shorter treatment time, fewer office visits, and reduction in chair time.\*

## Improved clip enhances performance.

In a process of continuous improvement and responding to user input, the clip mechanism has evolved over time. The latest clip, announced in May 2016, noticeably reduces the amount of force required to engage larger archwires. The clip has also shown improved rotation control, by reducing the “play” of larger archwires in the slot.

The lower forces can increase the ease of use of the appliance, chair time efficiency and patient comfort. The significant improvement of the rotation control may reduce the use of step bends for rotated teeth, helping to achieve more efficient and better finishes.

## Lab tests confirm significantly improved archwire engagement forces.

In vitro testing of SmartClip SL3 brackets with the existing clip compared to the brackets with the improved clip show significantly reduced engagement forces on large archwires. The force required to deliberately disengage archwires is reduced as well, while maintaining the ability to hold the wire throughout treatment.

Comparisons were made of the engagement forces between the improved clip and previous clip of the SmartClip SL3 brackets for 0.016"×0.025" and 0.019"×0.025" SS archwires. On average, the improved clip provides a 19% reduction in force for 0.016"×0.025" archwires and a reduction of 15% for 0.019"×0.025" archwires.

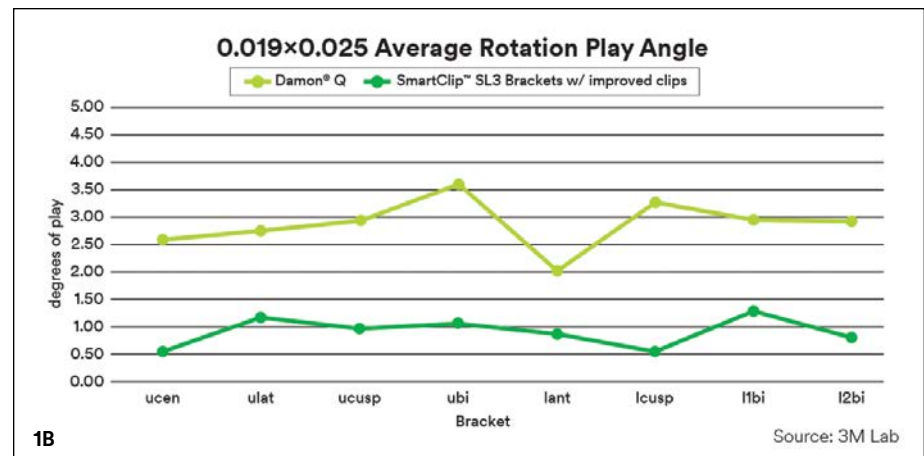
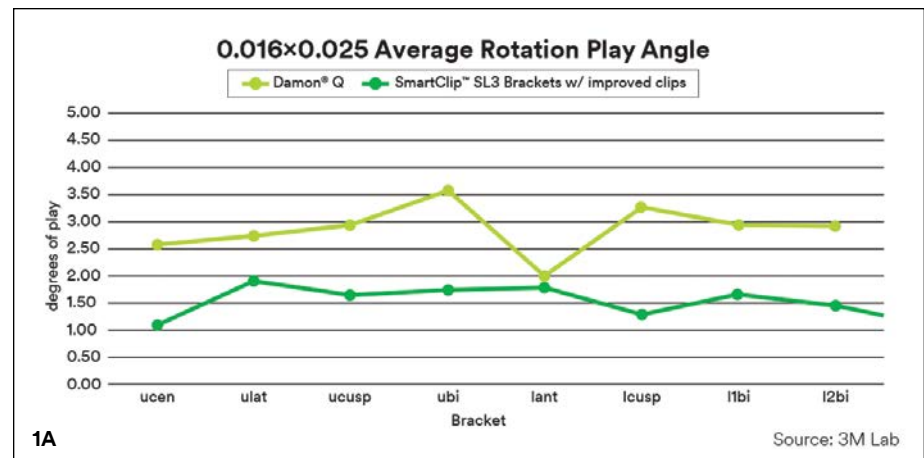
## Lab tests show a significant reduction in rotation play.

The amount of play in the bracket slot can adversely affect the archwire's ability to exert rotational control on a tooth. This is especially important in regard to rotating lower anteriors, a common occurrence in crowded cases. The improved clip design of SmartClip SL3 Brackets shows a 59% reduction in rotation play in the lower anterior brackets compared to the previous clip version when using 0.016"×0.025" archwire, and a 74% reduction in rotation play in lower anterior brackets when using 0.019"×0.025" archwire.

Overall, the SmartClip SL3 Brackets with the improved clip show an average 28% reduction in rotation play using 0.016"×0.025" archwires and 54% when using 0.019"×0.025" archwires. With the enhanced clip, all averages were less than 2 degrees of play with 0.016"×0.025" archwires and less than 1.5 degrees with 0.019"×0.025" archwire.

SmartClip SL3 brackets with the improved clips outperform Damon® Q Brackets in average rotation play angle, as shown in Figures 1A and 1B. SmartClip SL3 Brackets with the improved clip show on average 45% less rotation play than Damon Q brackets with 0.016"×0.025" archwires and on average 69% less rotation play with 0.019"×0.025" archwires.

## SmartClip™ SL3 Brackets... average less rotation play than Damon® Q brackets.



**Figure 1A-B:** Comparisons of rotation play angles between SmartClip™ SL3 Brackets with improved clip and Damon® Q Brackets.

## Evaluators in clinical practice see performance improvements.

Before releasing appliances with the improved clip, 18 experienced SmartClip Bracket practitioners from the U.S., Canada, China, and Europe were asked to evaluate the new clip. They were provided 10 cases of the SmartClip SL3 Brackets with the improved clip, upper and lower, 5×5, 0.022 slot, in the MBT™ Appliance System prescription.

Over the course of the evaluation, 82%, of the evaluators stated that they would purchase SmartClip SL3 brackets with the improved clip design over the previous design. Many commented how the noticeable change in the forces required to engage and disengage the archwire would be more comfortable to patients.

Patient comfort is of paramount importance when disengaging and engaging mid-size to larger size archwires. The customer evaluation data shows that the improvements made to the SmartClip SL3 Bracket clip have made a noticeable improvement in patient comfort. In the evaluation, a total of 90 mid-sized to larger archwires ranging from 0.014"×0.025" to 0.021"×0.025" were disengaged and engaged. Overwhelmingly, the evaluators felt that the rectangular wires were either "Easy" or "Very Easy" to disengage (89%) and engage (82%).

## Conclusion.

The results of the evaluation show that the minimized clip forces for engagement and controlled disengagement with the improved clip design of the SmartClip SL3 Brackets is noticeable to the evaluators and viewed positively, as is the improvement in rotational control.

The improved clip design allowed for effective archwire engagement while reducing the force required to remove archwires at wire changes. The added benefit of improved rotational control of the improved clip as shown by the lab data and verified in the evaluation is also supported.



# Unitek™ Treatment Management Portal (TMP) serving the Incognito™ Appliance System.

Incognito™  
Appliance System



## Dr. Aurélie Guidoux

Aurélie Guidoux earned her Dental degree in 2008 and her Orthodontic degree in 2012 from the Catholic University of Louvain, in Belgium. She works part-time in a private practice. She is a consultant for the Department of Orthodontic and Dento-facial orthopaedics of Cliniques Universitaires de Saint-Luc, Brussels, where she combines a scientific and pedagogic function. Dr. Guidoux treats many adult patients and delivers the most aesthetic and precise orthodontic treatments to her patients.

Communication is an important issue of the 21st century. Going faster, going further and always keeping in mind ecology. Many new technologies and a flood of information daily overwhelm us. Messages can pass unnoticed in a sea of information. The Unitek™ Treatment Management Portal (TMP) is an innovative tool that allows the orthodontist to interact with the 3M Orthodontic Lab, manage digital models, plan orthodontic treatments and customize the Incognito™ Appliance System using a one and only platform.

## Goodbye Incognito™ System Paper Order Forms:

The Unitek TMP software, compared to classical paper order forms, enhances the quality of instructions sent to the lab. Most of us have had the unpleasant experience of not having enough room to complete the paper order form correctly, using tons of sticky notes and praying that they are not lost during the mailing process. Managing orders is clear with Unitek TMP. Errors are reduced and orders are readily customized.

## Toward an Accurate Diagnosis:

Options to fill in information with the Unitek TMP form is more extended than the paper form. The requested information in regard to diagnosis and customization of the Incognito Appliance System is more exhaustive. New interesting features are now included in the Unitek TMP form such as (Figure 1):

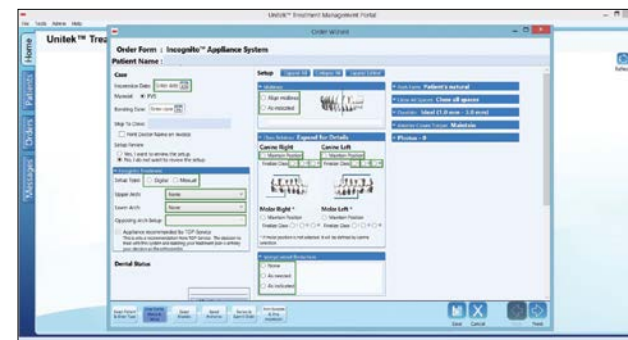


Figure 1

- **Arch form:** You can now specify if you want to keep the patient's arch form or to change it. You will then mention the arch form desired.
- **Lower arch width:** You can indicate if you want to maintain, decrease or increase the intercanine and/or intermolar width.

- **Closing all spaces:** You can specify the way you want to close the spaces, which can be really important for some cases.
- **Leveling of upper anteriors:** You can detail if you want to level gingival margins, level incisal edges, place lateral incisors 0.5 mm shorter than centrals or give specific recommendations.
- **Anterior crown torque:** You can point out to maintain or correct the anterior crown torque as indicated according to the treatment plan.

These tools build up the communication with the technician in the lab who is in charge of your cases. You can easily point out their attention to specific important details.

## A Step Toward an Increasingly Customized Incognito™ Appliance:

The Unitek TMP form allows you to choose the type of braces or bands for each tooth separately. You make your selection in a very complete drop-down menu, which is an easy way to individualize treatments (Figure 2).

Another novelty is that you can also select lateral section type of archwires separately for the right side or the left side (Figure 3).

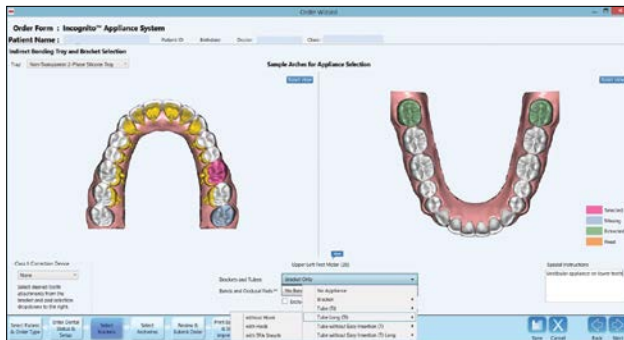

Figure 2

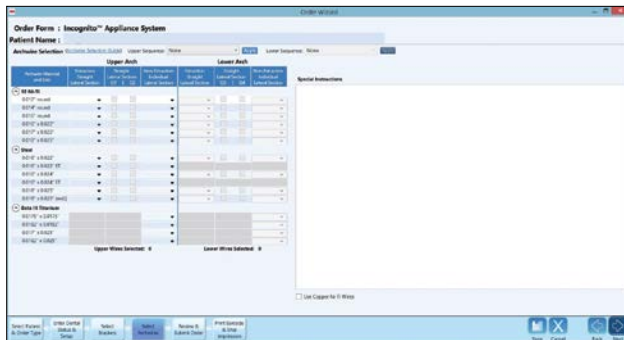


Figure 3

## A More Global View of Your Incognito™ Appliance System Orders:

When recording of patient prescription information is over, you will receive an order summary. You can quickly check if the order is complete and, if needed, go steps back for modifications before sending the request.

Data is also recorded in a more organized and systematic way than with the paper order forms and may be consulted at any time. Digital pictures and X-rays can directly be uploaded in the Unitek TMP platform and can be stored in the patient file.

## Interactive and Precise Incognito™ Appliance Setup Review:

Precision of the Incognito setup is of prime necessity to target the final results desired by patients. To maximize efficiency of the Incognito Appliance System, you must keep in mind from beginning little details that will deliver perfect functional and aesthetic results.

Thanks to measurement and viewing tools, the digital setup allows you to dynamically check the prepared setup. You can use facial, lingual, right or left lateral, upper or lower occlusal views to verify all parameters of your setup like overbite, overjet, torque, class relation, rotation, arch forms. Rotation of the digital model in all directions is handy and instructive. A Bolton analysis is quickly executed thanks to the measurement tools (Figure 4). The grid plane visibility offers the possibility to check the setup with the precision to the millimeter (Figure 5).

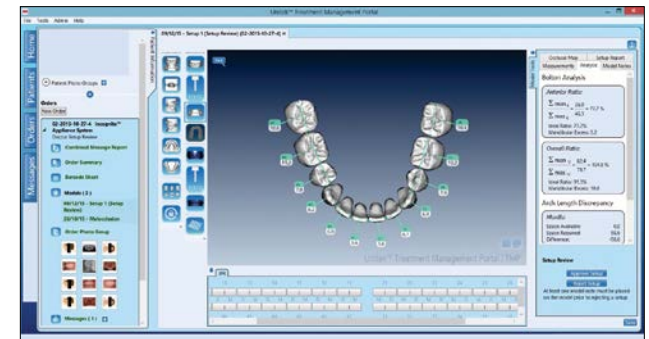


Figure 4

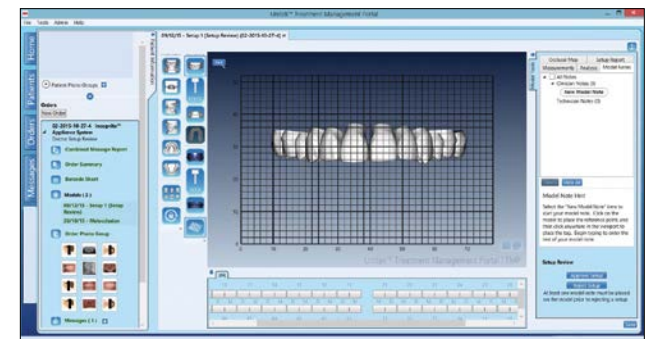


Figure 5

A particularly relevant tool is the overlay view to verify teeth movements between the initial malocclusion and the final setup model. It is more comfortable for orthodontists than comparing pictures and stone models (Figure 6). This advanced feature is an appealing tool to explain the treatment plan to your patients.

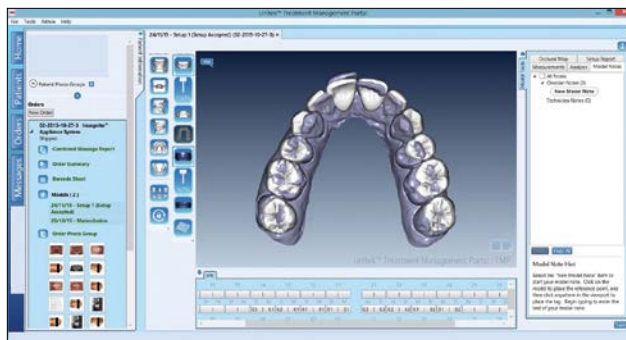


Figure 6

If some modifications are required, you may click on “New Model Note” and add a comment by pointing on the proper tooth or area (Figure 7). The technician in the lab can moreover add a “New Model Note” to give you some information about your setup.

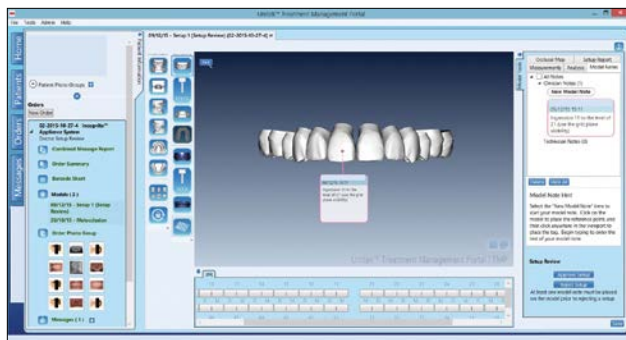


Figure 7

Communication with technicians is available as well through messaging within Unitek TMP, and is now easier than before (Figure 8).

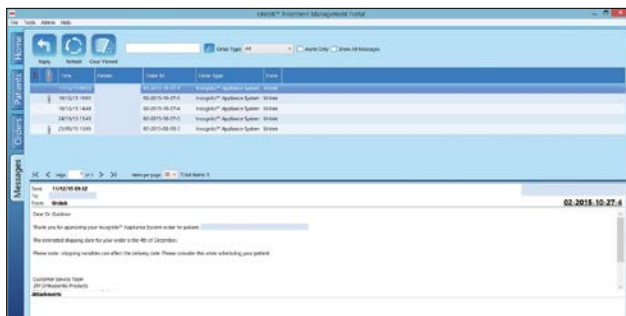


Figure 8

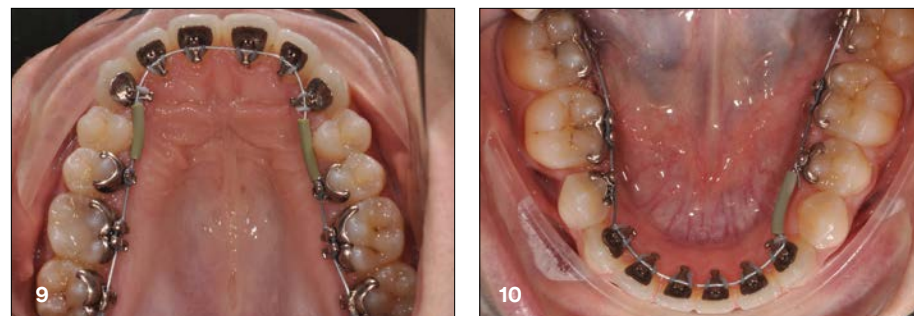


Figure 9-10: The different planning and analysis tools available within Unitek™ TMP help deliver lingual appliances ideally suited to achieving your treatment goals.

## Saving Precious Time:

Changing habits always require an adjustment period. At first, filling out the digital forms will take you more time than filling out the paper order forms. When you become used to the new interface, you will be delighted by the ease of use. There is no need to open many files at the same time; all of the information is stored in this one and only platform.

Integration of digital technologies in our daily practice is essential to increase communication and efficiency. However, we must find programs that help us in many ways to avoid multiplying technologies. The Unitek Treatment Management Portal is the ideal solution.

# 3M<sup>SM</sup> Health Care Academy

## Upcoming 2016 Educational Opportunities

DATE	LOCATION	SPEAKER(S)	EVENT
September 9-10	Spain	Dr. Leandro Fernandez, Dr. Paul Ward	Incognito™ Appliance System Course
September 15	Japan	Dr. Keizo Hirose, Dr. Toru Inami, Dr. Shoji Sugiyama	Incognito™ Appliance System Advanced Course
September 17-18	Russia	Dr. Sergey Popov	Incognito™ Appliance System Course
October 6-7	USA	Dr. Lisa Alvetro	In Office Course
October 12-13	Japan	Dr. Keizo Hirose, Dr. Shoji Sugiyama	Incognito™ Appliance System Course
October 14	Estonia	Dr. Simon Littlewood	Aesthetics and Efficiency
October 15	Hungary	Dr. Lars Christensen	Aesthetic Adult Treatment
October 15	Lithuania	Dr. Simon Littlewood	Aesthetics and Efficiency
October 19	Latin America	Dr. Hugo Trevisi	MBT™ Appliance System – Webinar on Versatility
October 21	Mexico	Dr. Jair Lizarin	Seminar – MBT™ Appliance System and Indirect Bonding
October 21-22	Germany	Dr. Lars Christensen, Dr. Esfandiar Modjahedpour	Incognito™ Appliance System Course
October 25	Slovenia	Dr. Anoop Sondhi	Self-Ligating Clinical Efficiency and VPO
October 27	Ukraine	Dr. Anoop Sondhi	TMD, Neuromuscular Orthodontics
October 27-28	Brazil	Dr. Hugo Trevisi	MBT™ Appliance System Professors Course
October 28	Switzerland	Dr. Esfandiar Modjahedpour	Incognito™ Appliance System Advanced Course
November 4	Brazil	Dr. Reginaldo Zanelato	Seminar – MBT™ Appliance System & Self-Ligation
November 4-5	Saudi Arabia	Dr. Lars Christensen	Adult Aesthetic Treatment
November 9-10	Brazil	Dr. Ricardo Moresca	MBT™ Appliance System Seminar
November 10-11	USA	Dr. David Kemp	In Office Course
November 11	Czech Republic	Dr. Lars Christensen	Aesthetic Adult Treatment
November 18	Brazil	Dr. Ricardo Moresca	Seminar – MBT™ Appliance System & Class II
November 19-25	Brazil	Dr. Julio Brant	In Office Course
November 20-21	Vietnam	Dr. Lisa Alvetro	Self-Ligation & Aesthetics
November 23	Thailand	Dr. Lisa Alvetro	Self-Ligation & Aesthetics
November 25-26	Australia	Dr. Lisa Alvetro	Self-Ligation & Aesthetics
November 25-26	Brazil	Dr. Ricardo Moresca	MBT™ Appliance System Seminar
December 3	Hungary	Dr. Beyza Kircelli	Incognito™ Appliance System Advanced Course
December 7	Turkey	Dr. Anoop Sondhi	Clinical Efficiency of Self-Ligating and Conventional Treatment Mechanics
December 9-11	Saudi Arabia	Dr. Anoop Sondhi	Contemporary Orthodontic Treatment with Self-Ligating Appliances and VPO

### 2017 Educational Opportunities *Watch for more information!*

February 17-18, 2017: Ski & Learn Park City (USA)  
 March 25-26, 2017: Nashville Resident Summit (USA)

▶ **Interested in an upcoming educational event?**  
 Contact your local 3M representative today!





## 3M<sup>SM</sup> Health Care Academy

# Clinical Cases



## 3M<sup>SM</sup> Health Care Academy

# Deep bite correction with ceramic brackets.

**CLARITY™ | ADVANCED**  
advanced ceramic brackets

**APC™ Flash-Free**  
Adhesive Coated Appliance System



### Dr. Patrice Pellerin

Dr. Pellerin received his post graduate Certificate in Orthodontics in 1991 from the University of Montreal. Before orthodontics, he practiced general dentistry for four years after earning his dental degree from the University of Montreal in 1985. Since 1991, he has maintained a solo private practice in Lachine, Quebec. In 1998, Dr. Pellerin converted his practice to a fully aesthetic practice. He is referred to by his peers as the grandfather of the completely

aesthetic practice. He has lectured worldwide to share his practice philosophy of highest aesthetics without compromise to accomplish treatment. Dr. Pellerin also currently teaches lingual and aesthetic orthodontics to the residents at the University of Montreal and University of Winnipeg. He has been an active member of the 3M Unitek Advisory Committee for Aesthetic Appliances since 2003, as well as a 3M Advocate for the use of aesthetic appliances since 2004.

### Introduction

A lot of doctors are hesitant to treat deep overbites with mandibular ceramic braces. The first thing to recognize is that now Clarity™ ADVANCED Ceramic Brackets have the same profile as the metal Victory Series™ Low Profile brackets which is a huge advantage over all other ceramic brackets. One way of dealing with deep bites and ceramic brackets on the mandibular arch is to delay the bonding of the lower arch until the bite is open enough to avoid contact of the maxillary teeth on the lower brackets. As you can see in this case, the delay was five months, but the total treatment time was 19 months, so we're not making the treatment longer but we are optimizing our choices of appliances to please our patient.

Our direct bonding procedures using APC™ Flash-Free Adhesive are so much more efficient that now, if a patient lives far from the office, we will opt for direct bonding over indirect bonding to reduce travel time and visits for patient convenience. Using APC Flash-Free Adhesive with direct bonding, no bond failures or emergency appointments during treatment.

### Patient

Female (F.B.)  
14 years, 10 months

### Patient's Main Concern

Spaces between my two front teeth and they are too long

### X-ray Findings

- Complete permanent dentition
- Pneumatized maxillary sinuses
- Root dilacerations on bicuspid, mainly UR5, UR4
- Evidence of formation of three wisdom teeth (lower left is missing)

## Dental Analysis

- Class II subdivision relationship on patient's right side
- Light to moderate crowding in both arches
- Midline discrepancy
- Upper midline discrepancy
- Excessive OB with too much incisor showing
- Narrow upper jaw
- Accentuated lower curves of Spee and Wilson

## Treatment Plan

- Upper/Lower – Clarity™ ADVANCED Ceramic Brackets 0.018 slot – MBT™ Appliance System prescription – APC™ Flash-Free Adhesive precoating
- Bonding charts: Upper MBT System deep bite 4.0 mm  
Lower MBT System standard 4.5 mm
- Band with occlusal headgear tube on UR6
- Extraction of UR7 and UR8 (wisdom teeth will be kept as replacement for UR7)
- UR8 showing a Nolla stage of development of 7
- Forsus™ Fatigue Resistant Device on patient's right side to regain the Class I molar relationship
- Light Class II elastics to finalize the midline correction
- Direct Bonding

Treatment	19 months (April 2013 – November 2014)		
Mx	April 2013	Direct Bonding	14 SE (7s), 16×16 SE (7s), 16×22 SE (8s), 17×25 Classic to the end
Md	September 2013	Direct Bonding	16 SE (7s), 16×22 SE (21s), 17×25 Classic to the end
# of visits	15		
Emergencies	0		

## Retention

- Fixed lingual wires 0.018 TMA
- Upper canine to canine/Lower first bicuspid to first bicuspid

\*UR8 was erupted enough and in contact with LR7, so no other specific retention was required to prevent extrusion of LR7

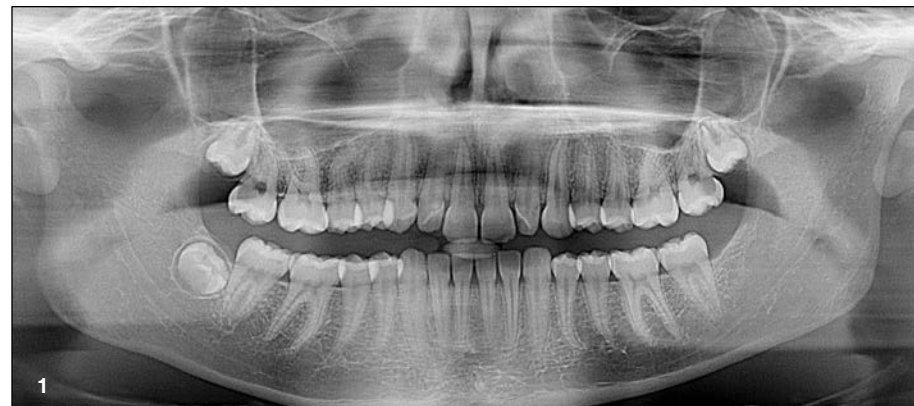

Figure 1: Initial X-ray.

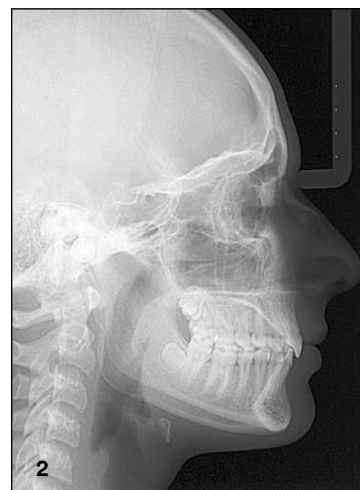

Figure 2: Initial cephalometric analysis.

Cephalometric Analysis				
SNA (°)	87.4	82.0	3.5	1.5 *
SNB (°)	82.9	80.9	3.4	0.6
ANB (°)	4.5	1.6	1.5	1.9 *
Maxillary Depth (FH-NA) (°)	96.5	90.0	3.0	2.2 **
Facial Angle (FH-NPo) (°)	92.8	88.6	3.0	1.4 *
FMA (MP-FH) (°)	16.1	23.9	4.5	-1.7 *
UFH:LFH, Upper (N-ANS/N-Gn) (%)	45.2	45.0	1.0	0.2
U-Incisor Protrusion (U1-APo) (mm)	-0.1	6.0	2.2	-2.8 **
U1 – Palatal Plane (°)	98.9	110.0	5.0	-2.2 **
L1 Protrusion (L1-APo) (mm)	-3.3	2.7	1.7	-3.5 ***
IMPA (L1-MP) (°)	92.0	95.0	7.0	-0.4
Interincisal Angle (U1-L1) (°)	150.6	130.0	5.0	4.1 ****
Upper Lip to E-Plane (mm)	-5.1	-5.9	2.0	0.4
Lower Lip to E-Plane (mm)	-3.4	-2.0	2.0	-0.7
Nasolabial Angle (Col-Sn-UL) (°)	129.3	102.0	8.0	3.4 ***
Maxillary length (ANS-PNS) (mm)	51.0	51.6	4.3	-0.1
Mandibular length (Go-Gn) (mm)	78.7	65.9	5.5	2.3 **
Facial Convexity (G'-Sn-Po') (°)	159.1	154.0	5.6	0.9
Wits Appraisal (mm)	4.1	-1.0	1.0	5.1 *****
SUMMARY ANALYSIS				
Class II Molar Relationship				
Skeletal Class II (A-Po)				
Skeletal Class II (ANB)				
Low Mandibular Plane Angle				
Protrusive Maxilla (A-N)				
Protrusive Mandible (Pg-N)				

Table 1: Cephalometric analysis.

Initial

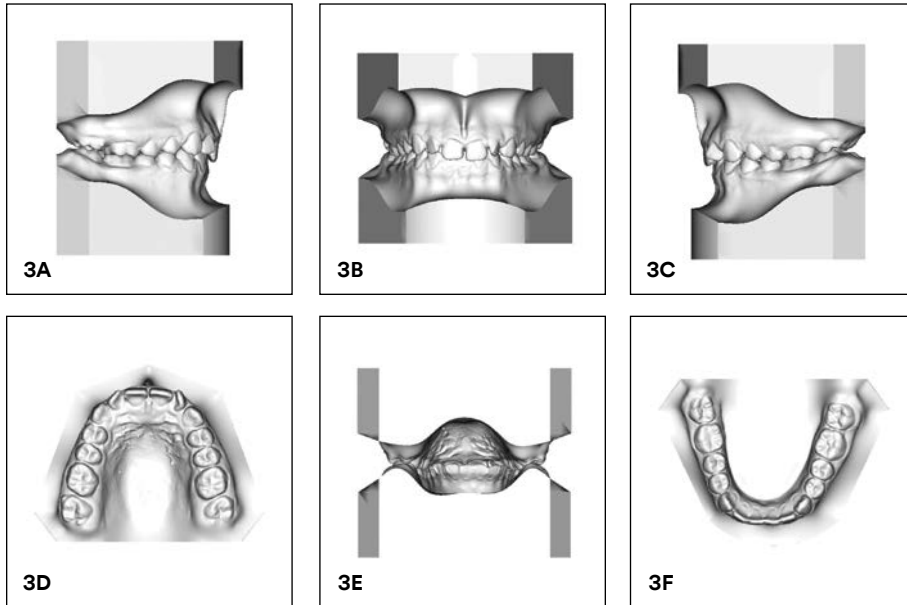


Figure 3A-F: Initial dental analysis.

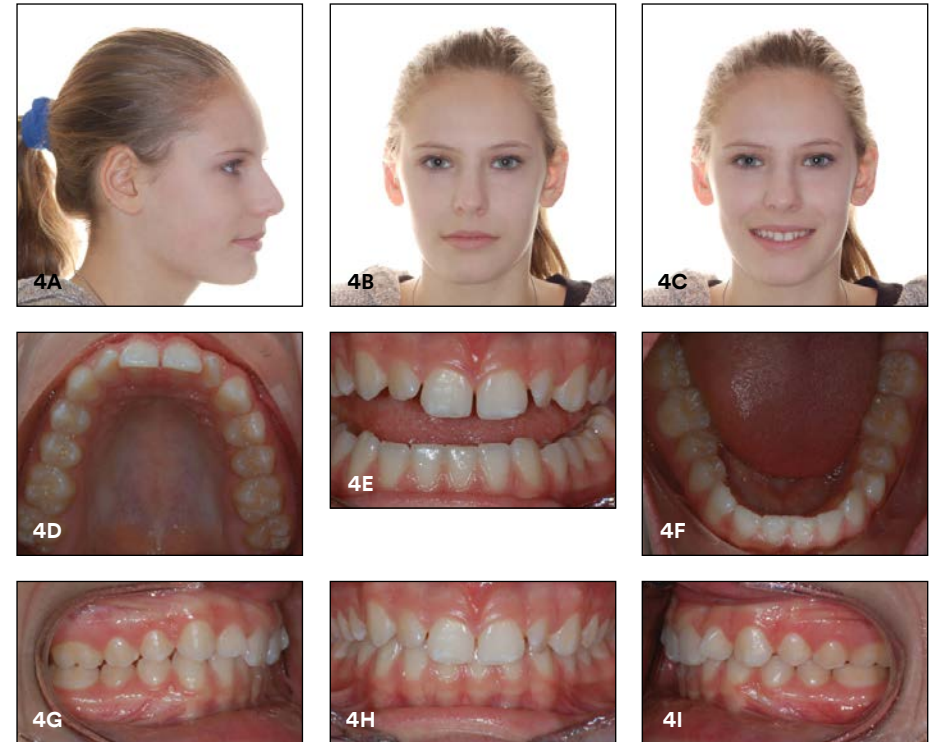


Figure 4A-I: Initial photos.



## Mid-Treatment

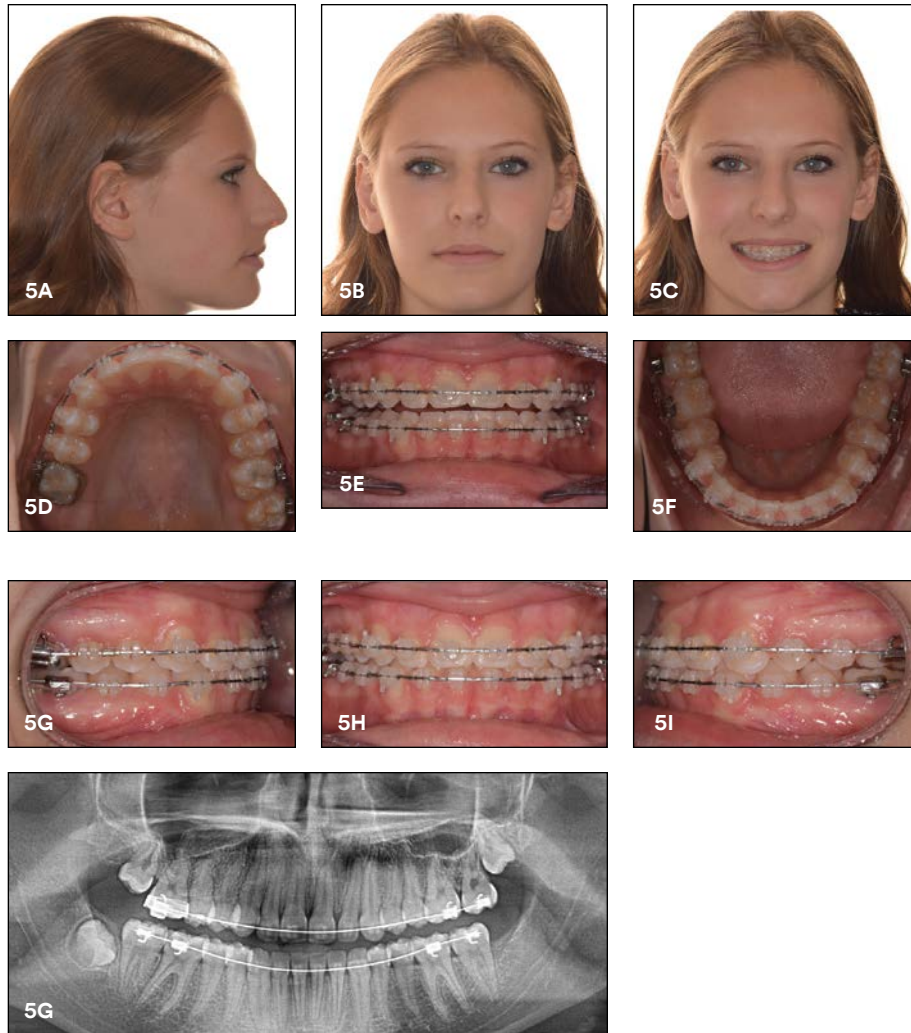


Figure 5A-J: Mid-treatment photos.

## Retention

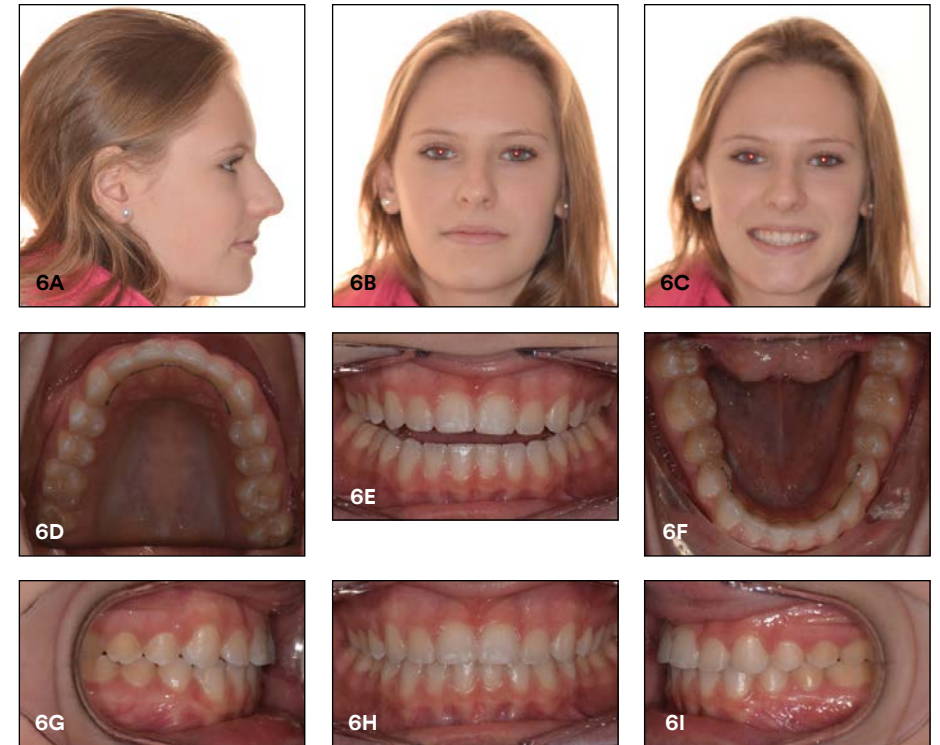


Figure 6A-I: Retention photos.

## Initial vs. Final


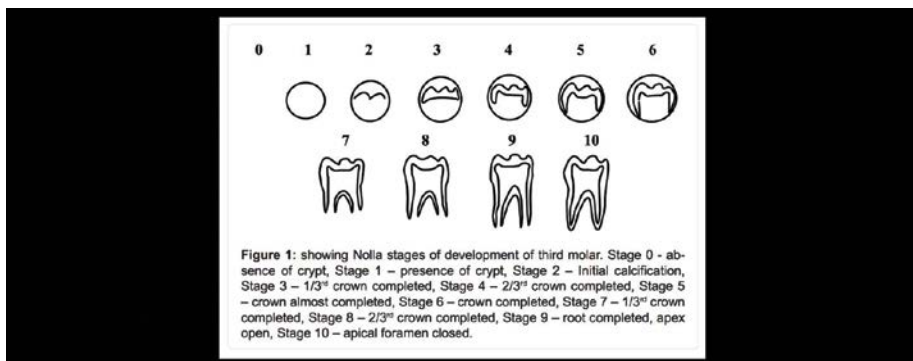


Figure 7A-B: Initial vs. final photos.

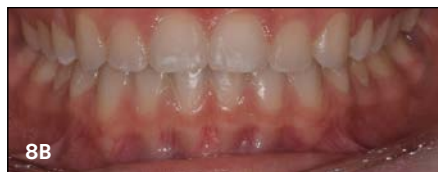
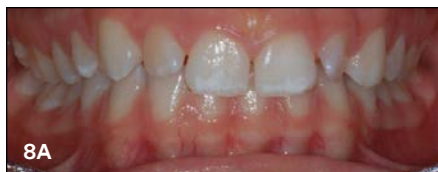
Figure 8A-B: Initial vs. final photos.

**Doctor's Note:** Nolla stage of development is used to assess the formation of the wisdom teeth in a molar extraction case.



From: Panchbhai AS. Radiographic evaluation of development stages of Third Molar in relation to Chronological Age as applicability in forensic Age estimation. Forensic Odontology. 2012;

1. Trevisi H, Trevisi Zanelato R. State-Of-The-Art Orthodontics, Self-Ligating Appliances, Miniscrews and Second Molar Extractions, Mosby, 2011. p164
2. Basdra EK, Stellzig A, Komposch G. Extraction of maxillary second molars in the treatment of Class II malocclusion. Angle Orthod. 1996;66(4):287-91.
3. Chipman MR. Second and third molars: their role in orthodontic therapy. Am J Orthod. 1961 Jul;47(7):498-520.

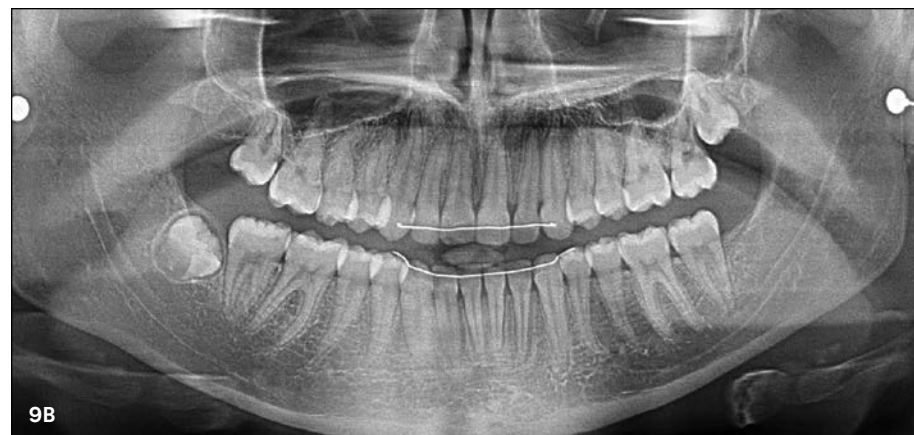
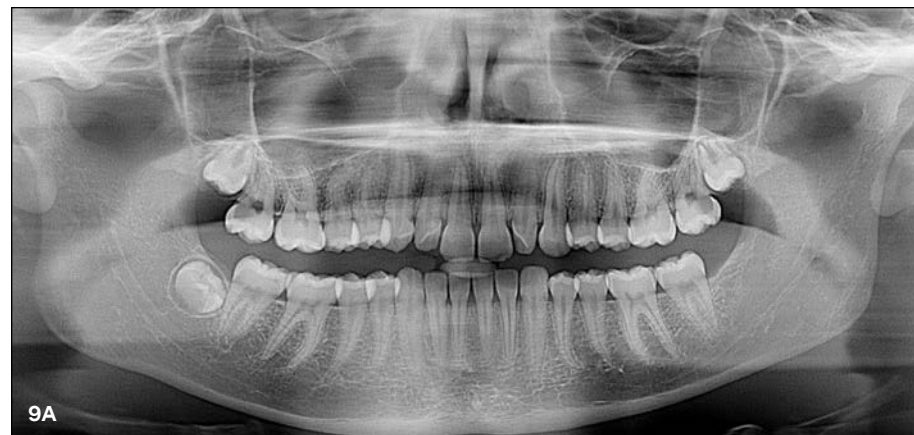
Figure 9A-B: Initial vs. final X-rays.

Case photos provided by Dr. Patrice Pellerin.

3M, APC, Clarity, Forsus, MBT, and Victory Series are trademarks of 3M. Used under license in Canada. © 3M 2016. All rights reserved.



## 3M<sup>SM</sup> Health Care Academy

# The Three E's: Efficiency, Effectiveness and Excellence

SMARTCLIP<sup>TM</sup> SL3  
SELF-LIGATING APPLIANCE SYSTEM

CLARITY<sup>TM</sup> SL  
SELF-LIGATING APPLIANCE SYSTEM



**Dr. Anoop Sondhi**

Dr. Anoop Sondhi received his dental degree from the Indiana University School of Dentistry, and his post-graduate certificate and M.S. in Orthodontics from the University of Illinois in 1977. Following his graduation, he was on the graduate faculty of the Department of Orthodontics at Indiana University. During his full-time academic appointment at Indiana University, he maintained a part-time private practice. Since 1988, he has

been in full-time private practice in Indianapolis, and continues to be a Visiting Professor for several graduate programs in Orthodontics. He has presented seminars and continuing education courses to several dental and Orthodontic organizations in the United States, and has been invited to give courses in Canada, Central America, South America, Europe, Asia, South Africa, Australia and New Zealand.

### Abstract

*This case demonstrates the efficiency of treatment with Clarity<sup>TM</sup> SL Self-Ligating Brackets and SmartClip<sup>TM</sup> SL3 Self-Ligating Brackets, the effectiveness of the Forsus<sup>TM</sup> Class II Correctors, and the excellence in finishing afforded by using Variable Prescription Orthodontics.*

The treatment of adult Class II Division 2 cases can frequently be challenging, because of the difficulty in correcting the deep overbite, as well as the challenge of correcting the anteroposterior discrepancy in a non-growing patient.

This patient presented with an asymmetric Class II Division 2 malocclusion. The left side was a full cusp Class II, and the right side a half cusp Class II. In addition, he had a deep anterior overbite. Somewhat unusual in his clinical presentation were the divergent axial inclinations of the maxillary central incisors. Instead of the usual lingual inclination of both maxillary central incisors, only the right central incisor was lingually inclined, and the left central incisor was flared labially.

Skeletally, there was a slight mandibular retrognathia, which was partly masked by a prominent chin button. A minor mandibular arch length deficiency was evident, and teeth #16 and 32 were impacted. Tooth #18 was partially unerupted, and the mesial marginal ridge was submerged below the distal marginal edge of tooth #19. The patient was 17 years old, and essentially an adult, non-growing patient. Figure 1A-H, Figure 2, and Figure 3 demonstrate the pre-treatment clinical records. The impacted third molars can be visualized, as well as the divergent inclinations of teeth #8 and 9.



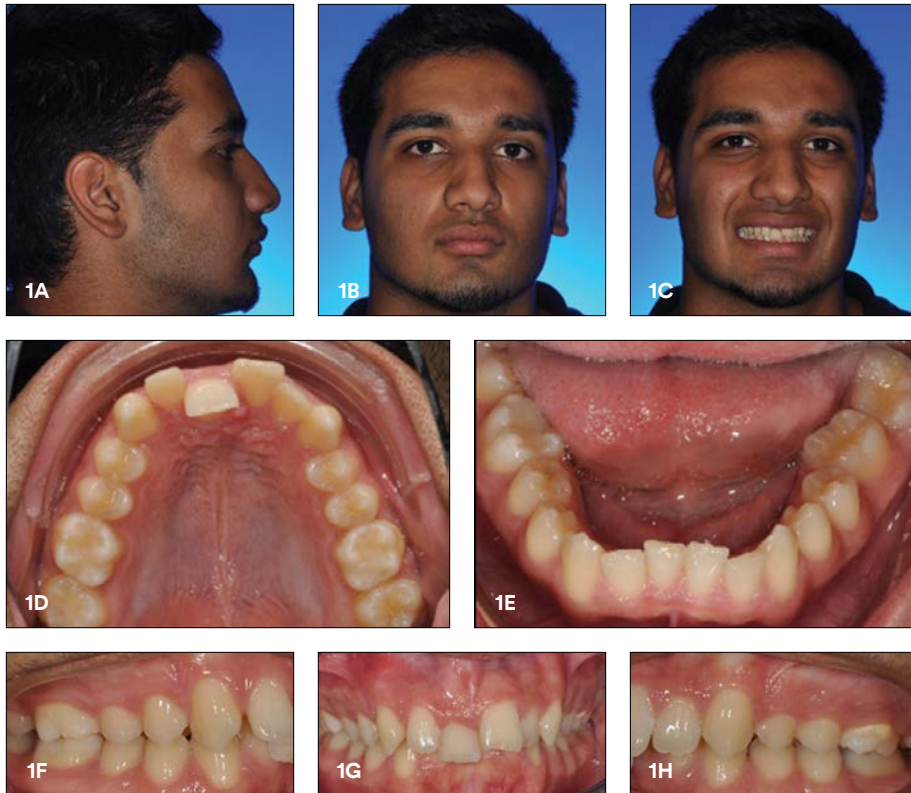

Figure 1A-H

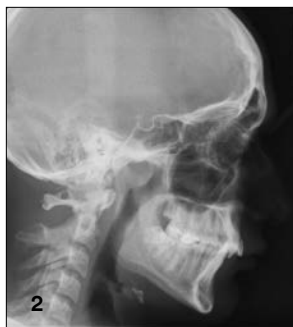

Figure 2

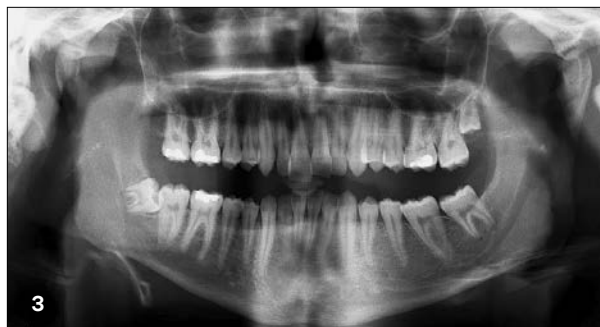

Figure 3

In the past, it would not have been uncommon for this type of case to be treated with the extraction of two maxillary premolars. However, for reasons of his overall facial profile, as well as the lip profile, extractions were considered undesirable. He was, however, advised that teeth #16 and 32 would eventually require extraction.

As the treatment plan was developed, it became clear that this case would allow for an excellent combination of the efficiency facilitated by self-ligated appliances, supplemented by the effectiveness of Class II correction with the Forsus™ Class II Corrector appliance, and the excellence and precision introduced by implementing the concept of using a Variable Prescription. It is evident, of course, that the bracket positioning would be for correction of the deep anterior overbite. However, it is important to recognize the applicability of using a Variable Prescription. Teeth #8 and 9 obviously have widely divergent axial inclinations, easily visualized not just clinically, but also on the cephalometric radiograph. The problem of using a static prescription, regardless of which type is used, is the evident illogic in placing brackets with similar torque and angulation values on teeth #8 and 9. Quite obviously, tooth #8 would require a substantial amount of lingual root torque, and tooth #9 will not. Further, since the use of a Forsus Class II corrector will clearly tend to cause labial proclination of the mandibular anterior segment, that would argue in favor of using low torque brackets in the mandibular arch.

An example of the selected prescription can be seen in Figure 4. For reasons described above, we used medium torque brackets (labeled green) in the maxillary arch, with the exception of the maxillary right central incisor, where we placed a high torque bracket (labeled blue). The mandibular arch was treated with low torque brackets (labeled yellow).



Figure 4



Figure 5A-E shows the photographs taken at the bonding appointment. The appliance of choice was Clarity™ SL Self-Ligating Brackets on the maxillary arch, with SmartClip™ SL3 Self-Ligating Brackets on the mandibular arch in the .018x.025 slot. A resin reinforced, fluoride releasing, glass ionomer material is used on the occlusal surfaces of the maxillary first molars to disarticulate the occlusion. Because of the significant displacement of tooth #8, the initial maxillary and mandibular archwire were .014 heat activated Nitinol archwires.

Eight weeks later, the patient was seen for a follow-up appointment, at which time some brackets were repositioned (Figure 6A-E). Please note the extremely efficient reduction in the imbrication of the maxillary incisors in just the first eight weeks of treatment. Upper and lower .014 and Nitinol tandem wires were added at this time, and some remaining brackets were repositioned at the follow-up appointment eight weeks later. At the third appointment, maxillary and mandibular .016x.025 Beta III Titanium archwires were placed to continue leveling the Curve of Spee, and to begin establishing torque control (Figure 7A-E).

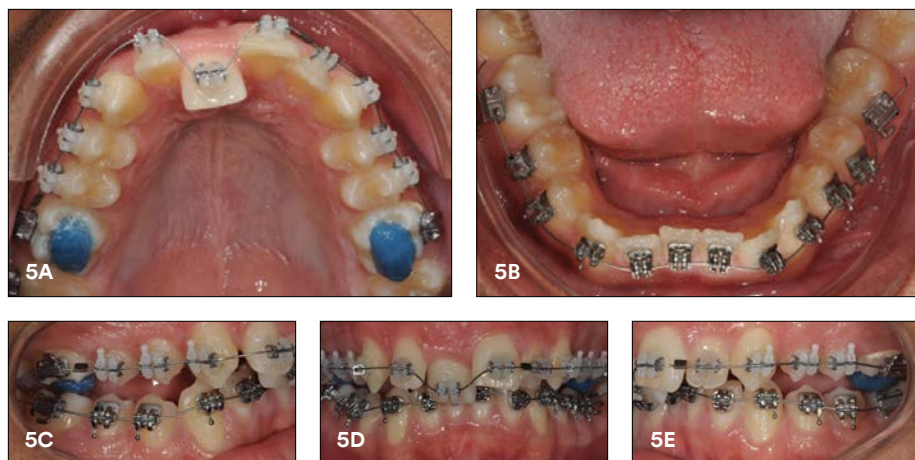


Figure 5A-E

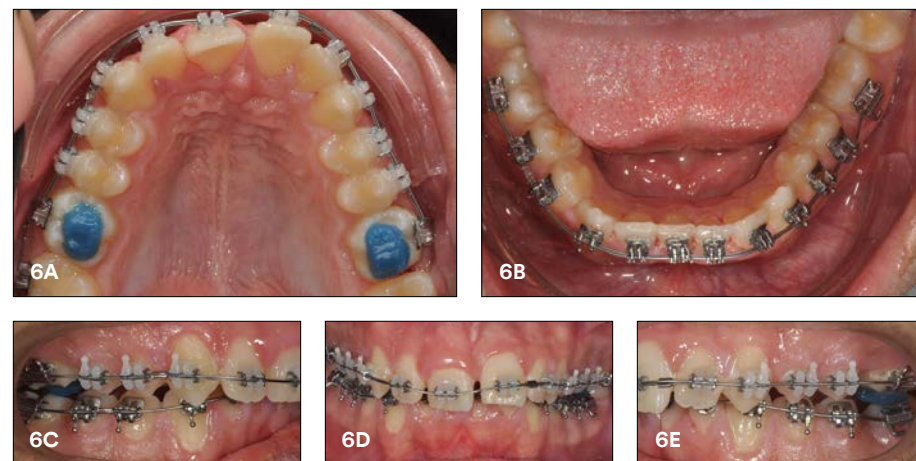


Figure 6A-E

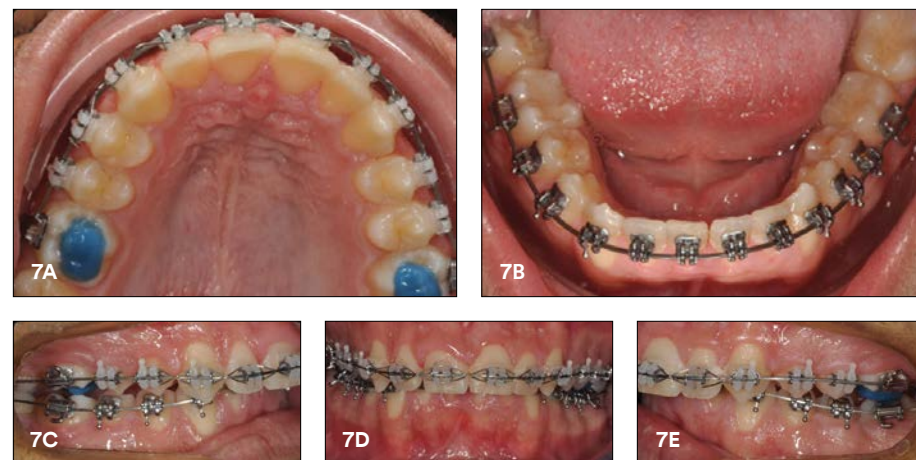


Figure 7A-E

Following 16 weeks of leveling, Forsus Class II Correctors (Figure 8A-C) were placed on the right and left sides. The Forsus appliance was placed for five months, following which the finishing .016x.025 Beta III Titanium archwires were inserted.

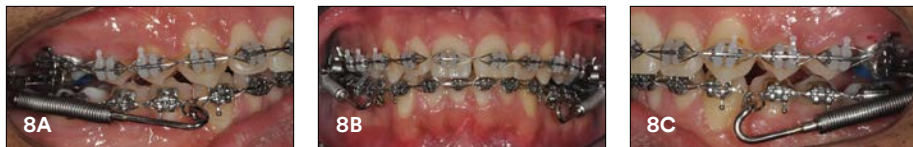

Figure 8A-C

Some minor 2<sup>nd</sup> and 3<sup>rd</sup> order adjustments were needed, and Figure 9A-H, Figure 10, and Figure 11 demonstrate the completed orthodontic treatment. Please note that, since Variable Prescription appliances were used, we did not have to place individual and separate torque activations for teeth #8 and 9. Further, the use of a low torque prescription in the mandibular arch minimized the lingual proclination of the mandibular incisors with the Class II corrector. Figure 12A-B and Figure 13 demonstrate a comparison of the pre- and post-cephalometric radiographs, as well as the superimposition tracings.

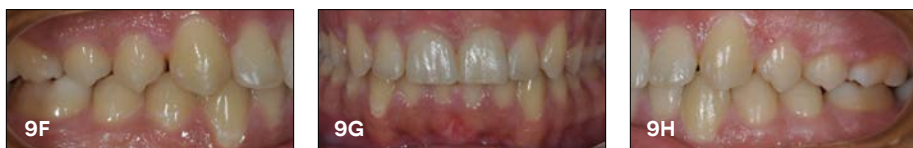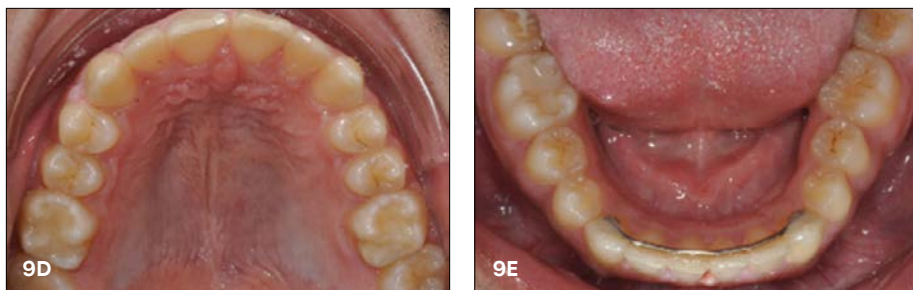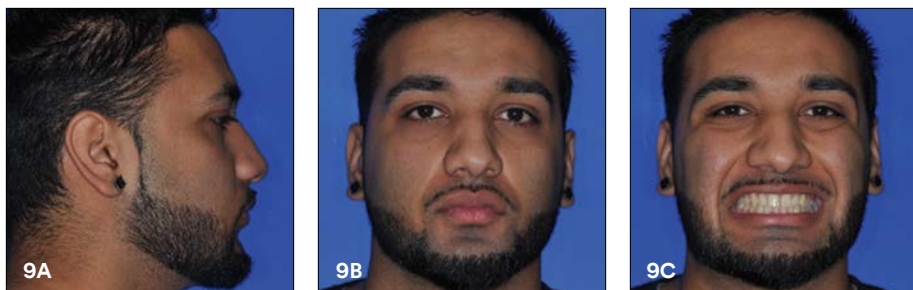


Figure 9A-H

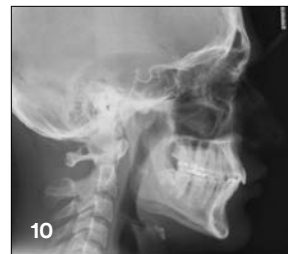

Figure 10

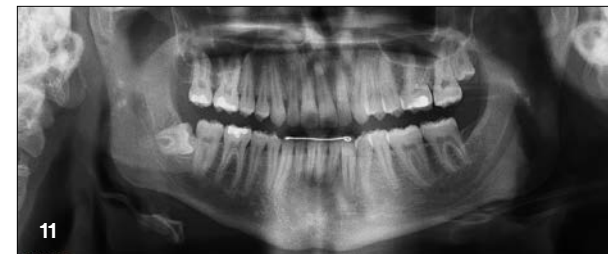

Figure 11

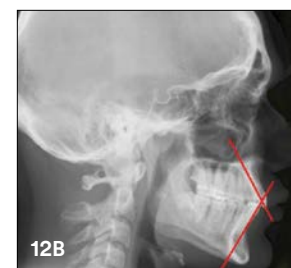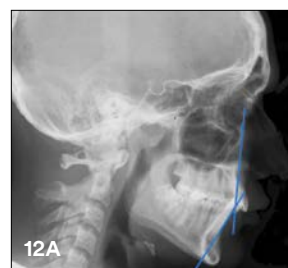


Figure 12A-B

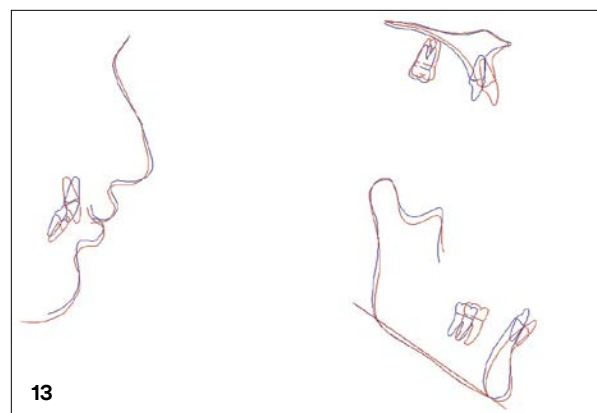


Figure 13

The total time in treatment was 17 months, which is a very efficient window of time for treatment of this case. This was achieved due to the efficient initial alignment afforded by self-ligation, the effectiveness of the Class II correction provided by the Forsus Class II corrector, and the caliber of the finishing details with the Variable Prescription.

*Case photos provided by Dr. Anoop Sondhi.*

Some article content was previously published in "The Tandem Archwire Concept with Self-Ligating Brackets.", Journal of Clinical Orthodontics, 2014; Vol XLVII, No 4. Used with permission.

3M, Clarity, Forsus, and SmartClip are trademarks of 3M. Used under license in Canada. © 3M 2016. All rights reserved.



## 3M<sup>SM</sup> Health Care Academy

# Enhancing Class II treatment efficiency with Clarity<sup>TM</sup> SL Self-Ligating Brackets and Forsus<sup>TM</sup> Class II Correctors.

CLARITY<sup>TM</sup> | SL  
SELF-LIGATING APPLIANCE SYSTEM



### Dr. Ricardo Moresca

Dr. Ricardo Moresca received his dental degree in 1991 and his post-graduate certificate in Orthodontics in 1996 from the Federal University of Paraná, Brazil, his M.S. in Orthodontics from the Methodist University of São Paulo, Brazil, in 2000 and his Ph.D. in Orthodontics from the University of São Paulo, Brazil, in 2006. Since 2004, he is Assistant Professor of the Department of Orthodontics at Federal University of Paraná, maintaining a part-time private practice in Curitiba, Brazil.

### Introduction

The Class II malocclusion is considered one of the most challenging treatment needs to orthodontists. Besides the skeletal and/or dental characteristics, facial features can also influence treatment options. In this case report, a half-cuspid Class II malocclusion patient was successfully treated with Forsus<sup>TM</sup> Class II Correctors, enabling reduction in treatment time and patient's compliance. Clarity<sup>TM</sup> SL Self-Ligating Brackets were selected to improve aesthetic appearance and performance (low friction during initial phases and control during Class II correction). The MBT<sup>TM</sup> System prescription was essential to achieve excellent torque control, especially in the lower anteriors.

### Patient

Female; 12 years, 11 months

### Patient's Main Concern

Misalignment of anterior teeth and spacing between upper central incisors.

### X-ray Findings

- Complete permanent dentition
- Roots mineralization beginning on third molars
- Short roots noted on teeth #1.1 and 2.1

### Dental Analysis

- Half-cusp Class II Division 2 malocclusion
- Deep overbite (5 mm)
- Upper central incisors extruded and tipped distally with a 2 mm diastema
- Upper lateral incisors tipped labially
- Lower posterior teeth tipped lingually
- Accentuated lower curve of Spee (4 mm)



## Treatment Plan

- Upper/Lower Clarity SL ceramic self-ligating brackets – .022" slot – MBT System Prescription
- Molar tubes bonded to upper and lower molars – .022" slot – MBT Prescription
- Buildups on lower first molars tubes to open the bite allowing lower brackets positioning
- Alignment and leveling of upper and lower arches
- Forsus™ Appliance for Class II correction (bonded first upper molar tubes were replaced with bands)

Treatment	20 months (February 2013 – October 2014)		
Mx	February 2013	Indirect	.014" SE, .016" SE, .014" and .016" SE, .017"x.025" SE, .019"x.025" SE, .019"x.025" SS, .019"x.025" Braided
Md	April 2013	Indirect	.014" SE, .016" SE, .018" SE, .017"x.025" SE, .019"x.025" SE, .019"x.025" SS, .019"x.025" Braided
Forsus™ Treatment	4 months (July 2013 – November 2013)		
# of visits	18		
Emergencies	1		

## Retention

- Removable appliance with bite plane on upper arch to avoid lower incisors extrusion
- 3x3 fixed lingual retainer on lower arch

## Initial Records

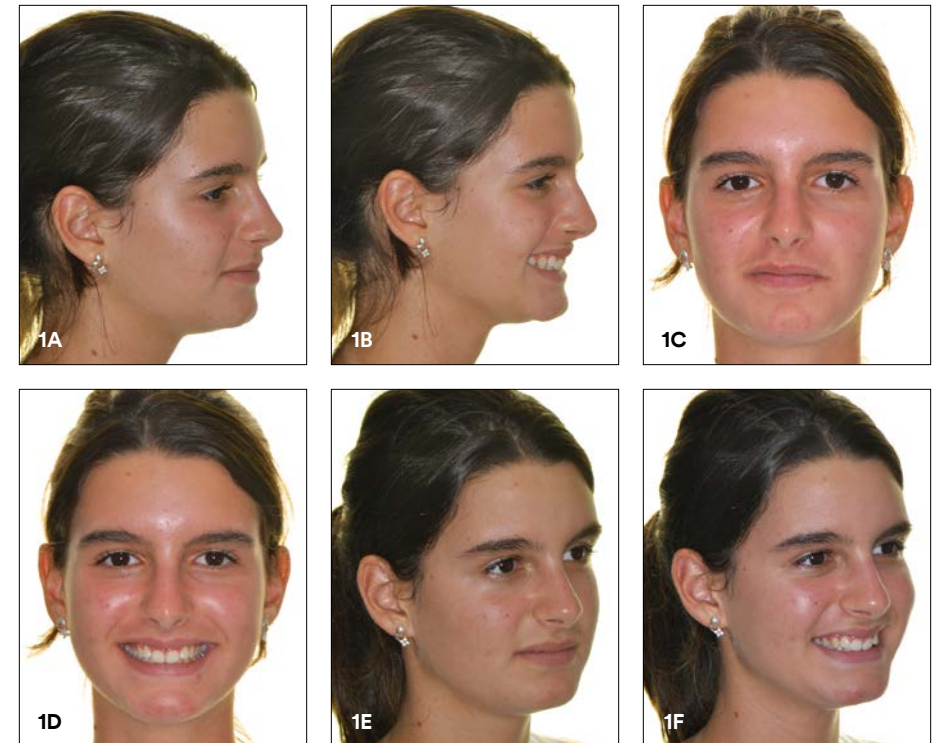


Figure 1A-F: Initial facial analysis.



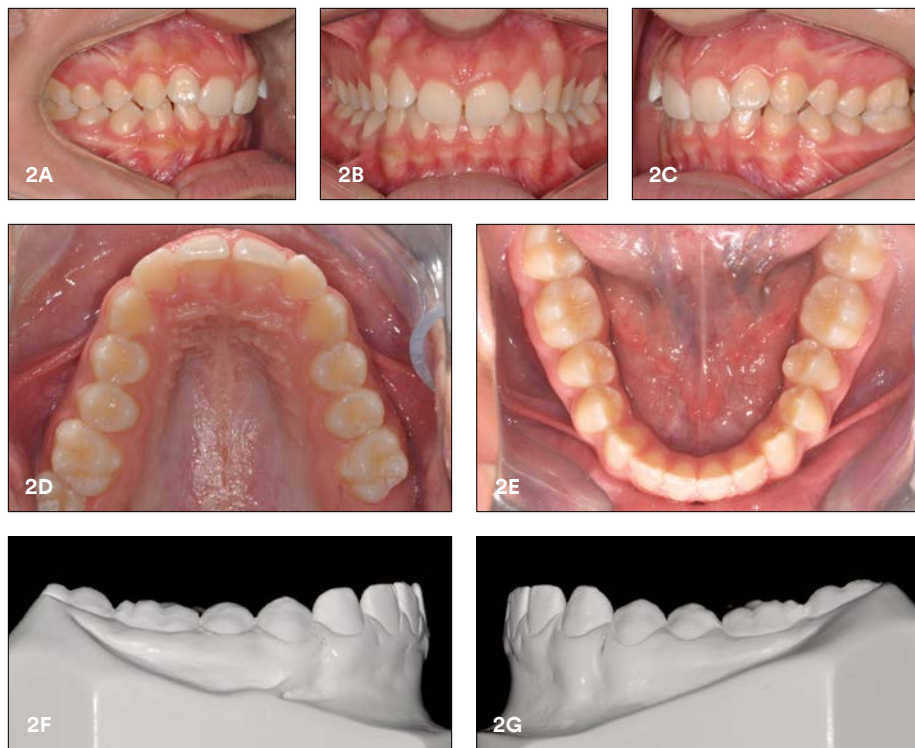


Figure 2A-G: Initial dental analysis.

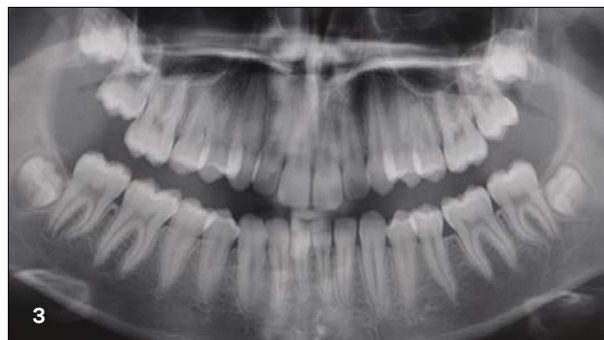

Figure 3: Initial panoramic X-ray.

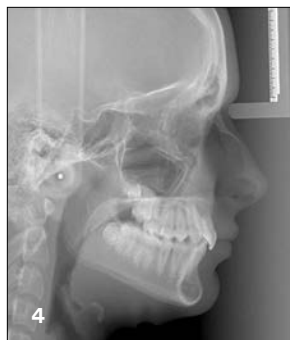

Figure 4: Initial cephalometric X-ray.

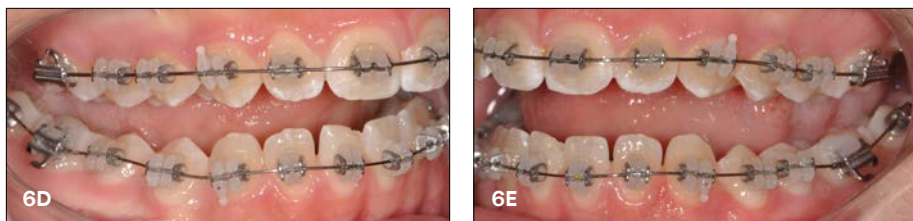
Cephalometric Analysis			
	Norm	Initial	Final
<b>Maxilla to Cranial Base</b>			
SNA (°)	82.0	82.1	81.5
<b>Mandible to Cranial Base</b>			
SNB (°)	80.0	80.2	80.0
SN – GoGn (°)	32.0	26.4	27.5
FMA (MP-FH) (°)	25.0	20.0	21.0
<b>Maxillo-Mandibular</b>			
ANB (°)	2.0	1.9	1.5
<b>Maxillary Dentition</b>			
U1 – NA (mm)	4.0	2.8	3.2
U1 – SN (°)	103.0	98.0	103.7
<b>Mandibular Dentition</b>			
L1 – NB (mm)	4.0	2.1	3.9
L1 – GoGn (°)	93.0	95.6	102.3
<b>Soft Tissue</b>			
Lower Lip to E-Plane (mm)	-2.0	-2.7	-2.8
Upper Lip to E-Plane (mm)	-4.0	-4.7	-5.3

Table 1: Cephalometric analysis.

## Treatment Progress

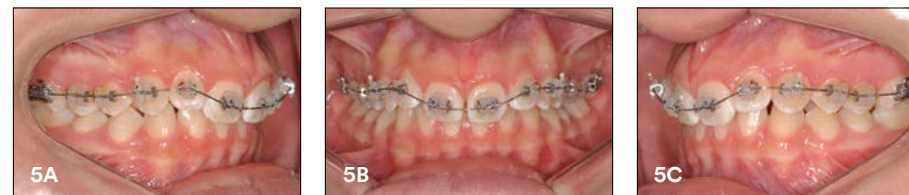
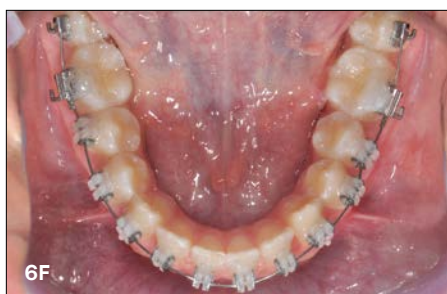
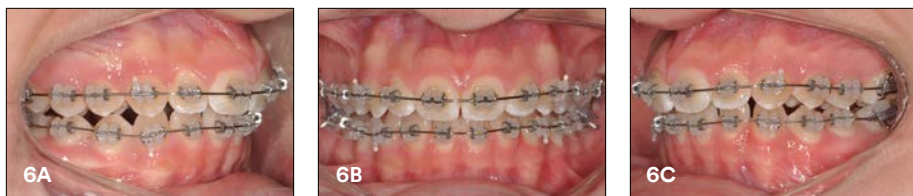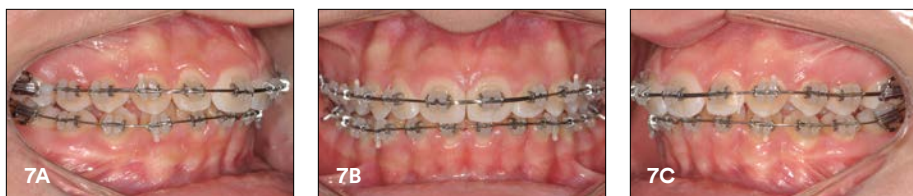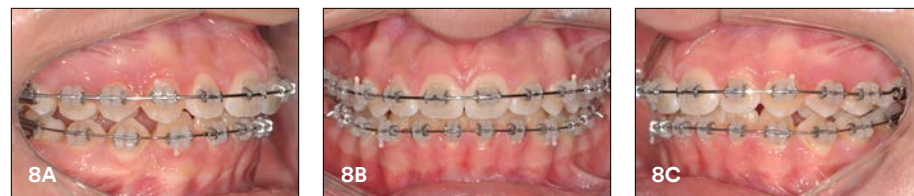Figure 5A-C: Upper arch – .014" SE.



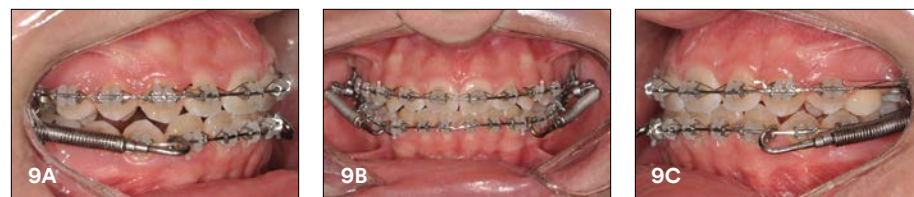**Figure 6A-F:** Upper arch – .016" SE; lower arch – .014" SE.



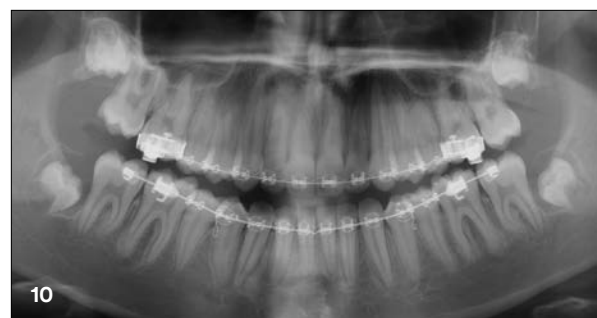**Figure 7A-C:** Upper arch – .014" and .016" SE; lower arch – .016" SE.



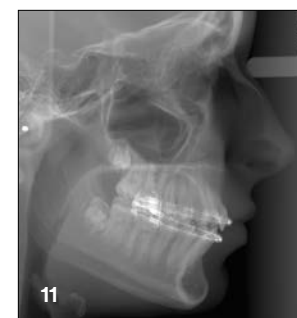**Figure 8A-C:** Upper arch – .017"x.025"; lower arch – .018" SE.



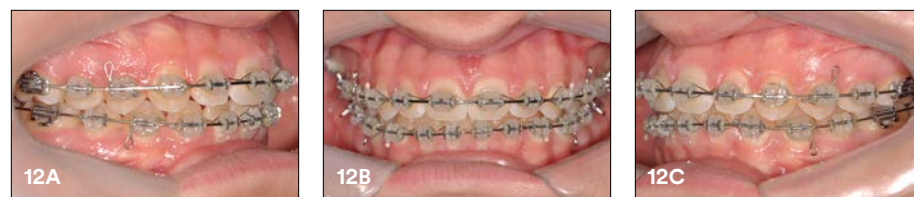
**Figure 9A-C:** Forsus™ Appliance.



**Figure 10:** Panoramic X-ray after Forsus™ Appliance.



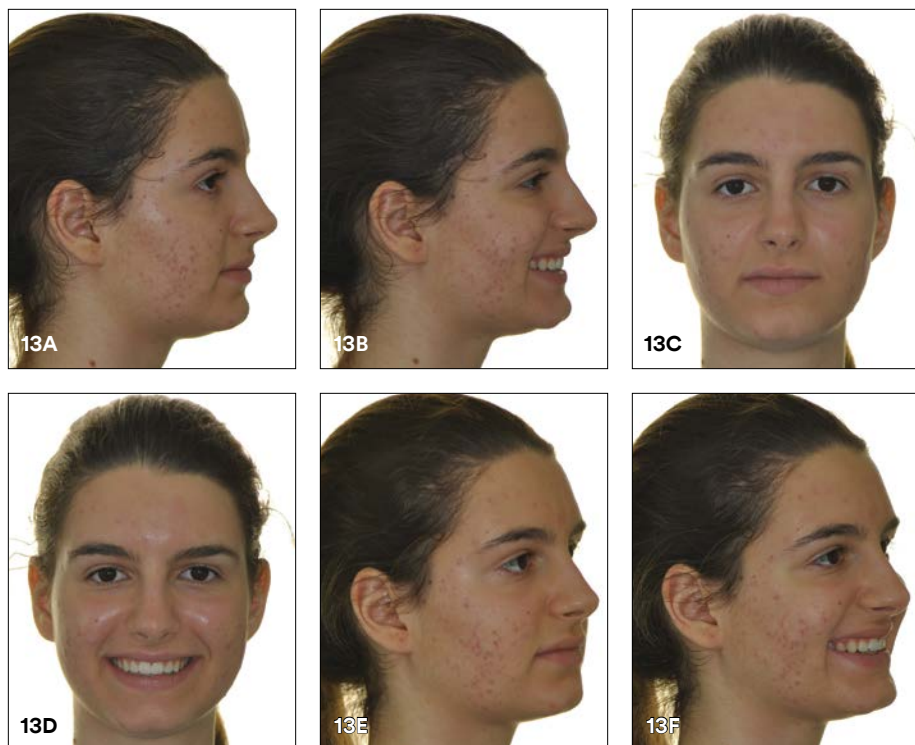**Figure 11:** Cephalometric X-ray after Forsus™ Appliance.



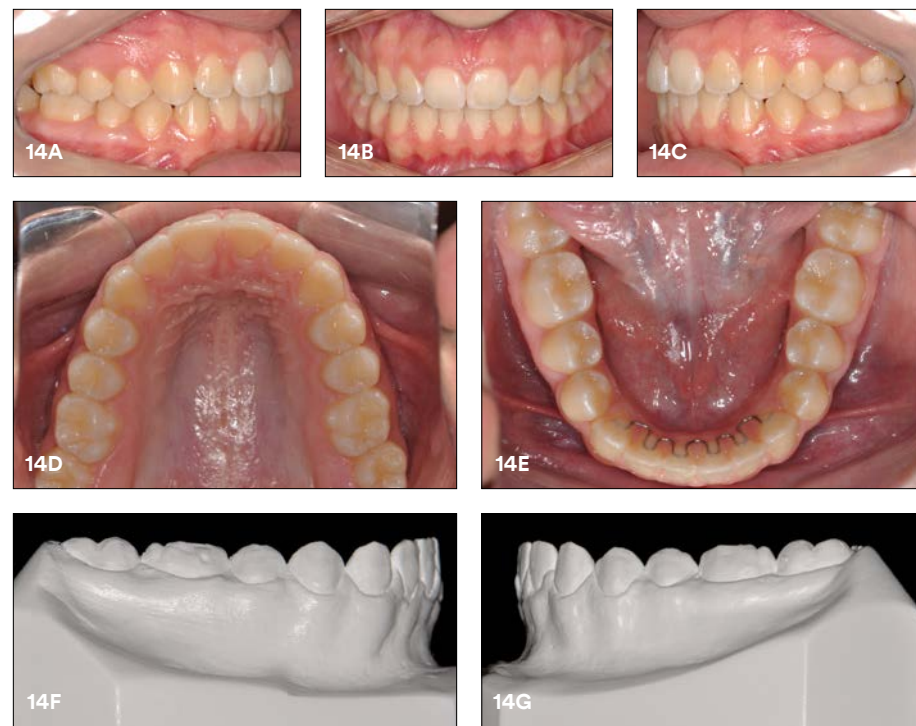
**Figure 12A-C:** Releveling after brackets repositioning.



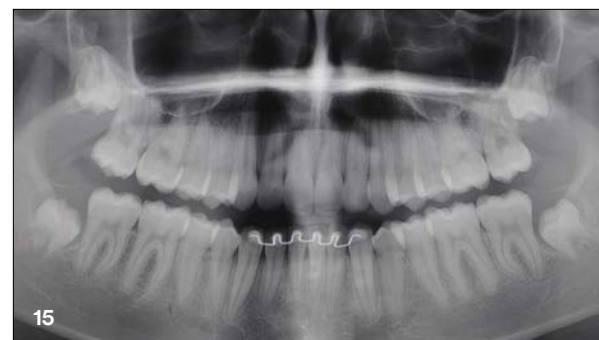## Final Records



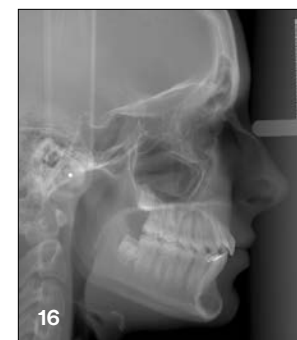**Figure 13A-F:** Final facial analysis.



**Figure 14A-G:** Final dental analysis.



**Figure 15:** Final panoramic X-ray.



**Figure 16:** Final cephalometric X-ray.

### Doctor's Notes


1. Lower brackets and tubes were bonded in the third month of treatment after an initial alignment of upper incisors. Buildups in first lower molar were planned to prevent upper teeth enamel wear and lower brackets failure.
2. First lower molars buildups were removed progressively during treatment allowing extrusion of these teeth during lower curve of Spee leveling.
3. SE denotes NiTi Super Elastic wire and SS denotes stainless steel wire.
4. This case was treated with Forsus Correctors, adapted to bands on first upper molars. Currently, it is recommended to use the Forsus™ Wire Mount that requires no bands.
5. Forsus Correctors were adapted to lower canine's brackets objecting a more horizontal vector during Class II correction due patient's horizontal skeletal pattern. Adapting Forsus Correctors on first premolar's bracket could produce a more vertical vector tending to intrude upper first molar that was not a desirable effect in this case.
6. The effects of Class II treatment with Forsus Correctors were in accordance to the reported in previous studies, including distal movement of upper molars, mesial movement of lower molars and proclination of lower incisor. No skeletal effect was observed.
7. After Forsus Appliance correction, nocturnal Class II elastic were applied (1/4 in./8 oz.). During finishing some brackets were repositioned to improve occlusal relationship.
8. MBT System incisors torque prescription ( $U1=17^\circ$ ;  $U2=10^\circ$ ;  $L1$  and  $L2=-6^\circ$ ) allowed an excellent torque control of these teeth especially in the lower arch. Proclination of lower incisors was well controlled despite the effects of the Forsus Corrector therapy and Curve of Spee leveling.

*Case photos provided by Dr. Ricardo Moresca*



## 3M<sup>SM</sup> Health Care Academy

# An orthodontic system optimal for passive self-ligating brackets – “JETsystem.”



**Dr. Shinichi Narita**

Dr. Shinichi Narita graduated from the Tokyo Medical and Dental University in 1991, and received his Doctor Degree in Orthodontics in 1998. He started his private practice, the Jiyugaoka Orthodontic Clinic, in 1999. He is a Fellow of the World Federation of Orthodontists, a Certified Doctor by the Japanese Orthodontic Society, and a Member of the American Association of Orthodontists, the Japanese Society for Jaw Deformity, the Japanese Academy of Facial Studies, and the Tokyo Orthodontic Society. Dr. Narita is the President of the JETsystem Study Group.

### Introduction

Since an encounter with a patient in 2006, I have been engaged in development of a system realizing marked reduction in duration of orthodontic treatment. Because I had doubts about the necessity of leveling, I expected that canine distal movement achieved at an early stage of orthodontic treatment would lead to reduction in treatment duration.

Performing canine distal movement at the beginning of the treatment process requires passive self-ligating brackets (PSL brackets) in place of conventional ligating brackets. When a 0.014-inch Heat Activated NiTi archwire is used as the main archwire on placement of conventional ligating brackets, the frictional force generated by ligation (approximately 100 gf) hinders proper movement of teeth. To enable canine distal movement immediately after placement of the orthodontic appliance, combined use of PSL brackets and superelastic NiTi closed coils yielding a frictional force not greater than 50 gf is needed.

In recent years, many articles investigating the difference in treatment duration between PSL brackets and conventional ligating brackets have been published in the *American Journal of Orthodontics and Dentofacial Orthopedics* (AJO-DO), and the majority of these articles concluded that no statistically significant difference in treatment duration was observed between these two brackets. However, it should be noted that these results do not mean there is no clinical difference between use of PSL brackets and conventional ligating brackets.

As we carefully read articles reporting no difference in treatment duration between these two brackets, we noted that such articles did not describe the treatment procedures in detail and contained a brief statement that the treatment was performed "according to the conventional procedures." An orthodontic treatment system used according to the conventional procedures cannot make full use of the strength of PSL brackets. I believed that the development of a treatment system that enables canine distal movement at the beginning of orthodontic treatment would be the key to successful reduction in treatment duration, and started investigation of such a system ... the JETsystem.

### JETsystem – a treatment system optimal for PSL brackets

As of June 2016, the current JETsystem has the following 20 features. These 20 features represent theoretical backgrounds of this system. It is not too much to say that the first 10 points of pre-treatment preparation are the key determinants of successful treatment. Not exclusive to orthodontic treatment, the importance of adequate preparation in advance has been emphasized by the old saying "Perfection is eighty percent planning and twenty percent working." Without prior preparation anticipating the treatment goal, as well as the routine examination/diagnosis, no excellent treatment result can be obtained. However, the most important point is the decision to "finish within one year" with planning backward from the goal, and then think and do what should be done now.

#### 1. Measurement in advance – No measurement, No KAIZEN

In general, the term "pre-treatment measurement" may be used to mean measurement of dental models or cephalometric analysis. Those measurements are necessary but inadequate. Producing an ideal setup representing post-treatment to measure teeth movement, the balance of the dental arch width, and the condition of post-treatment occlusion is to improve the precision of orthodontic treatment. At present, we measure plaster models and make an ideal setup from divided plaster teeth, but I believe that all such measurement processes will be digitalized in the near future. Instead of manual impression-taking with alginate or silicone material, every dental chair will be equipped with an optical scanner.

#### 2. Passive self-ligating brackets

Many orthodontists still misunderstand an orthodontic treatment system using PSL brackets. Several years ago, many articles addressing the difference in treatment duration between PSL brackets and conventional ligating brackets were published in AJO-DO, and the majority of these articles reported that no statistically significant difference in treatment duration was observed between these two brackets. Such articles did not describe the treatment procedures in detail and contained a brief statement that the treatment was performed according to the conventional procedures.

The result of orthodontic treatment may vary depending on the treatment system used. Brackets, wires, chains, and coils used for orthodontic treatment may be considered as parts of a personal computer. The performance of the computer may be changed by upgrading the system. A recent well-known example is an upgrade from Windows® 7 to Windows 8. According to many newspaper articles, a considerable number of users who had once upgraded to Windows 8 soon downgraded to Windows 7 and are currently using Windows 7. Observing that first-

hand personal computer systems using Windows 7 are still commercially available, even after the launch of Windows 10, the key importance of operating system in performance of a computer system may well be recognized. Thus, the difference in operating system changes the performance of a computer system even if the specifications of hardware components remain unchanged.

Conversely, if the operating system fails to fully utilize the difference in hardware components, there is a considerable possibility of little change in overall performance of the computer system. So much for allegory. In conclusion, a conventional system for orthodontic treatment cannot fully utilize the potential ability of PSL brackets, which results in little difference in treatment duration. If the treatment difference in PSL brackets and conventional brackets are tested with JETsystem, I believe there must be a significant difference in duration of orthodontic treatment between the two brackets. However, there is a substantial problem with this comparison: conventional brackets are apparently inferior to PSL brackets in treatment outcome. In such situation, there are ethical issues associated with clinical trials comparing PSL brackets with conventional brackets in JETsystem. While some university professors insist the importance of randomized controlled trials (RCTs), the essential prerequisite for starting such studies is clinical equipoise of the systems to be compared and this is why PSL brackets and conventional brackets used in JETsystem cannot be compared in RCTs.

Self-ligating brackets (SL brackets) were originally developed to save chair time, namely to reduce the time for ligation. Some types of SL brackets, however, enabled tooth movement by application of a force lower than ever (several dozens of gf). At present, Damon brackets are likely to be regarded as representative PSL brackets. I myself used Damon brackets about 10 years ago. However, I do not use them at present because they have several critical defects. First, because of its high profile, it is difficult to achieve torque control with Damon brackets. The greater the distance between wire and tooth surface, the more difficult to express the brackets pre-adjusted torque.

Furthermore, since the bracket width is not proportional to the tooth width, use of Damon brackets may be associated with problems in rotation control of maxillary anterior teeth. The last issue of Damon brackets is that only 0.022-inch brackets are available. Clarity™ SL Self-Ligating Brackets are devised to overcome the three defects described above. Although associated with some trouble in wire engagement and disengagement until getting used to it, Clarity SL brackets are PSL brackets that are low-profile, individually designed to have a bracket width proportional to the tooth crown width, and available for both 0.018- and 0.022-inch slots.

### 3. Bi-dimensional slots

For space closure utilizing the sliding mechanics, the friction force applied to brackets placed in the molar region should be desirably low. However, when using an archwire with a larger size such as a working wire (0.017×0.022 inch), as the friction becomes larger, then smooth space closure cannot be executed. On the other hand, using a smaller size archwire, the torque is lost in the anterior region and lingual inclination occurs. Is it feasible to meet these two apparently contradictory requirements at one time, providing sufficient torque in the anterior region and reducing the friction in the molar region to close the extraction space through application of a reduced force (less than 100 gf)?

The possible solution may be either to use brackets with the same slot size and wires with different sizes between anterior and posterior regions or to use both wires with brackets that have different slot sizes between anterior and posterior. At the beginning, the former approach was applied for JETsystem. However, since options for wires were limited and treatment outcome was unsatisfactory, the latter approach has been adopted since 2011. This latter approach is far superior to the former approach, because use of brackets with varying slot size in the anterior and posterior allows a wide selection of wires with many sizes made of different materials.

### 4. Bracket selection

To minimize the friction as much as possible, wires should preferably not be bent. That is, wires should preferably remain straight during tooth movement. This is the so-called "Straight-Wire" technique. However, elaborate wire bends may be generally produced during tooth movement in actual clinical practice. In principle, JETsystem uses NiTi wires until the extraction space is closed, without adding any bend. For this purpose, based on prior consideration of the necessary amount of torque applied to each bracket, the most appropriate bracket should be selected from products with varying torque designed for a particular site. In addition, considering the amount of pre- to post-operative change in tooth axis as well as tooth movement distance, brackets for anterior maxillary teeth are selected from high-torque or low-torque prescription. Brackets for lower anterior teeth with the same -6° torque are placed upside down as necessary in some cases involving tooth extraction to prevent excessive lingual inclination.

### 5. Ideal setup

To define the treatment goal accurately, preparation of an ideal setup model is essential. Preparation of an ideal setup model has two objectives: one is to examine the outlines of tooth movement distance for individual teeth and appropriateness of treatment plan; the other is to ensure accurate positioning. For this purpose, a setup model is prepared exactly according to the final treatment goal by ideally positioning individual teeth without any overcorrection in torque and other parameters.

Overcorrection, if any, is incorporated in brackets to ensure standardization of treatment. Incorporating overcorrection in a setup model hinders appropriate torque setting, thereby making treatment even more difficult.

### 6. Straight wire positioning

In the early 1970s, SWA was developed by Dr. Lawrence F. Andrews and, as is well known, most of the current conventional methods are modifications of SWA in nature. An important dogma in orthodontic treatment applying SWA is the concept of facial axis (FA) points as the reference points for placement of brackets. However, when brackets are actually placed on FA points, cuspids are slightly shifted to the lingual side, requiring wire bends to engage into the wire slots even if SWA is used. To avoid this, a Clarity SL bracket for the upper and lower lateral incisor is positioned not exactly on but somewhat mesially to the FA point, while a Clarity SL bracket for the cuspid are positioned so that its distal wing is exactly on the FA point. Such positioning of brackets ensures straight-wire treatment without wire bends and enables space closure with NiTi wires.

### 7. Just-fit bite turbo

In orthodontic treatment, resolving issues related to vertical occlusion is important. Particularly in cases of deep bite involving tooth extraction, smooth closure of extraction space requires substantial effort. Establishing an appropriate vertical dimension of occlusion solely by wire adjustment is difficult even for experienced orthodontists. Use of a bite turbo is a method for anterior bite raising. A bite turbo is a metal or resin block placed on the lingual side of maxillary anterior teeth to get in contact with and intrude anterior mandibular teeth. Although an optimal vertical dimension of occlusion cannot be established by this method alone, the solution of this issue is to prepare an ideal setup model. Using the resulting ideal setup model, a bite turbo with an ideal height was prepared for maxillary anterior teeth and placement of this bite turbo at a relatively early stage of treatment enabled smooth closure of extraction space.

### 8. Indirect bonding

At present, there is no method for accurate intraoral placement of brackets positioned on an ideal setup model other than indirect bonding. Although some tools for bonding of brackets digitally set up may be developed in the near future, the conventional technique is more accurate at present. While a wide variety of indirect trays are currently available, those made of materials easy to process and capable of consistent application are preferable. I currently use silicone trays with their occlusal surface reinforced with resin for molars and individual resin trays for other teeth.

### 9. Simultaneous tooth extraction

It goes without saying that enhanced metabolism is required for efficient tooth movement. In cases involving tooth extraction, tooth movement starts immediately after tooth extraction to utilize metabolic activity in the extraction socket. This is based on a mechanism similar to stimulation of tooth movement by corticotomy.

Following tooth extraction, the conventional orthodontic treatment system requires several months till initiation of canine distal movement and about half a year for the initial step of leveling. This means that canine movement and anterior retraction are initiated after extraction socket remodeling is completed. In JETsystem, aiming at completion of movement of most teeth before completion of extraction socket remodeling, all teeth to be extracted for orthodontic treatment (except for impacted 3rd molar teeth) are extracted in one day and the orthodontic appliance is placed on the following day to initiate aggressive canine distal movement at this time point.

### 10. Oral myofunctional therapy (MFT)

One issue I recognized after introducing orthodontic treatment by JETsystem into my clinical practice was that abnormalities in oral muscle function caused stagnation of treatment and delayed space closure of the extraction socket. Since JETsystem utilizes minute force, tongue thrust on swallowing and pronunciation as well as weak lip closing pressure have greater effects on treatment outcome of JETsystem compared with that of conventional procedure. Stagnated space closure and failed stabilization of occlusion at the final step lead to delay in removal of the orthodontic appliance. Oral myofunctional therapy (MFT) is essential for smooth progress of treatment.

### 11. Measurement at every office visit

Once orthodontic treatment is initiated, detailed measurements to monitor the progression of tooth movement are seldom performed in general. While I expect that, in the future, intraoral scanning will be performed at every office visit to allow comparison with the data obtained at the last visit and prediction of time to achieve the treatment goal, there is currently no choice but to follow the conventional procedures. For patients currently on orthodontic treatment by JETsystem, the following are performed at every office visit: intraoral photographs, measurement of extraction socket, use of NiTi closed coils instead of elastometric chains to provide stable and continuous orthodontic force, and measurement of traction force applied to each intermaxillary elastic with a spring scale. These measurements enable better and more accurate understanding of treatment progress and provide information for decision-making regarding force system change, for example.

### 12. Stimulation of metabolism

It goes without saying that enhanced metabolism is essential for efficient tooth movement.

#### Aerobic exercise

I recommend aerobic exercise three times a week to college students and adults. Since tooth movement results from bone metabolism, smooth bone metabolism is imperative. To assure smooth bone metabolism, I believe that enhancement of systemic metabolism is important. I do not recommend aerobic exercise to junior and senior high school students, because their metabolic activity is high.

#### Sleep

During sleep, the parasympathetic nerve system is dominant in the autonomic nervous system and stimulates bone metabolism. Accordingly, in orthodontic treatment in adults, I instruct my patients to have appropriate sleeping hours.

### 13. Canine first

The greatest difference between conventional orthodontic treatment and JETsystem is *aggressive canine movement immediately starting from the time of placement of the orthodontic appliance*. This concept applies to all cases, regardless of need for tooth extraction.

In the conventional orthodontic treatment system, canine distal movement starts after wires of larger size are inserted following completion of leveling. In the JETsystem, in contrast, canine distal movement is initiated using 0.014-inch Heat Activated NiTi wires as initial wires. This treatment strategy is achieved by using PSL brackets. When conventional ligating brackets are used, a ligation force of approximately 100 gf is applied and an even greater force needs to be applied to accomplish canine distal movement. A textbook written by William R. Proffit states that 200 gf is required. If such a force were applied from the initial stage using 0.014-inch Heat Activated NiTi wires as main wires, the results would be obviously ineffective. Use of PSL brackets enables canine distal movement at an orthodontic force as small as 50 gf. It should be noted that the activity of the extraction socket is maintained only for three months. Achieving canine movement as much as possible while the extraction socket is still active is the key to successful reduction of overall treatment duration. The new concept "Canine first" enables reduction in duration of orthodontic treatment that has been impossible with conventional procedures.



### 14. Anchor screws

Traditionally, the technique used for anchorage had been thought to determine the outcome of orthodontic treatment. However, the advent of anchor screws as absolute means of anchorage greatly changed the clinical practice of orthodontics. In modern orthodontic treatment, anchor screws have been used in many systems including JETsystem. In addition, anchor screws achieved tooth movement in ways previously thought to be impossible and allowed to design three-dimensional tooth movement.

### 15. Variable treatment interval

To determine the optimal appointment interval is another key point in reducing total treatment duration. Since crowding is prevalent among Asians including Japanese, shorter appointment intervals facilitate smooth treatment progress at the initial stage. In cases involving tooth extraction, office visits during the first 2-3 months until engagement of working wires are scheduled at two-week intervals for wire change and bracket replacement. Even if no manipulation is necessary, MFT is preformed at every appointment. Once engagement of working wires is completed, appointments at 1-month intervals are sufficient. In the late stage of treatment involving use of robot-bended archwire, appointments are scheduled at two-week intervals again during the final adjustment period for 2-3 months.

### 16. Light-side force

In my opinion, there is "good" orthodontic force and "bad" orthodontic force. In JETsystem, orthodontic force causing adverse effects on periodontal tissue, inducing excessive tooth inclination and torsion or gingival recession, or root resorption is termed as "bad" force (Dark-side force), while orthodontic force facilitating efficient and painless tooth movement with normal physiological conditions maintained is termed "good" force (Light-side force).

Most orthodontists not familiar with JETsystem may be concerned about torque and distal inclination of cuspids presumably due to involvement of the unique bracket position (straight-wire positioning) mentioned above. In addition, such concern appears to be further amplified by nickel-titanium wires (NiTi wires) basically used throughout the treatment process. Based on the results of experiments on ligation force conducted in 2005 (60-83 gf), I use .017x.022 wires as main wires in actual clinical practice. In addition, inspired by Professor Gakuji Ito of Kagoshima University on the occasion of a previous graduate school lecture, that "tooth movement can occur even at an orthodontic force as small as 10 gf," I use superelastic NiTi closed coils (25 gf) for distal movement of cuspids in junior high school students, and use of PSL brackets is essential for tooth movement at such a small orthodontic force. At an orthodontic force of around 25 gf, excessive inclination and torque are prevented by restoring force. May the force be with you.

### 17. Friction control

Friction control means adjustment of frictional force during tooth movement, reducing it to almost zero to facilitate tooth movement and sometimes increasing it to inhibit tooth movement. The purpose of using PSL brackets is to reduce frictional force to almost zero and thereby enable friction control. The conventional orthodontic treatment system bears contradiction in that it fixes brackets and archwires with frictional force generated by ligation and simultaneously attempts to separate them by application of even greater orthodontic force. As a consequence, distal inclination and rotation occur. JETsystem aims at minimizing such unnecessary frictional force to near zero before space closure is completed. For example, a coil is ligated to the lower part of each bracket. To reduce normal force, no excessive reverse curves or 1st- 2nd- and 3rd-order bends were introduced in .017x.022 wires used as the main wires. Furthermore, frictional force is increased to inhibit tooth movement after space closure is completed.

### 18. Initial movement

#### 1) Initial elastic (intermaxillary elastic)

Use of intermaxillary elastics immediately after placement of the orthodontic appliance is termed "initial elastic." When I used the "initial elastic" strategy for the first time in early 2008, I was so worried about treatment failure that I scheduled the next appointment of a patient 10 days after the first visit. Every orthodontist has likely experienced fear upon application of intermaxillary elastics with Niti round wires. The greatest difference in the use of intermaxillary elastics between conventional methods and JETsystem is the strength of force applied. Conventionally, force exceeding the ligation force (around 100 gf) was generally applied to intermaxillary elastics and an authoritative textbook, *Contemporary Orthodontics* by William R. Proffit, states that 250 gf is applied. Based on the "Light-side force" concept, 50 gf is applied in JETsystem.

#### 2) Initial coil spring (NiTi closed coil spring)

Recognizing the importance of early approach to extraction socket, I developed a new approach called "initial coil spring" involving canine distal movement initiated immediately after placement of the orthodontic appliance using NiTi closed coil springs. Although tooth movement during the first month after placement of the orthodontic appliance is not so significant because of time-consuming remodeling of alveolar septum, subsequent movement achieved at 2-3 months after placement is remarkable. For junior and senior high school students, 25 gf and 50 gf are applied for canine distal movement and anterior retraction, respectively. For college students and adults, 50 gf and 100 gf are applied for canine distal movement and anterior retraction, respectively.

### 19. Leverage torque control

Leverage torque control is a technique for controlling anterior torque using hooks. Anterior torque is controlled by selection of hook length. This technique has theoretical rationales and exhibits remarkable effects if an optimal wire size is selected. Anterior brackets with .018-inch slot allows early initiation of torque control. Anterior retraction with hooks usually results in lingual inclination of retracted teeth. This is a phenomenon associated with use of shorter hooks. In contrast, use of longer (8 mm) hooks in combination with wires of almost full size enables anterior retraction with slight labial inclination. This is a useful method realizing anterior torque control without application of torque to wires.

### 20. Zero-step method

The Zero-step method is a concept that treatment processes conventionally divided into multiple steps and sequentially conducted are all conducted in parallel as if there were no discrete steps. Based on an idea that an orthodontic treatment system may be analogous to process management in manufacturing industry, I have learned project management from "The Goal: A Process of Ongoing Improvement" and have been investigating how to achieve total optimization.

Although conventional clinical practice in orthodontics has addressed a reduction in chair time at each appointment, this is nothing but the pursuit of sub-optimization and does not necessarily have a beneficial effect on the overall treatment outcome. The JETsystem aims at optimization (minimization) of overall treatment by process management.

### Conclusion

This article has introduced JETsystem, a method for orthodontic treatment taking advantage of PSL brackets. JETsystem does not inhibit bloodstream, utilizes orthodontic force causing minimal pain (Light-side force), reduces frictional force, corrects balance of perioral muscle, takes full advantage of in vivo metabolic activity, and is constructed considering features and characteristics of various materials.

As a consequence, this system has reduced treatment-related pain and treatment duration. Hereafter, I would like to continue further KAIZEN, aiming at reducing the duration of dynamic orthodontic treatment involving tooth extraction in junior and senior high school students to 6-9 months and see more smiles of my patients.

**Case 1:**  
Class I, crowding, maxillary and mandibular right and left 1<sup>st</sup> bicuspids extracted

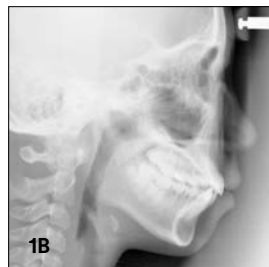
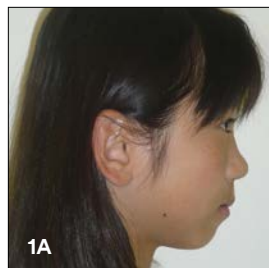
Figure 1A-B: Case 1 initial.

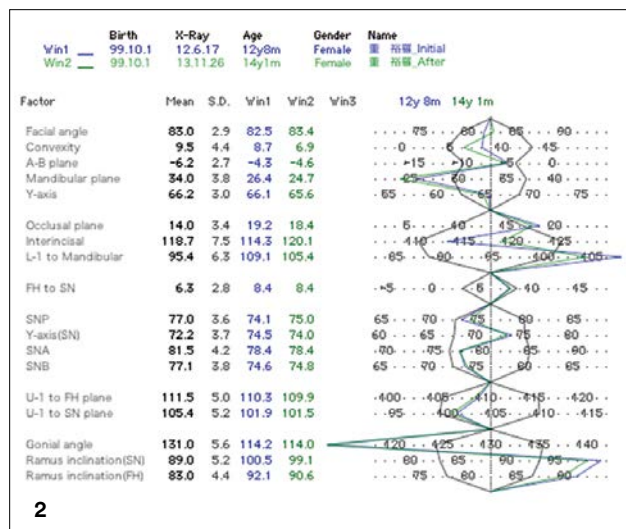


Figure 2: Case 1 cephalometric diagnosis.

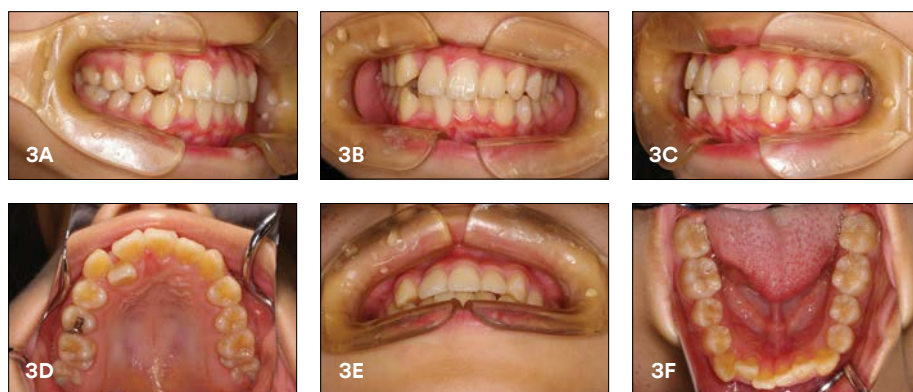


Figure 3A-F: Case 1 initial.

**Pre-treatment**

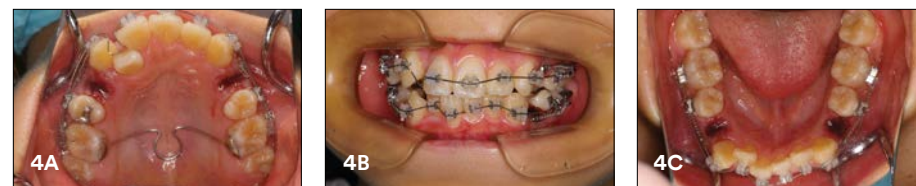

Figure 4A-C

**Two months**

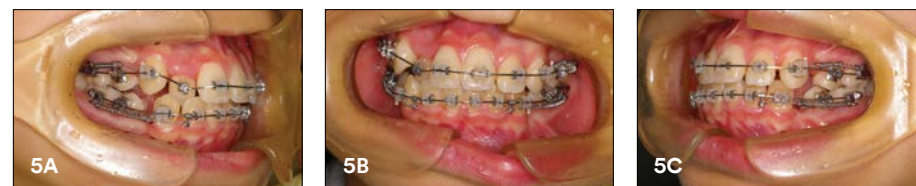

Figure 5A-C

**Four months**

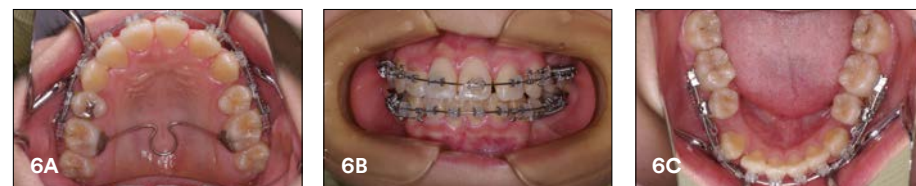

Figure 6A-C

**Six months**

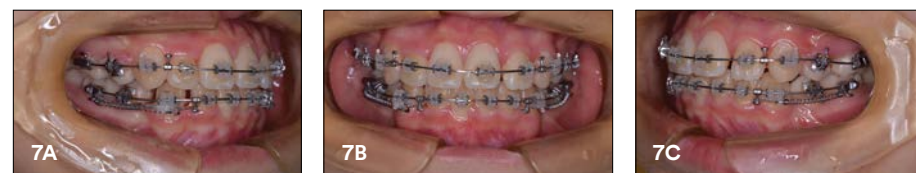

Figure 7A-C

**Ten months**

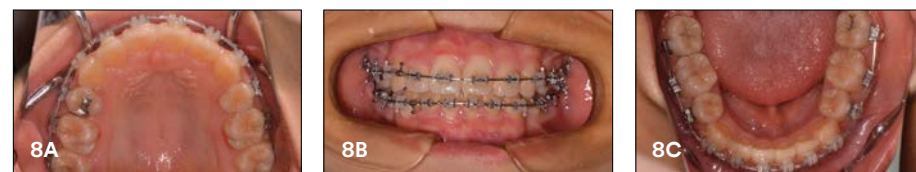

Figure 8A-C



### Post-treatment at 14 months

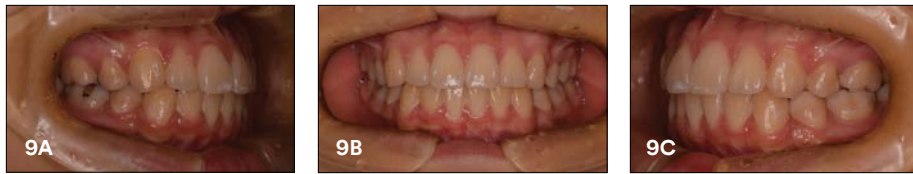

Figure 9A-C

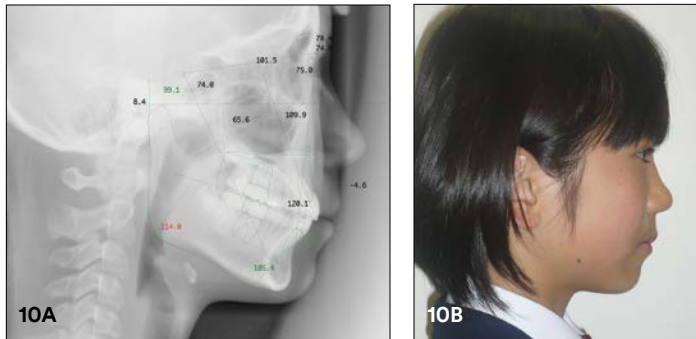


Figure 10A-B: Case 1 post-treatment.

### Retention after 24 months

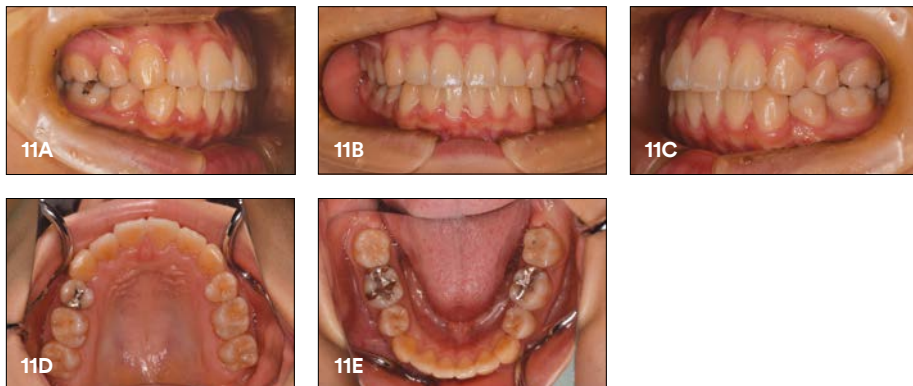


Figure 11A-E

### Case 1 Narrative:

A 12-year, 8-month-old female patient presented with a concern about high canines. Her facial appearance was symmetric and her facial type was of Convex type. A slight tension was noted in the mentalis muscle. Angle Class I malocclusion was observed with overjet of 2.5 mm and overbite of 2.5 mm. The maxillary and mandibular arch length discrepancies were -8 mm and -8 mm, respectively. Lingual transposition of the maxillary right lateral incisor and mandibular anterior crowding were noted. Tooth formation of maxillary and mandibular right and left 3rd molars were observed and there was no abnormality in tooth number. Initial cephalometric analysis in the lateral view revealed the following measurements: SNA, 78.4°; SNB, 74.6°; ANB, 3.8°; FMA, 26.4°; FMIA, 44.5°; U1-FH, 110.3°; and Interincisal angle, 114.3°.

Based on these findings, a diagnosis of Angle Class I with crowding was established. Orthodontic treatment by JETsystem using passive self-ligating (PSL) brackets (Clarity™ SL and SmartClip™ Self-Ligating Brackets) of varying slot size, .018-inch slot for anterior brackets (3-3) and .022-inch slot for posterior brackets, was planned to improve lingual transposition of the maxillary lateral incisor and mandibular anterior crowding. For resolution of crowding and improvement of lip protrusion, maxillary and mandibular right and left 1st bicuspid were all extracted on the day prior to the date of placement of the orthodontic appliance.

Brackets were positioned on a plaster model in advance (straight-wire positioning) and then bonded using an indirect tray. For reinforced anchorage, a trans-palatal arch was bonded between the maxillary right and left 1st molars. Maxillary and mandibular right and left canine distal movement was initiated immediately after placement of brackets using 25 gf NiTi closed coils. In addition, application of 3/8-inch intermaxillary elastics between the maxillary canine and mandibular 1st molar was initiated to achieve tight occlusion. Almost complete resolution of crowding was achieved in 4 months after placement of brackets, indicating that active canine movement was almost completed. At this point, maxillary and mandibular anterior retraction was initiated using 50 gf NiTi closed coils. The extraction space was closed 10 months after placement of brackets, and brackets were placed on the 2nd molars.

Although torque control of the maxillary right lateral incisor took time, the total duration of treatment was 14 months. Both upper and lower lips recessed and her facial profile was improved. Postoperative panoramic radiograph identified no apparent root resorption and no problem with root parallelism. Postoperative cephalometric analysis in the lateral view demonstrated changes in FMIA (44.5° to 49.9°) and Interincisal angle (114.3° to 120.1°) that contributed to improvement of the patient's facial profile.



## Case 2: Class II Division 1, maxillary right and left 1<sup>st</sup> bicuspids extracted

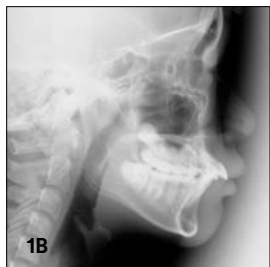
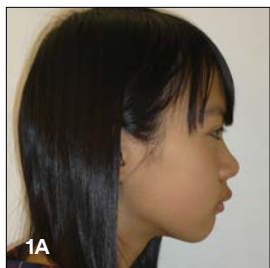

Figure 1A-B: Case 2 initial.

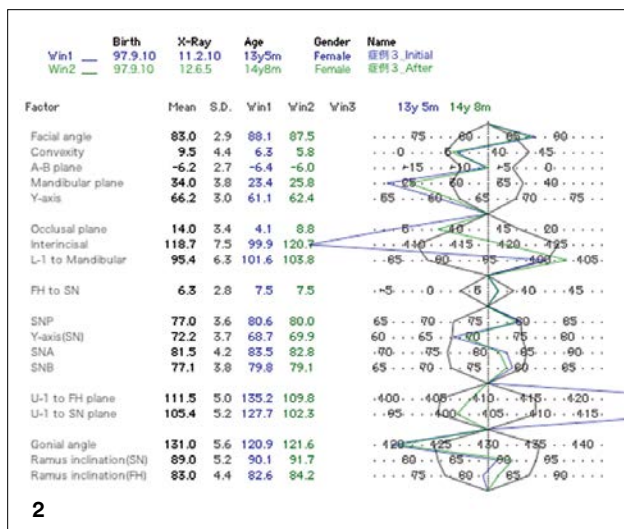


Figure 2: Case 2 cephalometric diagnosis.

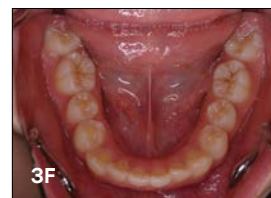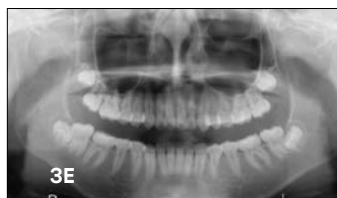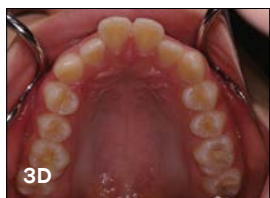


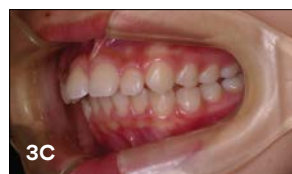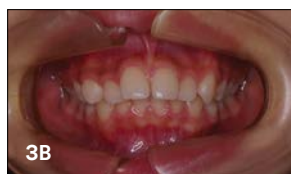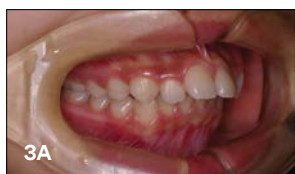Figure 3A-F: Case 2 initial.

### Pre-treatment

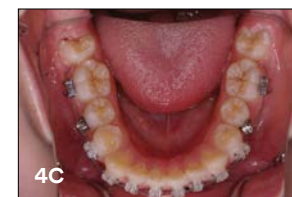
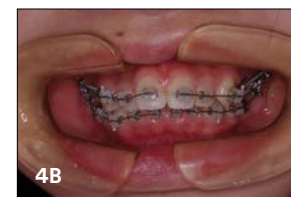
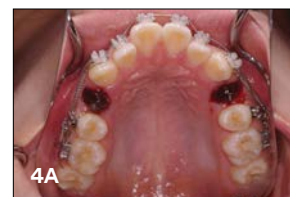Figure 4A-C

### Two months

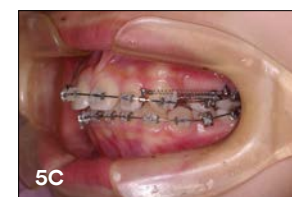
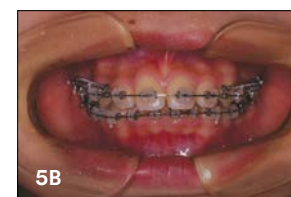
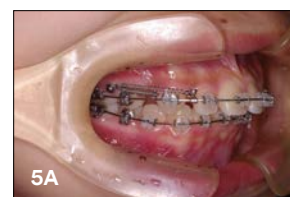

Figure 5A-C

### Four months

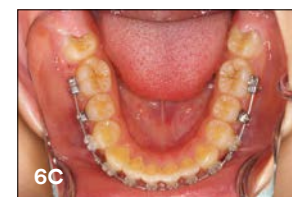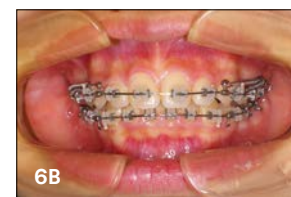

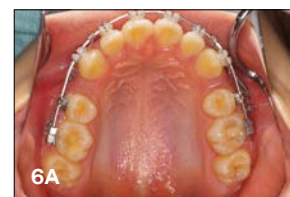
Figure 6A-C

### Six months

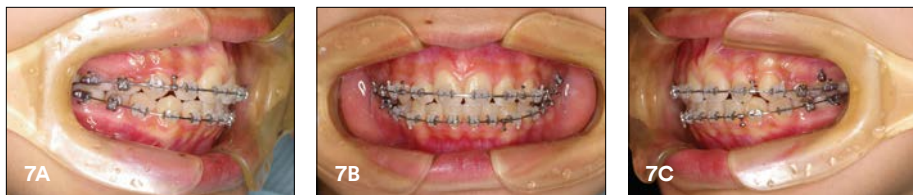

Figure 7A-C

### Ten months

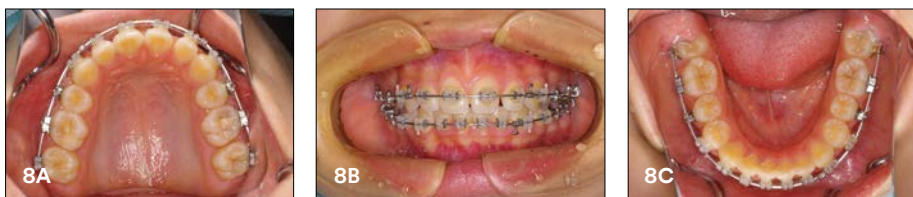

Figure 8A-C

### Post-treatment at 14 months

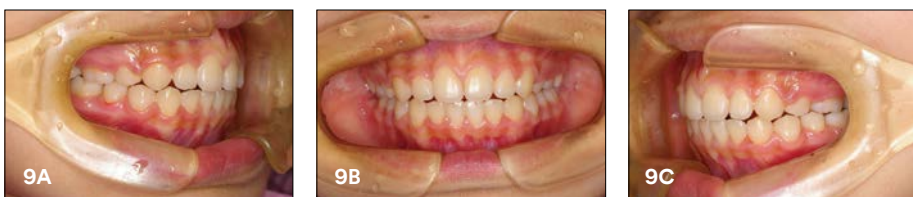

Figure 9A-C

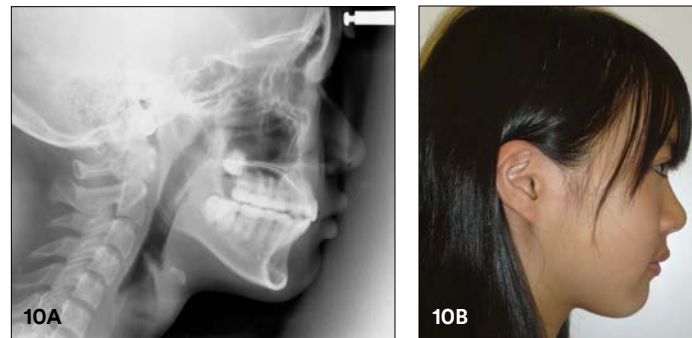


Figure 10A-B: Case 2 post-treatment.

### Retention after 24 months

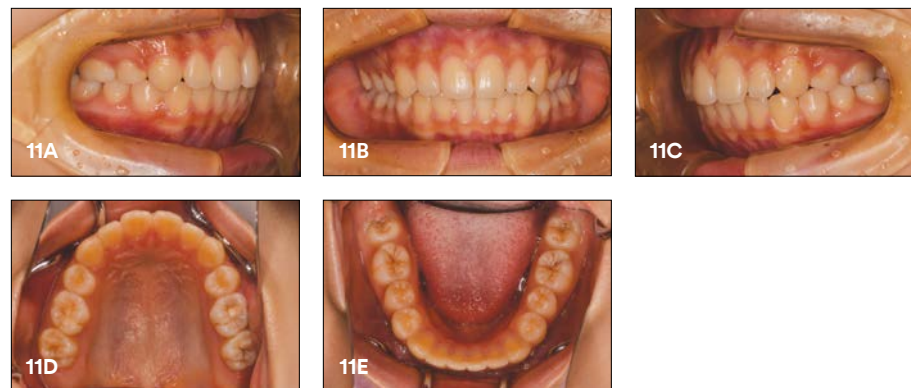


Figure 10A-E

### Case 2 Narrative:

A 13-year-and 6-month-old female patient presented with main complaint of a concern with anterior teeth. Her facial appearance was symmetric and her facial type was of Convex type. A tension was noted in the mentalis muscle. Angle Class II malocclusion was observed for right and left molar occlusions with overjet of 9 mm and overbite of 4.5 mm. The maxillary and mandibular arch length discrepancies were -4 mm and -3 mm, respectively. Excessive labial inclination of the maxillary central incisors was observed. Tooth formation of maxillary and mandibular right and left 3rd molars were observed and there was no abnormality in tooth number. Initial cephalometric analysis in the lateral view revealed the following measurements: SNA, 83.5°; SNB, 79.8°; ANB, 3.7°; FMA, 23.4°; FMIA, 55°; U1-FH, 135.2°; L1-Mand., 101.9°; and Interincisal angle, 99.9°.

Based on these findings, a diagnosis of Angle Class II division 1 was established. Orthodontic treatment by JETsystem using passive self-ligating (PSL) brackets (Clarity™ SL and SmartClip™ Self-Ligating Brackets) of varying slot size, .018-inch slot for anterior brackets (3-3) and .022-inch slot for posterior brackets, was planned to improve labial inclination of the maxillary central incisors. For improvement of lip protrusion, maxillary and mandibular right and left 1st bicuspid were all extracted on the day prior to the date of placement of the orthodontic appliance.

Brackets were positioned on a plaster model in advance (straight-wire positioning) and then bonded using an indirect core. For reinforced anchorage, anchor screws were implanted into the maxillary right and left 1st molars. Maxillary and mandibular right and left canine distal movement was initiated immediately after placement of brackets using 50 gf NiTi closed coils. On the same day, application of 3/8-inch intermaxillary elastics between the maxillary canine and mandibular 1st molar was initiated to achieve tight occlusion. Furthermore, 2 months after placement of brackets, maxillary and mandibular anterior retraction was initiated using 50 gf NiTi closed coils. The extraction space was almost closed 8 months after placement of brackets. Although maxillary and mandibular arch coordination took time, the total duration of treatment was 13 months.

To address preoperative deep bite, brackets were removed leaving a shallower bite. Both upper and lower lips recessed and the patient's facial profile was improved. Postoperative panoramic radiograph identified no apparent root resorption and no problem with root parallelism. Postoperative cephalometric analysis in the lateral view demonstrated changes in U1-FH (135.2° to 109.8°) and Interincisal angle (99.9° to 120.7°) that contributed to improvement of the patient's facial profile. Following gradual bite deepening after removal of brackets, bite stabilization was achieved 2 years after initiation of orthodontic treatment.

### References

1. Narita S, JET system - Preparation for initiating treatment by JET system Part 2, Journal of Orthodontic Practice 2012;9:99-115 (published in Japanese)
2. Narita S, JET system - Why passive self-ligating? Journal of Orthodontic Practice 2012;11:83-97 (published in Japanese)
3. Narita S, JET system - Materials used for treatment by JET system, Journal of Orthodontic Practice 2013;6:83-95 (published in Japanese)
4. Narita S, JET system - Clinical cases: Angle Class II division 1 maxillary protrusion, Journal of Orthodontic Practice 2013;9:75-94 (published in Japanese)
5. Giancotti A, Mossicato P, Greco M, En Masse Retraction of the Anterior Teeth Using a Modified Bidimensional Technique, J Clin Orthod 2012 ; 46 : 267-273
6. Sia SS, Shibazaki T, Koga Y, Yoshida N, Speedy, accurate and controllable anterior teeth retraction by an improved method: a sliding mechanics force system with power arms, Biological Mechanisms of Tooth Eruption, Resorption and Movement 2006 ; 297-303
7. Proffit WR, Fields HW, Contemporary Orthodontics 4th ed. xxx-xxx

*Case photos provided by Dr. Shinichi Narita.*



**Don't miss an issue!**

Have *Orthodontic Perspectives Innova*  
sent to your e-mail. Sign up today at  
[3M.com/SendMeOPI](http://3M.com/SendMeOPI)



3M Oral Care  
2510 Conway Avenue  
St. Paul, MN 55144-1000 USA  
Phone 1-800-423-4588  
Web [3M.com/ortho](http://3M.com/ortho)

3M Canada  
Health Care Division  
300 Tartan Dr.  
London, ON N5V 4M9 Canada  
Phone 1-800-443-1661

3M, APC, Clarity, Forsus, Incognito, MBT, SmartClip,  
Unitek, and Victory Series are trademarks of 3M.  
3M Health Care Academy is a service mark of 3M.  
Used under license in Canada. All other trademarks  
are property of their respective holders.  
© 3M 2016. All rights reserved.  
70-2021-5295-8 1610