

# Treatment of a deep carious lesion of second lower premolar with 3M™ Filtek™ One Bulk Fill Restorative

Clinical dentistry and photography by: Dr. Filippo Dini, Viareggio, Italy

## About the Case:

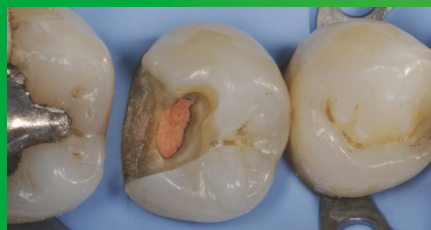
Male patient 47 years old.

Patient reported pain when drinking cold beverages.  
The x-ray showed the extension of caries close to pulp.  
Endodontic treatment was required.

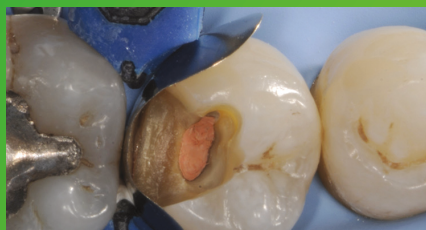
## Challenge:

The deep cervical margin and the preservation of tissue for the post-endo restoration posed challenges in this case. Excellent adaptation between the material and cavity walls is critical.

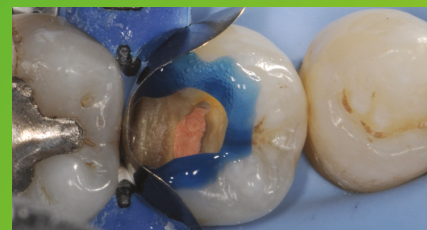## Step-by-Step:



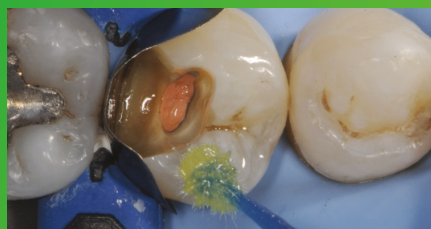**Fig. 1: Initial Situation:** Second lower right premolar with a deep carious lesion restoration that required endodontic treatment. Image is showing the final preparation after removing the temporary filling.



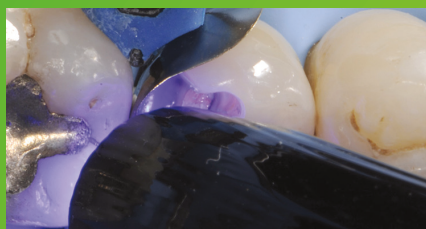**Fig. 2: Placement and adaptation of the sectional matrix.**



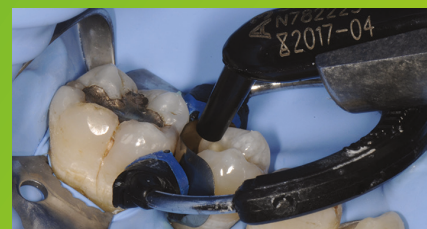**Fig. 3: Enamel is etched for 15 seconds using 3M™ Scotchbond™ Universal Etchant for a selective etch approach, followed by rinsing and drying.**



**Fig. 4: 3M™ Scotchbond™ Universal Adhesive is applied and scrubbed into the surface for 20 seconds.**

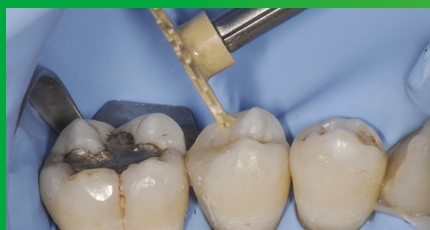

**Fig. 5: After air drying for approximately 5 seconds, the adhesive is light cured for 10 seconds with 3M™ Elipar™ DeepCure-S LED Curing Light.**

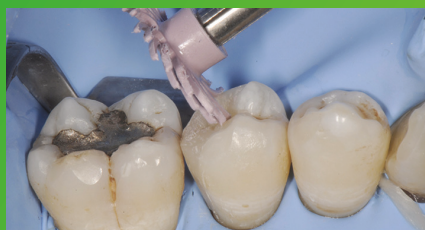

**Fig. 6: 3M™ Filtek™ One Bulk Fill Restorative, in shade A3, is directly placed into the cavity in a single increment and then cured according to the Instructions for Use.**

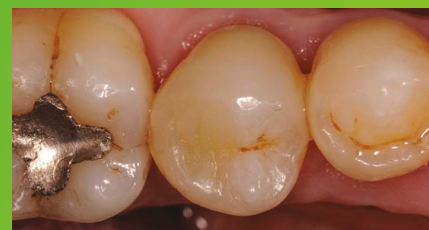# Treatment of a deep carious lesion of second lower premolar with 3M™ Filtek™ One Bulk Fill Restorative (continued)



**Fig. 7:** Following finishing, to achieve the final polish of the restoration, the 3M™ Sof-Lex™ Pre-Polishing Spiral is used, as a first step, on a moist surface.



**Fig. 8:** A final high-gloss polish is created using the 3M™ Sof-Lex™ Diamond Polishing Spiral on a moist surface.



**Fig. 9:** Final restoration is very natural-looking and aesthetic.

## The 3M Difference:

In deep and tight cavities, incremental layering can be a timely challenge and lead to poor marginal adaptation. With its easy handling and excellent adaptation, 3M™ Filtek™ One Bulk Fill Restorative enables one-step placement up to 5 mm, without compromising the aesthetics of posterior restorations.

Refer to Instructions for Use (IFU) for complete product information.



### 3M Oral Care

3M Australia Pty Limited  
Building A, 1 Rivett Rd  
North Ryde NSW 2113  
Ph: 1300 363 454  
3M.com.au/oralcare

3M New Zealand Limited  
94 Apollo Drive, Rosedale  
Auckland 0632  
Ph: 0800 80 81 82  
3M.co.nz/oralcare

3M, Elipar, Filtek, Scotchbond and Sof-Lex are trademarks of 3M Company.  
All other trademarks are owned by other companies. Please recycle. © 3M 2017.  
All rights reserved.