

Direct restorations with 3M™ Filtek™ One Bulk Fill Restorative on upper premolar and molar due to primary and secondary caries.

Clinical dentistry and photography by: Dr. Giuseppe Marchetti, Parma, Italy

About the Case:

Female patient 35 years old.

The patient came to the dental office with caries in multiple teeth and pain.

Challenge:

For direct restorations like these, it is critical to have excellent adaptation to ensure good marginal contact. Good handling and sculptability are important when shaping the material.

Step-by-Step:

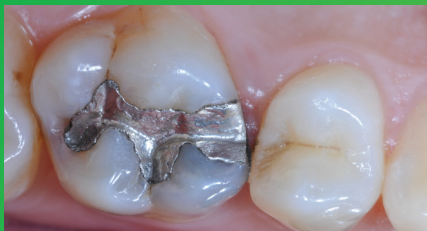

Fig. 1: Initial Situation: Replacement of an insufficient amalgam restoration of first upper molar and treatment of carious lesion on premolar. Patient was experiencing pain.

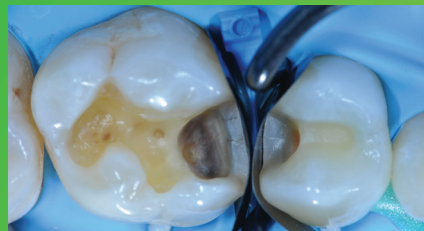

Fig. 2: Amalgam and carious tissue removed. Placement and adaptation of the sectional matrix.

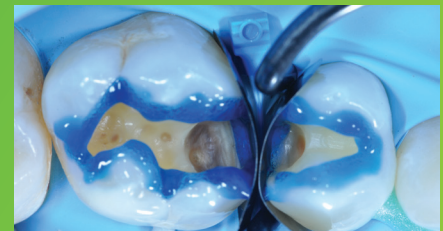


Fig. 3: Enamel is etched for 15 seconds using 3M™ Scotchbond™ Universal Etchant for a selective etch approach, followed by rinsing and lightly drying.

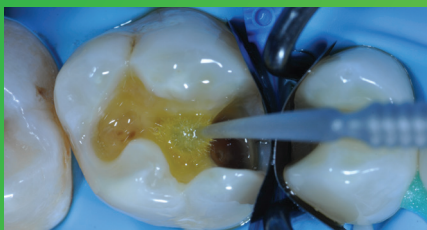

Fig. 4: 3M™ Scotchbond™ Universal Adhesive is applied and scrubbed into the surface for 20 seconds. After air drying for approximately 5 seconds, the adhesive is light cured for 10 seconds with 3M™ Elipar™ DeepCure-S LED Curing Light.

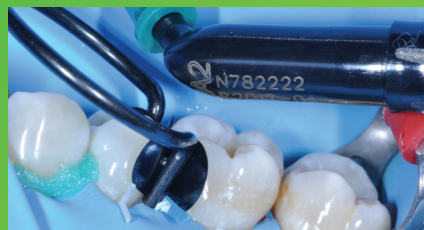

Fig. 5: 3M™ Filtek™ One Bulk Fill Restorative, in shade A2, is directly placed into the cavity in a single increment and then cured according to the Instructions for Use.

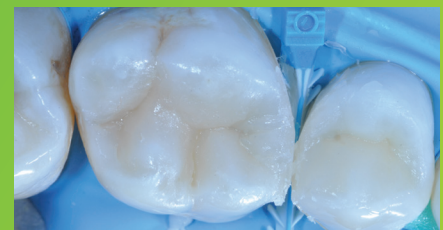

Fig. 6: 3M™ Filtek™ One Bulk Fill Restorative following contouring and finishing.

Direct restorations with 3M™ Filtek™ One Bulk Fill Restorative on upper premolar and molar due to primary and secondary caries (continued)

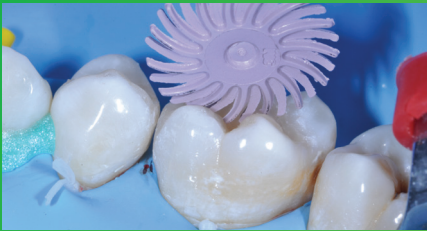

Fig. 7: After using the 3M™ Sof-Lex™ Pre-Polishing Spiral, a final high-gloss polish is created using the 3M™ Sof-Lex™ Diamond Polishing Spiral on a moist surface.

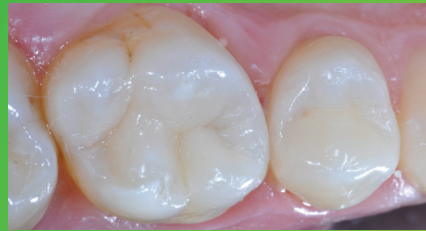

Fig. 8: Final restoration is very natural-looking and esthetic.

The 3M Difference:

For large posterior restorations, incremental layering can be timely and lead to poor marginal adaptation. With its easy handling and excellent adaptation, 3M™ Filtek™ One Bulk Fill Restorative enables one-step placement up to 5 mm. Additionally, its increased opacity results in more esthetic posterior restorations.

Refer to Instructions for Use (IFU) for complete product information.

3M

3M Oral Care
2510 Conway Avenue
St. Paul, MN 55144-1000 USA
Phone 1-800-634-2249
Web 3M.com/dental

3M Canada
Post Office Box 5757
London, Ontario N6A 4T1
Canada
1-888-363-3685

3M, Elipar, Filtek, Scotchbond and Sof-Lex are trademarks of 3M Company. Used under license in Canada. All other trademarks are owned by other companies. Please recycle. Printed in U.S.A. © 3M 2016. All rights reserved.