

## 3M<sup>SM</sup> Health Care Academy

# The Three E's: Efficiency, Effectiveness and Excellence

SMARTCLIP<sup>TM</sup> SL3  
SELF-LIGATING APPLIANCE SYSTEM

CLARITY<sup>TM</sup> SL  
SELF-LIGATING APPLIANCE SYSTEM



### Dr. Anoop Sondhi

Dr. Anoop Sondhi received his dental degree from the Indiana University School of Dentistry, and his post-graduate certificate and M.S. in Orthodontics from the University of Illinois in 1977. Following his graduation, he was on the graduate faculty of the Department of Orthodontics at Indiana University. During his full-time academic appointment at Indiana University, he maintained a part-time private practice. Since 1988, he has

been in full-time private practice in Indianapolis, and continues to be a Visiting Professor for several graduate programs in Orthodontics. He has presented seminars and continuing education courses to several dental and Orthodontic organizations in the United States, and has been invited to give courses in Canada, Central America, South America, Europe, Asia, South Africa, Australia and New Zealand.

### Abstract

*This case demonstrates the efficiency of treatment with Clarity<sup>TM</sup> SL Self-Ligating Brackets and SmartClip<sup>TM</sup> SL3 Self-Ligating Brackets, the effectiveness of the Forsus<sup>TM</sup> Class II Correctors, and the excellence in finishing afforded by using Variable Prescription Orthodontics.*

The treatment of adult Class II Division 2 cases can frequently be challenging, because of the difficulty in correcting the deep overbite, as well as the challenge of correcting the anteroposterior discrepancy in a non-growing patient.

This patient presented with an asymmetric Class II Division 2 malocclusion. The left side was a full cusp Class II, and the right side a half cusp Class II. In addition, he had a deep anterior overbite. Somewhat unusual in his clinical presentation were the divergent axial inclinations of the maxillary central incisors. Instead of the usual lingual inclination of both maxillary central incisors, only the right central incisor was lingually inclined, and the left central incisor was flared labially.

Skeletally, there was a slight mandibular retrognathia, which was partly masked by a prominent chin button. A minor mandibular arch length deficiency was evident, and teeth #16 and 32 were impacted. Tooth #18 was partially unerupted, and the mesial marginal ridge was submerged below the distal marginal edge of tooth #19. The patient was 17 years old, and essentially an adult, non-growing patient. Figure 1A-H, Figure 2, and Figure 3 demonstrate the pre-treatment clinical records. The impacted third molars can be visualized, as well as the divergent inclinations of teeth #8 and 9.

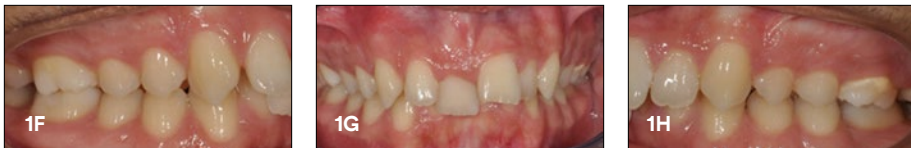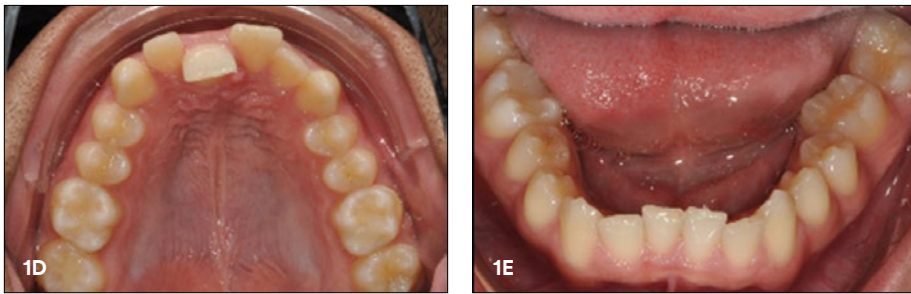



Figure 1A-H

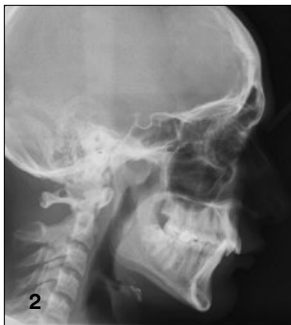

Figure 2

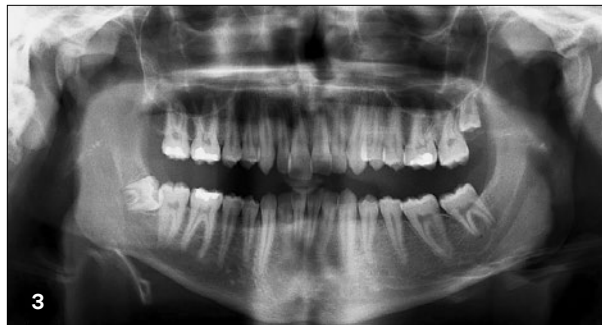

Figure 3

In the past, it would not have been uncommon for this type of case to be treated with the extraction of two maxillary premolars. However, for reasons of his overall facial profile, as well as the lip profile, extractions were considered undesirable. He was, however, advised that teeth #16 and 32 would eventually require extraction.

As the treatment plan was developed, it became clear that this case would allow for an excellent combination of the efficiency facilitated by self-ligated appliances, supplemented by the effectiveness of Class II correction with the Forsus™ Class II Corrector appliance, and the excellence and precision introduced by implementing the concept of using a Variable Prescription. It is evident, of course, that the bracket positioning would be for correction of the deep anterior overbite. However, it is important to recognize the applicability of using a Variable Prescription. Teeth #8 and 9 obviously have widely divergent axial inclinations, easily visualized not just clinically, but also on the cephalometric radiograph. The problem of using a static prescription, regardless of which type is used, is the evident illogic in placing brackets with similar torque and angulation values on teeth #8 and 9. Quite obviously, tooth #8 would require a substantial amount of lingual root torque, and tooth #9 will not. Further, since the use of a Forsus Class II corrector will clearly tend to cause labial proclination of the mandibular anterior segment, that would argue in favor of using low torque brackets in the mandibular arch.

An example of the selected prescription can be seen in Figure 4. For reasons described above, we used medium torque brackets (labeled green) in the maxillary arch, with the exception of the maxillary right central incisor, where we placed a high torque bracket (labeled blue). The mandibular arch was treated with low torque brackets (labeled yellow).



Figure 4

Figure 5A-E shows the photographs taken at the bonding appointment. The appliance of choice was Clarity™ SL Self-Ligating Brackets on the maxillary arch, with SmartClip™ SL3 Self-Ligating Brackets on the mandibular arch in the .018x.025 slot. A resin reinforced, fluoride releasing, glass ionomer material is used on the occlusal surfaces of the maxillary first molars to disarticulate the occlusion. Because of the significant displacement of tooth #8, the initial maxillary and mandibular archwire were .014 heat activated Nitinol archwires.

Eight weeks later, the patient was seen for a follow-up appointment, at which time some brackets were repositioned (Figure 6A-E). Please note the extremely efficient reduction in the imbrication of the maxillary incisors in just the first eight weeks of treatment. Upper and lower .014 and Nitinol tandem wires were added at this time, and some remaining brackets were repositioned at the follow-up appointment eight weeks later. At the third appointment, maxillary and mandibular .016x.025 Beta III Titanium archwires were placed to continue leveling the Curve of Spee, and to begin establishing torque control (Figure 7A-E).

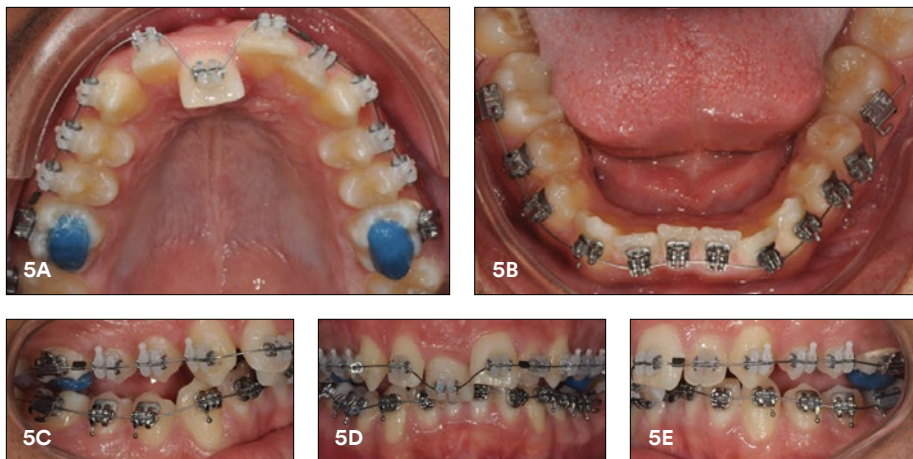


Figure 5A-E

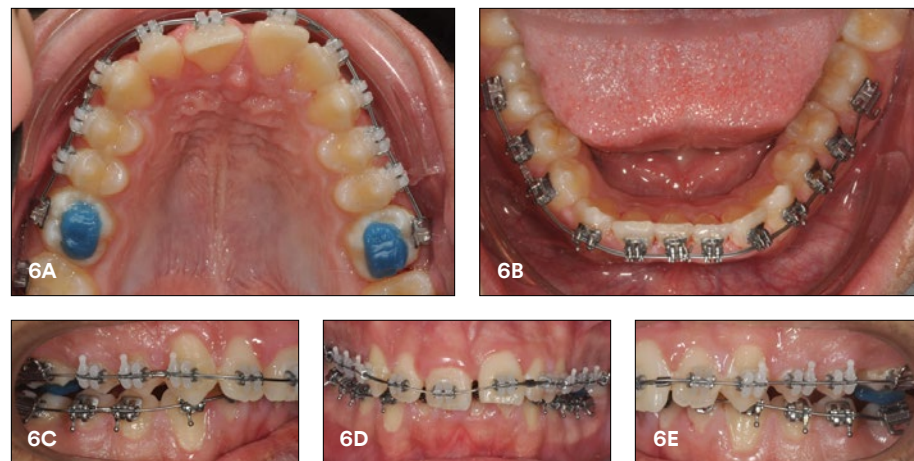


Figure 6A-E

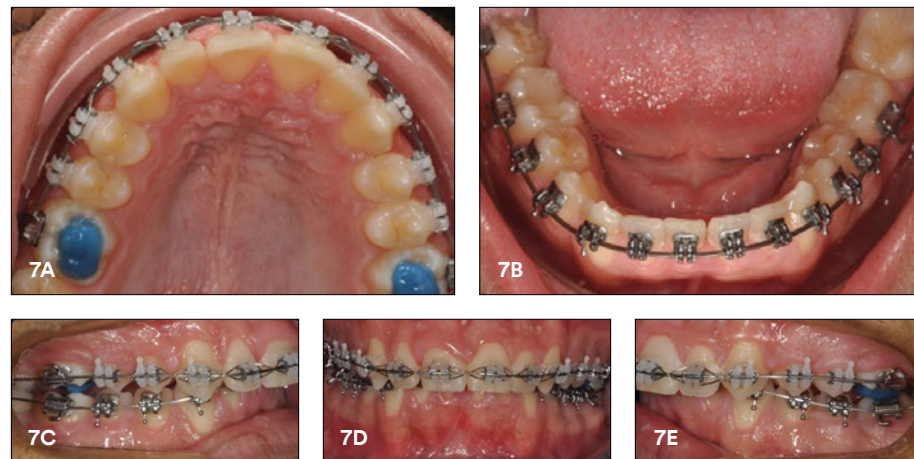


Figure 7A-E

Following 16 weeks of leveling, Forsus Class II Correctors (Figure 8A-C) were placed on the right and left sides. The Forsus appliance was placed for five months, following which the finishing .016x.025 Beta III Titanium archwires were inserted.

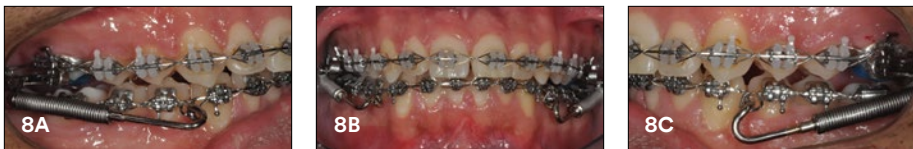

Figure 8A-C

Some minor 2<sup>nd</sup> and 3<sup>rd</sup> order adjustments were needed, and Figure 9A-H, Figure 10, and Figure 11 demonstrate the completed orthodontic treatment. Please note that, since Variable Prescription appliances were used, we did not have to place individual and separate torque activations for teeth #8 and 9. Further, the use of a low torque prescription in the mandibular arch minimized the lingual proclination of the mandibular incisors with the Class II corrector. Figure 12A-B and Figure 13 demonstrate a comparison of the pre- and post- cephalometric radiographs, as well as the superimposition tracings.

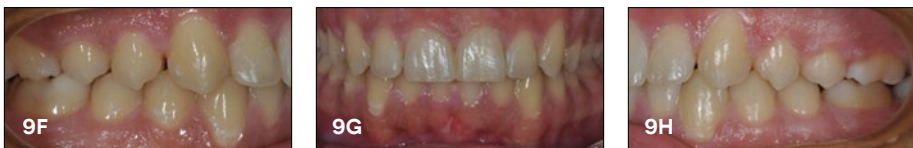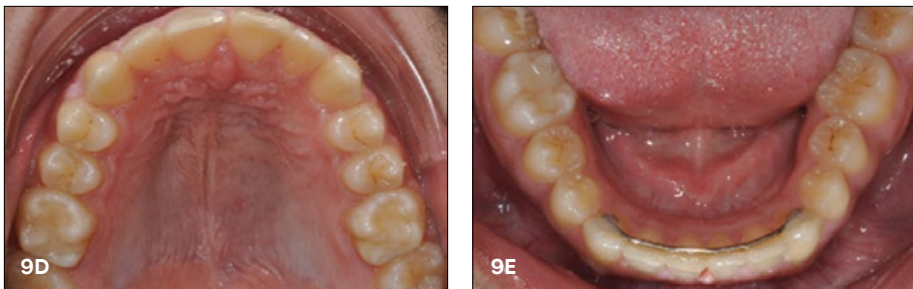

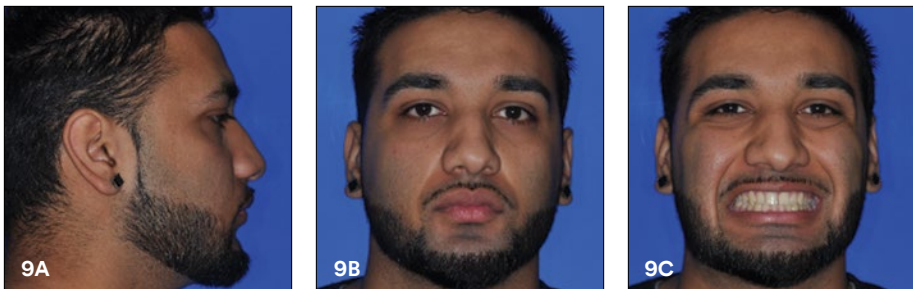
Figure 9A-H

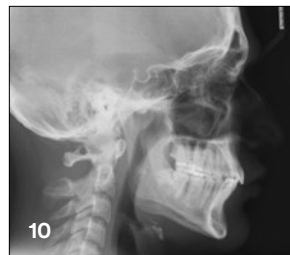

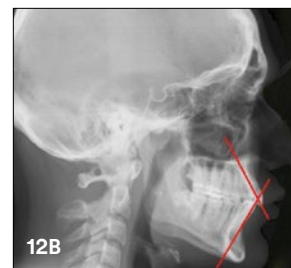
Figure 10

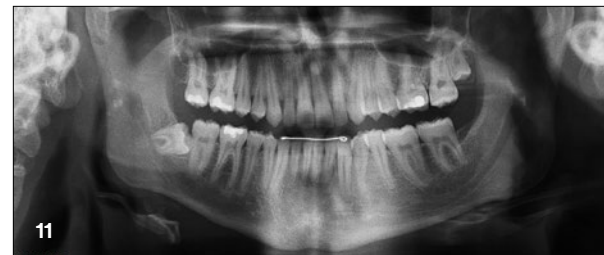
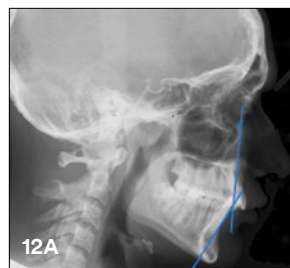
Figure 11

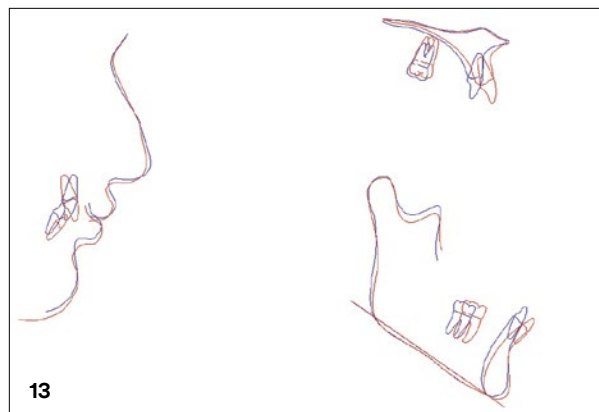


12A



12B

Figure 12A-B



13

Figure 13

The total time in treatment was 17 months, which is a very efficient window of time for treatment of this case. This was achieved due to the efficient initial alignment afforded by self-ligation, the effectiveness of the Class II correction provided by the Forsus Class II corrector, and the caliber of the finishing details with the Variable Prescription.

Case photos provided by Dr. Anoop Sondhi.

Some article content was previously published in "The Tandem Archwire Concept with Self-Ligating Brackets.", Journal of Clinical Orthodontics, 2014; Vol XLVII, No 4. Used with permission.

3M, Clarity, Forsus, and SmartClip are trademarks of 3M. Used under license in Canada. © 3M 2016. All rights reserved.

