



Science.
Applied to Life.™

Orthodontic Perspectives Innova

News, Information, and Clinical Case Studies





James Ingebrand
Vice President &
General Manager
3M Oral Care

In my travels to meet with orthodontists, I hear from many that the current competitive environment is increasingly difficult. Patients not only choose among providers, but now they also choose by different treatment methods and claims about the final results available from each. Patients hear about dental GPs placing brackets, and clear tray aligners, and better smiles promised in just six months. It almost seems that comprehensive, quality treatment is under assault.

At 3M, we understand that lasting success in meeting this challenge comes from an unwavering commitment to quality, clinical excellence, and treatment efficiency. As your partner, our goal is to help you succeed in your practice, delighting the patient with a great treatment experience, and you with your planned treatment results.

To help you toward your goals, 3M Oral Care leverages a broad technology portfolio, extensive manufacturing expertise and a global presence to deliver unique and differentiated products that help you succeed. 3M's science background, applied to your needs, brings new ideas to you in the form of products and services that enable excellence in treatment.

If you are at the AAO Annual meeting, visit us at the 3M booth. Learn how 3M's aesthetic and efficient orthodontic solutions are helping orthodontists differentiate their practices, grow case starts and enjoy clinical, professional and personal success across the world.

I would also invite you to read further into this May 2016 issue of *Orthodontic Perspectives Innova*. This issue brings together doctors from around the globe to share their experience and success with 3M Oral Care products.

Four cases highlight the wide breadth of treatment with aesthetic Clarity™ ADVANCED Ceramic Brackets. We also look in depth into the SmartClip™ SL3 Appliance System, unique among self-ligating bracket systems. It provides a high level of treatment efficiency with a design that addresses problems experienced with more common self-ligating bracket designs. And it is now even easier to use with an enhanced self-ligating clip.

You will also find interesting product news, treatment tips and important dates for upcoming educational opportunities for you and your staff. *Orthodontic Perspectives Innova* is in its 23rd year of continuous publication, providing industry news and information to orthodontists. I hope you find the information in this issue of value to your practice. Please contact your 3M representative if you have any questions or need any more information on any of the products included here.

Orthodontic Perspectives Innova is published periodically by 3M to provide information to orthodontic practitioners about 3M orthodontic products and services. 3M welcomes article submissions or article ideas. Contact address: Editor, Orthodontic Perspectives Innova, 3M Oral Care, 3M Center, 275-2W-08, St. Paul, MN 55144-1000. To call for more information: In the United States and Puerto Rico, call (800) 852-1990 ext. 4399. In Canada call (800) 443-1661 and ask for extension 4399. Or, call (651) 736-7690 (direct).

Copyright © 3M 2016. All rights reserved. No part of this publication may be reproduced without the consent of 3M. Some of the doctors contributing to the *Orthodontic Perspectives Innova* publication may receive compensation from 3M.

3M, “3M Science. Applied to Life.”, APC, AlastiK, Clarity, Forsus, Incognito, MBT, SmartClip, Sondhi, Unitek, and Victory Series are trademarks of 3M. 3M Health Care Academy is a service mark of 3M. Used under license in Canada. All other trademarks are property of their respective holders.

Visit our website at
3M.com/ortho

Table of Contents

News and Information

Product news and announcements.....	3
U.S. Education Events – 2016.....	6
Global Incognito™ Appliance System course schedule for 2016	7

3M™ Health Care Academy

Clinical Cases

Clarity™ ADVANCED Ceramic Brackets and Incognito™ Appliance System Case Study <i>by Dr. Patrice Pellerin.....</i>	9
SmartClip™ SL3 Self-Ligating Appliance: A Case for Orthodontic Treatment Efficiency <i>by Dr. Moe Razavi</i>	16
Eight Keys for Successful and Efficient Treatment with SmartClip™ and Clarity™ SL Appliances <i>by Dr. Gilad Har-Zion.....</i>	20
Class I: Crooked teeth, crowding, midline discrepancy <i>by Dr. Patrice Pellerin.....</i>	25
Class II: Aesthetic Treatment with Clarity™ ADVANCED Ceramic Brackets Patient Experienced Failure in Treatment with Aligners <i>by Dr. Anoop Sondhi.....</i>	30
Class III: Missing teeth, tight teeth, Class III cuspid relationship <i>by Dr. Patrice Pellerin.....</i>	34

Clarity™ ADVANCED Ceramic Brackets with Forsus™ Class II Correctors – the efficient aesthetic treatment choice for your patients.


CLARITY™ | ADVANCED
advanced ceramic brackets




Clarity™ ADVANCED Ceramic Brackets have quickly become the traditional bracket of choice for aesthetic treatment. Small, strong, easy to ligate, easy to debond, and amazingly aesthetic, they offer a complete treatment solution for patients considering treatment options. Combined with APC™ Flash-Free Adhesive, this system is a practice differentiator in an ever more competitive treatment environment.



But when Class II Correction comes into the mix, non-aesthetic options are still being offered to patients. Yes, headgear works. But what patient in today's market would choose headgear over an aesthetic solution that works quickly, efficiently, comfortably, and importantly, unnoticeably.

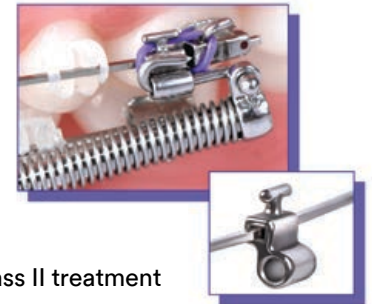

Patient with headgear



Patient wearing Forsus™ Correctors

Forsus™ Class II Correctors were the pioneer among intraoral Class II appliances. Proven in treatment for more than a decade, they give you a completely aesthetic treatment system for your patients who need Class II. Now with the addition of the Forsus wire mount, the system can be used with or without banded molars, installed with no labs required. Even if Class II treatment was not in the initial treatment plan, it can be added at any time with simple installation.



Read a case study where Clarity ADVANCED Ceramic Brackets have been combined in treatment with the Incognito™ Appliance System..

Clarity™ ADVANCED Ceramic Brackets and Incognito™ Appliance System Case Study by Dr. Patrice Pellerin

Read more about Clarity ADVANCED Ceramic Brackets and Forsus Class II correctors by visiting 3M.com/ortho.

Clarity™ ADVANCED Ceramic Brackets – Case Overview booklet released.

CLARITY™ | **ADVANCED**
advanced ceramic brackets



A new resource for doctors, featuring Clarity™ ADVANCED Ceramic Brackets in treatment, is now available on the 3M web site. The Clarity™ ADVANCED Ceramic Brackets – Case Overview is an informative compilation of many cases using Clarity ADVANCED Brackets for Class I, Class II and Class III patients.

The cases show the wide variety of requirements that these versatile brackets can successfully treat, while providing an excellent aesthetic solution for the patient.

There will be additional cases added over time, so feel free to check back for additional information.

For a sample of the cases covered in the new booklet, see the following articles:

Class I: Crooked teeth, crowding, midline discrepancy

Class II: Aesthetic Treatment with Clarity™ ADVANCED Ceramic Brackets Patient Experienced Failure in Treatment with Aligners

Class III: Missing teeth, tight teeth, Class III cuspid relationship



To view the entire Case Overview booklet, visit the website at **3M.com/ADVANCED** and see the listing under "Resources"

Efficiencies of SmartClip™ SL3 Self-Ligating Appliances enhanced with improved ligating clip.

SMARTCLIP™ SL3
SELF-LIGATING APPLIANCE SYSTEM

As part of an ongoing continuing improvement process for 3M products, 3M R&D engineers have responded to a call for improved engagement and disengagement forces for the ligating clips on SmartClip™ SL3 Self-Ligating Appliances. While visually the change is hardly noticeable, the improved clips change the forces needed to engage and disengage archwires, and in particular, rectangular archwires. The result is an improved experience for both the doctor and patient. In the process, the shape of the enhanced clip has also improved the rotation control characteristics of the brackets.



There are also two articles featuring the SmartClip appliance system in this issue. One includes Information on the SmartClip Bracket's aesthetic counterpart – Clarity™ SL Self-Ligating Appliances.

SmartClip™ SL3 Self-Ligating Appliance: A Case for Orthodontic Treatment Efficiency, Dr. Moe Razavi, Canada

Eight Keys for Successful and Efficient Treatment with SmartClip™ and Clarity™ SL Self-Ligating Appliances, Dr. Gilad Har-Zion, Israel

Unitek™ Miniature Twin Brackets now available in the MBT™ Appliance System prescription.

Treatment proven Unitek™ Miniature Twin Brackets provide the clinical treatment characteristics of a full-size twin bracket, but in a smaller size for greater patient comfort and aesthetics. Now, you can choose these popular brackets in the MBT™ Versatile+ Appliance System prescription.

The MBT System is known worldwide for predictable outcomes, even in the most difficult cases. Unitek Miniature Twin brackets are manufactured from sturdy 17-4 stainless steel, are metal injection molded (MIM), and feature both torque-in-base and a micro-etched base. Smooth bidirectional hooks on the cuspids and bicuspid provide superior elastic engagement, and the ample under tie-wing area means easier ligation.

For an easier and faster bonding process, you will also soon be able to choose 3M-exclusive APC™ II Adhesive Coating with your Unitek Miniature Twin MBT Brackets, giving you an efficient treatment combination. Contact your 3M Oral Care sales representative today or visit 3M.com/ortho for additional information.



MBT™
Versatile+ Appliance System

Explore a world of color with our “Paint Your Smile” web app.

Paint Your Smile is a web-based program designed for teen patients to have a fun experience choosing their orthodontic braces and then selecting colorful AlastiK™ Ligatures for their teeth. Teen patients like to experiment with colors, and this tool allows them to express their individuality with Clarity™ ADVANCED Ceramic Braces or Victory Series™ Low Profile Braces.

With this website application:

- The braces and ligature choices are placed on an uploaded image of themselves.
- For the best outcome, be sure to recommend that they use a photo with a big full smile.
- The final image that your patient creates with the application can be shared via social media sites such as Twitter and Facebook, forwarded by email or saved on their device.

You can link to the application from your website, or use this tool in the reception area or during the patient consult! Using a tablet, smartphone or desktop computer, it can be a fun way to show patients what they will look like with braces on their teeth and help to close the sale. With bold colors, whimsical imagery and upbeat language, **PaintYourSmile.com** is sure to connect with any audience.

For more information, ask your local 3M Oral Care representative.



3MSM Health Care Academy

U.S. Education Events – 2016

Franklin, TN
June 2-3, 2016

**Ecstatic about Esthetics:
The New Game in Orthodontics**
Kemp Orthodontics In-Office Seminar

This unique in-office course will help you understand how to increase practice profitability.

▶ Register online!
go.3M.com/KempIOC

Sidney, OH
October 6-7, 2016

**Creating Systems to Differentiate your
Practice in a Changing Market**
Alvetro Two-Day Seminar

▶ **Mark your calendar!**
Watch for additional information.

Bellagio
Las Vegas, NV
September 17-18, 2016

Esthetics and Your Bottom Line
3M 2016 Orthodontic Summit

3M Oral Care invites you to attend the 3M 2016 Orthodontic Summit! Learn how to get more patients in your practice by exploring today's orthodontic landscape and the shift to esthetic appliances. Gain insight and hear clinical pearls and tips from experienced orthodontists who have driven growth in their practices through esthetics and clinical excellence.

FEATURING...

Dr. Adam Schulhof
Dr. Paul Tran
Dr. Shane Langley

Dr. Moe Razavi
Dr. Mark Causey

▶ Register online!
3MOralCare.cvent.com/Vegas

Dallas, TX
September 30 – October 1, 2016

MiniScrew Certification Course
with Jason B. Cope, DDS, PhD

This two-day certification course covers the placement and use of miniscrew implants (MSIs) in specific cases.

For more information, contact
Shannon Horton at info@CopestheticCE.com

Dallas, TX
December 2-3, 2016

Advanced MiniScrew Treatment Mechanics
with Jason B. Cope, DDS, PhD

This two-day advanced course covers the use of miniscrew implants (MSIs) in advanced cases of the sagittal and vertical dimension.

For more information, contact
Shannon Horton at info@CopestheticCE.com

3MSM Health Care Academy

Global IncognitoTM Appliance System course schedule for 2016



<p>London, UK May 20-21, 2016</p> <p>Speakers Dr. Robbie Lawson Dr. Roberto Stradi</p> <p>Language English</p> <p>Contact cmm cmmevents.net/incognito</p>	<p>Hiroshima, Japan September 7-8, 2016</p> <p>Speaker Dr. Shoji Sugiyama</p> <p>Language Japanese</p> <p>Contact 3M Oral Care Japan Masaya Kawate +81-3-6409-5511 mkawate@mmm.com</p>	<p>Tokyo, Japan October 12-13, 2016</p> <p>Speakers Dr. Keizo Hirose Dr. Shoji Sugiyama</p> <p>Language Japanese</p> <p>Contact 3M Oral Care Japan Masaya Kawate +81-3-6409-5511 mkawate@mmm.com</p>
<p>Fukuoka, Japan May 25-26, 2016</p> <p>Speaker Dr. Keizo Hirose</p> <p>Language Japanese</p> <p>Contact 3M Oral Care Japan Masaya Kawate +81-3-6409-5511 mkawate@mmm.com</p>	<p>Madrid, Spain September 9-10, 2016</p> <p>Speakers Dr. Leandro Fernandez Dr. Paul Ward</p> <p>Languages Spanish and English <i>with simultaneous translations</i></p> <p>Contact cmm cmmevents.net/incognito</p>	<p>Munich, Germany October 21-22, 2016</p> <p>Speakers Dr. Lars Christensen Dr. Esfandiar Modjahedpour</p> <p>Languages German and English <i>with simultaneous translations</i></p> <p>Contact cmm cmmevents.net/incognito</p>

Advanced courses:

<p>Düsseldorf, Germany March 11, 2016</p> <p>Speaker Dr. Esfandiar Modjahedpour</p> <p>Language German</p> <p>Contact 3M Oral Care Germany Brigitte Mader +49 8191-9474-5015 brigitte.mader@mmm.com</p>	<p>Tokyo, Japan September 15, 2016</p> <p>Speakers Dr. Keizo Hirose Dr. Toru Inami Dr. Shoji Sugiyama</p> <p>Language Japanese</p> <p>Contact 3M Oral Care Japan Masaya Kawate +81-3-6409-5511 mkawate@mmm.com</p>
---	--



Visit 3M.com/ortho for
more information!



Clinical Cases



3MSM Health Care Academy

CLARITY™ | **ADVANCED**
advanced ceramic brackets

 **Incognito™**
Appliance System

Clarity™ ADVANCED Ceramic Brackets and Incognito™ Appliance System Case Study



Dr. Patrice Pellerin

Dr. Pellerin received his post graduate Certificate in Orthodontics in 1991 from the University of Montreal. Before orthodontics, he practiced general dentistry for four years after earning his dental degree from the University of Montreal in 1985. Since 1991, he has maintained a solo private practice in Lachine, Quebec. In 1998, Dr. Pellerin converted his practice to a fully aesthetic practice.

He is referred to by his peers as the grandfather of the completely aesthetic practice. He has lectured worldwide to share his practice philosophy of highest aesthetics without compromise to accomplish treatment. Dr. Pellerin also currently teaches lingual and aesthetic orthodontics to the residents at the University of Montreal and University of Winnipeg. He has been an active member of the 3M Unitek Advisory Committee for Aesthetic Appliances since 2003, as well as a 3M Advocate for the use of aesthetic appliances since 2004.

Introduction

This case shows a typical situation when a busy/successful adult patient comes in the office for treatment. Most of the time, the treatment needed is more comprehensive, requiring more tooth movement than they may think, or worse, more than they read on the internet.

This particular young woman wanted a treatment option as invisible as possible: something fast, and nothing removable because it wouldn't fit her busy schedule, and because in the end something removable would possibly make her treatment far longer and potentially not as successful.

Having to talk a lot in her occupation, she was concerned with having a lower lingual appliance. For that reason, we presented the option of using Clarity™ ADVANCED Ceramic Brackets on the lower arch. It turned out to be an excellent option and decision in her case. She was happy with the appearance and the comfort of the appliances was to her satisfaction. From a clinical perspective, we were very satisfied with the efficiency of the appliances chosen for this case.



Initial



Final

Patient

Female (S.D.); 32 years, 1 month

Patient's Main Concern

Doesn't like the position of her upper front teeth that are sticking out

X-ray Findings

- Permanent dentition
- Evidence of formation of 1 wisdom tooth (LL8)
- Condyles asymmetrical and irregular

Dental Analysis

- Class II 7 mm
- Important constriction of the maxilla
- Lower midline discrepancy
- Excessive OJ (11 mm)
- Accentuated lower curve of Spee and Wilson
- Lower lip trapping

Treatment Plan

- Upper Incognito™ Brackets
- Lower – Clarity™ ADVANCED Ceramic Brackets 0.018 slot – MBT™ System prescription (APCFF)
- Bonding charts: MBT System standard 4.5 mm
- Extraction of UR4, UL4 (composite pontics to hide the extraction sites)
- Class II elastics on both sides +++ and control molar anchorage

Treatment	17 months (October 2012 – March 2014)		
Mx	October 2012	Indirect	14 SE (5s), 18 SE (6s), 16×22 SE (5s), 18×25 TMA (9s), 16×22 SS to the end ²
Md	January 2013 ¹	Direct	14 SE (5s), 16 SE (5s), 16×16 SE (4s), 16×22 SE (9s), 17×25 Classic (21s), 16×22 SS to the end ²
# of visits	21		
Emergencies	0		

Retention

- Fixed lingual wires 0.018 TMA
- Upper canine to canine/Lower first bicuspid to first bicuspid
- Upper Hawley retainer nighttime use only to control the spaces of the extraction sites

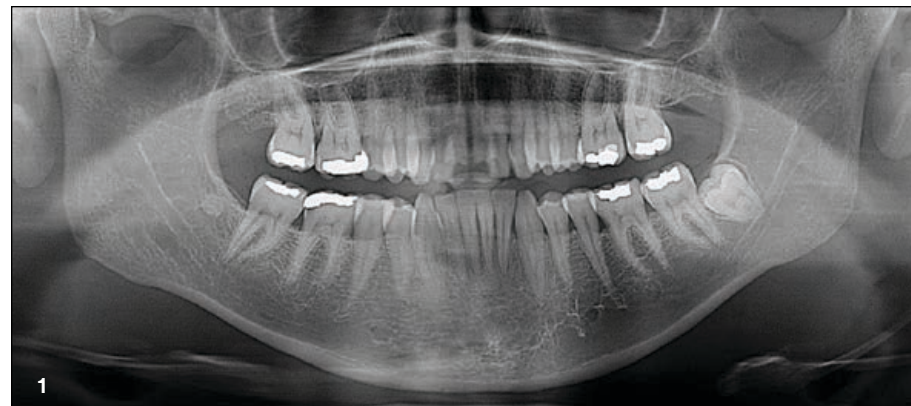


Figure 1: Initial X-ray.

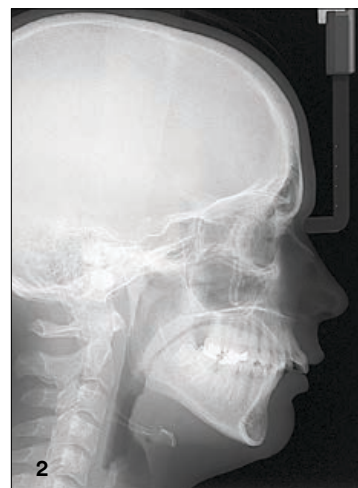


Figure 2: Initial cephalometric analysis.

Cephalometric Analysis				
SNA (°)	89.5	82.0	3.5	2.1 **
SNB (°)	79.3	80.9	3.4	-0.5
ANB (°)	10.2	1.6	1.5	5.8 *****
Maxillary Depth (FH-NA) (°)	93.9	90.0	3.0	1.3 *
Facial Angle (FH-NPo) (°)	83.4	88.6	3.0	-1.7 *
FMA (MP-FH) (°)	30.0	23.9	4.5	1.4 *
UFH:LFH, Upper (N-ANS/N-Gn) (%)	42.7	45.0	1.0	-2.3 **
U-Incisor Protrusion (U1-APo) (mm)	6.6	6.0	2.2	0.3
U1 – Palatal Plane (°)	117.8	110.0	5.0	1.6 *
L1 Protrusion (L1-APo) (mm)	-5.4	2.7	1.7	-4.8 *****
IMPA (L1-MP) (°)	87.3	95.0	7.0	-1.1 *
Interincisal Angle (U1-L1) (°)	128.2	130.0	5.0	-0.4
Upper Lip to E-Plane (mm)	-0.2	-6.0	2.0	2.9 **
Lower Lip to E-Plane (mm)	-1.8	-2.0	2.0	0.1
Nasolabial Angle (Co-Sn-UL) (°)	110.4	102.0	8.0	1.0 *
Maxillary length (ANS-PNS) (mm)	50.1	51.6	4.3	-0.3
Mandibular length (Go-Gn) (mm)	76.2	65.9	5.5	1.9 *
Facial Convexity (G'-Sn-Po) (°)	163.6	154.0	5.6	1.7 *
Wits Appraisal (mm)	12.3	-1.0	1.0	13.3 *****
SUMMARY ANALYSIS				
Class II Molar Relationship				
Skeletal Class II (A-Po)				
Skeletal Class II (ANB)				
Protrusive Maxilla (A-N)				
Retrusive Mandible (Pg-N)				
Deep Overbite				
Excessive Overjet				

Table 1: Cephalometric analysis.

Initial

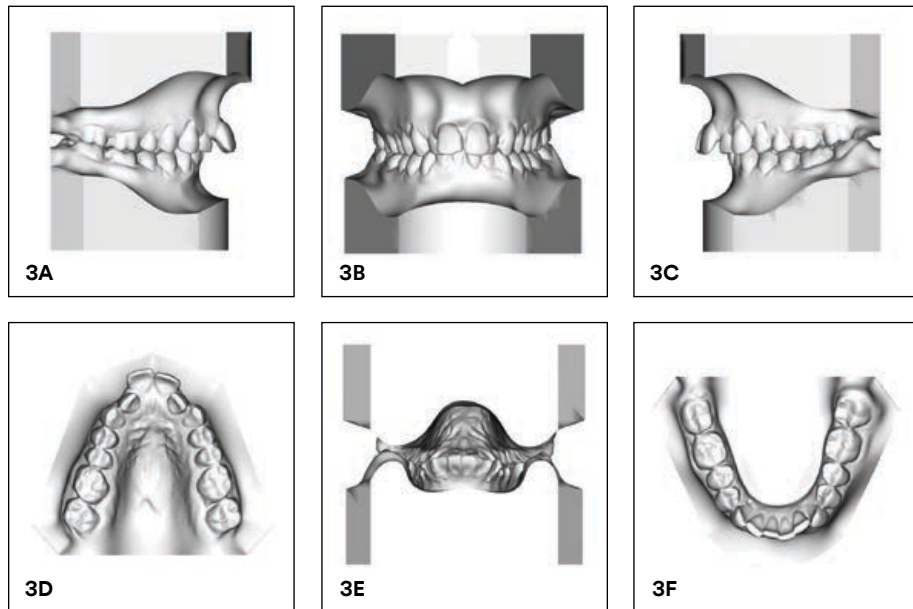


Figure 3A-F: Initial dental analysis.

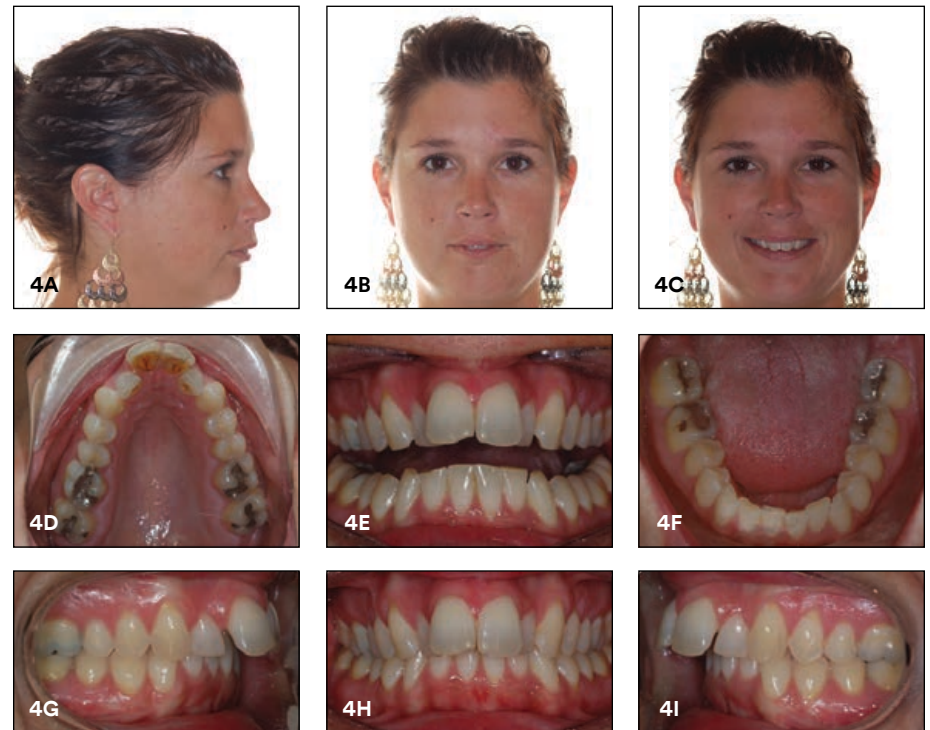

Figure 4A-I: Initial photos.

Treatment Plan: Incognito™ Appliance System

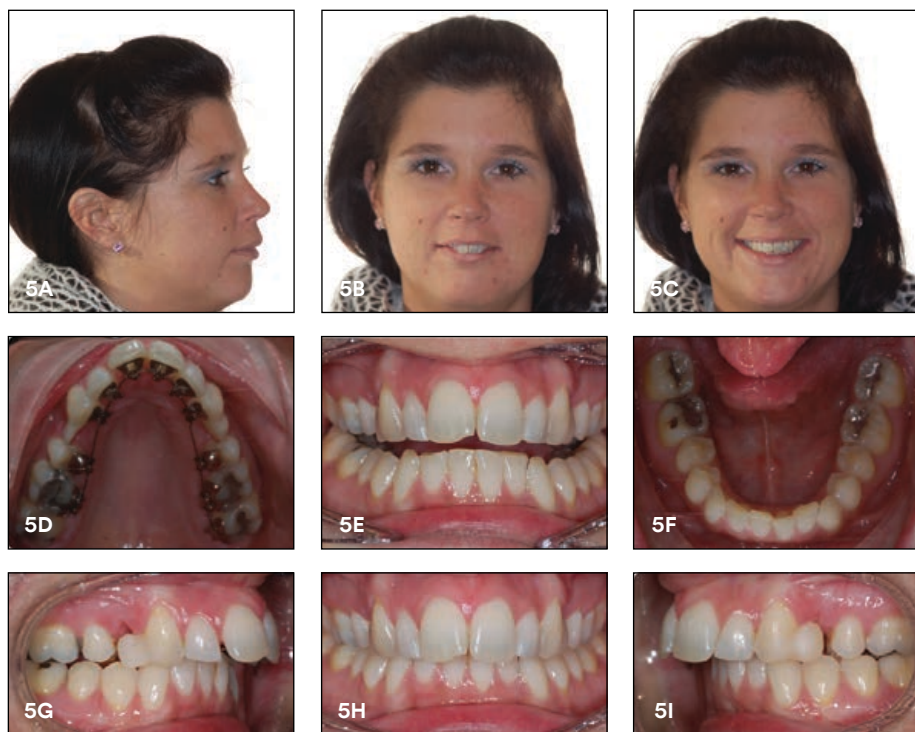

Figure 5A-I: Incognito™ Appliance System photos.

Treatment Plan: Clarity™ ADVANCED Ceramic Brackets (1)

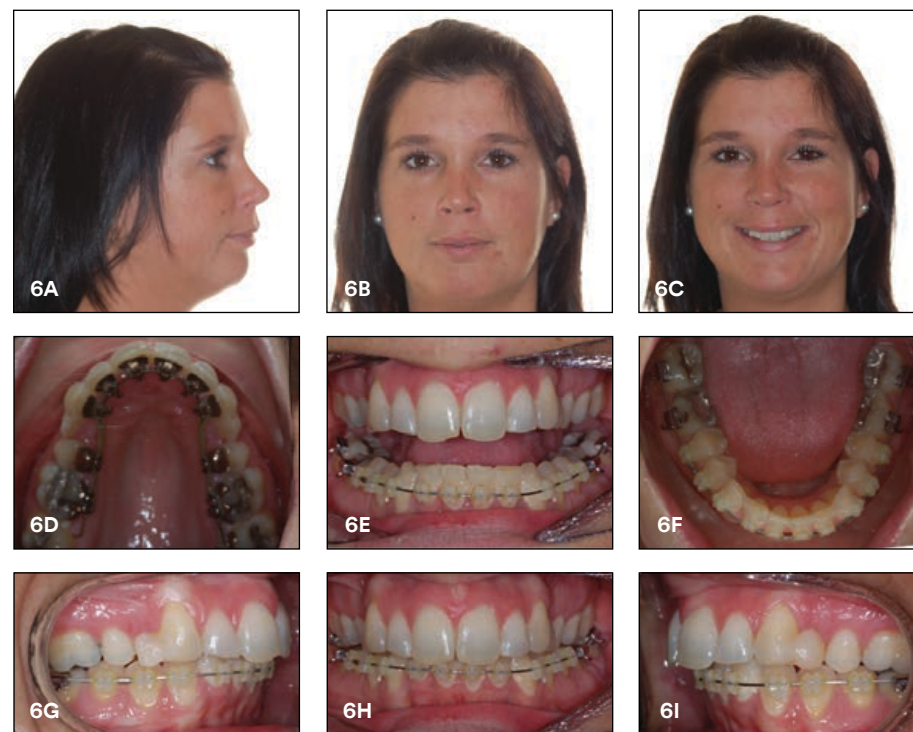

Figure 6A-I: Clarity™ ADVANCED Ceramic Brackets (1) photos.

Treatment Plan: Clarity™ ADVANCED Ceramic Brackets (2)

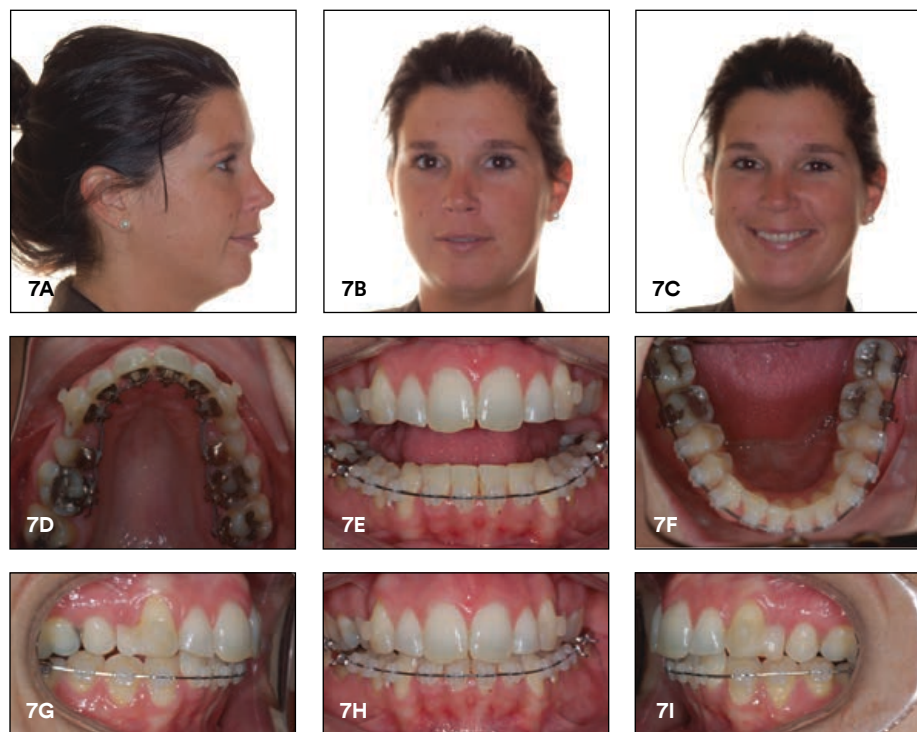

Figure 7A-I: Clarity™ ADVANCED Ceramic Brackets (2) photos.

Mid-Treatment

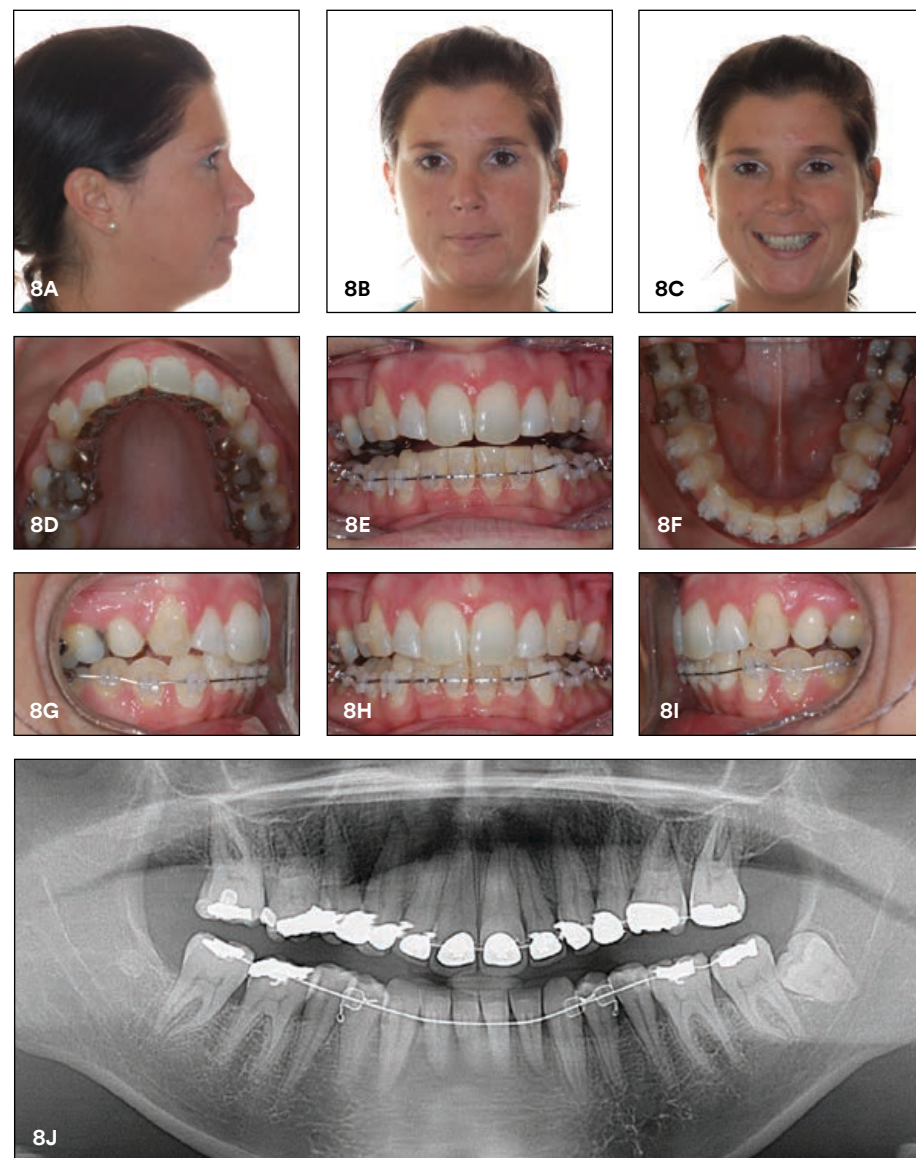


Figure 8A-J: Mid-treatment photos.

Retention

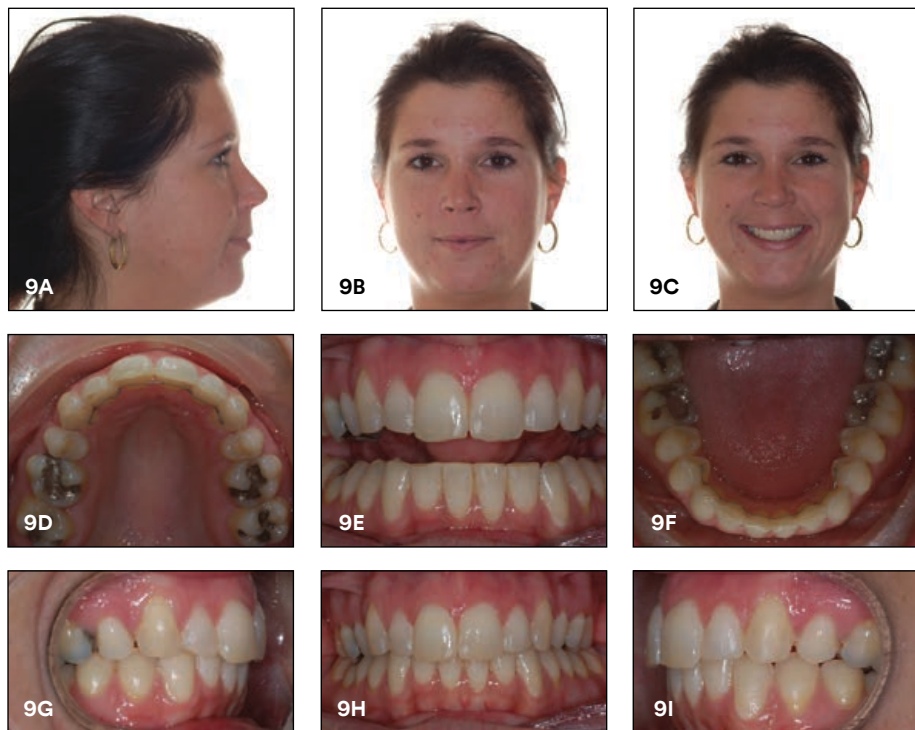

Figure 9A-I: Retention photos.

Initial vs. Final



Figure 10A-B: Initial vs. final photos.

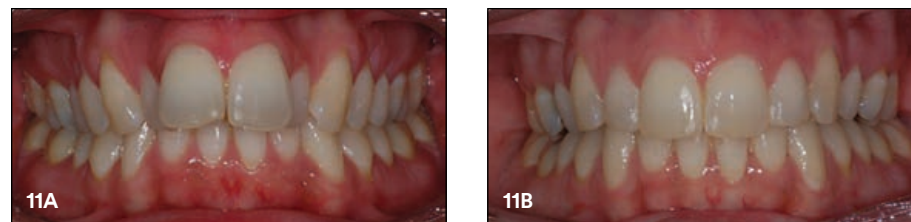


Figure 11A-B: Initial vs. final photos.

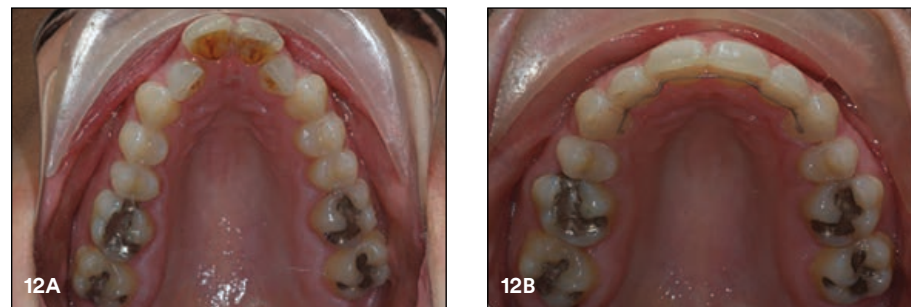


Figure 12A-B: Initial vs. final photos.

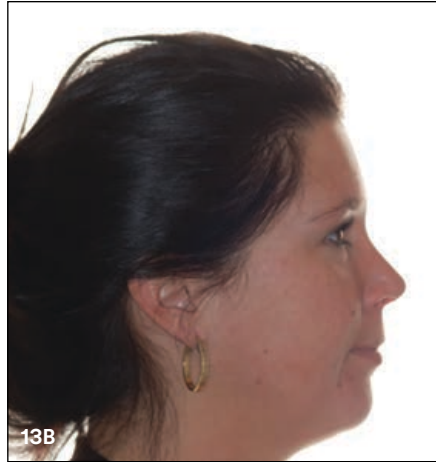
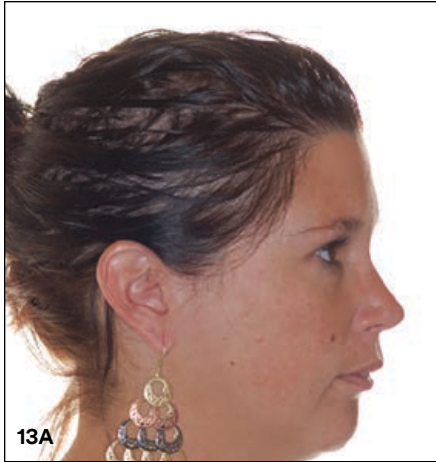
Figure 13A-B: Initial vs. final photos.

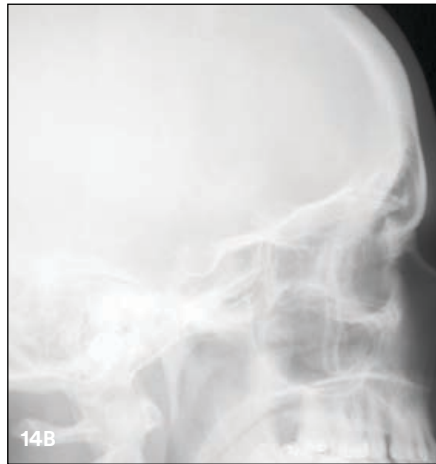
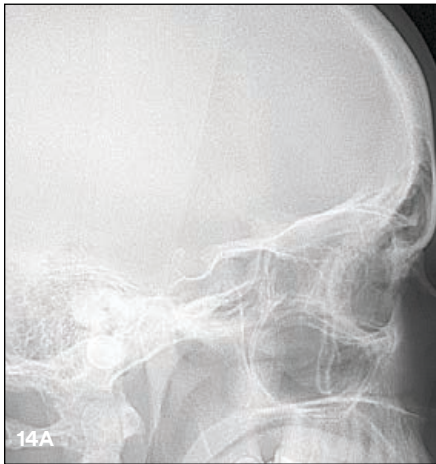
Figure 14A-B: Initial vs. final photos.

Doctor's Notes

1. Notice that the mandibular arch was bonded 3 months after the upper Incognito appliance was bonded. In this way, we benefit from the bite opening effect of the lingual braces without having to bond occlusal or anterior bite openers.
2. Note that this case was finished on stainless steel wires (SS) in both arches, as this is the arch wire material that is recommended to close spaces with the Incognito appliance. As for the lower arch, stainless steel was used to reproduce the arch form from the Incognito set-up as shown in the Unitek™ Treatment Management Portal | TMP.
3. Good torque expression with the combination of Incognito™ Hidden Braces/ Clarity ADVANCED Ceramic Brackets with APC™ Flash-Free Adhesive appliances.

Case photos provided by Dr. Patrice Pellerin.

3MSM Health Care Academy

SMARTCLIPTM | SL3
SELF-LIGATING APPLIANCE SYSTEM

SmartClipTM SL3 Self-Ligating Appliance: A Case for Orthodontic Treatment Efficiency



Dr. Moe Razavi

Dr. Moe Razavi received his dental training at Case Western Reserve University – DDS ('02), orthodontic certificate ('05), and MSD ('05). Upon completion of his orthodontic training, he was invited to join the department as an assistant clinical professor, where he founded and directed the Skeletal Anchorage Clinic, and has integrated various TAD systems into the training program.

He served as the orthodontist for the Cleveland Browns, and is currently a member of the clinical staff at the University of Alberta. Dr. Razavi is a diplomate of the American Board of Orthodontists, a Fellow of the Royal College of Dentists in Canada, and an ad hoc reviewer for the American Journal of Orthodontics, and the Journal of Clinical Orthodontics. Dr. Razavi maintains a private practice in Ottawa, Canada.

Introduction

In the current marketplace, orthodontists are no longer just competing for potential patients with other orthodontists, but also, numerous dentists who have been coached by dental practice management experts to avoid referrals of patients from their offices. In such a competitive landscape, orthodontists can no longer afford to provide their patients with inefficient orthodontic treatment that often takes two to three years, with monthly visits to “tighten” the braces as perceived by the patients. As experts in the field, we need to arm ourselves with treatment tools that allow for efficient and effective orthodontic treatment means to obtain the desired treatment results, in a shorter period of time, with fewer adjustment appointments. The following case report demonstrates combining the SmartClipTM SL3 Self-Ligating Appliance, with the use of a soft-tissue laser to provide effective and efficient treatment in an adolescent patient.

Diagnosis and Treatment Plan

A 13-year-old female presented with the chief complaint of “eye teeth have not come in.” Clinical examination revealed Class I malocclusion with impacting and blocked out maxillary right and left canine teeth, an increased overbite, and mild maxillary and mandibular tooth-size-arch-length discrepancy (Figure 1A-J). A large midline maxillary diastema was present, with a heavy frenum. Cephalometric analysis revealed well-balanced skeletal relationship with retroclined maxillary and mandibular incisor teeth. Comprehensive orthodontic treatment using fixed appliances was presented. In order to allow for efficient treatment progression, it was advised to use a soft tissue laser to expose the maxillary right and left canine teeth, as well as to remove the frenum to avoid future recurrence of the maxillary diastema.

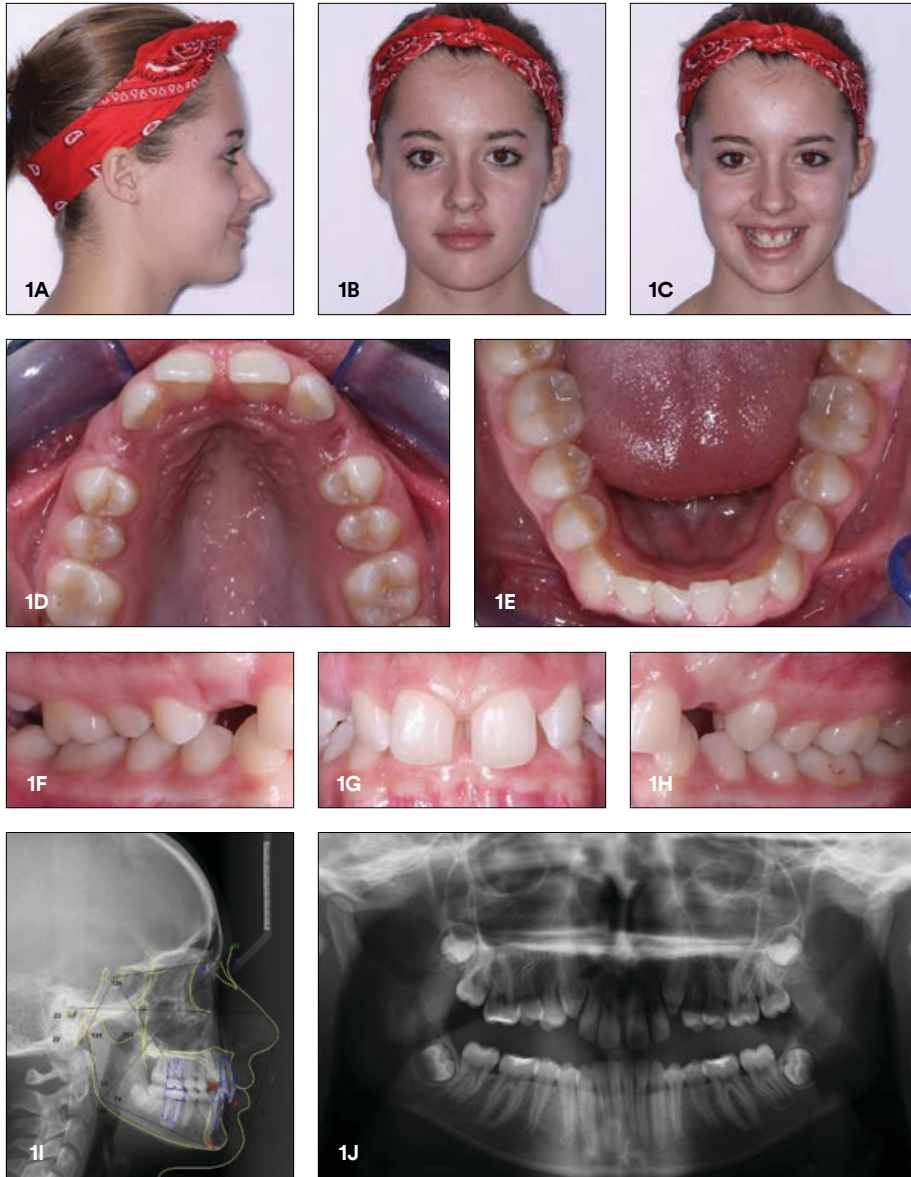


Figure 1A-J

Treatment Progress

Fixed appliances (.022x.028 SmartClip™ SL3 Self-Ligating brackets) were bonded and leveling and aligning was initiated. To assist with the improvement of the inclination of the maxillary and mandibular incisors, Variable Prescription Orthodontic (VPO) high-torque prescription was used in this specific case. The passive self-ligating appliances offered the advantage of reduced friction which often occurs during guided eruption of high canine teeth when ligated brackets are used. An initial aligning wire of .014 SE Nitinol was used immediately after initial bonding, and upon return of the patient for the first adjustment appointment, a combination of .014/.016 SE Nitinol Tandem wires were used. Open coil springs were placed to increase the space for the eruption of the maxillary canines, and a light chain module was used to reduce the size of the diastema (Figure 2). Once sufficient space was created for the eruption of the canine teeth, the tips of these teeth erupted into the oral cavity (Figure 3). In order to improve treatment efficiency

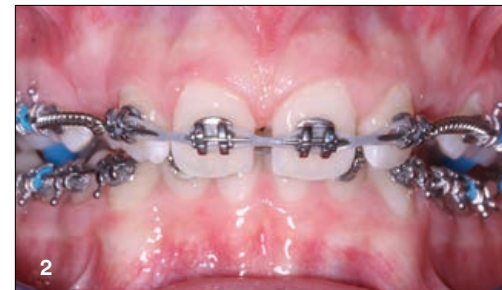

Figure 2

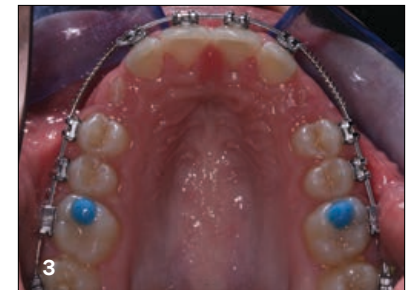

Figure 3

and allow for ideal bracket placement, a soft-tissue laser was used to expose adequate clinical crown space, and the maxillary canine brackets were placed with ideal bracket positioning. Tandem wire mechanics were used to guide the canine teeth into the arch. The .014 SE Nitinol wire was used to engage the canine brackets, while the .016 SE Nitinol wire was used in conjunction with passive Nitinol open coil springs to maintain the spaces for the eruption of the canines (Figure 4A-C).

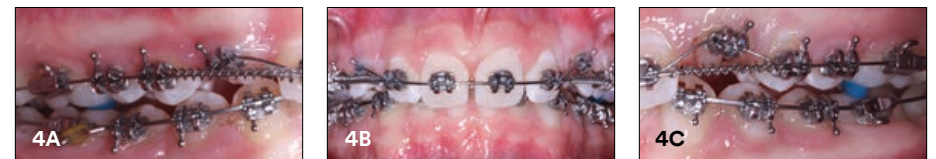

Figure 4A-C

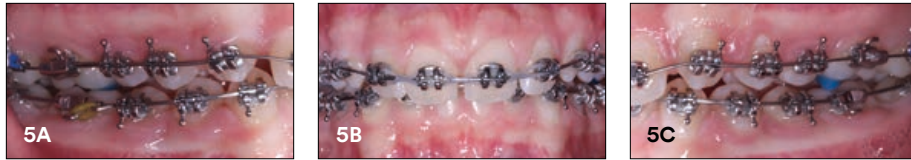

Figure 5A-C

As the canine teeth moved further into the arch, both tandem wires were engaged in the canine brackets for final leveling and alignment (Figure 5A-C). Wires were sequenced next to .019x.025 Heat-Activated Nitinol wires, before a mid-treatment panorex was taken to assess root position. Occlusion was detailed with the final working wires of .019x.025 Beta Titanium, and intermaxillary elastics. A fixed mandibular retainer was placed prior to the debond appointment, and removal of the maxillary frenum was achieved using a soft-tissue laser.

Treatment Results and Conclusions

The patient was seen for a total of 10 appointments during the 14.5-month active treatment period. Post treatment records revealed a Class I molar relationship with ideal overjet and overbite (Figure 6A-J). It was recommended to have the gingival margins of the maxillary incisors assessed one year after removal of the appliances for a possible gingival contouring to obtain optimal smile esthetics. However, at a subsequent retainer check appointment, the gingival inflammation had subsided and a gingivectomy was not deemed necessary (Figure 7A-H). A cephalometric superimposition indicated improved incisor inclination of the maxillary and mandibular incisor teeth. The use of VPO high-torque prescription allowed us to achieve this treatment goal in a relatively short treatment time, as the increased torque value accounts for the “slop” in the system and the loss of torque during routine orthodontic treatment as we rarely finish in a full-size .021x.025 wire (Figure 8). The increased torque value of the brackets utilized allowed us to finish with our .019x.025 wire, while obtaining the desired treatment torque values without the need for additional detailing bends and resulting increased treatment time.

In today’s competitive orthodontic landscape, patients want speedy treatment options. However, we should not provide expedient treatment in exchange for a reduction of treatment quality. Instead, we should aim to utilize the tools that allow for esthetic and functional treatment results, in an effective and efficient manner. This case is an example of using the SmartClip SL3 Self-Ligating Appliance, combined with Variable Prescription Orthodontics and soft-tissue lasers to provide the patient with a smile that will last a lifetime.

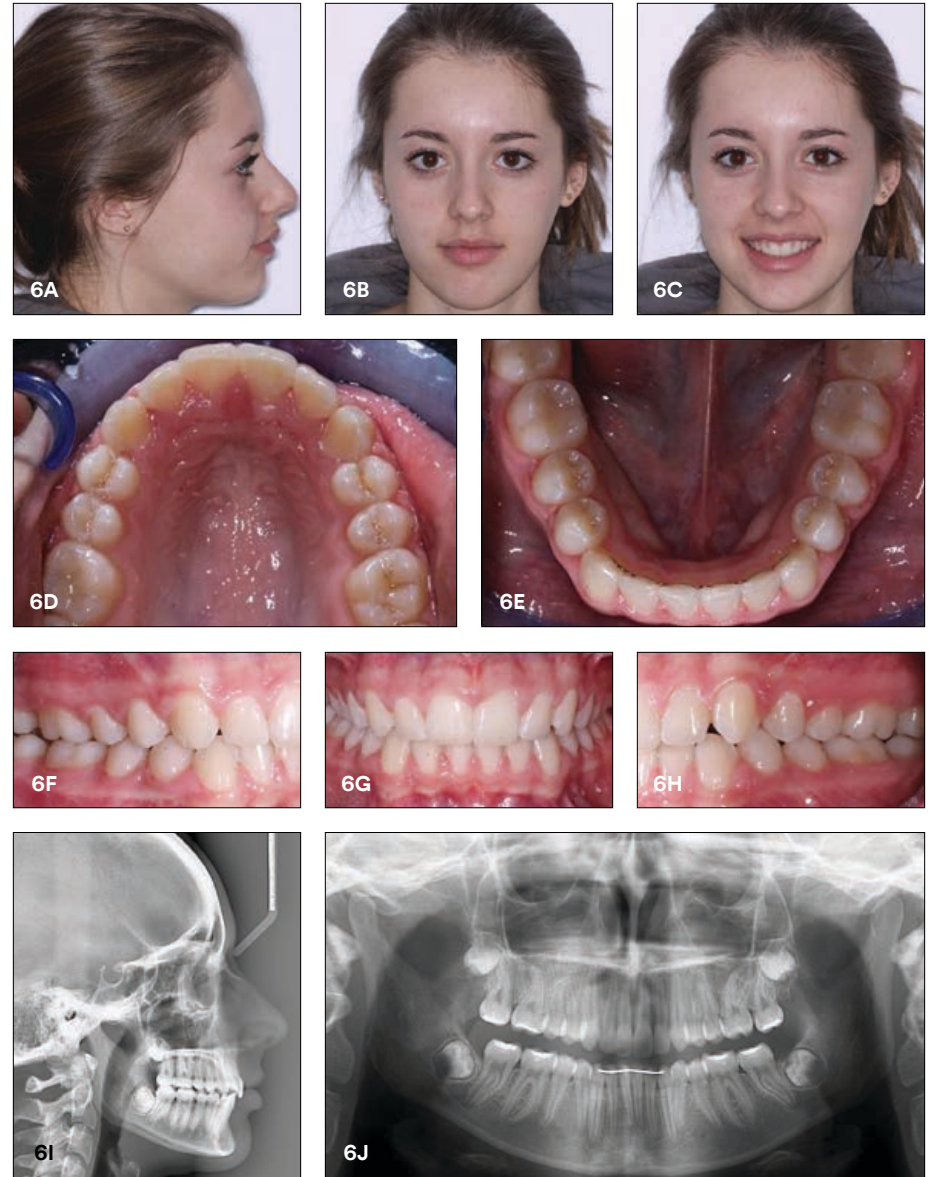


Figure 6A-J

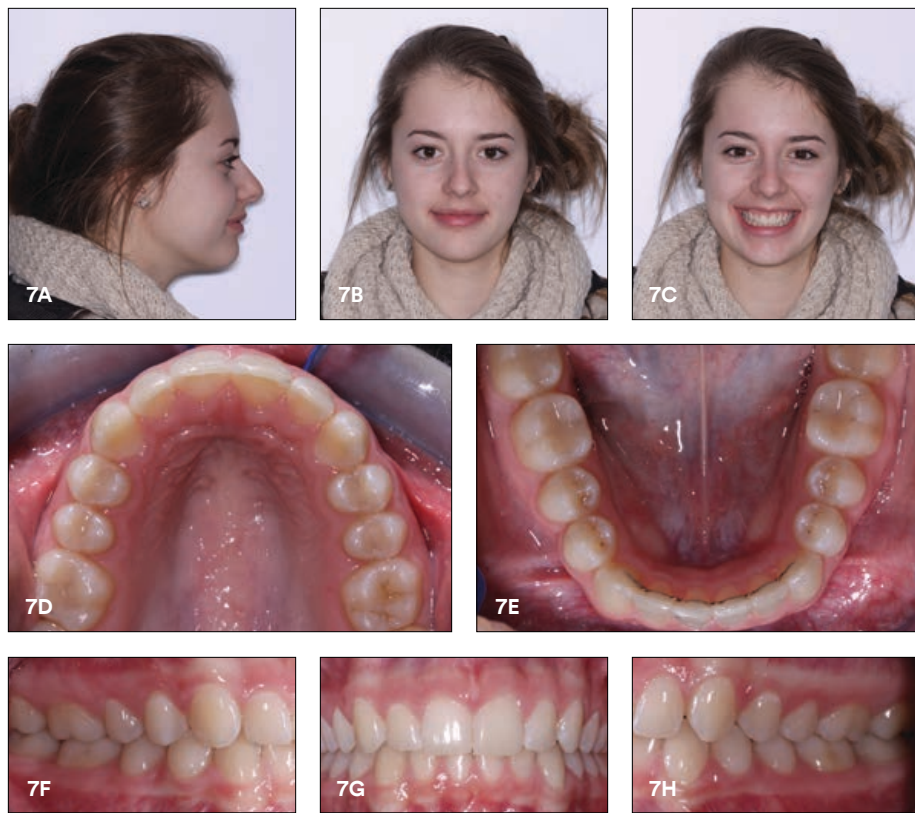

Figure 7A-H

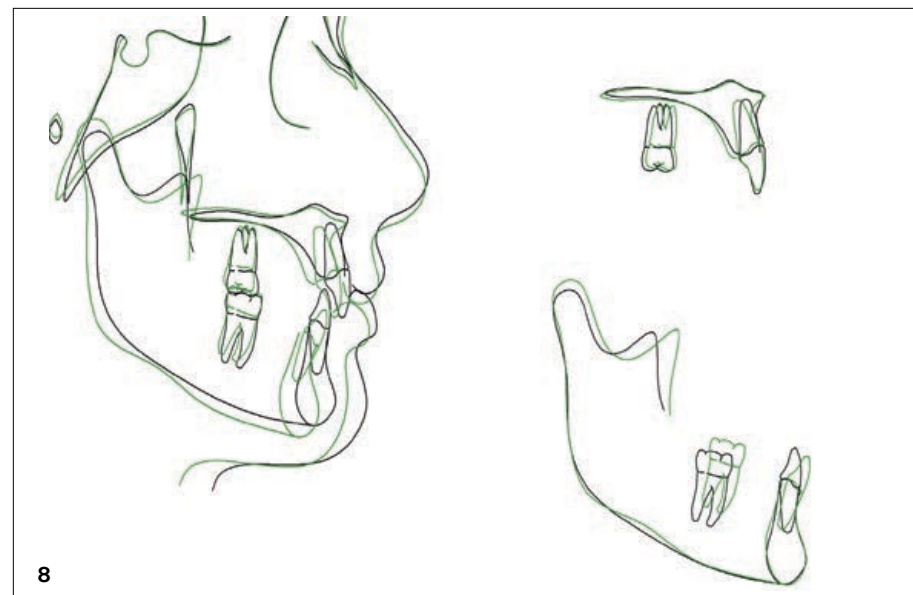


Figure 8

Case photos provided by Dr. Moe Razavi.

3MSM Health Care Academy

Eight Keys for Successful and Efficient Treatment with SmartClipTM and ClarityTM SL Appliances

SMARTCLIPTM | SL3
SELF-LIGATING APPLIANCE SYSTEM

CLARITYTM | SL
SELF-LIGATING APPLIANCE SYSTEM



Dr. Gilad Har-Zion

Dr. Gilad Har-Zion received a D.M.D. in 1992, and the MSc. (Magna cum laude), Specialist in Orthodontics in 2001 from Hebrew University, Jerusalem.

1999- Private and public practices – Orthodontics.

2000- Instructor in graduate course in Orthodontics, Hebrew University, Jerusalem, Israel

2008- Member of the committee for board examinations in Orthodontics, the Israel Dental Association.

2006- Examiner in phase II board examinations in Orthodontics, the Israel Dental Association.

Dr. Har-Zion has been practicing with the MBTTM Appliance System since 2000, and the SmartClipTM and ClarityTM SL Self-Ligating Systems since 2004. Current research includes friction in self-ligating brackets as well as clinical phenomena associated with various self-ligating systems.

Dr. Har-Zion has lectured and presented posters in Israel, Europe and in USA, and has published several scientific articles in peer-reviewed Orthodontic journals. He serves as a reviewer for several international orthodontic journals. Memberships include: Israel Dental Association, Israel Orthodontic Society, Israel Forum of Lingual Orthodontics, European Orthodontic Society, World Federation of Orthodontists and the American Association of Orthodontists.

The transition to SmartClipTM SL3 Self-Ligating Brackets and/or ClarityTM SL Self-Ligating Brackets can be challenging to the clinician who is only experienced with conventional brackets. This is because the addition of the two Nitinol clips to the familiar twin bracket design not only omits the usage of elastic modules and/or metal ligatures, it in fact creates a completely different appliance system. In many aspects, this appliance has different characteristics when compared to conventional appliances. Therefore, the aim of this article is to clarify some of the differences between the systems and to supply clinicians with several guidelines which will enable them to deliver successful and efficient treatment with these appliances.

Don't change your diagnostic regimens or treatment plans!

SmartClip and Clarity SL brackets form marvelous appliance systems. Yet, there is no magic in them. Using these brackets will not turn an extraction case into a non-extraction case since they cannot create space in the arch out of nowhere. Furthermore, these appliances will not eliminate the usage of expanders, headgear or functional appliances. So, if your case dictates any of the above, do not hesitate to employ it.

Don't use your old archwires with the SmartClipTM and ClarityTM SL Appliances

It is highly recommended to use the archwires which were specially designed and developed for use with these systems (Figure 1). These specialized archwires significantly differ from the archwires used with conventional bracket systems.

Firstly, the initial archwires are more elastic and exert weaker levels of force. This is due to the fact that SmartClip and Clarity SL are binary brackets in nature¹. This means that there are only two possible positions of the archwire relative to the bracket. The archwire can either be outside the lumen of

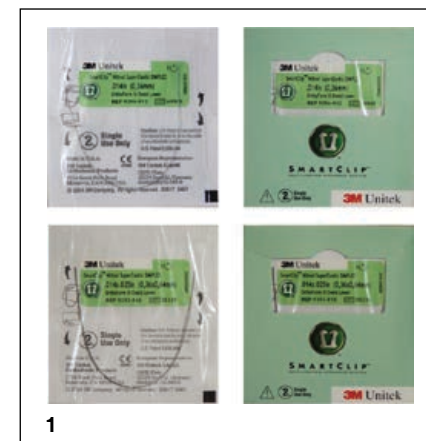

Figure 1: 3M special archwires for SmartClipTM /ClarityTM SL Appliances.

the bracket or it can be clipped and be contained by the lumen of the bracket. In other words, unlike conventional brackets, it is not possible to only half engage the archwire to the bracket. Consequently, in order to enable clipping of the initial archwires into SmartClip/Clarity SL brackets bonded to malaligned teeth, and to prevent spontaneous disengagement of the clipped archwire, the initial archwires must be very soft and elastic. In addition, due to the fact that frictional resistance is very low in SmartClip and Clarity SL appliances, smaller force levels are needed to overcome the frictional resistance within the system. Hence, the specialized archwires apply weaker forces in comparison with their conventional members.

Secondly, many of the initial and intermediate archwires developed for these systems include a built-in stop (Figure 2). This is to prevent the archwire from sliding to one side of the bracket system while disengaging from the distal attachment on the opposite side (“snaking”). A phenomenon which is very common with SmartClip and Clarity SL appliances owing to the minute frictional resistance in these systems.

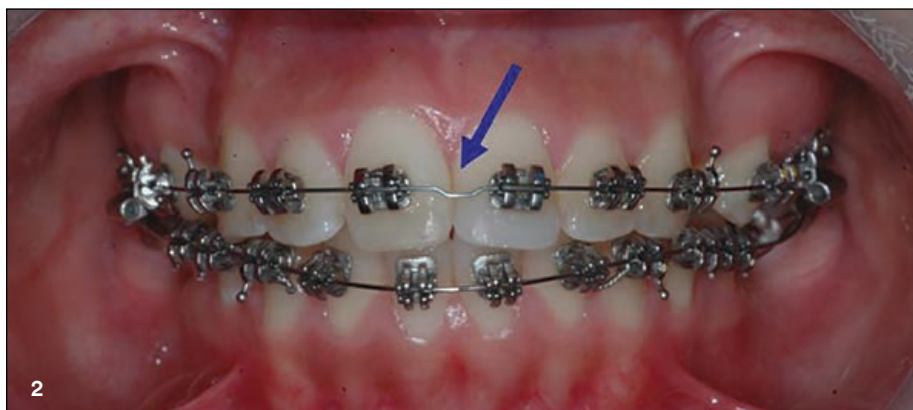

Figure 2: A central stop on an archwire in order to prevent “snaking.”

Thirdly, some of the specialized archwires have unique dimensions (i.e. 0.014"×0.025"; 0.016"×0.025"). The rationale is that when a small diameter archwire is inserted into a SmartClip/Clarity SL bracket it is not forced into the bottom of the slot as in conventional ligation. Hence, a leeway is created between the archwire and the lumen of the bracket (Figure 3). This leeway enables several degrees of play in this archwire-bracket combination and therefore prevents complete rotational control. Consequently, it is necessary to fill the depth of the slot by increasing the wire size in the bucco-lingual dimension.




Figure 3: In SmartClip™/Clarity™ SL Brackets, a small diameter archwire is not forced into the bottom of the slot.





Figure 4A: A conventional rectangular archwire impinges against the Nitinol clips due to lack of parallelism with the slot of the bracket. **Figure 4B:** In order to be inserted into the bracket a conventional rectangular archwire must be torqued parallel to the slot of the bracket.



And finally, hybrid archwires can be of great help in these systems. Hybrid archwires are rectangular archwires in which the corners have been rounded. They were designed specifically in order to eliminate the difficulty of engaging rectangular archwires into a SmartClip/Clarity SL bracket. The problem with conventional rectangular archwires is that, unless the archwire is aligned almost parallel with the bracket slot, it will be stuck against the Nitinol clips which will prevent the insertion of the archwire into the bracket (Figure 4A-B). Owing to their rounded corners, there is less need to align hybrid archwires parallel to the bracket slot so they are much easier to engage.

Don't try to implement your former archwire sequence with these appliances

It is much better to use one of the recommended archwire sequences.^{1,2} Cases must be started using thin soft round archwires. It is well known that every archwire bracket combination has a critical contact angle for binding (\emptyset) in the vertical (occluso-gingival) dimension.^{3,4} However, due to the fact that in SmartClip/Clarity SL brackets the locking mechanism is relatively rigid they also have a critical contact angle for binding in the horizontal (bucco-lingua) dimension.^{5,6} In order to avoid binding and enable quick and efficient leveling and alignment these critical contact angles must not be exceeded. One of the ways to accomplish that is by starting cases with thin soft round archwires. It also implies that Burstone's concept of “variable-modulus orthodontics”⁷ (i.e. starting cases with soft thick rectangular archwires which are later replaced by stiffer archwires with the same dimensions), is not applicable for SmartClip/Clarity SL appliances. This is because thick rectangular archwires will instantly exceed the critical contact angles and thus significantly slow down the velocity of tooth movement.

As mentioned before, complete correction of the initial rotations with small round archwires is not possible with SmartClip/Clarity SL appliances. Consequently, in order to finish the leveling and alignment stage it is necessary to fill the depth of the slot. It can be achieved either by increasing the wire size or by inserting another small diameter archwire on top of the first one thus almost completely filling the slot in the bucco-lingual dimension; a technique coined the *tandem archwire technique*⁸ (Figure 5). This archwire combination enhances rotational control. In addition, it provides better horizontal and vertical control of teeth position (Figure 6A-C).

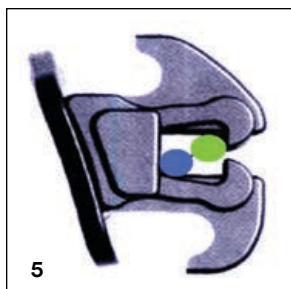


Figure 5: Two small diameter archwires fill the horizontal dimension of a SmartClip™/Clarity™ SL Bracket.

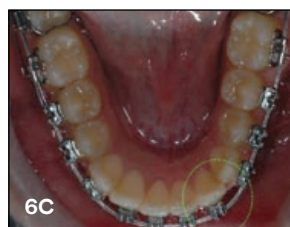
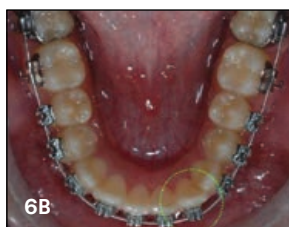
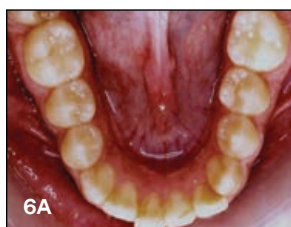

Figure 6A: The initial mal-occlusion. **Figure 6B:** Six weeks after bonding and engaging a NiTi 16 archwire residual rotation of the lower left lateral incisor still persists. **Figure 6C:** Four weeks after engaging a NiTi 14 archwire on top of the NiTi 16 archwire (“tandem technique”) the rotation is corrected.

Owing to the minute frictional resistance in the system β Titanium archwires are capable of delivering all the necessary forces and moments which are required in order to finish a case. Thus, stainless steel archwires are redundant in most non-extraction cases.

Don't apply the same old interappointment intervals

As a matter of fact, it is highly advisable not to use a constant interappointment interval at all!

Ideal and fast expression of archwires within SmartClip/Clarity SL brackets is guaranteed owing to the clips. This is due to the fact that unlike elastic modules, the Nitinol clips do not degenerate with time. Thus, when an archwire is inserted into the brackets the tooth will move until the archwire fully expresses itself. Hence, in comparison with conventional appliances some of the interappointment intervals should be lengthened because there is no need to call the patient for replacing decaying elastic modules, tightening metal ligatures etc. On the other hand, since the level of friction in the system is very low, archwires express themselves much faster and so in certain situations the interval between appointments can be shortened.

The bottom line is that, in order to deliver an efficient and speedy treatment, the clinician must be able to evaluate how much time it is going to take for a specific archwire to fully express itself in a certain situation.

Don't clip the initial archwire in both the clips when teeth are severely malaligned

As SmartClip and Clarity SL Brackets are the only *twin self-ligating brackets*, it is possible to engage the initial archwire in only one of the clips of brackets which are bonded to severely malaligned teeth (Figure 7). Thus, increasing inter-bracket span and archwire flexibility while reducing the contact angles in the vertical and horizontal dimensions.⁹

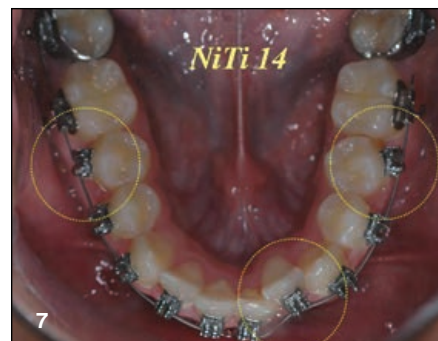


Figure 7: After bonding, a NiTi 14 archwire is clipped only to one clip in severely malaligned teeth.

When engaging thick NiTi and stainless steel archwire make sure that they are completely engaged in all the clips

As mentioned before, unlike conventional brackets, partial engagement of the archwire relative to SmartClip/Clarity SL bracket slot is not possible. For that reason, thick archwires which are not fully clipped will be pressed against the Nitinol clip which will then function as a very effective rotation wedge and will cause the tooth to rotate! (Figure 8) This rotation is very hard to correct in the advanced stages of treatment as thick archwires are usually too stiff to be inserted into the bracket slot of a rotated tooth. So, the clinician is compelled to regress to a smaller archwire in order to pick up the rotated tooth while unnecessarily elongating treatment time. Therefore, it is of utmost importance not to dismiss the patient before checking and double-checking that the thick archwire is fully clipped throughout the arch!

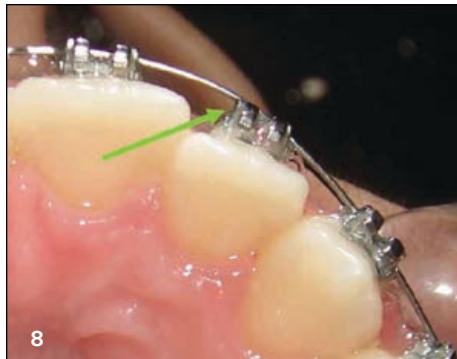


Figure 8: An upper left lateral incisor which rotated because the mesial clip of the bracket was not completely clipped in the former appointment!

During space closure the incisors must be tied to the archwire in order to maintain torque control

Some clinicians using SmartClip/Clarity SL appliances try to reduce the friction throughout the space closing stage employing different tactics. Two of these strategies include placing an elastic chain under the archwire or tying the anterior six teeth with a “figure of 8” metal ligature under the archwire followed by connecting an elastic chain/Nitinol spring/tie back between the distal molar and the hook of the canine bracket. The trouble with the above method is that while the spaces are being closed, the archwire is being pushed away from the bottom of the slot (Figure 9A-C), so a great deal of torque is being lost! (Figure 10A-C) As a result, in order to maintain

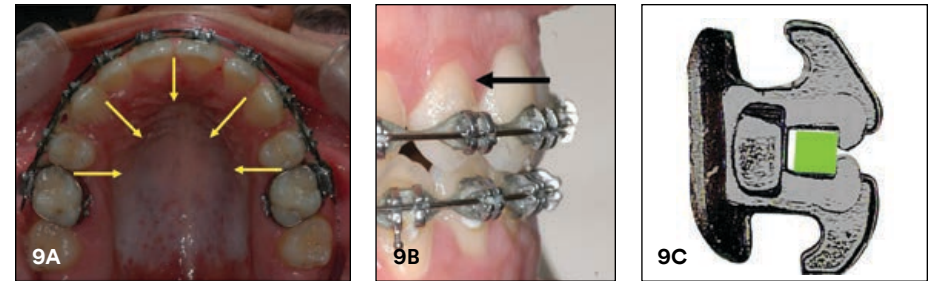


Figure 9A: When spaces are closed using a continuous elastic chain a constricting force is created upon the dental arch. **Figure 9B:** In the anterior area this force tends to pull the incisors in a distal direction. **Figure 9C:** As a result the archwire is forced against the Nitinol clips.

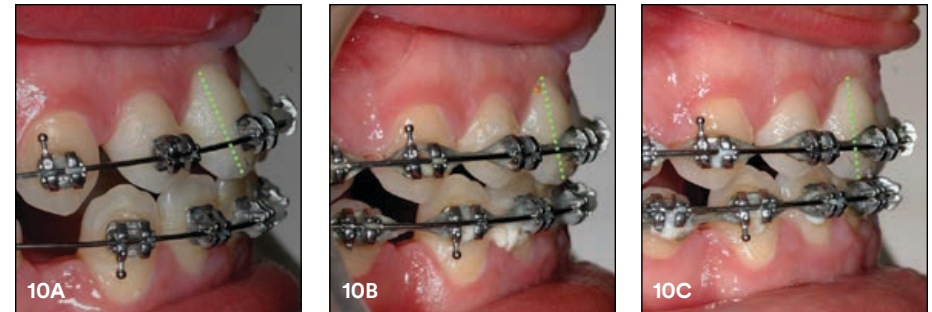


Figure 10A: The beginning of the space closure stage. The spaces were closed with a continuous elastic chain which was placed under a S.S. 19x25 archwire. **Figure 10B:** 9 weeks into the space closure stage. Loss of torque control of the incisors is obvious. **Figure 10C:** 19 weeks into the space closure stage. The incisors are still losing torque.

torque control it is imperative to push the archwire into the depth of the slot of the anterior brackets. That can be achieved by adding elastic modules or a metal ligature over the archwire in the anterior brackets (Figure 11). Another possible way is to close spaces utilizing posted stainless steel archwires in combination with an elastic chain/Nitinol spring/tie back between the distal molar and the post (Figure 12A-B). Such a system combines a low friction retraction force together with an anterior component of force which pushes the archwire into the depth of the slot of the anterior brackets. In this manner, closing spaces and controlling torque is achieved at the same time.

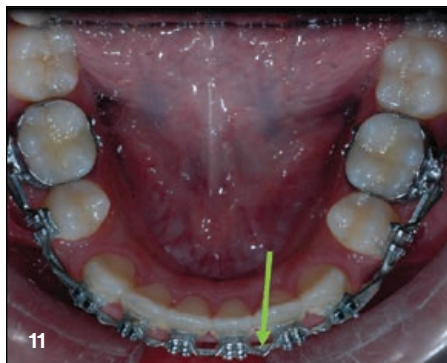


Figure 11: During space closure a stainless steel ligature is tied over the archwire in order to push it against the bottom of the slot.

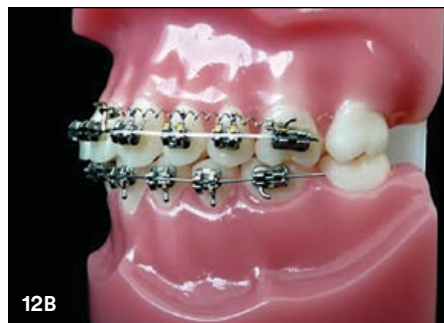
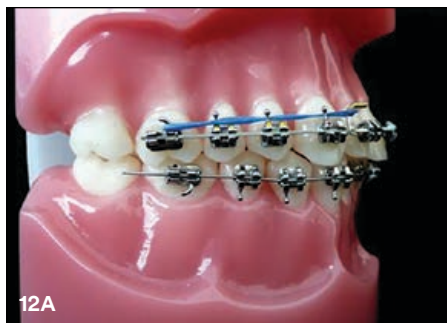

Figure 12A-B: Space closure technique utilizing a posted S.S. 19x25 archwire.

Using ligatures and/or elastic modules can be very beneficial on certain occasions

Thanks to their familiar twin design both SmartClip and Clarity SL brackets possess the “active on demand” feature. In other words, these passive self-ligating brackets can be easily activated by tying an elastic module/metal ligature.¹ That aspect can be very useful in clinical situations which demand precise control of teeth positions, namely the finishing stages.

Elastic modules/metal ligatures can also be selectively used when engaging thin archwires with SmartClip/Clarity SL appliances in order to push the archwire into the depth of the slot to achieve/maintain alignment on these archwires, which do not fill the horizontal dimension of the bracket.

In the initial stages of treatment, elastic modules/metal ligatures can be utilized in order to loosely tie a very remote tooth to the archwire just like with conventional brackets. In addition, elastic chains can be connected to the brackets and used as an adjunct to derotate severely rotated teeth.

As the treatment advances, it is highly recommended to secure teeth that were extremely rotated initially with an elastic module/metal ligature in order to prevent disengagement from the archwire and rapid relapse of the rotation.

Following the aforementioned keys can certainly help the astute clinician avoid some of the most common mistakes which are so prevalent with the transition from conventional appliances to SmartClip and/or Clarity SL appliances. It will also help him exploit the many advantages which these unique systems offer.

Acknowledgment: The author would like to thank Dr. Ziva M.L. Lurie for her help with the manuscript.

Case photos provided by Dr. Gilad Har-Zion.

References

1. Sondhi A.; Smart Things to Know About the SmartClip™ Self-Ligating Appliance System. Orthod. Perspec. 2007; 14: 4-9.
2. Weinberger GL.; An Optimized Treatment Protocol (OTP) for the SmartClip™ Self-Ligating Appliance System. 3M Unitek. 2007; 10-12.
3. Kusy RP, Whitley JQ.; Assessment of Second-Order Clearances Between Orthodontic Archwires and Bracket Slots via the Critical Contact Angle for Binding. Angle Orthod. 1999; 69: 71-80.
4. Thorstenson GA.; SmartClip™ Self-Ligating Brackets Frictional Study. Orthod. Perspec. 2005; 12: 8-11.
5. Reznikov N, Har-Zion G, Barkana I, Abed Y, Redlich M.; Influence of Friction Resistance on Expression of Superelastic Properties of Initial NiTi Wires in “Reduced Friction” and Conventional Bracket Systems. J. Dental Biom. 2010; 613142.
6. Reznikov N, Har-Zion G, Barkana I, Abed Y, Redlich M.; Measurement of Friction Forces Between Stainless Steel Wires and “Reduced Friction” Self-Ligating Brackets. Am. J. Orthod. Dentofacial Orthop. 2010; 138: 330-338.
7. Burstone CJ.; Variable-Modulus Orthodontics. Am. J. Orthod. 1981; 80: 1-16.
8. Rodrigue C.; The Tandem Archwire Technique: Enhanced Rotational Control with 3M™ Self-ligating Appliances. Orthod. Perspec. 2008; 15: 3-5.
9. Har-Zion G.; Self-Ligation: A Clinician's point of View. Am. J. Orthod. Dentofacial Orthop. 2009; 136: 756-757.

3MSM Health Care Academy

Class I Crooked teeth, crowding, midline discrepancy

This case is a sample of the cases contained in the newly published Clarity™ ADVANCED Ceramic Bracket Case Overview booklet. To view the complete publication, visit 3M.com/ortho and follow the links to the Clarity ADVANCED Brackets page.



Dr. Patrice Pellerin

Dr. Pellerin received his post graduate Certificate in Orthodontics in 1991 from the University of Montreal. Before orthodontics, he practiced general dentistry for four years after earning his dental degree from the University of Montreal in 1985. Since 1991, he has maintained a solo private practice in Lachine, Quebec. In 1998, Dr. Pellerin converted his practice to a fully aesthetic practice.

He is referred to by his peers as the grandfather of the completely aesthetic practice. He has lectured worldwide to share his practice philosophy of highest aesthetics without compromise to accomplish treatment. Dr. Pellerin also currently teaches lingual and aesthetic orthodontics to the residents at the University of Montreal and University of Winnipeg. He has been an active member of the 3M Unitek Advisory Committee for Aesthetic Appliances since 2003, as well as a 3M Advocate for the use of aesthetic appliances since 2004.

Patient

Female (M.D.L.); 20 years, 3 months

Patient's Main Concern

Crooked lower front teeth, and too long and too forward upper front teeth

X-ray Findings

- Complete permanent dentition
- Pneumatized maxillary sinuses
- Evidence of formation of wisdom teeth

*Patient should have removed earrings before X-ray

Dental Analysis

- Class I with a light Class II relationship on the left side
- Light to moderate crowding in both arches
- Midline discrepancy
- Narrow upper jaw

Treatment Plan

- Upper/Lower – Clarity™ ADVANCED Ceramic Brackets 0.018 slot – MBT™ System prescription (APCFF')

- Bonding charts: Upper MBT System open bite 4.5 mm/Lower MBT System open bite 4.5 mm
- Use of a half bracket² on LL1
- Light Class II elastics to correct the Class II relation
- Indirect Bonding Double Clear Tray Technique

Treatment	12 months (April 2013 – April 2014)		
Mx	April 2013	Indirect	14 SE ³ (5s), 16×22 SE (4s), 17×25 Classic ⁴ (26s), 16×16 SE (4s), 17×25 Classic to the end
Md	April 2013	Indirect	14 SE (13s), 18 SE (6s), 16×22 SE (11s), 17×25 Classic (7s), 16×16 SE (5s), 17×25 Classic to the end
# of visits	13		
Emergencies	0 ⁵		

Retention

- Fixed lingual wires 0.018 TMA
- Upper canine to canine/Lower first bicuspid to first bicuspid

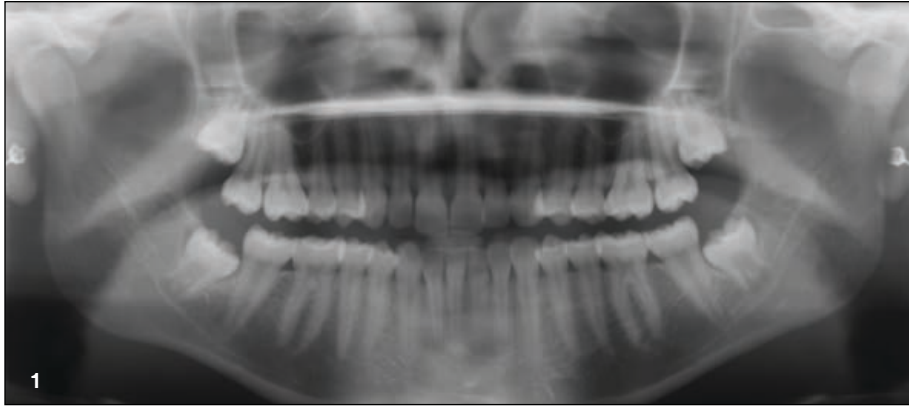


Figure 1: Initial X-ray.

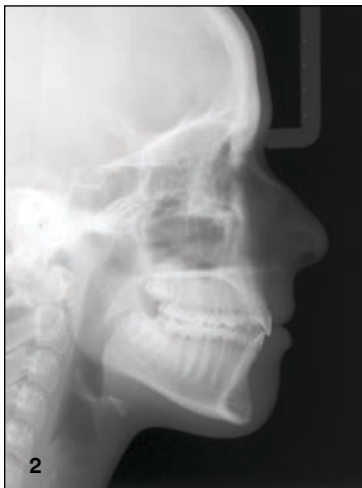

Figure 2: Initial cephalometric analysis.

Cephalometric Analysis					
SNA (°)	82.4	82.0	3.5	0.1	
SNB (°)	76.6	80.9	3.4	-1.3	*
ANB (°)	5.7	1.6	1.5	2.7	**
Maxillary Depth (FH-NA) (°)	91.4	90.0	3.0	0.5	
Facial Angle (FH-NPo) (°)	86.5	88.6	3.0	-0.7	
FMA (MP-FH) (°)	27.9	23.9	4.5	0.9	
UFH:LFH, Upper (N-ANS/N-Gn) (%)	43.3	45.0	1.0	-1.7	*
U-Incisor Protrusion (U1-APo) (mm)	2.2	6.0	2.2	-1.7	*
U1 – Palatal Plane (°)	104.0	110.0	5.0	-1.2	*
L1 Protrusion (L1-APo) (mm)	-1.0	2.7	1.7	-2.2	**
IMPA (L1-MP) (°)	91.2	95.0	7.0	-0.5	
Interincisal Angle (U1-L1) (°)	136.2	130.0	5.0	1.2	*
Upper Lip to E-Plane (mm)	-4.9	-6.0	2.0	0.5	
Lower Lip to E-Plane (mm)	-2.2	-2.0	2.0	-0.1	
Nasolabial Angle (Col-Sn-UL) (°)	124.9	102.0	8.0	2.9	**
Maxillary length (ANS-PNS) (mm)	51.2	51.6	4.3	-0.1	
Mandibular length (Go-Gn) (mm)	73.1	65.9	5.5	1.3	*
Facial Convexity (G'-Sn-Po') (°)	160.9	154.0	5.6	1.2	*
Wits Appraisal (mm)	3.6	-1.0	1.0	4.6	****
SUMMARY ANALYSIS					
Class II Molar Relationship					
Skeletal Class II (A-Po)					
Skeletal Class II (ANB)					
Retrusive Mandible (Pg-N)					

Table 1: Cephalometric analysis.

Initial

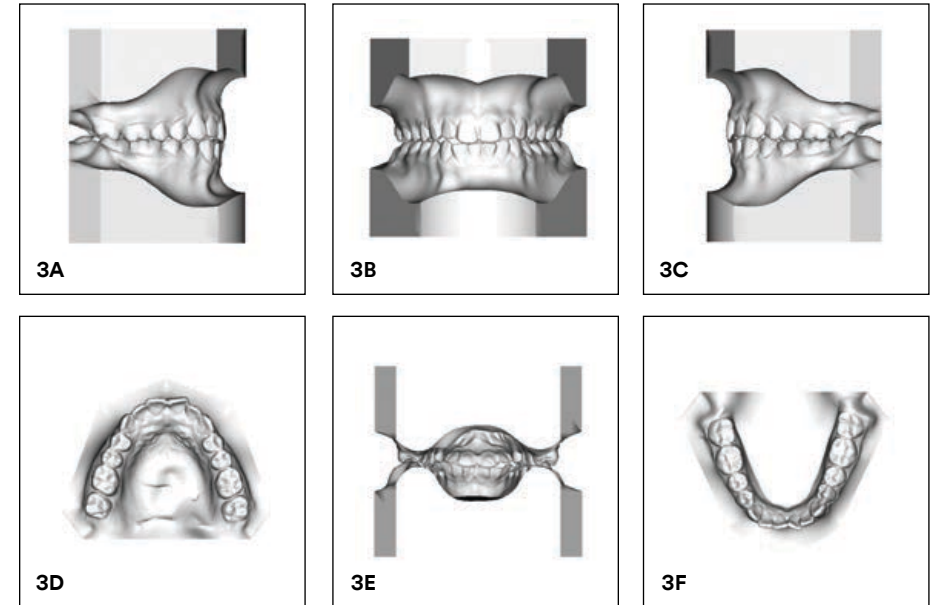


Figure 3A-F: Initial dental analysis.

Initial

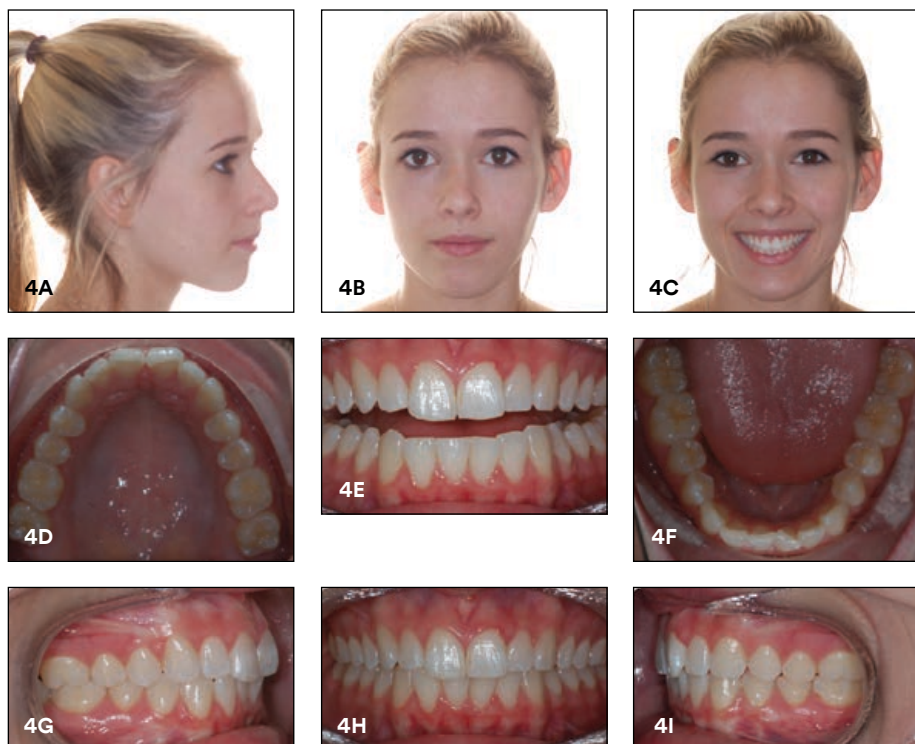

Figure 4A-I: Initial photos.

Clarity™ ADVANCED Ceramic Brackets – Half Brackets

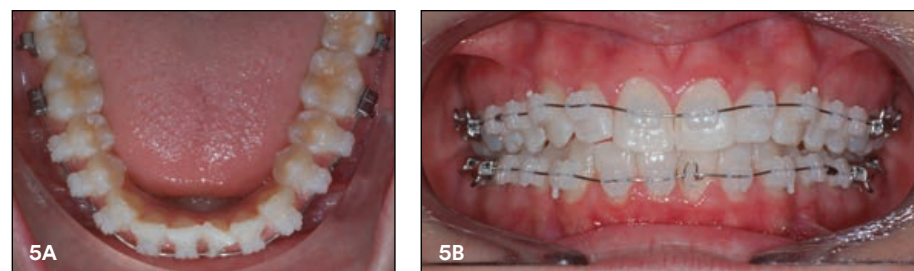


Figure 5A-B

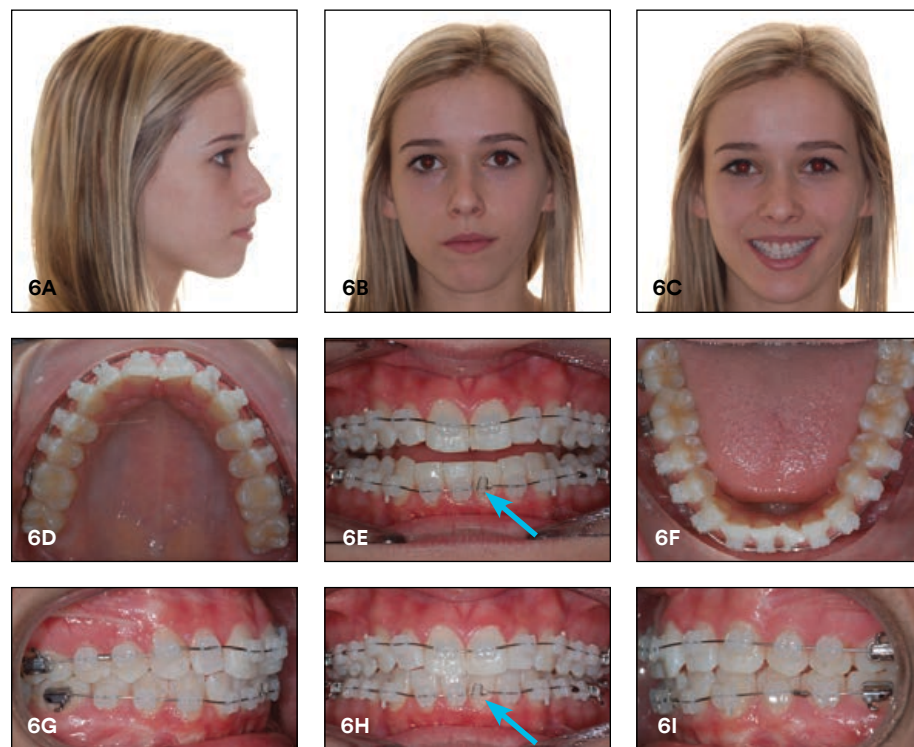

Figure 6A-I

Mid-Treatment

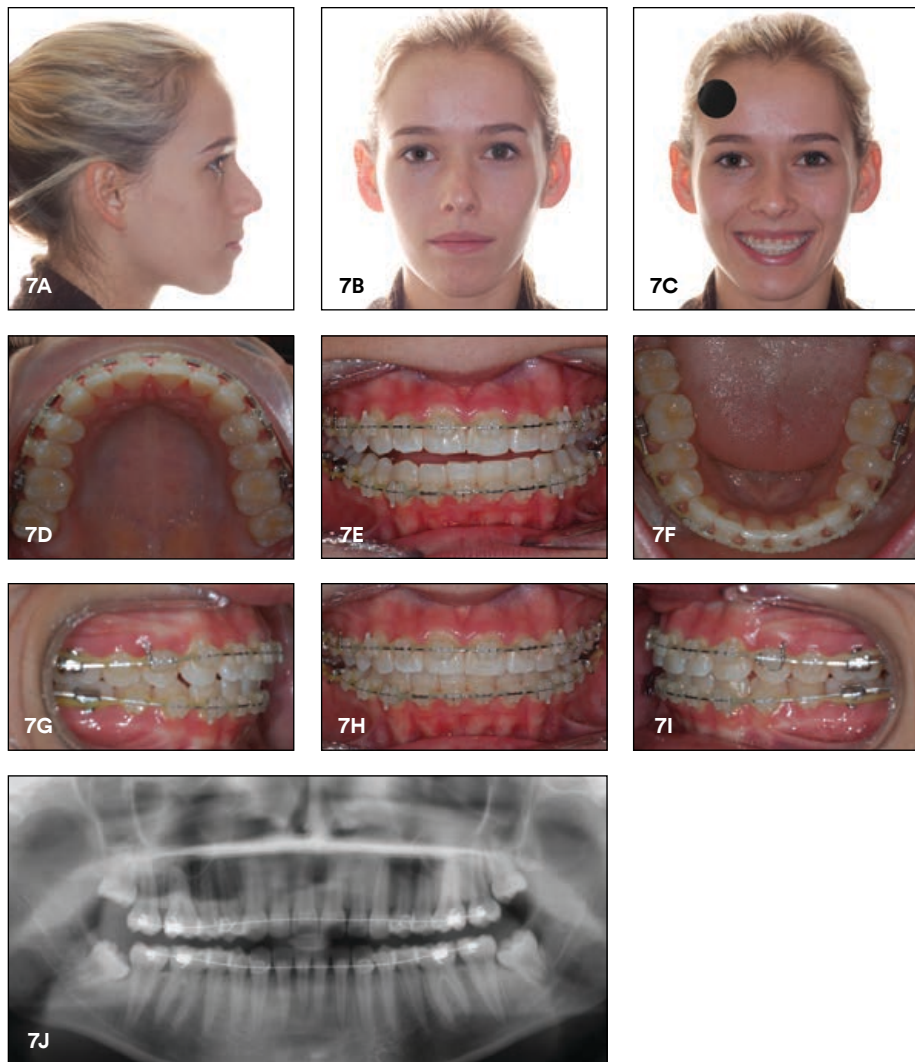


Figure 7A-J: Mid-treatment photos.

Retention

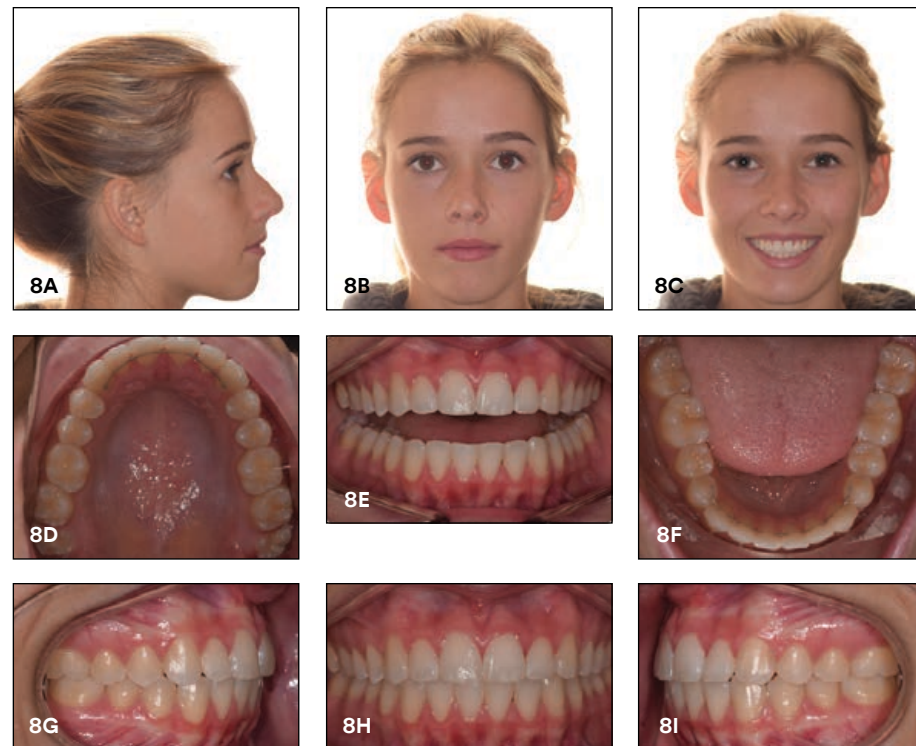

Figure 8A-I: Retention photos.

Initial vs. Final




Figure 9A-B: Initial vs. final photos.

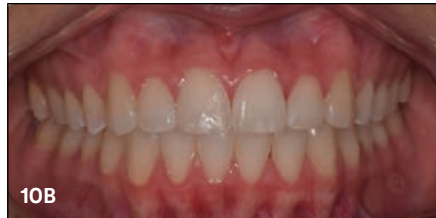
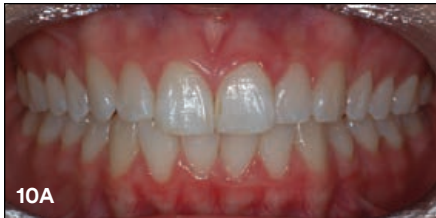
Figure 10A-B: Initial vs. final photos.

Doctor's Notes

1. **APCFF** denotes **APC™ Flash-Free Adhesive Coated Appliance**
2. If a severe rotation doesn't allow you to position a normal bracket in the proper position on the tooth, one may choose to first open the space with coil or use an eyelet or buttons. Once the rotation is corrected and there is access, a regular bracket can be positioned.

My preference is to take advantage of a feature unique to all the brackets in the Clarity™ brand bracket family: a pre-serrated bracket base that facilitates consistent and easy debonding. This feature enables the clinician to cut the Clarity bracket in two, allowing access to proper bracket positioning ("LA" point) with torque and angulation control (always depending of the bracket you are using - in this case, a lower anterior bracket with MBT™ Appliance System prescription has no angulation). To do so, simply use a sharp pin and ligature cutter to easily create a smaller bracket with the correct torque and angulation. The reason to use a "sharp" pin and ligature cutter is not to cut the bracket (they are pre-serrated), but rather to cut the non-woven mat in the case of Clarity™ ADVANCED Brackets with APC™ Flash-Free Adhesive, or the metal slot in the case of a Clarity™ SL Self-Ligating Bracket.

3. **SE** denotes NiTi Super Elastic wire
4. **Classic** denotes NiTi Classic wire
5. Using **APC™ Flash-Free Adhesive with indirect bonding**, no bond failures or emergency appointments during treatment.

Case photos provided by Dr. Patrice Pellerin.

3MSM Health Care Academy

Class II

Aesthetic Treatment with ClarityTM ADVANCED Ceramic Brackets Patient Experienced Failure in Treatment with Aligners

This case is a sample of the cases contained in the newly published ClarityTM ADVANCED Ceramic Bracket Case Overview booklet. To view the complete publication, visit 3M.com/ortho and follow the links to the Clarity ADVANCED Brackets page.



Dr. Anoop Sondhi

Dr. Anoop Sondhi received his dental degree from the Indiana University School of Dentistry, and his post-graduate certificate and M.S. in Orthodontics from the University of Illinois in 1977. Following his graduation, he was on the graduate faculty of the Department of Orthodontics at Indiana University. During his full-time academic appointment at Indiana University, he maintained a part-time private

practice. Since 1988, he has been in full-time private practice in Indianapolis, and continues to be a Visiting Professor for several graduate programs in Orthodontics. He has presented seminars and continuing education courses to several dental and Orthodontic organizations in the United States, and has been invited to give courses in Canada, Central America, South America, Europe, Asia, South Africa, Australia and New Zealand.

Patient

Female; 28 years, 10 months

Patient's Main Concern

Inability to bite posterior teeth together, midline discrepancy. Previous treatment with Invisalign[®] was unsuccessful.

X-ray Findings

- Complete permanent dentition
- Third molars have been extracted
- Atypical root morphology noted on teeth #18, 19, 30 and 31

Dental Analysis

- Asymmetric Class II Division 1 malocclusion
- Right side half cusp Class II
- Left side Class I
- Severe midline discrepancy
- Bilateral posterior open bite

Treatment Plan

- Upper/Lower ClarityTM ADVANCED Ceramic Brackets .018 slot – Variable Prescription

- Molar tube set atypically to upright tooth #19
- Class II elastics on the right side for Class II correction
- Indirect Bonding with SondhiTM Rapid Set Indirect Bonding System
- No emergency appointments

Treatment	13 months (March 2014 – April 2015)		
Mx	4/16/14	Indirect	.016 Nitinol SE .016x.022 Nitinol .016x.022 SS
Md	4/16/14	Indirect	.016 Nitinol SE .016x.022 Nitinol .016x.022 SS
# of visits	6		
Emergencies	0		
Total Treatment Time	11 months		

Retention

- Maxillary and mandibular .040 Essix[®] Retainers

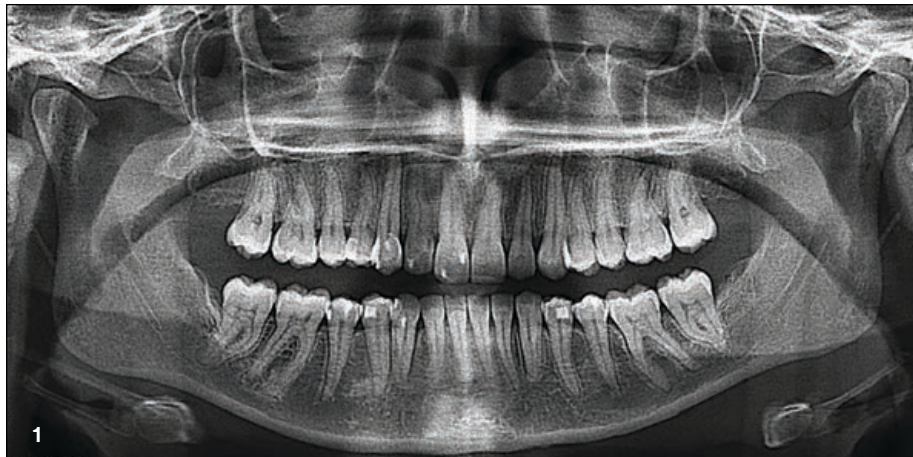

Figure 1: Initial X-ray.

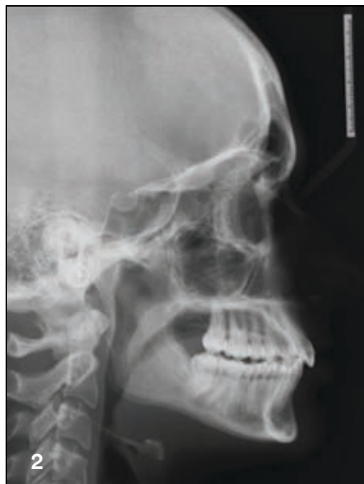

Figure 2: Initial cephalometric analysis.

Initial Analysis					
Skeletal Measurements					
Convexity (NA-APo) (°)	3.4	4.9	3.0	-0.5	
Facial Angle (FH-NPo) (°)	93.8	88.6	3.0	1.7	*
SNA (°)	83.8	82.0	3.5	0.5	
SNB (°)	81.3	80.9	3.4	0.1	
ANB (°)	2.5	1.6	1.5	0.6	
Palatal-Mand Angle (PP-MP) (°)	20.0	25.0	6.0	-0.8	
Y-Axis (SGn-SN) (°)	64.5	67.0	5.5	-0.5	
Dental Measurements					
Occ Plane to FH (°)	-2.6	-11.0	2.0	4.2	****
IMPA (L1-MP) (°)	93.5	95.0	7.0	-0.2	
Wits Appraisal (mm)	-0.5	-1.0	1.0	0.5	

Table 1: Initial analysis.

Initial

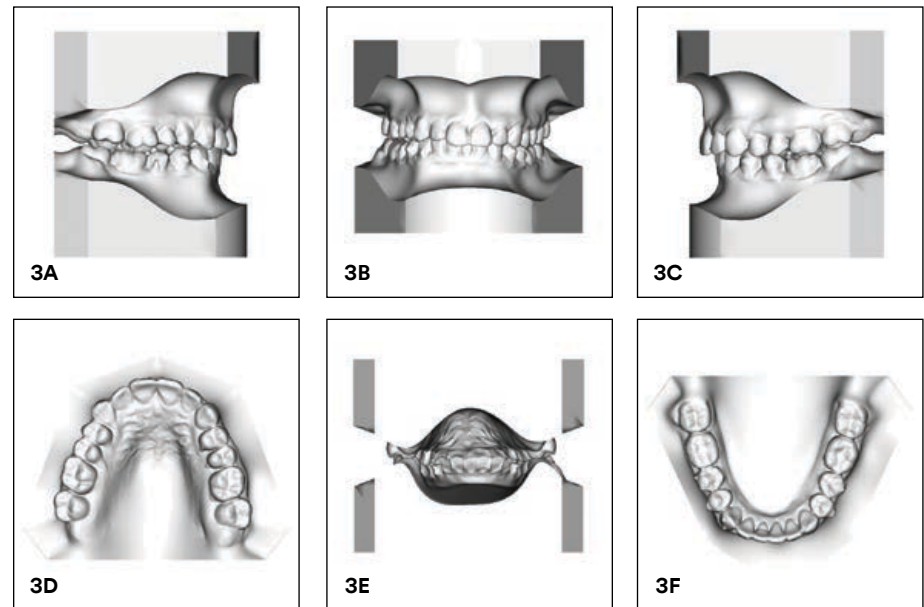


Figure 3A-F: Initial dental analysis.

Initial

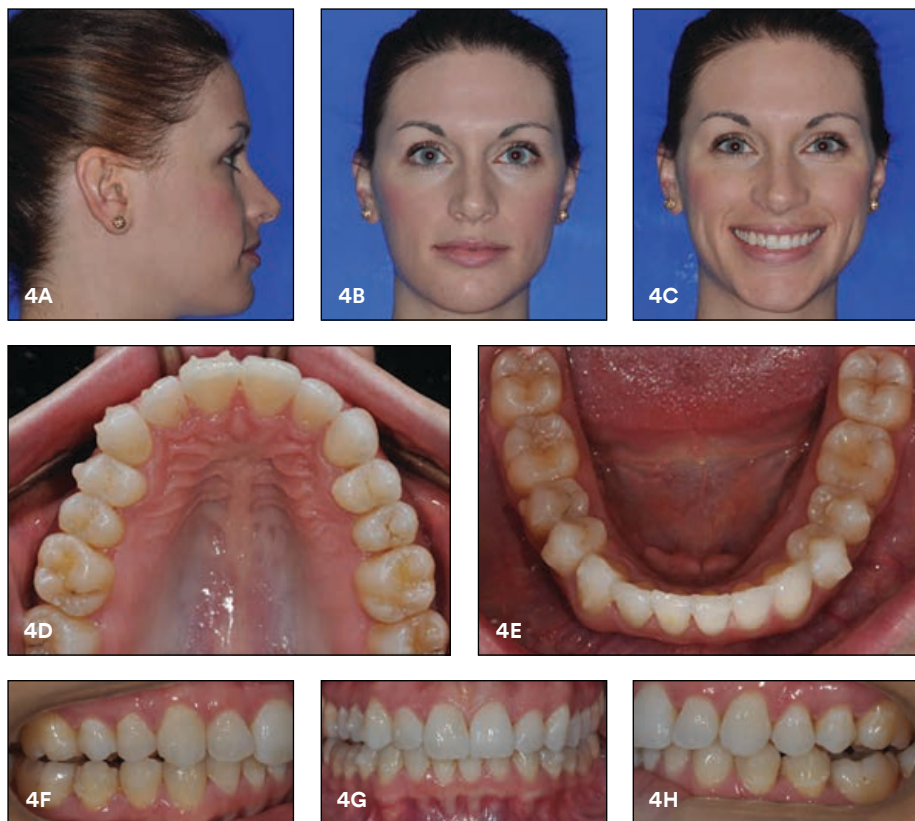


Figure 4A-H: Initial photos.

Mid-Treatment

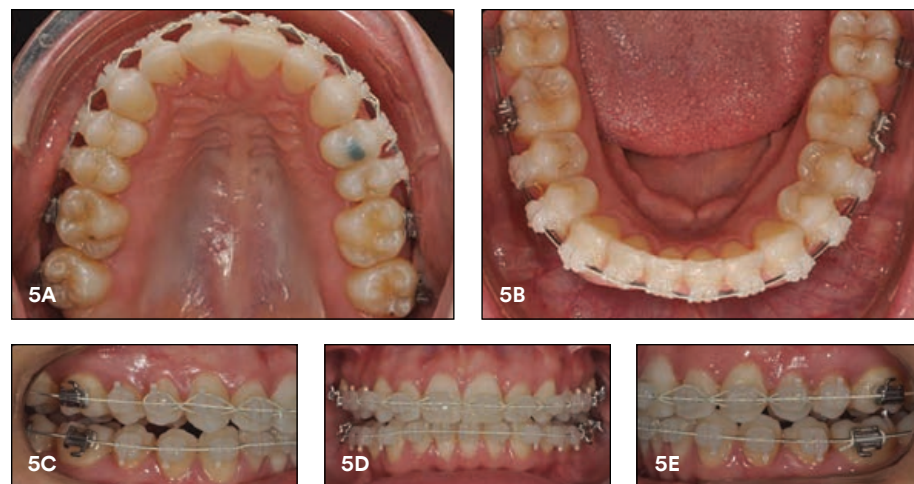

Figure 5A-E: Mid-treatment photos.

Final

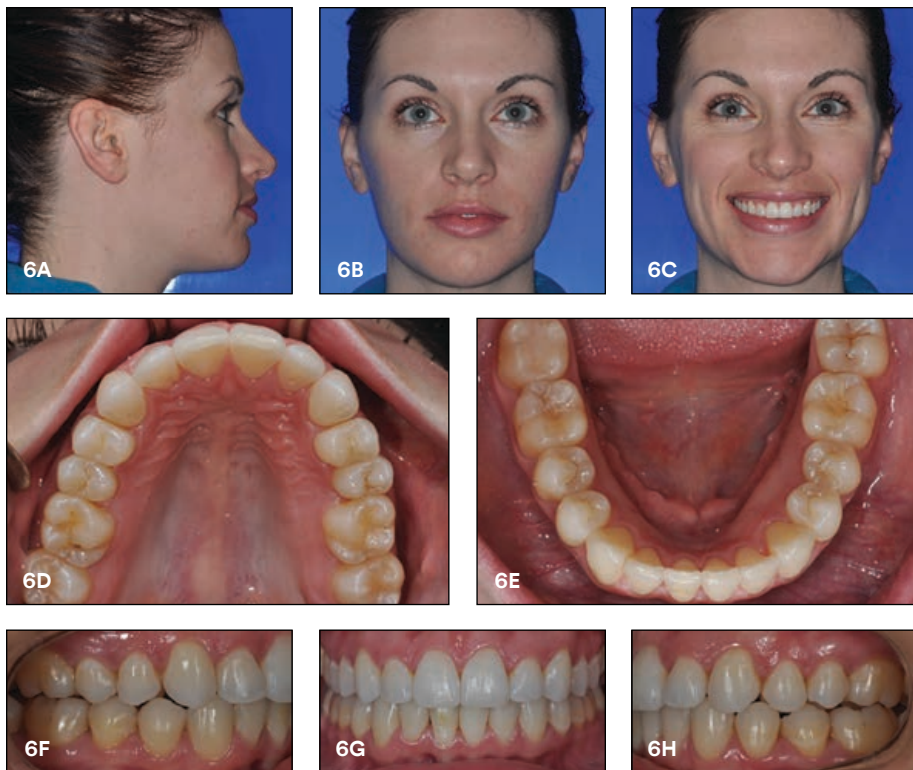

Figure 6A-H: Final photos.

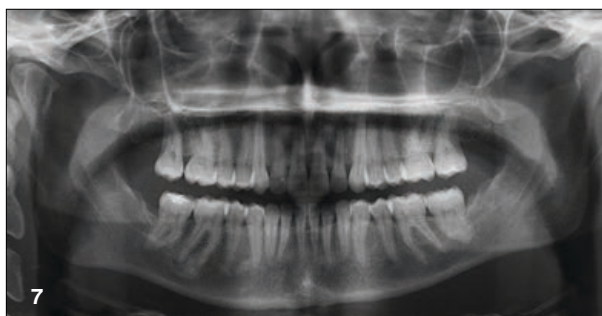


Figure 7: Final X-ray.

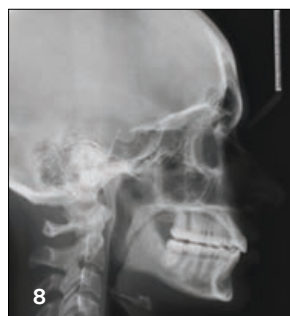

Figure 8: Final cephalometric analysis.

Initial and Final Comparison

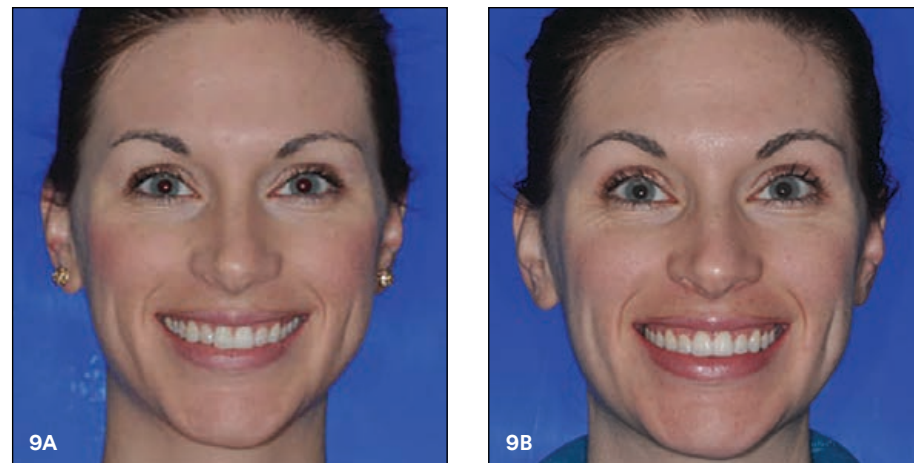

Figure 9A-B: Initial vs. final photos.

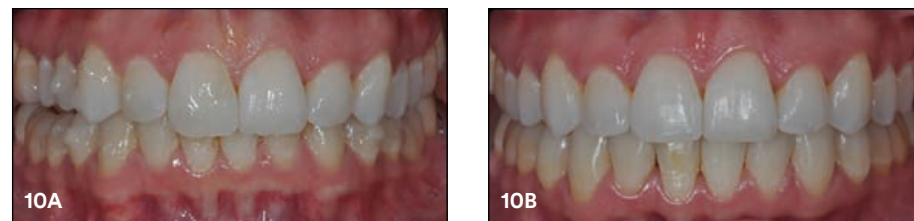


Figure 10A-B: Initial vs. final photos.

Doctor's Notes

This case report demonstrates that adult patients who may not be particularly good candidates for aligner therapy are extremely receptive to the new generation of esthetic brackets.

Case photos provided by Dr. Anoop Sondhi.

3M, Clarity, and Sondhi are trademarks of 3M. Used under license in Canada. All other trademarks are property of their respective owners. © 3M 2016. All rights reserved.

3MSM Health Care Academy

Class III

Missing teeth, tight teeth, Class III cuspid relationship

This case is a sample of the cases contained in the newly published Clarity™ ADVANCED Ceramic Bracket Case Overview booklet. To view the complete publication, visit 3M.com/ortho and follow the links to the Clarity ADVANCED Brackets page.



Dr. Patrice Pellerin

Dr. Pellerin received his post graduate Certificate in Orthodontics in 1991 from the University of Montreal. Before orthodontics, he practiced general dentistry for four years after earning his dental degree from the University of Montreal in 1985. Since 1991, he has maintained a solo private practice in Lachine, Quebec. In 1998, Dr. Pellerin converted his practice to a fully aesthetic practice.

He is referred to by his peers as the grandfather of the completely aesthetic practice. He has lectured worldwide to share his practice philosophy of highest aesthetics without compromise to accomplish treatment. Dr. Pellerin also currently teaches lingual and aesthetic orthodontics to the residents at the University of Montreal and University of Winnipeg. He has been an active member of the 3M Unitek Advisory Committee for Aesthetic Appliances since 2003, as well as a 3M Advocate for the use of aesthetic appliances since 2004.

Patient

Male (S.A.); 36 years, 11 months

Patient's Main Concern

Had extraction of teeth in the upper jaw as a teenager, teeth are very tight, do some more teeth need to be removed?

X-ray Findings

- Permanent dentition
- Missing two upper bicuspid (UR4, UL4?)
- Wisdom teeth erupted
- Pneumatized maxillary sinuses
- Condylar irregularity (left), and asymmetrical

Dental Analysis

- Class II molar relationship, Class III cuspid relationship
- Inadequate OJ/OB (end to end relation)
- Missing two upper bicuspid
- Crossbite of teeth UR6, UR2, UL2
- Dental crowding (-6 mm upper arch, -10 mm lower arch)
- Weak attached gingiva, UR6, UL6, LL5

Treatment Plan

- Upper – Clarity™ ADVANCED Ceramic Brackets 0.018 slot – MBT™ System prescription (APC™ Flash-Free Adhesive)
- Indirect bonding using bonding open bite charts 4.5 mm
- Extraction of LL5, LR5
- Sectional direct bonding (second molar to first bicuspid) using bonding open bite charts 5 mm, with active tie back retraction
- When the space is adequate direct bonding lower cuspid to cuspid with open bite charts 5 mm
- Class III and vertical elastic mechanics
- Reassess the vertical relationship and patient comfort with the wisdom teeth

Treatment 27 months (October 2012 – January 2015)

Treatment	27 months (October 2012 – January 2015)		
Mx	October 2012	Indirect	14 SE (7s), 16×16 SE (6s), 16×22 SE (6s), 17×25 Classic (25s), 16×22 SE (5s) 17×25 Classic to the end
Md	December 2012	Direct	16×16 SE (6s), 17×25 Classic (12s), 16×16 SE (14s), 14 (12s), 16×16 (12s), 17×25 Classic to the end
# of visits	24		
Emergencies	0		

Retention

- Fixed lingual wires 0.018 TMA
- Upper canine to canine/lower first bicuspid to first bicuspid
- Lower Essix retainer nighttime use only

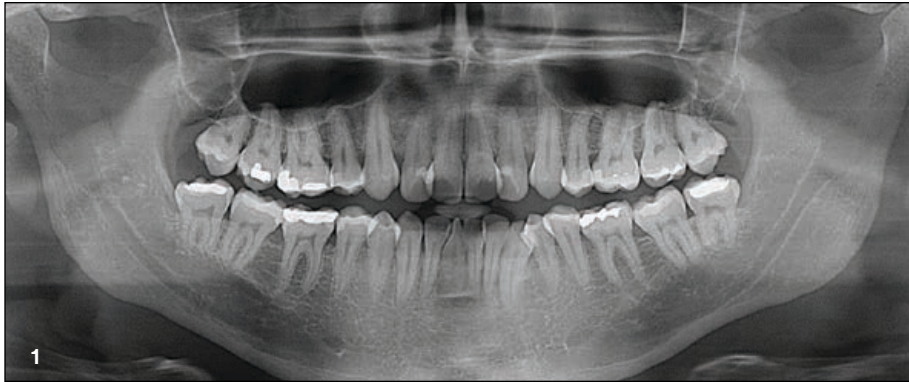

Figure 1: Initial X-ray.

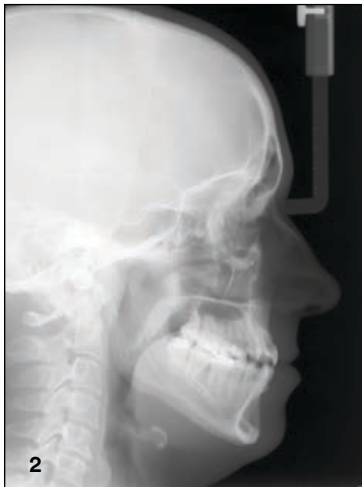

Figure 2: Initial cephalometric analysis.

Cephalometric Analysis					
SNA (°)	81.5	82.0	3.5	-0.1	
SNB (°)	78.6	80.9	3.4	-0.7	
ANB (°)	2.9	1.6	1.5	0.9	
Maxillary Depth (FH-NA) (°)	94.1	90.0	3.0	1.4	*
Facial Angle (FH-NPo) (°)	91.0	89.6	3.0	0.5	
FMA (MP-FH) (°)	24.5	22.9	4.5	0.4	
UFH:LFH, Upper (N-ANS/N-Gn) (%)	42.4	45.0	1.0	-2.6	**
U-Incisor Protrusion (U1-APo) (mm)	2.9	6.0	2.2	-1.4	*
U1 – Palatal Plane (°)	117.7	110.0	5.0	1.5	*
L1 Protrusion (L1-APo) (mm)	1.2	2.7	1.7	-0.9	
IMPA (L1-MP) (°)	87.9	95.0	7.0	-1.0	*
Interincisal Angle (U1-L1) (°)	130.9	130.0	5.0	0.2	
Upper Lip to E-Plane (mm)	-8.9	-8.0	2.0	-0.4	
Lower Lip to E-Plane (mm)	-3.8	-2.0	2.0	-0.9	
Nasolabial Angle (Col-Sn-UL) (°)	113.1	102.0	8.0	1.4	*
Maxillary Length (ANS-PNS) (mm)	50.2	51.6	4.3	-0.3	
Mandibular Length (Go-Gn) (mm)	73.4	65.9	5.5	1.4	*
Facial Convexity (G'-Sn-Po') (°)	169.2	154.0	5.6	2.7	**
Wits Appraisal (mm)	-0.2	-1.0	1.0	0.8	
SUMMARY ANALYSIS					
Class I Molar Relationship					
Skeletal Class II (A-Po)					
Skeletal Class I (ANB)					
Protrusive Maxilla (A-N)					

Table 1: Cephalometric analysis.

Initial

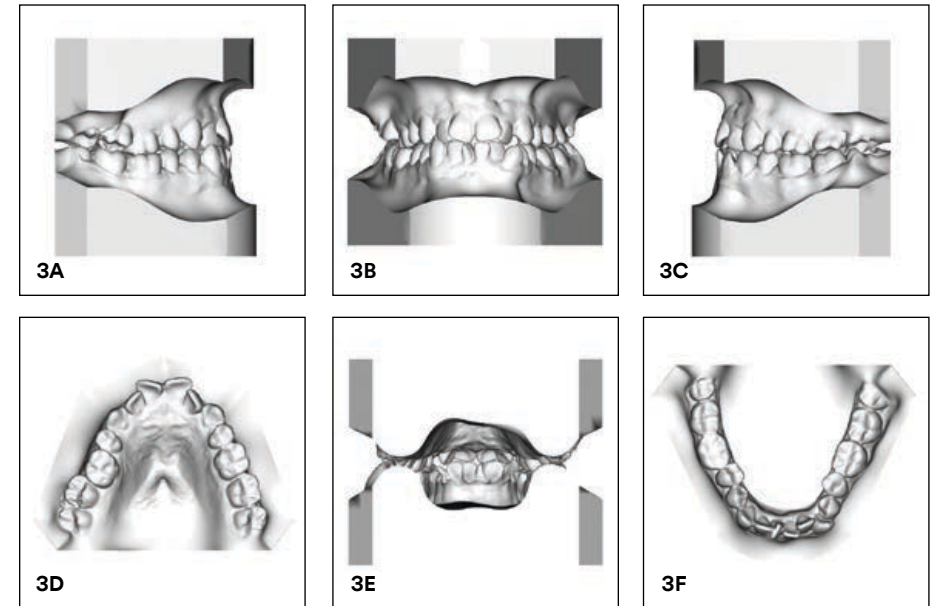


Figure 3A-F: Initial dental analysis.

Initial

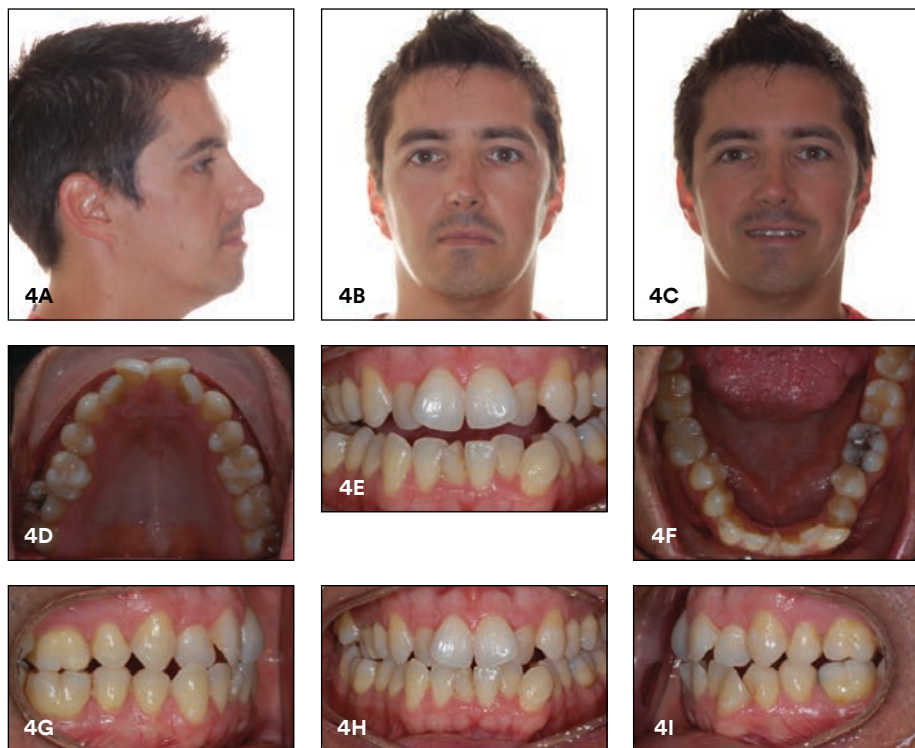


Figure 4A-I: Initial photos.

Treatment Plan (1)

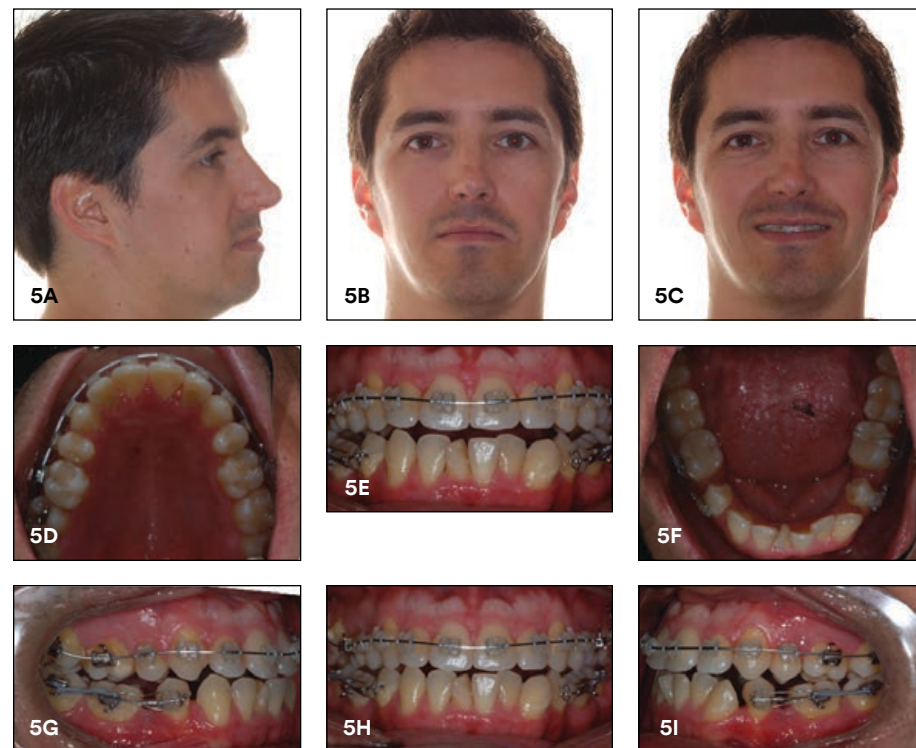


Figure 5A-I: Treatment plan (1) photos.

Treatment Plan (2)

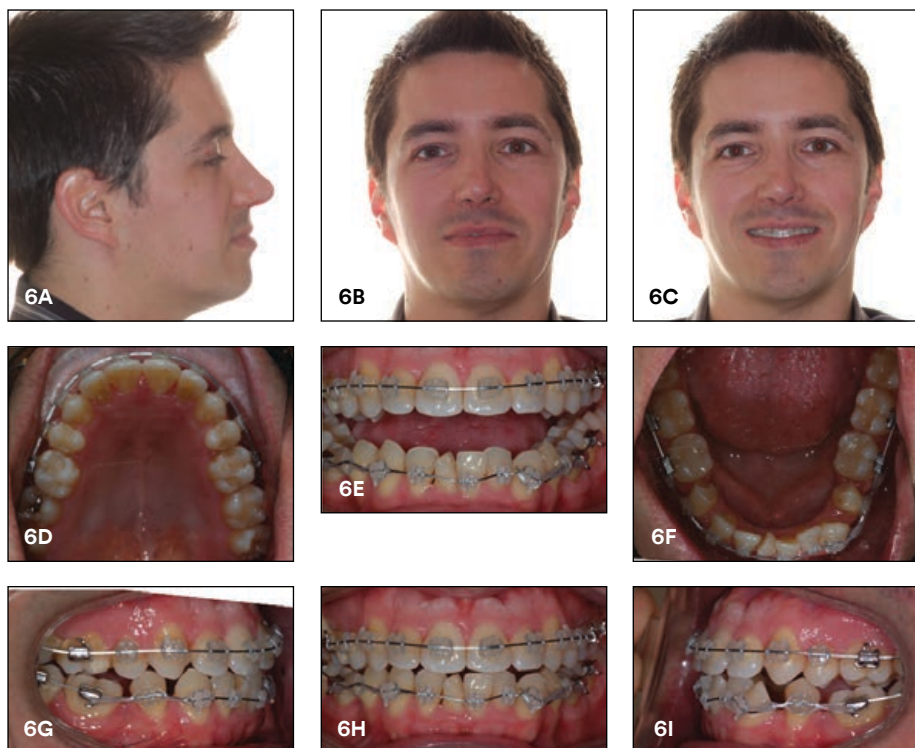


Figure 6A-I: Treatment plan (2) photos.

Mid-Treatment

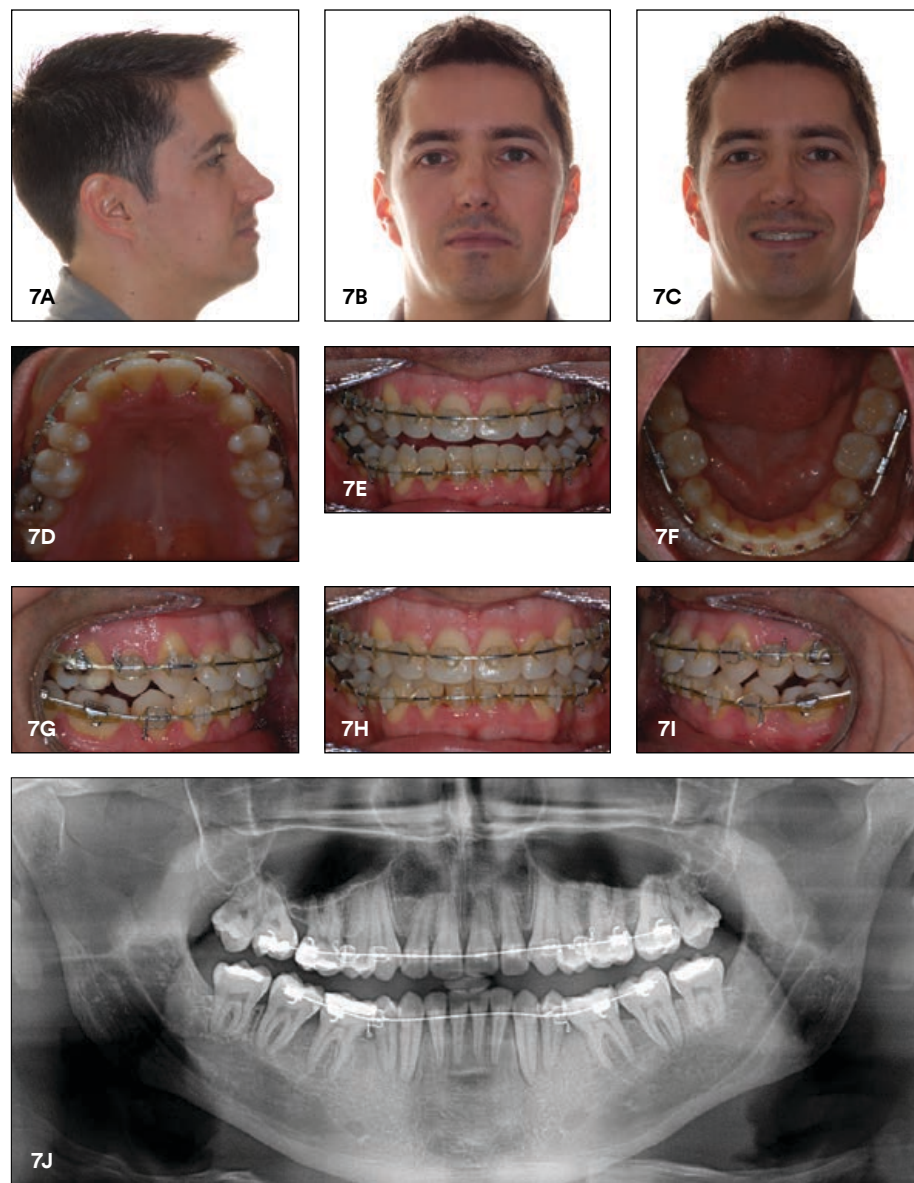


Figure 7A-J: Mid-treatment photos.

Active Tie-Back Retraction

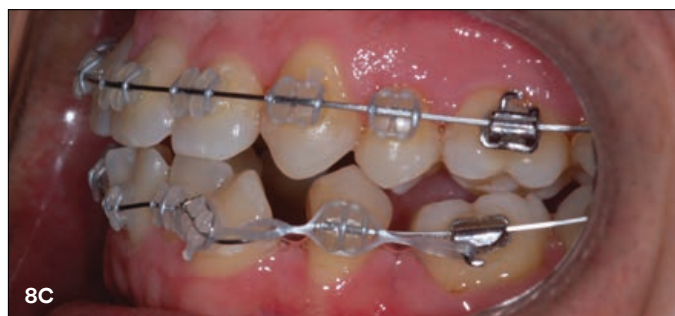
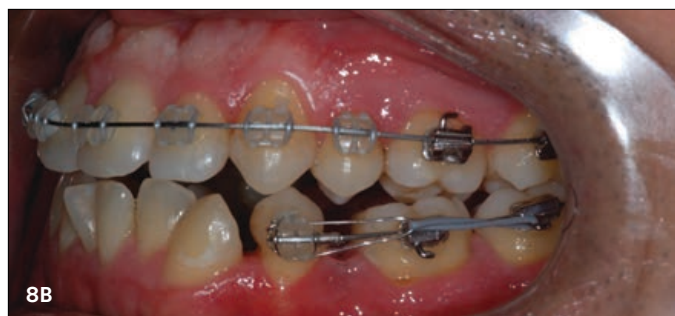
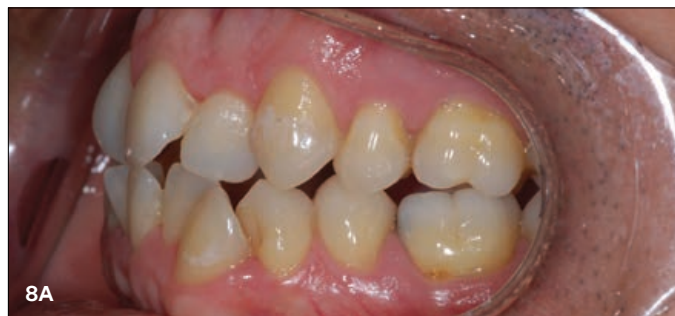Figure 8A-C: Active tie-back retraction photos.

Retention

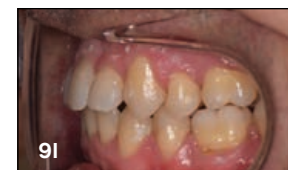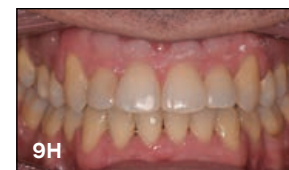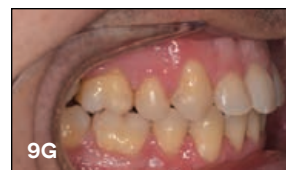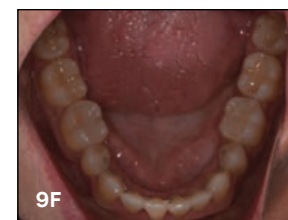



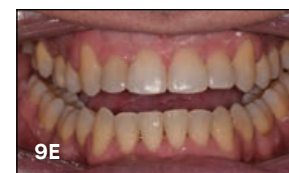
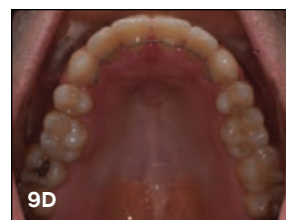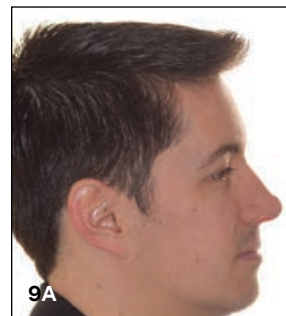Figure 9A-I: Retention photos.

Initial and Final Comparison




Figure 10A-B: Initial vs. final photos.

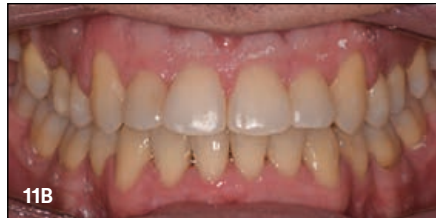
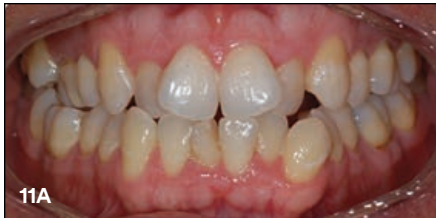
Figure 11A-B: Initial vs. final photos.

Doctor's Notes

1. The retraction is completed using some of the mechanical concepts from Dr. Burstone's segmented arch technique, controlling the side effects, but with a modern twist. You don't have to reinvent the wheel. Stick to basic biomechanics and you will always have control, or at least you will know what to expect.

Case photos provided by Dr. Patrice Pellerin.



3M Oral Care
2510 Conway Avenue
St. Paul, MN 55144-1000 USA
Phone 1-800-423-4588
Web 3M.com/ortho

3M Canada
Health Care Division
300 Tartan Dr.
London, ON N5V 4M9 Canada
Phone 1-800-443-1661

3M, "3M Science. Applied to Life.", APC, AlastiK, Clarity, Forsus, Incognito, MBT, SmartClip, Sondhi, Unitek, and Victory Series are trademarks of 3M. 3M Health Care Academy is a service mark of 3M. Used under license in Canada. All other trademarks are property of their respective holders. © 3M 2016. All rights reserved. 70-2021-5283-4 1605