

# **Management of a Peristomal Ulcer Using a Calcium Alginate Dressing with a Sacral-Shaped Transparent Adhesive Dressing**

## **A Case Study**

Bridget O'Brien, RN, BSN, CETN and  
Crina V. Floruta, MSN, RN, CS, ANP, CETN;  
The Cleveland Clinic Foundation, Cleveland, OH

# Management of a Peristomal Ulcer Using a Calcium Alginate Dressing with a Sacral-Shaped Transparent Adhesive Dressing

## A Case Study

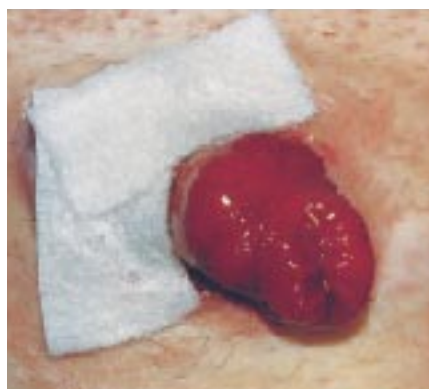
Bridget O'Brien, RN, BSN, CETN and Crina V. Floruta, MSN, RN, CS, ANP, CETN; The Cleveland Clinic Foundation, Cleveland, OH

### Overview

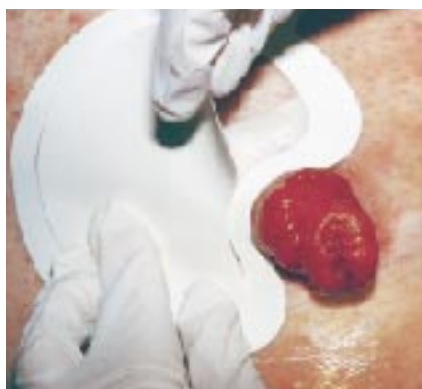Peristomal ulcers, regardless of etiology, present a challenging clinical situation. It is necessary to dress the wound, manage the wound exudate and develop an effective pouching system. Because exudate from the peristomal wound interferes with ostomy appliance adherence, peristomal ulcers have traditionally been managed with nonadherent pouching systems. Recent advances in wound care products have expanded the range of

treatment options for peristomal ulcers which provide security, extended wear-time and cost-effectiveness.<sup>1</sup>

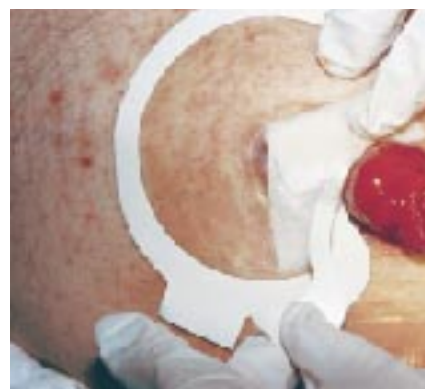Calcium alginate dressings are ideal for the management of moderate-to highly-exudating wounds, absorbing up to 20 times their weight in exudate.<sup>2,3</sup> Their high absorbency provides effective wound exudate management, requiring



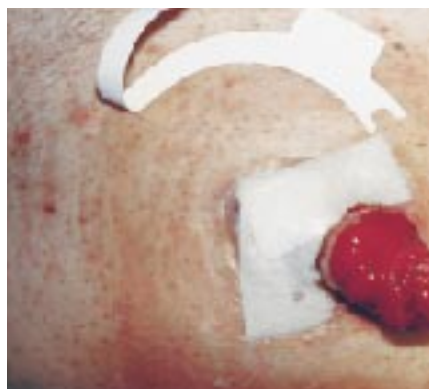**Figure 1.** 3M™ Tegagen™ HI Alginate Dressing is applied to the peristomal ulcer.



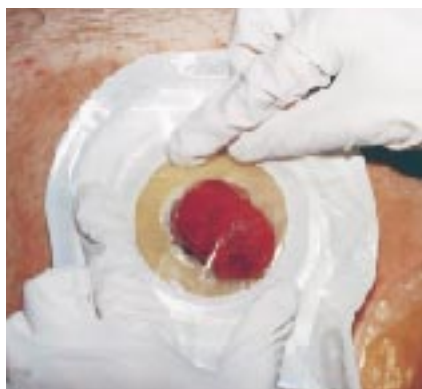**Figure 2.** 3M™ Tegaderm™ HP Transparent Dressing (#9543) is positioned over the calcium alginate dressing.



**Figure 3.** The transparent dressing is secured over the alginate dressing.



**Figure 4.** The paper frame of the transparent dressing is peeled away.



**Figure 5.** The one-piece drainable pouch is positioned and secured over the transparent dressing.

less frequent dressing changes than gauze. A secondary dressing must be used to secure alginates in place. Transparent adhesive dressings, when used as a secondary dressing, protect the wound bed from bacteria and environmental contaminants, secure the primary dressings in place, and minimize leakage of wound exudate.<sup>4</sup> Transparent dressings also provide a dry surface allowing for effective adhesive adherence of the pouching system.

This case study illustrates the effectiveness of using an alginate dressing with a sacral-shaped transparent adhesive dressing for the treatment of a peristomal ulcer. The alginate dressing managed ulcer drainage for 2 to 3 days. The “curved” shape of the transparent film dressing accommodated the contours of the peristomal wound, sealed the alginate dressing in place, and provided a surface for the adherence of the ostomy appliance.

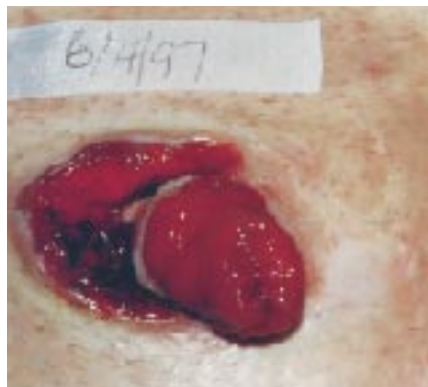
## Case History

A 30-year-old male with a history of colitis presented with a non-healing peristomal ulcer. The patient had a total abdominal colectomy with end ileostomy in October 1995. The peristomal ulcer developed in March 1997. At presentation, the ulcer measured 4.6cm x 1.4cm. The ulcer etiology was unknown but it apparently developed as a result of severe chemical irritation aggravated by rubbing of the two-piece pouching system. No diagnosis of pyoderma gangrenosum was made.

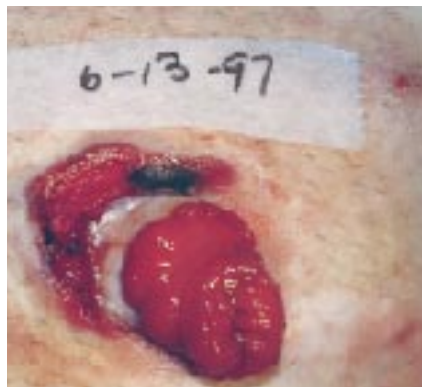
After 12 weeks of treatment with various products including foam, alginate and hydrocolloid dressings there was essentially no reduction in wound size. At the end of this period, the ulcer actually increased in size having measurements of 4.5cm x 2.5cm.

## Treatment Plan

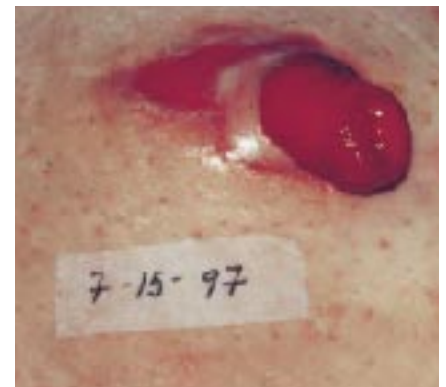
Sharp debridement of the exuberant hypergranulation tissue was completed by the colorectal surgeon. Tegagen HI alginate dressing was placed on the wound bed covered by Tegaderm HP transparent dressing (#9543) (Figures 1 through 5). A one-piece drainable pouch was selected to avoid excess pressure and friction. The patient changed the dressing every 2 to 3 days. The patient returned to the clinic for re-evaluation approximately every other week.



**Figure 6.** The peristomal ulcer after surgical debridement at initiation of treatment.



**Figure 7.** The peristomal ulcer after approximately 1 1/2 weeks of treatment.



**Figure 8.** The peristomal ulcer after approximately 6 weeks of treatment.

## Results

- Pre-treatment ulcer size: 4.5cm x 2.5cm (Figure 6)
- Day 10 ulcer size: 3.2cm x 4.5cm (Figure 7)
- Week 3 ulcer size: 3.0cm x 1.8cm
- Week 6 ulcer size: 2.5cm x 1.8cm (Figure 8)

## Conclusion

The combination of the two dressings and the one-piece drainable pouch was a viable alternative in the management of a peristomal ulcer. The products were found to be cost-effective by providing a two-to three-day wear-time compared to previous daily changes. The combination of the two dressings was highly effective in reducing the peristomal ulcer size by approximately two-thirds over six weeks. Their use simplified the procedure enough for the patient to become independent and to resume his regular activities.

## References

1. Hampton, Beverly G., and Bryant, Ruth A.: Ostomies and Continent Diversions. St. Louis: Moseby, Year Book Inc., 1992.
2. Gensheimer D. (1993). A Review of Calcium Alginates. Ostomy/Wound Management. 39 (1), 34–38.
3. Fanucci, D., Seese, J. (1991). Multi-faceted Use of Calcium Alginates. Ostomy/Wound Management 37, Nov./Dec., 16–22.
4. Walker, D. "Back to Basics. Choosing the Correct Wound Dressing." American Journal of Nursing 96 (9): 35–39. 1996.



### Health Care

3M Center, Building 275-4W-02  
St. Paul, MN 55144-1000  
USA  
1 800 228-3957  
healthcare@3M.com  
www.3M.com/healthcare

### 3M Canada Inc.

Post Office Box 5757  
London, Ontario N6A 4T1  
Canada  
1 800 563-2921



40% Pre-consumer waste paper  
10% Post-consumer waste paper

H.I. 4509  
Printed in U.S.A.  
© 3M 1998 70-2009-1575-2