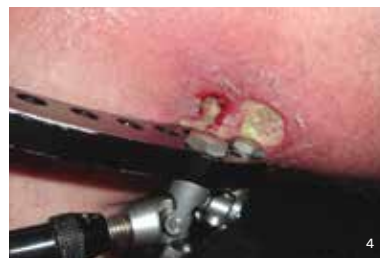

Additional Pressure Injury Definitions¹



Medical Device-Related Pressure Injury:

This describes an etiology. Medical device-related pressure injuries result from the use of devices designed and applied for diagnostic or therapeutic purposes. The resultant pressure injury generally conforms to the pattern or shape of the device. The injury should be staged using the staging system.

Mucosal Membrane Pressure Injury:

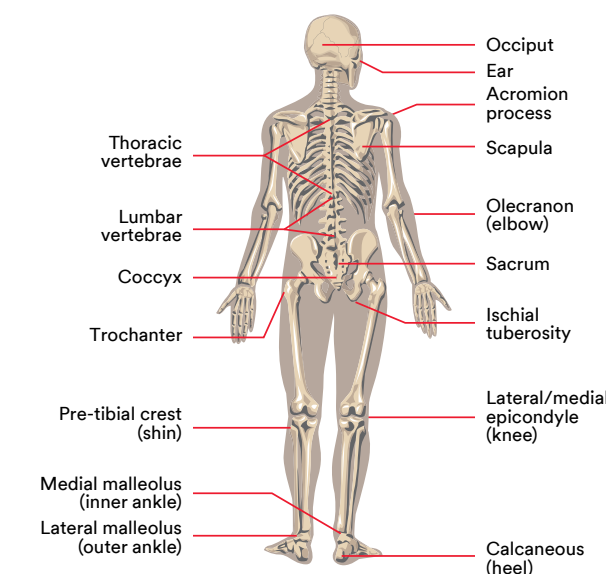
Mucosal membrane pressure injury is found on mucous membranes with a history of a medical device in use at the location of the injury. Due to the anatomy of the tissue, these ulcers cannot be staged.

Distinguishing Between IAD and Pressure Injuries

Incontinence-Associated Dermatitis (IAD) is severe inflammation caused by liquid stool, mixed incontinence, or urine, which can lead to destruction of the epidermis. Distinguishing IAD from Stage I or Stage II pressure injuries can be difficult, but if your patient/resident is not incontinent, they cannot have IAD. Below are additional differentiators between the two conditions.³

	IAD	Pressure Injury
History	Urinary and/or fecal incontinence	Exposure to pressure/shear
Symptoms	Pain, burning, itching, tingling	Pain
Location	Affects perineum, perigenital area, buttocks, gluteal fold, medial and posterior aspects of upper thighs, and/or lower back; may extend over bony prominence	Usually over a bony prominence or associated with location of a medical device
Shape/edges	Affected area is diffused with poorly defined edges/may be blotchy	Distinct edges or margins
Presentation/depth	Intact skin with erythema (blanchable or non-blanchable), partial-thickness skin loss	Presentation varies from intact skin with non-blanchable erythema to full-thickness skin loss. Base of wound may contain non-viable tissue.
Other	Secondary superficial skin infection (e.g., candidiasis) may be present	Secondary soft tissue infection may be present

Frequent Anatomical Sites of Pressure Injury



Pressure Injury Assessment Parameters

Perform head-to-toe assessment upon admission and intervals consistent with patient condition and facility policy and procedures.

- Location/distribution
- Dimensions - length - width - depth
- Exudate - color - consistency - odor - amount
- Condition - base - surrounding - skin - sinus tracts/undermining
- Infection signs or symptoms - local vs. systemic
- Pain
- Presence of medical device(s)

Pressure Injury Staging Guide

A pressure injury (also known as a pressure ulcer) is localized damage to the skin and underlying soft tissue usually over a bony prominence or related to a medical or other device. The injury can present as intact skin or an open ulcer and may be painful. The injury occurs as a result of intense and/or prolonged pressure or pressure in combination with shear. The tolerance of soft tissue for pressure and shear may also be affected by microclimate, nutrition, perfusion, co-morbidities, and condition of the soft tissue.¹ This pocket guide is designed to be a reference tool for clinicians to help stage pressure injury tissue damage.

Stage 1 Pressure Injury:
Non-blanchable erythema of intact skin

Stage 2 Pressure Injury:
Partial-thickness skin loss with exposed dermis

Stage 3 Pressure Injury:
Full-thickness skin loss

Stage 4 Pressure Injury:
Full-thickness skin and tissue loss

Unstageable Pressure Injury:
Obscured full-thickness skin and tissue loss

Deep Tissue Pressure Injury:
Persistent non-blanchable deep red, maroon, or purple discoloration

¹Pressure injury definition and descriptions from the National Pressure Ulcer Advisory Panel (NPUAP) 2016 Staging Consensus Conference. Available here: <http://www.npuap.org/resources/educational-and-clinical-resources/npuap-pressure-injury-stages/>. Used with permission of the National Pressure Ulcer Advisory Panel, 2018.

²NPUAP.org ©2011 Gordian Medical, Inc. dba American Medical Technologies.

³Beeckman D, et al. Proceedings of the Global IAD Expert Panel. Incontinence-Associated Dermatitis: Moving Prevention Forward. Wounds International 2015.

⁴NPUAP copyright and used with permission.

For more information, visit 3M.com/PressureInjury, contact your 3M Medical Solutions Division representative or call the 3M Helpline at 1-800-228-3957.



3M Medical Solutions Division
3M Health Care
2510 Conway Ave.
St. Paul, MN 55144 USA

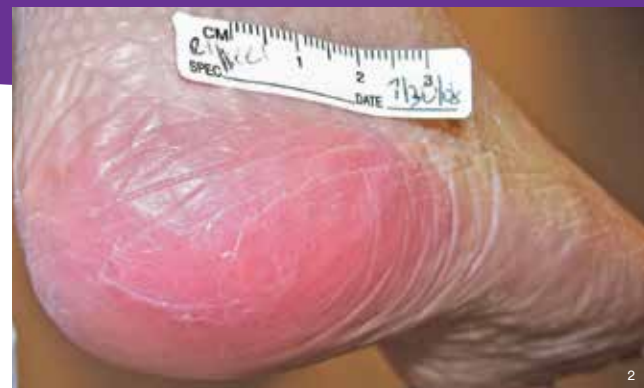Phone 1-800-228-3957
Web 3M.com/Medical

3M is a registered trademark of 3M.
Please recycle. Printed in USA.
© 3M 2018. All rights reserved.
70-2008-3143-9



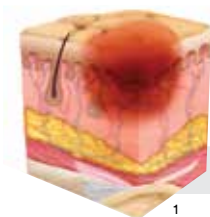3M Medical Solutions Division

Pressure Ulcer/Injury (PU/I) Staging Guide

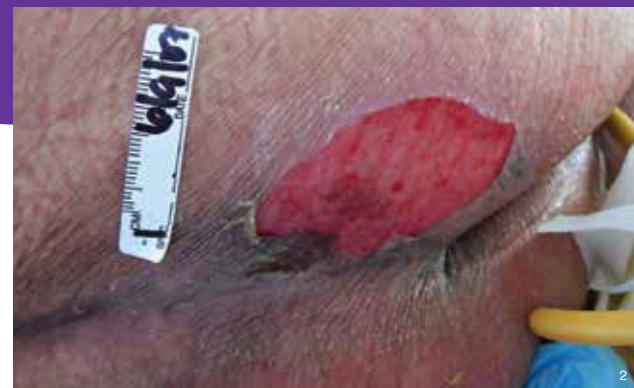

Stage 1 Pressure Injury:
Non-blanchable erythema of intact skin

Intact skin with a localized area of non-blanchable erythema, which may appear differently in darkly pigmented skin. Presence of blanchable erythema or changes in sensation, temperature, or firmness may precede visual changes. Color changes do not include purple or maroon discoloration; these may indicate deep tissue pressure injury.¹

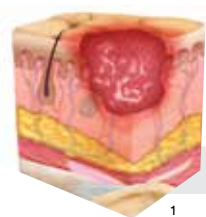

Stage 1

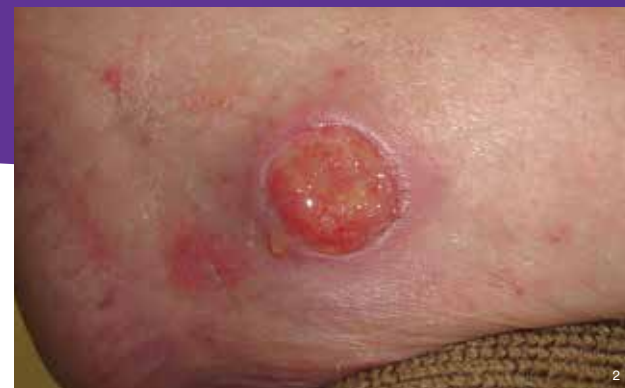

Stage 2 Pressure Injury:
Partial-thickness skin loss with exposed dermis

The wound bed is viable, pink or red, moist, and may also present as an intact or ruptured serum-filled blister. Adipose (fat) is not visible and deeper tissues are not visible. Granulation tissue, slough, and eschar are not present. These injuries commonly result from adverse microclimate and shear in the skin over the pelvis and shear in the heel. This stage should not be used to describe Moisture-Associated Skin Damage (MASD), including Incontinence-Associated Dermatitis (IAD), Intertriginous Dermatitis (ITD), Medical Adhesive-Related Skin Injury (MARS), or traumatic wounds (skin tears, burns, abrasions).¹

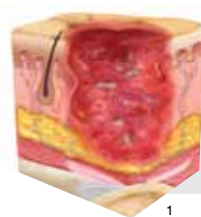

Stage 2

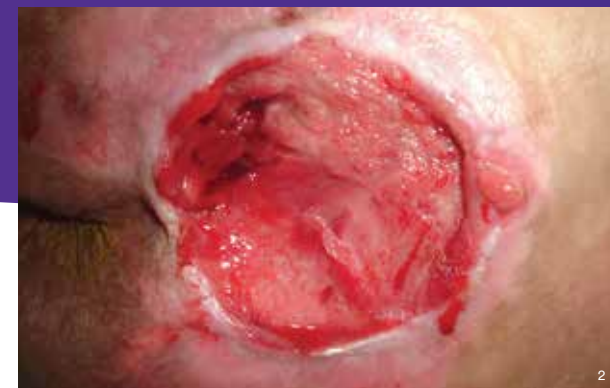

Stage 3 Pressure Injury:
Full-thickness skin loss

Full-thickness loss of skin, in which adipose (fat) is visible in the ulcer, and granulation tissue and epibole (rolled wound edges) are often present. Slough and/or eschar may be visible. The depth of tissue damage varies by anatomical location; areas of significant adiposity can develop deep wounds. Undermining and tunneling may occur. Fascia, muscle, tendon, ligament, cartilage, and/or bone are not exposed. If slough or eschar obscures the extent of tissue loss, this is an Unstageable Pressure Injury.¹

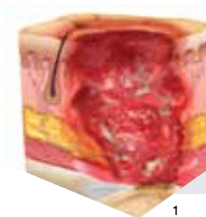

Stage 3

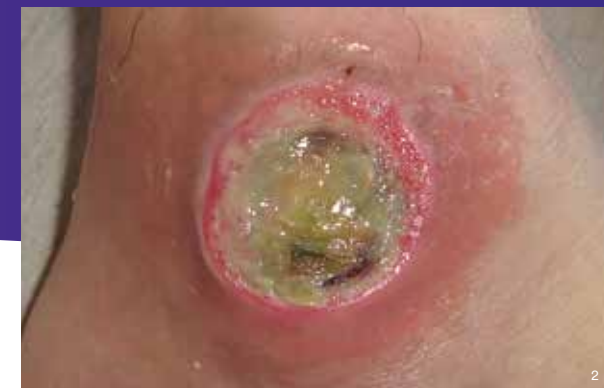

Stage 4 Pressure Injury:
Full-thickness skin and tissue loss

Full-thickness skin and tissue loss with exposed or directly palpable fascia, muscle, tendon, ligament, cartilage, or bone in the ulcer. Slough and/or eschar may be visible. Epibole (rolled edges), undermining, and/or tunneling often occur. Depth varies by anatomical location. If slough or eschar obscures the extent of tissue loss, this is an Unstageable Pressure Injury.¹

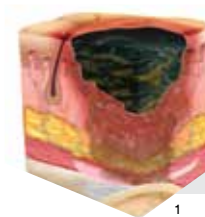


Stage 4

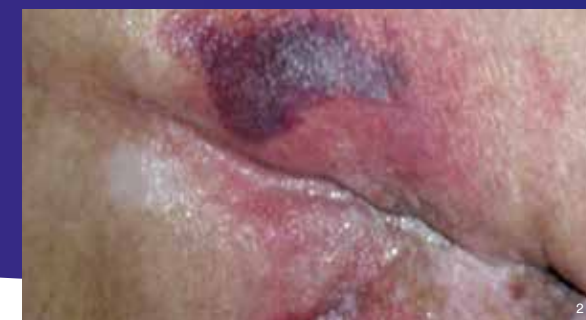

Unstageable Pressure Injury:
Obscured full-thickness skin and tissue loss

Full-thickness skin and tissue loss in which the extent of tissue damage within the ulcer cannot be confirmed because it is obscured by slough or eschar. If slough or eschar is removed, a Stage 3 or Stage 4 pressure injury will be revealed. Stable eschar (i.e., dry, adherent, intact without erythema or fluctuance) on the heel or ischemic limb should not be softened or removed.¹




Unstageable



Deep Tissue Pressure Injury:
Persistent non-blanchable deep red, maroon, or purple discoloration

Intact or non-intact skin with localized area of persistent non-blanchable deep red, maroon, or purple discoloration, or epidermal separation revealing a dark wound bed or blood-filled blister. Pain and temperature change often precede skin color changes. Discoloration may appear differently in darkly pigmented skin. This injury results from intense and/or prolonged pressure and shear forces at the bone-muscle interface. The wound may evolve rapidly to reveal the actual extent of tissue injury or may resolve without tissue loss. If necrotic tissue, subcutaneous tissue, granulation tissue, fascia, muscle, or other underlying structures are visible, this indicates a full-thickness pressure injury (Unstageable, Stage 3, or Stage 4). Do not use DTPI to describe vascular, traumatic, neuropathic, or dermatologic conditions.¹



Suspected Deep Tissue Injury